

*Hydroa*  
Bowen, J.T.

HYDROA VACCINIFORME, BAZIN;  
HUTCHINSON'S SUMMER ERUP-  
TION; WITH HISTOLOGICAL  
EXAMINATION.

BY

JOHN T. BOWEN, M.D. (Boston),  
Assistant Physician for Skin Diseases,  
Massachusetts General Hospital.

REPRINTED FROM THE JOURNAL OF  
CUTANEOUS AND GENITO-URINARY  
DISEASES

FOR MARCH, 1884.

LIBRARY.  
SURGEON GENERAL'S OFFICE

JUL 20 1909

832





LIBRARY.  
SURGEON GENERAL'S OFFICE

832

JUL 20 1909

HYDROA VACCINIFORME, BAZIN; HUTCHINSON'S SUMMER ERUPTION; WITH HISTOLOGICAL EXAMINATION.

BY

JOHN T. BOWEN, M.D.,

Boston.

Assistant Physician for Skin Diseases, Massachusetts General Hospital.

A CONSIDERABLE number of cases of hydroa vacciniforme are now on record, of late mostly from English, German and Norwegian sources. No instance of the disease has been reported in America, however, so far as I am aware, and no histological examinations of excised lesions are anywhere recorded. For these reasons, if apology is necessary, the following case is reported.

J. G., ten years of age, male, came with his father to the skin department of the Massachusetts General Hospital on August 30, 1893, from Lawrence, Mass., his native place. Father is an American, mother Scotch; both healthy, and no family history of importance could be elicited. Patient is an only child. The only other diseases that he has had are measles and typhoid fever. The present affection first showed itself at five years of age, during the Summer, when the boy was out of doors in the fields and woods a large portion of the time. Since then the affection has recurred constantly in successive outbreaks, mostly during the summer months and always *after exposure to the sun*. In Winter there have usually been a few mild attacks, and the father thinks that he has never been entirely free for a longer period than two months at a time. The outbreaks were confined to the face until one year ago, when



similar appearances were noted on the hands; but on the latter there have not been in all more than two dozen lesions. At the beginning of some of the attacks there have been nausea, vomiting and malaise, but not in all. There has always been considerable itching of the affected parts. Of late the attacks have appeared rather less frequently, and there has not been so much fluid in the lesions. The appetite and general health are said to be good.

The patient when seen presented the appearance of a rather undersized, pale and anæmic boy, of distinctly light complexion. The face is covered with closely aggregated and confluent pits, of exactly the contour and general appearance of those left by variola, and the boy has repeatedly been asked by strangers when he had small-pox. The deepest scars and most confluent pits are upon the nose and malar prominences, so that the nose appears attenuated. The forehead is but slightly pitted, the scars diminishing in number and depth toward the edge of the hairy scalp, where they cease entirely. The ears are covered with cicatricial depressions, especially marked upon the helix. (Fig. 1.)

The active lesions consist first of small red papules and vesicles, of which a number are now to be seen, and which the father, an intelligent man, declares to be the primary manifestation. The minute papule rapidly becomes vesicular, and vesiculo-pustular, and of these there are a large number scattered over the face and ears. The lesions may progress no farther than this, or they may enlarge still more until those of the largest size represent rounded, vesicular elevations with a distinct and sometimes very marked *umbilication* in the center. The umbilicated center is surrounded by a ring of clear or turbid fluid, while the periphery is occupied by an erythematous halo. All of the vesicles are not umbilicated, but only, as a rule, those furthest advanced. The center presents, besides the umbilication, a peculiar *dark blue or black* aspect, which can be seen on close examination to be due to the floor of the lesion, and not to the contents of the vesicle. In many of the lesions this dark floor contains several *distinct points of a deeper hue* than the rest. These vesicular and pustular lesions may become confluent, as is seen prominently upon the ears.

The next stage, which is also represented on this patient, consists in the crusting of the vesicular center. The dark blue or black center, with its vesicular covering, gives place to a thick black crust, which is very adherent, and, when finally



thrown off, leaves a deep, usually circular, "punched out" pit, which is at first of a deep red color. In several instances new lesions could be seen forming within an old pit or scar. There was no pigmentation. The hands show upon their dorsal sur-

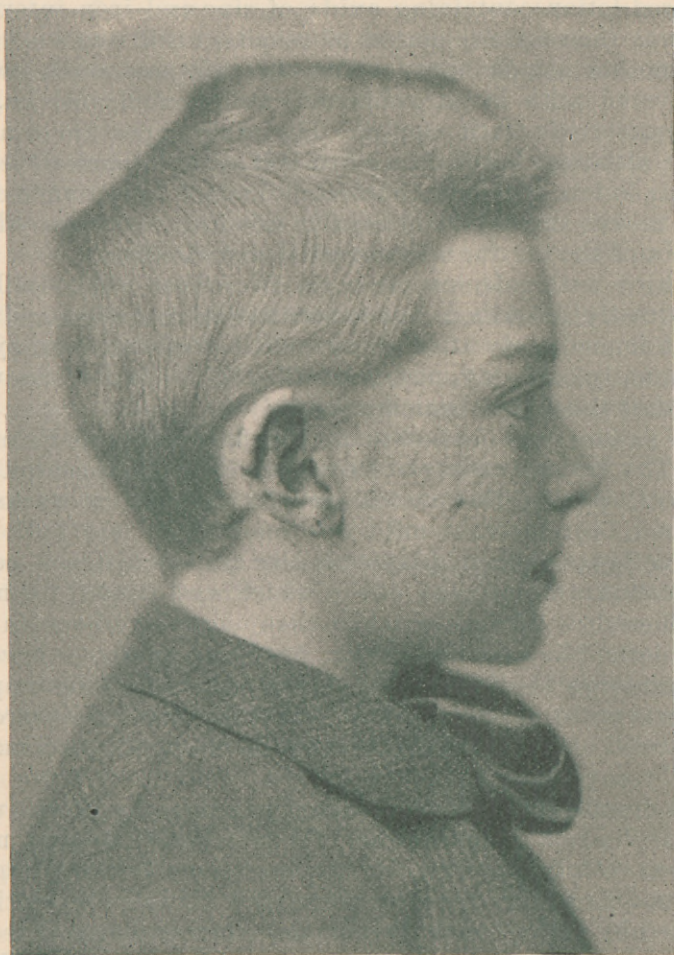

FIG. 1.

faces a dozen or fifteen pits upon each, with one or two small vesicular lesions. These appearances do not extend above the wrists, and there has never been a lesion upon any other part of the body than the face and hands. The cervical and submaxil-



lary glands are considerably enlarged, as are also the inguinal. The other glands are normal. There are no lesions or abnormal appearances upon the mucous membranes.

On October 27th the patient was seen again. The lesions had disappeared more quickly than usual under the use of a carbolized lotion containing oxide of zinc and iron internally. There was then a short period of respite, until two weeks ago, when another attack began. The ears are now much swollen and covered with large, confluent, umbilicated vesicles, with the characteristic dark center. The same appearances are on the face, although fewer than when last seen. A well-developed vesicular lesion, with the characteristic dark appearance of the center, as seen through the vesicular covering, was removed from the helix of the ear for microscopical examination.

A third outbreak was seen on December 13th, similar to those already described, but somewhat more intense. It had come on immediately after going out of doors on a sunny, but exceptionally cold day, and according to the father the whole face had at the outset been much swollen.

The patient was last seen in the first week of February, 1894. The lesions seen on December 13th disappeared soon afterward, leaving the customary pits, but a few weeks ago there had been another mild outbreak which was still to be seen. A few small, primary vesicular lesions without central discoloration were present, one of which was excised for microscopical study. The patient had been using by advice an ointment colored black by lampblack, but this appears to have had no influence on the recurrence of the lesions. It was impossible, however, to determine how faithfully this procedure had been carried out. The disfigurement of the application made it naturally unpopular.

This disease was described many years ago by Bazin<sup>1</sup> under the name hydroa vaccini-forme. Of late years it seems not to have been seen by the French. At least, I can find nothing that corresponds to it in their writings, and Bazin's description is dismissed by Brocq<sup>2</sup> with the remark that it does not seem to correspond to any of the dermatoses actually classified. Hutchinson<sup>3</sup> in 1888 described the same affection under the title of "Summer eruption," while Handford<sup>4</sup> in an excellent article

<sup>1</sup> Cours de Semiotique Cutanée, 1855.

<sup>2</sup> Traitement des Maladies de la Peau, 1892, p. 347.

<sup>3</sup> Clinical Society's Transactions. Vol. xxii.

<sup>4</sup> Illustrated Med. News, 1889.



in the *Illustrated Medical News*, with colored illustration, showed that Hutchinson's cases and his own were the same as those described by Bazin as *Hydroa vacciniforme*. Since then cases have been reported by Jamieson,<sup>1</sup> Berliner,<sup>2</sup> Buri,<sup>3</sup> Broes van Dort,<sup>4</sup> Brooke<sup>5</sup> and Boeck.<sup>6</sup> H. Radcliffe-Crocker in the last edition of his text-book gives a very good description of the disease, adding that he has seen two cases himself.

A brief résumé of the important clinical features may not be out of place here. The disease begins, as a rule, in the first years of life, and is far more frequent in the male sex. It is excited by exposure to the sun and affects consequently the uncovered parts of the body almost exclusively, although Bazin notes its occurrence on the covered portions also. The bridge of the nose, cheeks and ears are prominently affected as well as the backs of the hands. In some cases the legs, when exposed, have been affected, but in my own case, although the boy frequently went barefoot in Summer, it had never appeared except on face and hands. The disease occurs in attacks, usually in the Summer season, the patients being comparatively free in Winter. My patient seems to have had more attacks in Winter than had occurred in the cases previously reported. Another peculiarity of my case is that the itching was quite a pronounced feature. As a rule there is no itching. The eruption may be accompanied at the outset by a slight constitutional disturbance, and begins either as vesicles or as small red elevations, which develop rapidly into vesicles and bullæ, and frequently become confluent. Many of these vesicular lesions become depressed in the center and resemble a vaccination vesicle. Around the umbilicated center there is often a ring of fluid, and a red areola surrounds the whole lesion. The center has a dark blue or black aspect, owing, as will be seen, to the necrotic and hæmorrhagic corium seen through the overlying vesicle. Some of the lesions may become purulent. The necrotic center becomes converted into a thick black crust, which is with difficulty detached, and when it finally falls off leaves a deep permanent scar almost exactly like that left by variola. The attacks last as a rule several weeks. They seem to become milder toward puberty, and to cease in adult age.

<sup>1</sup> Lancet, 18 August, 1889.

<sup>2</sup> Monatsheft, f. prakt. Derm. Bd. xi., 1890.

<sup>3</sup> Monatsheft, f. prakt. Derm. Bd. xiii., p. 181.

<sup>4</sup> Monatsheft, f. prakt. Derm., March, 1892.

<sup>5</sup> British Journal of Derm. Vol. iv., 1892.

<sup>6</sup> Archiv. f. Derm. und Syph., 1894, p. 23.



*Histological Examination.*

The well-developed lesion from the ear, which showed the characteristic dark appearance of the center, was hardened in absolute alcohol, imbedded in paraffine and cut in serial sections.

*A necrosis of the central portion of the nodule* proved, as was to be expected, the salient feature. The sections from the middle of the lesion, representing the most advanced stage of the process, showed, upon staining with various reagents—hæmatoxylin and eosine, Orth's carmine, safranin, etc.—a central portion consisting of both corium and epidermis, where the normal connective tissue and epithelial cells had nearly or quite lost their susceptibility to staining.

The outer horny layer was found to be unbroken and more or less distinctly stained by safranin or carmine. The lower layers of stratum corneum, together with the entire rete, were completely necrotic, giving no reaction to ordinary staining fluids, with the exception of an imperfect nuclear staining here and there. The middle and lower layers of the rete were converted into a reticular tissue, forming a network filled with granular detritus and an occasional leucocyte. This network was everywhere necrotic. At the border of the rete and corium the network ceases. The necrosis, however, extends downward beneath the vesicle through the entire corium, ceasing only a short distance above the subcutaneous tissue. The depth to which this necrosis extends is particularly striking. The corium throughout the affected area retains few of its normal appearances. The connective tissue cells have in great part lost their power of reacting to staining fluids. The fibres are broken up and forced apart and contain in their interstices an abundance of various-sized granules and detritus which are prominently brought out by staining with safranin. In the region of the papillary layer, enlarged necrotic blood-vessels filled with blood cells are seen in many of the sections, and often in the vicinity of these vessels a free hæmorrhage into the necrotic tissue is apparent. In many of the sections, especially in those corresponding to the center of the lesion, a hair follicle may be seen, as shown in the figure, which has participated in the general necrosis.

The necrosis ceases quite abruptly at the sides and also at the base of the lesion. The epidermis adjacent to the necrotic portion is slightly increased in thickness and is otherwise nor-



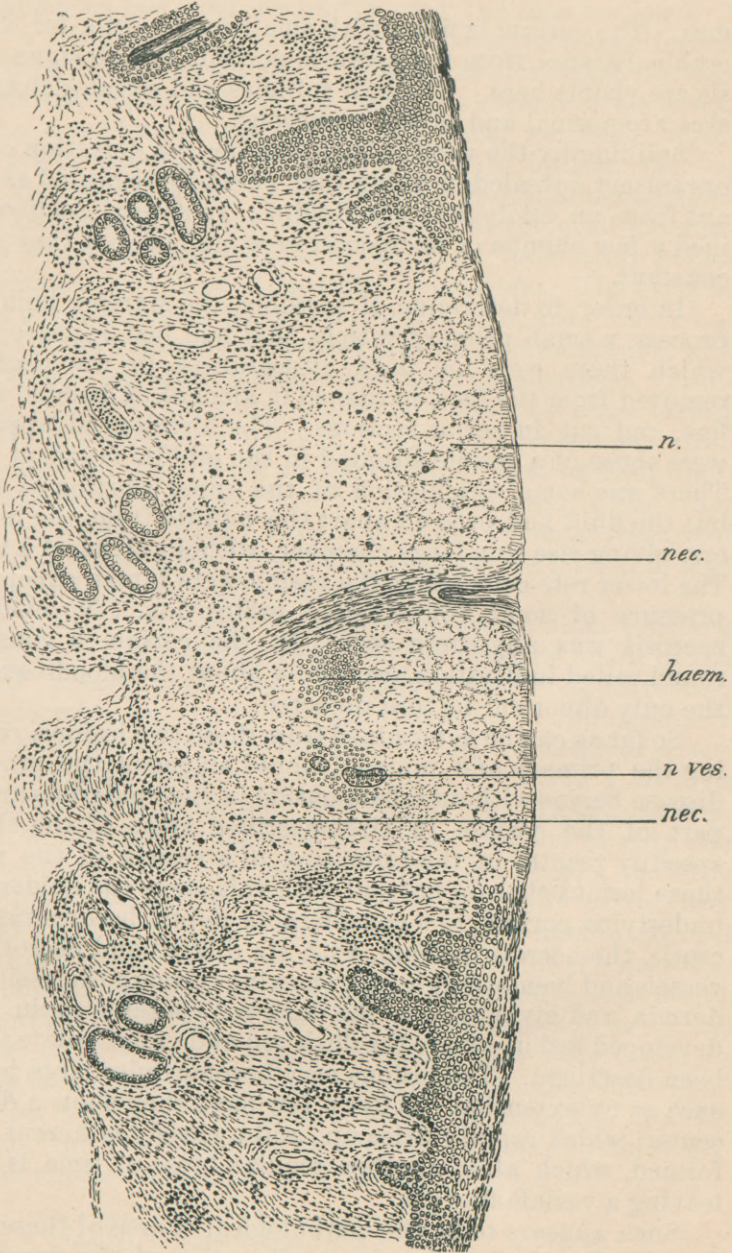


FIG. 2.

*n.*, network in the epidermis. *nec.*, necrosis in the corium. *haem.*, hæmorrhage in the connective tissue. *n. ves.*, necrotic vessel filled with blood globules.



mal. The corium is filled with small round cells for a considerable distance from the necrotic portion, but no signs of necrosis are visible here. The hair follicles and sweat glands in this area are normal and rather numerous.

Staining by the various methods for the detection of microorganisms, revealed nothing that could be regarded as important from an etiological standpoint. In several sections examined a few clumps of micrococci were stained, but they were not constant.

In order to determine, if possible, the starting point of the process, a small primary vesicle, that had just appeared, and in which there were no dark appearances in the center, was removed from the face, hardened in alcohol, imbedded in paraffine, and cut in serial sections. The histological appearances were those of a vesicle situated in the middle layers of the rete. There was some reticulation of the upper portion of the rete, but the fluid had pressed apart the middle from the lower layers, giving rise to a large chamber, without signs of a network. The lower rete cells below the vesicle were intact, except for the presence of some round-celled infiltration. No evidence of necrosis was anywhere seen. In the corium a considerable round-celled infiltration, especially about the blood-vessels, was the only abnormal feature detected.

So far as can be determined from these two lesions, representing the primary and more advanced stages of the process, the disease begins with an inflammation in the epidermis and upper part of the corium in circumscribed areas of the skin, and speedily results in the formation of a vesicle in the rete. In those lesions that do not end with this stage the epidermis and underlying corium to a considerable depth become rapidly necrotic, the necrotic corium, with its dilated and necrotic blood-vessels and hæmorrhagic foci, showing through the vesicular epidermis, and giving rise to the dark red center seen in the well-developed lesion, and to the dark red and violet points that have been described. The lesions may become quite large by confluence or by extension. After a few days they show a depressed center, which rapidly dries up, and a closely adherent crust is formed, which after another regular lapse of time is cast off, leaving a variola-like pit.

Such appears to be the pathological course of these lesions. But the description gives no explanation of the circumscribed necrosis thus produced by the sun's rays, and an analogy with any other known dermatosis is searched for with difficulty.



The affection has most similarity with the *acne necrotica* of Boeck,<sup>1</sup> a disease whose relationship to *acne varioliformis* has not been definitely settled. Pick<sup>2</sup> considers them distinct affections, and describes a case of each; the second of his cases, which he considers Boeck's *acne necrotica*, certainly corresponds pretty accurately in description with *hydroa vacciniforme*. Touton<sup>3</sup> reported at the German Dermatological Congress in 1891 a case of *acne necrotica* with histological examination, in which the microscopic appearances have many points of resemblance with those of *hydroa vacciniforme*. The marked vesicular appearances of the latter are absent in *acne necrotica*, but there is the same circumscribed necrosis, umbilication, and enlargement of papillary blood-vessels with hæmorrhage. Bronson and Fordyce<sup>4</sup> have also reported a case of *acne varioliformis* of the extremities in which Fordyce's microscopic examination offers many points of analogy with *hydroa vacciniforme*. The relationship of these three affections, if any, I shall not attempt to indicate. They have at least the common feature of a circumscribed necrosis followed by variola-like pits, and may be studied side by side with advantage.

The studies of Weigert<sup>5</sup> in variola indicated that, contrary to the general belief, the necrosis was the primary result of the small-pox poison, and that the inflammatory appearances, which determine so largely the characteristics of the papule or pustule, were secondary phenomena. A large number of observations convinced him that in every lesion of variola a necrosis of the lower rete cells can be found by diligent search, although in the earliest papules it may be present in only one or two sections from the center. Hence his theory that the poison attacks and destroys the lower rete cells as the first pathological change. The early lesion in this case of *hydroa vacciniforme*, was therefore carefully examined for the necrosis, to determine if the sun's rays by their chemical action might cause a primary necrosis of the rete in the same way as do the organisms (?) in variola. But no necrotic cells were found in this early stage, the appearances being simply inflammatory, so that, so far as can be concluded from the examination of a single lesion, the inflammation in corium and epidermis is primary, the necrosis a secondary phenomena.

<sup>1</sup> *Archiv. f. Derm. u. Syph.*, 1889, p. 37.

<sup>2</sup> *Archiv. f. Derm. u. Syph.*, 1889, p. 551.

<sup>3</sup> *Archiv. f. Derm. u. Syph.*, 1892, *Ergänzungsheft*, p. 287.

<sup>4</sup> *JOURN. OF CUTAN. AND GEN. URIN. DIS.*, April, 1891.

<sup>5</sup> *Lehre von den Pocken*. Breslau, 1874.



Weigert came to the conclusion that the umbilication of the pustule was due to the necrotic masses in the rete, which held down the center of the lesion firmly, while the epidermic cells at the sides proliferated and formed a raised wall. Somewhat the same explanation may be offered for the umbilication of the lesions of hydroa vacciniforme. We have here, as in variola, a necrotic center with fluid exudation, and it is probable that these necrotic cells binding down the upper covering are the cause of the umbilication. There was not a decided epithelial proliferation found at the periphery of these lesions, as Weigert considers necessary for the formation of the umbilication in variola, yet there was a slight increase in thickness of the epidermis. It may be doubted whether this epithelial proliferation is an essential factor in umbilication. But the necrosis seems to play a prominent part, as it is only in lesions in which there is a central necrosis that we see umbilication, as in variola, vaccinia, acne necrotica, probably varicella, etc.

Of late years attention has been directed to the action of the *chemical* rays of the sunlight as the cause of eczema solare, sunburn, etc., in cases where there was great sensitiveness to the sun's rays, while intense heat from other sources caused no symptoms. Hutchinson has described numerous cases of recurrent papular, pruriginous and eczematous eruptions which occur chiefly on the exposed parts of the body during the Summer months. The relation of these various conditions to hydroa vacciniforme should be more carefully studied, but it seemed to be already proved that the sun's rays may cause not only superficial inflammatory cutaneous changes, but in certain individuals a deep, sharply bounded destruction of tissue.

The treatment of the affection has not been especially successful. Almost any protective covering in the form of paste or ointment will probably be of service. Veils of red and turmeric,<sup>1</sup> colors which are supposed to neutralize the ultra-violet or chemical rays are recommended, and have been of value in eczema solare.

<sup>1</sup> Unna. Monatsheft, f. Prakt. Derm., 1885.







