

ADAMI (J. G.)

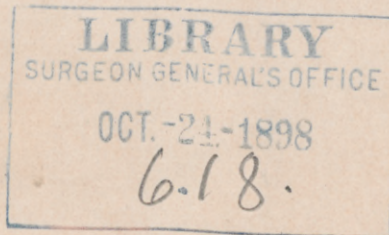
With
J. G. Adami's
Compliments.

BOOKS RECEIVED.

UPON THE
EXISTENCE OF A MINUTE MICRO-ORGANISM
ASSOCIATED WITH CASES OF
PROGRESSIVE PORTAL CIRRHOSIS.

BY J. G. ADAMI, M.A., M.D., F.R.S.E.,
PROFESSOR OF PATHOLOGY, MCGILL UNIVERSITY, MONTREAL.

REPRINTED FROM THE MONTREAL MEDICAL JOURNAL, JULY, 1898.



UPON THE EXISTENCE OF A MINUTE MICRO-ORGANISM
ASSOCIATED WITH CASES OF PROGRESSIVE
PORTAL CIRRHOSIS.¹

BY

J. G. ADAMI, M.A., M.D., F.R.S.E.

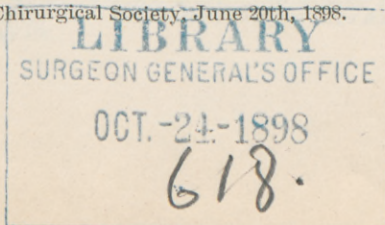
Professor of Pathology, McGill University, Montreal.

It will be known to members of this Society that, working in 1894 and '95 in Nova Scotia, I was not only able to confirm the previous observation of Wyatt Johnston, that a very interesting disease occurring among the cattle in a district to the north of the Peninsula, was infectious and epizootic, but further, obtained from cases of this so-called Pictou Cattle Disease, a characteristic micro-organism pathogenic for rabbits and guinea pigs. This organism I found constantly in the cultures from the livers and abdominal lymphatic glands, and fairly frequently in cultures made from other organs.

The main feature of this Pictou Cattle Disease is a peculiarly extensive cirrhosis of the liver accompanied by swelling of the periportal and retroperitoneal lymph glands, with some ascites and a condition of multiple follicular ulceration of the fourth or true stomach. The ulcers are generally found in a cicatrised condition.

The first recognisable symptoms (of which the most marked is the rapid diminution in the amount of milk given off together with a peculiar bitter taste and odour of the same when heated) occur only from 24 hours to ten days before death; evidently therefore the extreme cirrhosis of the liver must have been advancing for a long period without symptoms. Death occurs most frequently with progressive weakening and paresis; in some few cases there is a period

¹ Read before the Montreal Medico-Chirurgical Society, June 20th, 1898.



of intense excitement almost maniacal followed by exhaustion and death.

The micro-organisms present in this disease are most difficult to stain in the tissues; indeed, the difficulty that I have found in determining any method whereby they can with certainty be demonstrated, has prevented me so far from publishing an extended description of my results.¹ Apparently they stain easily, but lose their stain with extreme facility. With practice I have been able to recognize them in an unstained form in the tissues and in this condition they have a faint brownish tinge and a halo is faintly but definitely recognisable. For a long time it appeared to be almost a matter of chance whether I was able to stain them or not, or more correctly, only if I was fortunate enough to clear the sections with sufficient rapidity did I get the microbes stained. Yet another difficulty in staining this micro-organism has been its minute size within the tissues, so that with the ordinary 15th inch immersion which I have used until the last year or two, unless they were stained to the right extent, neither under nor over stained, they were recognisable with great difficulty. Still, there they were, and under the proper conditions they could be found in great numbers in the liver and abdominal lymphatic glands.

If thus an extreme condition of cirrhosis of the liver is brought about in animals by the proliferation in the tissues of a micro-organism which sets up the chronic and progressive hepatic disturbance, it has seemed to me possible that a similar result may be produced in man. As a matter of fact, for some years past Hanot and the French school of Pathologists have insisted that one form of cirrhosis—the large, smooth, cirrhotic liver with jaundice, the form now frequently spoken of as Hanot's cirrhosis—is of infectious origin, though they have not been able as yet to declare what is the microbe causing the infection. To the best of my knowledge however, no one has so far ventured to state that the more common or so-called atrophic cirrhosis, the ordinary hobnailed liver, is of microbial causation. While the time has gone past when it was taught that such hobnailed livers are directly caused by alcohol, the prevailing opinion is that alcohol or other irritant by setting up a condition of chronic gastro-enteritis and destruction of the mucous membrane of the upper portion of the intestinal canal, permits the absorption of toxic substances from the food, and these toxic substances taken up by the portal blood induce

¹ Statements concerning my investigations in Nova Scotia and early studies of the micro-organisms associated with the disease are published in the Reports of the Department of Agriculture for the years 1894 and 1895. At the Montreal meeting of the British Medical Association last year, I also read a paper upon the subject, of which epitomes were published in the *British Medical Journal*, *Lancet*, &c.

a surrounding chronic phlebitis with or without direct action upon the liver cells.

During the last four years I have carefully studied all cases of hepatic cirrhosis which have come to the post-mortem room at the Royal Victoria Hospital to observe whether I could make out the existence in them of micro-organisms to such an amount and so constantly that we may safely conclude that the disease is associated with the presence of these micro-organisms. Here again the same difficulty pursued me as was present in the earlier stage of my studies upon the Pictou Cattle Disease; at times I could distinguish in sections the presence of numbers of minute diplococcus-like bodies, but further sections from the same case did not stain well, and there has been the added difficulty that the liver contains so many fine granules that in the unstained condition it is extremely difficult to make oneself positive that what one sees is not of the nature of some cellular precipitate or fine deposit. In two cases in 1895 and 1896, I thought that I had gained cultures from the liver, but upon growing these they were overrun with the colon bacillus and I lost them. In a more recent case, during last month, I was able to gain from an agar tube of the liver juice an extremely minute diplococcus staining with great difficulty, and scarcely visible. The tube was reported to me as being sterile and only upon the 4th or 5th day of the growth did I examine it myself, and found there this presence of small micro-organisms in small numbers, but when I tried to make further growths the microbe had already died out, if indeed, what I saw was anything beyond the microbes already present in the juice, upon inoculation of the tube, which had not proliferated.

In connection with this case, which was one of atrophic portal cirrhosis with pigmentation, I have been able to find micro-organisms in considerable quantities in the tissues. Dr. Abbott, who has been working on this case more especially in connection with the pigmentation of the organs, showed me some sections of the abdominal lymph glands which she had stained by Weigert's fibrin stain, and which under the high power had a peculiarly granular appearance. Upon examining with the 18th inch immersion, I found that the fine granules resolved themselves into great numbers of minute microbes of the character which I had learnt to recognise in connection with the Pictou Cattle Disease; namely, the micro-organisms present were extremely minute, even smaller than those seen in the Pictou Cattle Disease; in the main they were present as diplococci with a slight halo round them, very much smaller than the diplococcus of pneumonia, but like that organism certain of those present were longer and more distinctly in the form of diplo-bacilli.

Many of the forms present resemble closely minute editions of the gonococcus. Further, the micro-organisms vary to some extent in size; this may be a matter of imperfect staining or may be another evidence of the polymorphism to which I have already drawn attention. On the whole inasmuch as certain examples are distinctly bacillary, the organism then should be placed among the bacilli rather than the diplococci.

Examining a series of livers by Weigert's fibrin method, I am in doubt as to whether the bacilli truly resist the action of the iodine solution, for while I get good results in some cases, in others I see a very large number of what I may term 'shadows.' It may be therefore only that the bacteria are relatively resistant to the action of the iodine.

To-day I have elaborated a still more satisfactory stain which shows the presence of bacteria with certainty. The method is as follows:

ne / Taking the sections that have been well hardened and cutting them by the freezing microtome, I place them for a minute or two in a weak solution of acetic acid in order to clear the cells as much as possible. I then wash out the acetic acid and place in absolute alcohol; from this I transfer to a solution of methylene blue in anilin oil. This oil takes up the blue with fair ease and I employ a half saturated solution. In this I leave the sections for half an hour. The methylene blue-anilin oil mixture has the advantage over an anilin oil gentian violet mixture in that it does not overstain. At the end of half an hour I transfer the sections for a quarter of a minute into a mixture of two parts of anilin oil to ~~two~~ parts of xylol, then rapidly into xylol. If there is any tendency to excessive stain, I treat them for a longer period with a mixture of two parts of anilin oil to one of xylol before placing in the xylol; they then are mounted.

The method is not perfect, for the tissue is not completely decolorised; nevertheless, the bacteria are to be seen clearly in the newly formed connective tissue. Staining by this method I also find that not all the bacteria take the stain completely; there is a large proportion which has retained a brownish tinge, but these from their diplococcus shape and faint halo, can only be microbes. Many of the microbes are also without doubt within the liver cells.

I thus come to the conclusion that a large number of the microbes present are probably dead, and have absorbed some colouring matter from the blood or the bile. So far I have come across this one form in very considerable numbers in every case of advanced hobnailed cirrhotic liver which I have examined (five cases) with one possible

exception, the exception being a case in which the undertaker had embalmed the body, and the crystals and débris of the embalming material cause so much dirt in the sections that it is difficult to make out the state of affairs, but even in this case I believe I can detect some of the characteristic bacteria.

Thus at the present time I would go so far as to say that in a certain number of cases, at least, of hobnailed liver, there is present, more especially in the liver and the abdominal lymph glands, a minute micro-organism resembling closely that found pathogenic in the infective cirrhosis of cattle; a form which is present most frequently as a minute micrococcus but sometimes has a more bacillary appearance, and which is thus to some extent polymorphous.

Appendix, July 9th, 1898.

Since reading this communication, through the kindness of Professor Hektoen and Dr. Flexner, I have had the opportunity to examine fifteen other livers showing distinct evidence of portal cirrhosis from the material at the Rush Medical College, Chicago, and the Johns Hopkins Hospital respectively. I have not, as yet, examined all the material from the latter source, but in all the Chicago cases, as in ten well marked examples from Baltimore, I recognise the appearances above described. More satisfactory staining of the doubtful case above mentioned, show the undoubted presence of diplococci.

A fuller description of my observations, together with the description of the bacillus, isolated by me recently from a case of cirrhosis, will be communicated to the meeting of the British Medical Association, at Edinburgh, by Dr. Osler. I would only add here that the methylene blue, aniline oil method of staining described above, while giving very fair results for immediate study, does not in my hands yield permanent specimens, the dye tending to fade out of the microbes.

