

ABBE (R.)

al

COMPLIMENTS OF
ROBERT ABBE, M. D.,
11 WEST 50TH STREET,
NEW YORK.

PARANEPHRIC CYSTS.

BY
ROBERT ABBE, M. D.

REPRINTED FROM
The New York Medical Journal
for August 9, 1890.

413-

*Reprinted from the New York Medical Journal
for August 9, 1890.*



PARANEPHRIC CYSTS.*

BY ROBERT ABBE, M. D.

THE variety of cystic tumors one may encounter in the abdominal cavity is not great.

Ovarian, parovarian, salpingeal, in the female, and hydatid, pancreatic, distended gall-bladder, and hydronephrotic cysts and pus collections, which are common to both sexes, are about all which one will find. Exceptionally one may meet a cystic tumor that will have an entirely different clinical history and require different treatment. There may be variations of the above, as the cyst of an extra-uterine pregnancy, or one of the class under consideration which heretofore may have been ranked with hydronephrosis of the common type. It is proper that they should be differentiated, clinically and anatomically, and it is with a view to giving a suitable rank to this class that I present the history of two striking cases that were extremely puzzling to me until laparotomy cleared up the nature of both :

CASE I. *Large Paranephric Cyst; Exploratory Laparotomy; Incision and Lumbar Drainage; Cholesterin in the Fluid; Recovery.*—A lady of forty-eight years, referred to me from Dr. Pellet, of Hamburg, N. J., was in fair condition when first seen by me on August 12, 1889. She gave no history of special illness ex-

* Read before the New York Surgical Society, April 23, 1890.

cept an attack of inflammation of the kidneys lasting two weeks, seventeen years ago. Since that time the functional activity of the kidney has been normal and, as far as she has been aware, nothing unusual has occurred in the appearance of her urine. She had excellent digestion and health. No members of her family ever had tumors of any description. She had seven children in the past twelve years without unusual event. Four years ago she first noticed a swelling of her left side, not hard, and extending from the left loin toward the groin, about as long and as broad as her hand. It was painless and did not seem to grow for two years or more. Her health not being affected, she paid little heed to its presence, though she says she at first consulted Dr. T. G. Thomas, who said it was connected, he thought, with her kidney. As it enlarged it filled the left iliac fossa, encroached on the median line, passed the level of the umbilicus, and grew upward to the ribs. During the past few weeks it has grown much more rapidly, and there has been a dull aching in the back.

Her general health has not deteriorated.

On examination, a large tumor was found to fill the left half of the abdomen, extending across to the opposite iliac fossa. It seemed like a large cyst, constricted somewhat vertically, the median portion dome-shaped, with the navel at the summit.

The tumor filled the left iliac fossa and extended well across into the right. It rose into the left lumbar and hypochondriac region and raised the costal cartilages. A sulcus marked its surface obliquely to the left of the median line, and in this portion was resonance, as of an adherent intestine lying more or less vertically. Elsewhere the tumor was entirely dull on percussion. Auscultation was negative.

Vaginal examination reveals a large patulous cervix, the uterus pushed backward and to the right, and movable independently of the tumor. The latter fills the anterior portion of the pelvis and gives a sense of resistance like a thin-walled cyst. The general appearance was of an ovarian cystoma of large size composed mainly of two principal cysts. The most unaccountable feature was the oblique intestine confined to its surface. This was suspected to be adherent. On account of her history

that Dr. Thomas had thought it renal in the early stage, the urine was carefully observed. It was of rather low specific gravity, 1.010; acid; no albumin, and contained a few pus cells and epithelium—not enough to give the slightest suspicion of renal trouble.

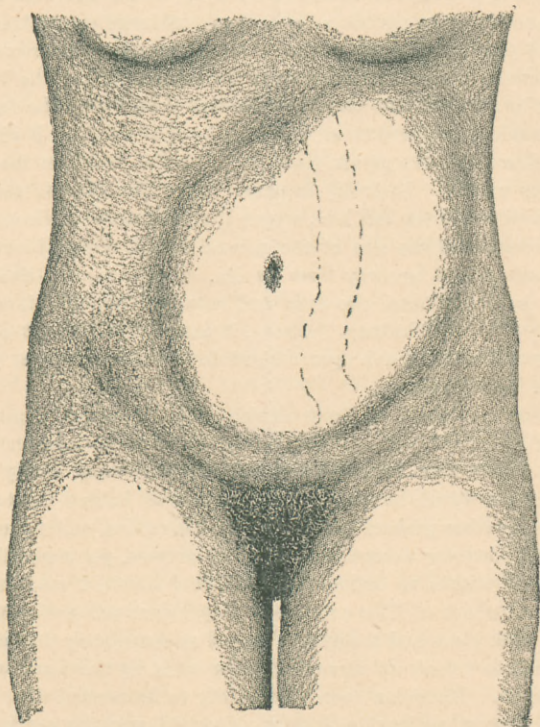
On August 14, 1889, I made exploratory median laparotomy.

The cyst presented at once in the incision, but differed entirely in appearance from an ovarian cyst. It was invested by an independent loose peritoneal covering, with large vessels traversing it laterally. The presenting adherent intestine was evidently the descending colon raised from its normal bed. The hand, being introduced into the abdomen, was passed over the face of the tumor downward to ascertain its base of origin. It dipped well down into the pelvis, then up behind it freely to the ilio-lumbar region. Laterally it passed over the smooth surface into a sulcus in the left loin, where the peritonæum reflected on to the tumor at the site of the normal colon, which, however, had been raised far away from its site. On the median side the hand passed around the cyst and returned beneath it to the region of the left kidney. Above, it passed freely over the top, and, reaching the diaphragm, slipped down behind the cyst again to the kidney region.

It was evident then, from all sides, that the tumor originated about the left kidney, and that it had best be opened posteriorly. At the same time, to avoid opening the peritoneal cavity posteriorly, it would be necessary to keep well behind the reflection of lumbar parietal peritonæum. Therefore, while protecting the anterior wound with hot compresses, yet maintaining my hand within to define the peritoneal limits, I made a free lumbar incision as if for colotomy. Rapid evacuation of the contents took place and the cyst collapsed so completely that it was difficult to detect its remaining thin walls by the hand in the abdomen. The colon descended nearly to its normal site.

The most noticeable feature observed was the spread-out kidney. It was not distended, but flattened out against the loin, a crater-like rim being felt on its surface, marking the bed from which the cyst sprung. This was an unmistakable feeling, and was recognized by manipulation through the lumbar as well as

the abdominal wound, but best from in front. Some time was taken to discover if possible any connection between the cyst and the pelvis of the kidney, but no sense of distended calyces or funnel-shaped pelvis was present; and it was completely evident that the cyst was independent of the renal pelvis. The anterior wound was closed, and large drainage-tubes introduced through the lumbar wound into the cyst.



The fluid evacuated was as remarkable as the cyst. It measured between ten and twelve pints, was of a pinkish milky color, thin, turbid, and glistening with myriads of cholesterin

crystals, which, on standing, deposited to the amount of one fifth the bulk of fluid. The latter was of specific gravity 1.030; contained a large quantity of albumin; microscopically, cholesterin, red blood-cells, a large number, and a trifling number of pus cells; large multinuclear cells, granular round cells, irregular granular masses, and free fat. The patient made a speedy and uninterrupted convalescence. The urine was watched for possible appearance of crystals of cholesterin, which certainly had not appeared before operation. On the day following operation a trace of albumin, a few casts, and a few cholesterin crystals were found, but never afterward. These may readily be explained by the manipulation and probing during the operation, which may easily have lacerated some part of the delicate sac. No urine ever appeared at the lumbar wound.

Under irrigation and drainage the cyst closed, so that in four weeks it would hold but four ounces on distension. In six weeks she was discharged cured, a slight sinus remaining which healed soon after her return home. Since that date, more than six months, the patient has remained perfectly well; has gained thirty pounds in weight, and is actively employed at home.

The second case presented itself three months later.

CASE II.—The patient was a young lawyer, aged twenty-three years, of good physique. About the 1st of September he was taken with acute pain in the right hypochondrium, nearly in the region of the gall-bladder, and simultaneously noticed a large swelling at the site of the present tumor. When he was seven years old, and again at fifteen, he remembers to have had similar attacks. He had no fever with this attack and the pain gradually subsided.

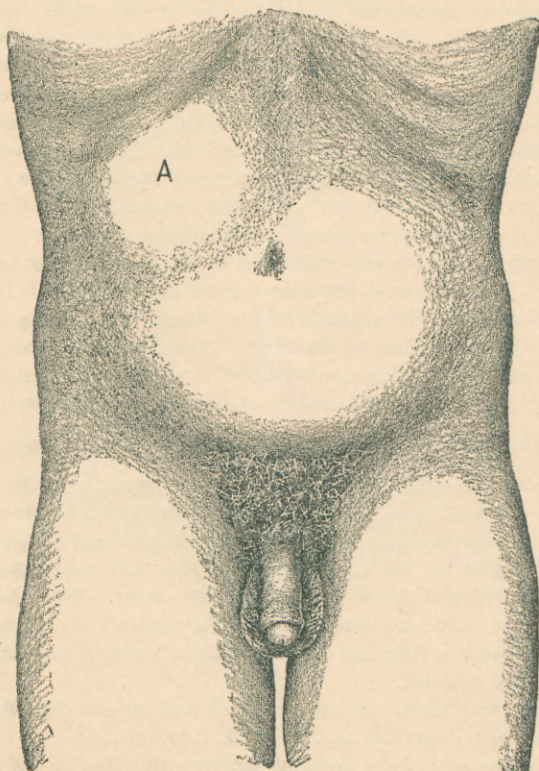
He came under the care of Dr. Kinnicutt and Dr. Draper, with whom I saw him on October 3, 1889.

He seemed to be in good health, excepting that he had a tumor in his side that gave him a little pain.

His normal pulse was 55. Temperature varied from 98° to 99° during two weeks' observation before operation.

Examination showed a globular tumor of the abdomen in the right hypochondriac region, the apex of which lay between

the point of the tenth rib and the navel. Palpation showed it to be of very even surface, but more prominent near the point of the tenth rib. It sloped equally in all directions. The loin was also filled by it, so that pressure there raised the summit, but there was no lumbar prominence as there was in front. The liver



boundary was raised three quarters of an inch upward. The tumor descended to the level of the navel and extended across the median line. This was discovered rather by palpation than percussion. The colon was pushed downward. There had been

no jaundice. The urine was normal. Palpation in different attitudes revealed a lateral movement of the mass of two inches. There was no history of renal colic, with its characteristic pain.

On first examination, my conclusion was that we had to deal with a greatly distended gall bladder. The following points were a fair guide to this decision: 1. There was an absence of history of renal symptoms. 2. The tumor was evidently a fluid one. 3. The position was considerably higher in the abdomen than the tumor of hydronephrosis. 4. The rotund fullness was most pointed at the apex of the tenth rib and enlarging thence toward the navel. 5. The history of this attack of acute pain, with two preceding ones in former years, was like that of gall-stone impaction. During the two weeks following the patient had no pain; walked about and drove out.

Further examination showed a slight increase in growth across the median line, with less fullness between the navel and the tenth rib. While admitting the possibility of this tumor springing from the kidneys after the fashion of the paranephric cysts, the case previously narrated being fresh in my memory, I was yet more inclined to regard it as occupying the site of the gall-bladder when distended. It may have had a little more latitude of motion than a gall-bladder of similar size, and possibly could be said to be more full in the lumbar region than that.

The patient was eating and sleeping well. Urine was normal in specific gravity and reaction; had no albumin, or sugar, or abnormal elements on microscopical examination. The presence of the tumor, however, was a menace to him, and therefore, after consultation with Dr. Draper, Dr. Kinnicutt, and Dr. Bull, I operated under ether on October 22, 1889. Incision vertical, as for cholecystotomy. On opening the abdominal cavity, the presenting surface of the tumor was at a glance, as in the former case, seen to be covered by the posterior peritoneal wall of the abdominal cavity, indicated by the appearance of the large vessels traversing it laterally, and by the relatively loose attachment of peritonæum to the tumor. The fingers, passed into the cavity, found the liver free, but pushed upward,

and the gall-bladder normal. Passing backward, the possibility of hydatid cyst springing from the liver was excluded. The slope of the tumor in all directions was backward toward the loin. It was free from adhesions on every side.

While conducting these explorations somewhat vigorously, the peritoneal layer investing the tumor was seen to grow rapidly œdematous and puff up so as to fill the incision. Growing rapidly thinner, it burst open in the wound as I attempted to secure it with forceps, and gave exit to a rapid flow of watery, colorless, limpid fluid, sufficient of which was caught for examination. The presenting rent was secured in the wound, and the fluid kept out of the peritoneal cavity. The rent was enlarged, and the flow seen to come from the loose-meshed retroperitoneal tissue. The tumor so rapidly disappeared and its remnant sank back into the loin so quickly that it was difficult to identify any distinct cyst wall among the cellular tissue, and it was deemed unwise to strip up the peritonæum for further exploration. The evacuation being completed, an estimate was made that two pints of fluid had escaped.

A digital examination of the site of the tumor was made. The rent in the peritonæum was two inches above the colon at its hepatic flexure. The liver was entirely uninvolved. The finger passed backward to the aorta and renal vessels, thence downward around the colon and over it to the kidney, whose entire surface was palpated. The lower end was round, smooth, and normal. The rest of its surface was not quite as even as natural, and was spread out into four flattened lobulations. The collapsed tumor sac and adjacent colon fell back so as to cover this area, and no trace of other abnormal condition could be discovered. The posterior rent was therefore stitched to the abdominal incision and the latter closed, except for drainage of the retroperitoneal space, through which the fluid had escaped. My original intention had been to drain posteriorly if I found such a renal cyst, but the bursting of the sac required anterior drainage.

The cyst fluid was of very low specific gravity—1.003. It contained a trace of albumin; no urine salts; no bile salts; no hydatid elements; some chlorides. During evacuation hydatid

daughter cysts were watched for but not seen. The diagnosis, therefore, must remain of thin-walled cyst of the surface of the kidney, growing so as to distort the organ by surface pressure.

After operation, free drainage of limpid fluid continued for thirty-six hours, when it rapidly lessened, and his convalescence was uninterrupted. His temperature fell to normal in four or five days. On the fourth day he had considerable albumin appear in his urine, with casts. All disappeared during the four days succeeding, and he was discharged cured during the fourth week.

He has since been carefully examined by Dr. Draper, nearly six months after operation, and he remains free from all signs of trouble.

There seems in the cases given to be evidence that in both we had renal cysts *not* of the usual type of hydronephrosis. The pelves of the kidneys were not the seat of distension, and excepting that, through scratching, a few cholesterol crystals entered the urinary channel a few hours after operation, there was no contamination of the urine by the cyst contents.

The retention cysts of the renal cortex resulting from fibrous change in granular kidney are usually multiple and rarely attain much size. They are bilateral also. Congenital cysts are very rare and due to cystic degeneration of rudimentary tubes. The kidney substance is not left in bulk as in the cases narrated, but attenuated or wanting, and the victims of this deformity are apt to have other deformities and die in infancy. Simple cysts and paranephric cysts, however, are of a class by themselves that directly concern the surgeon by their rarity and importance.

The pathology of their origin is not easily ascertained, as they have usually so attenuated the capsule of the gland and compressed the neighboring cortex as to make it impossible to say whether they sprang from the meshes of the cellular layer beneath the capsule, or from the Malpighian

corpuscles, or from their investing cellular layer, or from lymphatic channels. The contents of the cyst give no clew to its origin; they are as various as in cysts elsewhere, varying from clear aqueous contents of very low specific gravity and containing a trace of albumin and salt through every grade of colloid and straw-colored serum. Usually clear, they may have such ingredients as cholesterin, which results from the degeneration of any fatty or cellular substance, or, as seems most probable, of blood. They never have urinous elements in solution.

This uncertainty as to origin entitles such tumors as have been described to the name of paranephric cysts, *resting upon* the kidney, there being no evidence that they arise within the cortex. The recorded cases are not very numerous. They have been known to grow to larger proportions than the first one I have mentioned, and to have been mistaken for ovarian tumors. This seems extremely easy to do if one regards the shape and fluctuation of the tumor and the appearance of the patient. If an early history of growth in the ilio-hypochondriac region can be elicited, or if the physical examination reveals a course of the intestine over its surface, such as the colon took in one case under consideration, it would give a strong point toward differential diagnosis. In my second case the relation of the colon was also of interest, it being pushed down and in front of the tumor. This is perhaps one of the best points for diagnosis that the colon is usually in front of a renal tumor. Yet, as Morris says, an exceptionally large renal tumor will push the colon aside, and, on the other hand, a portion of intestine will occasionally though rarely fasten itself in front of an ovarian cyst.

As regards the second case, which resembled a distended gall-bladder, I may say on reviewing it that the tumor, while not less prominent than a gall-bladder cyst,

was perhaps *less pyriform, more movable laterally*, and somewhat more easily raised by lumbar pressure than even a large gall-bladder would have been. Its position was too high for the usual hydronephrosis.

The successful treatment of all serous cysts by incision and drainage makes it probable that no other treatment would have been more successful or less dangerous in these cases. The first case of large cyst shows that a lumbar incision without guidance from within would have probably penetrated the peritoneal sac before entering the cyst, on account of the persistent reflection of the peritonæum close to the kidney, in spite of the fact that the colon had been raised to the surface of the cyst. Exploratory aspiration also would have allowed the muddy cholesterin fluid to empty somewhat into the peritonæum if puncture had been made anywhere but close to the kidney.



REASONS WHY

Physicians Should Subscribe

FOR

The New York Medical Journal,

EDITED BY FRANK P. FOSTER, M. D.,

Published by D. APPLETON & CO., 1, 3, & 5 Bond St.

1. **BECAUSE** : It is the *LEADING JOURNAL* of America, and contains more reading-matter than any other journal of its class.
2. **BECAUSE** : It is the exponent of the most advanced scientific medical thought.
3. **BECAUSE** : Its contributors are among the most learned medical men of this country.
4. **BECAUSE** : Its "Original Articles" are the results of scientific observation and research, and are of infinite practical value to the general practitioner.
5. **BECAUSE** : The "Reports on the Progress of Medicine," which are published from time to time, contain the most recent discoveries in the various departments of medicine, and are written by practitioners especially qualified for the purpose.
6. **BECAUSE** : The column devoted in each number to "Therapeutic Notes" contains a *résumé* of the practical application of the most recent therapeutic novelties.
7. **BECAUSE** : The Society Proceedings, of which each number contains one or more, are reports of the practical experience of prominent physicians who thus give to the profession the results of certain modes of treatment in given cases.
8. **BECAUSE** : The Editorial Columns are controlled only by the desire to promote the welfare, honor, and advancement of the science of medicine, as viewed from a standpoint looking to the best interests of the profession.
9. **BECAUSE** : Nothing is admitted to its columns that has not some bearing on medicine, or is not possessed of some practical value.
10. **BECAUSE** : It is published solely in the interests of medicine, and for the upholding of the elevated position occupied by the profession of America.

Subscription Price, \$5.00 per Annum. Volumes begin in January and July.

