

EDEBOHLS (G.M.)

---

*Combined Gynecological Operations.*

BY

GEORGE M. EDEBOHLS, A.M., M.D.,  
GYNECOLOGIST TO ST. FRANCIS' HOSPITAL, NEW YORK.

---



FROM  
THE AMERICAN JOURNAL OF THE MEDICAL SCIENCES,  
SEPTEMBER, 1892.



COMBINED GYNECOLOGICAL OPERATIONS.

BY GEORGE M. EDEBOHLS, A.M., M.D.,  
GYNECOLOGIST TO ST. FRANCIS' HOSPITAL, NEW YORK.

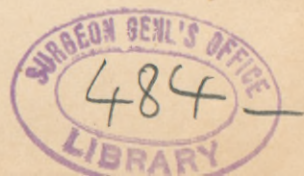THE fact cannot be gainsaid that the marvellous progress in the diagnosis and treatment of diseases peculiar to women, attained within the past decade, is due almost entirely to surgical as distinguished from purely medical gynecology—which, stated in other words, means that modern gynecology is essentially surgical.

Surgical it is, and in a surgical direction its advances in the near future are likely to be made: surgery bred of increasing experience and knowledge in diagnosis and pathology; surgery based upon clear and rational indications and growing ever more exact and skilful in its methods; surgery, finally, inspired solely by one consideration, namely, the best interests of the patient, all things considered, in the individual case. In determining the latter point the personal equations of both operator and patient will come largely into play and prove important factors in reaching a decision as to the best mode of procedure.

The uncertainties of other methods of treatment as compared with surgical measures are proverbial. Not that for this reason other methods are to be discarded. But in proportion as the risks from surgical treatment can be diminished will surgery steadily gain in favor, both on account of its more positive and permanent results, and the shorter time required for cure in the very great majority of cases. The latter is a very important consideration, and it must be the constant endeavor of the progressive gynecologist to still further reduce the time required to lead a case to a successful issue by surgical measures.

In a line with this thought is the subject of combined gynecological operations, by which is meant the performance, at the same sitting and upon the same patient, of various gynecological operations heretofore usually distributed over several sittings. Not alone are valuable time and much bodily suffering and mental anguish thus saved the patient, but the results of our procedures are likely to be much more perfect.

Let us take, for instance, a case of complete procidentia uteri, the cure of which is attempted by plastic operations. Let us suppose that curettement, amputation of the cervix, anterior and posterior colporrhaphy, perineorrhaphy, and ventro-fixation of the uterus are all indicated by the existing pathological conditions. It will make a world of difference in



the result, as well as in the time required to attain a successful result, whether the operator is able to perform all these operations within a reasonable time, at one sitting, or whether he will be obliged to leave one or more of them to be performed at one or more subsequent sittings. Say, for instance, every operation above named is performed save the ventro-fixation. It is common experience that plastic operations below, however skilfully performed, are in the very great majority of cases insufficient to withstand the continuous tendency of the uterus to again descend, favored as that tendency is by the relaxation of all pelvic supports due to the prolonged prolapsus. As a result, when the time arrives at which the ventro-fixation can be added, it will be found that one or more of the plastic operations on the vaginal wall and perineum may have to be done over. Or if the perineorrhaphy be omitted and the ventro-fixation performed at the first sitting, the lack of support below will allow the uterus to tear itself away from the adhesions, holding it to the anterior abdominal wall. That both of these cases are not supposititious, my own experience in my first case sadly taught me, just as my later experience has demonstrated that when all the above-named operations are performed at the same sitting, a good result may be confidently anticipated.

Further than this, the cure is complete in from three to four weeks, as compared with an indefinite period demanded when the operations are performed at different times; and the patient is spared that unenviable frame of mind associated with looking forward to an indefinite number of operations to follow each other at indefinite intervals of time.

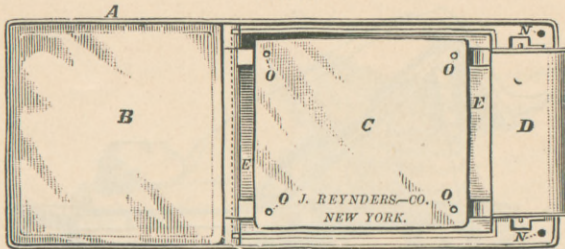
The writer firmly believes that the next step forward in gynecological surgery will be in the direction of the *simultaneous* performance of as many operations as the patient may require to make her well, and that the gynecologist of the highest skill in operative work—which, to my mind, almost necessarily presupposes also the greatest skill in diagnosis—will consider that he has done justice neither to himself nor to his patient, unless, as a rule, admitting of but rare exceptions, he will be able safely and well to do all the surgery required in her case at a single sitting. It is the purpose of this paper to record some of the efforts made by the writer in this direction.

To do combined operations *with safety to the patient*, presupposes, first of all, perfect asepsis and a not too prolonged anæsthesia. The operator must feel almost absolutely sure that no symptom of sepsis can arise after operation to harass his mind with doubts as to which of his operative procedures has been at fault in this regard. Otherwise his state of mind, both at the time of and after operation, must be far from enviable.

As regards the period of time during which a patient may safely remain under the effects of an anæsthetic, individual opinions will probably vary very widely. I myself have placed the practical limit in my


own work at one and a half hours, and have but on two or three occasions needed more time than this, no matter how many combined operations were required.

FIG. 1.



Edebohls' operating-table. Top of table. *A*, metal frame; *B*, polished glass plate for head and shoulders; *C*, ditto, for body; *D*, metal surface; *E*, trough; *N*, holes for foot-supports.

FIG. 2.



Table, complete, with foot-supports (*K*) and ankle-straps (*L*).

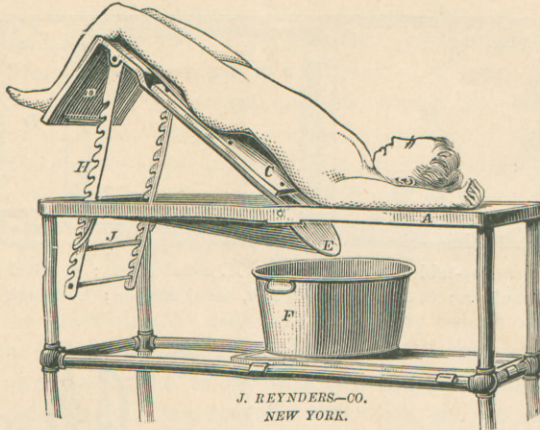
To do combined operations *well* within the time limits of safe anaesthesia, requires, in addition to the necessary degree of operative skill and dexterity, sufficient and efficient assistance, a perfected technique of the various operations attempted, and an instrumentarium suitable to rapid work.

Perhaps, then, I may be pardoned a brief description of the technique of the various typical operations entering into combinations, as I have practised them, before giving attention to the combinations themselves.

All of the various operations now to be described are performed upon

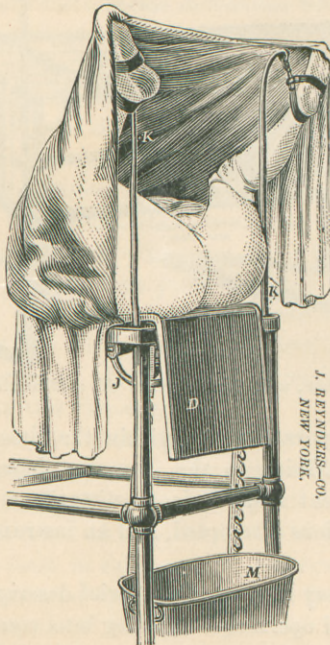
the author's combined laparotomy and gynecological operating-table, a description of which may be found in the *Medical Record*, N. Y., Nov. 14, 1891.

FIG. 3.



Table, showing method of obtaining the Trendelenburg posture. Any position between the horizontal and an inclination of  $45^{\circ}$  may be obtained on the table.


FIG. 4.



Table, showing modified lithotomy position, for examination, and for operations upon perineum, vagina, uterus, and bladder. *D*, carrying the buttocks of patient, can be raised to any convenient height.

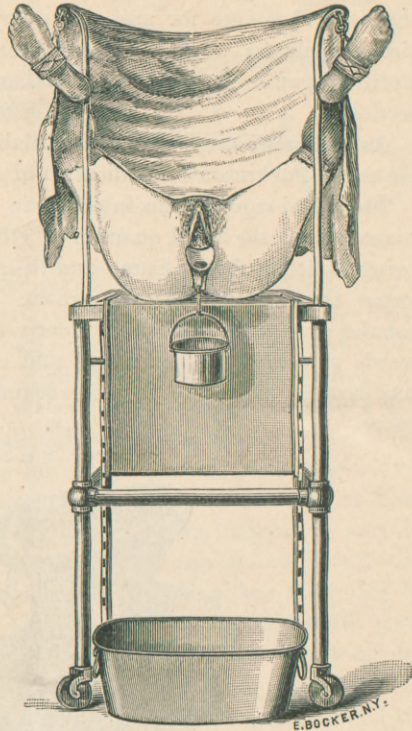
Operations upon the uterus, cervix, and anterior vaginal wall are all performed with the patient in the dorsal position, and with the aid of the writer's self-retaining speculum, described at length in the *Medical Record*, N. Y., March 7, 1891, p. 283. I have lately somewhat modified

FIG. 5.



Self-retaining vaginal speculum.

FIG. 6.



Speculum, showing method of use.

the speculum, making it smaller and more portable, although preserving its essential characteristics.<sup>1</sup> The modified instrument measures a little less than 10 centimetres in its longest diameter and fits into its accompanying pail. The latter is 10 centimetres in diameter, 7.5 centimetres deep, and has a capacity of about 6.60 grammes. Any pail, however,

<sup>1</sup> The instrument, as originally made, was hammered out of copper by hand. In the further course of manufacture the original design was more or less arbitrarily departed from, until the instrument as turned out by different makers often assumed shapes so distorted, fantastic, and grotesque that it was with difficulty recognized even by its originator. Mr. E. Bocker, 582 Hudson Street, New York, under my supervision, finally took a great deal of pains to make an accurate model, and had a mould made of the same. The instrument as now turned out by him and by John Reynders & Co., being cast, has the advantage of uniform correctness of shape.

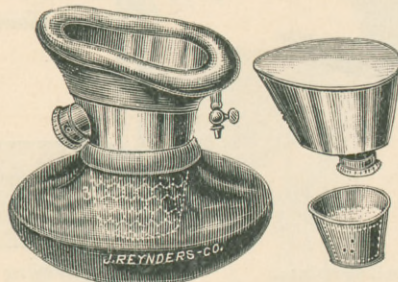
with a capacity up to a litre, may be used, or an equivalent solid weight may be substituted.

The use of constant irrigation, as facilitated by this speculum, is a decided advantage as compared with the use of sponges in the performance of combined operations, diminishing the risk of sepsis and contributing materially to rapidity of work. Personally I have discarded the use of sponges for any and every purpose, using constant irrigation for plastic work on uterus, cervix, vagina, and perineum, and sterilized gauze serviettes for all other operations, including abdominal section.

As an anæsthetic I all but invariably employ ether, administered by means of Parkinson's modification of Ormsby's inhaler.

The advantages of this inhaler are its simplicity of construction and management, the small quantity of ether required—three to four ounces being sufficient for an hour—and the avoidance of the diffusion of ether vapor through the operating-room. After a use of the Parkinson inhaler extending back over nearly three years, I have nothing but words of commendation for it, and the smoothness of the anæsthesia has been a matter of frequent comment by visitors to my operating-room.

FIG. 7.



Parkinson ether-inhaler.

I will now proceed to describe, as briefly as I may, the details of technique, as I now practise them, in the various gynecological operations.

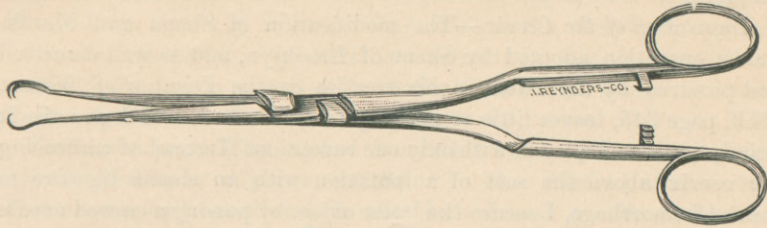
*Currettement of the Uterus.*—With the patient in the dorsal position and after thorough disinfection of the vagina with creolin-mollin, 10 per cent., followed by irrigation with 1 : 2000 sublimate solution, the speculum is introduced and the anterior lip of the cervix seized and drawn down by the double tenaculum forceps herewith illustrated. The tenaculum forceps has two teeth on one point, and a single tooth, fitting between these two, on the opposite point.

The points as well as the ratchet lock on the handle are kept in true working order by means of the improved antiseptic lock which I have



elsewhere described. (*Medical Record*, N. Y., March 15, 1890, p. 310.) It has proved to the writer a most valuable and practical instrument in almost all his plastic and abdominal work. A few additional instances of its utility will be alluded to further on in the paper.

FIG. 8.



Tenaculum forceps.

After seizing the anterior lip, the cervix is dilated, if necessary, by a simple dilator (I prefer the ordinary two-branched, glove-stretcher form, Sims' or Wylie's modification thereof); a double-current catheter (Bozeman, Fritsch, or Kelly) is introduced and the uterine cavity washed with a 1:2000 sublimate solution. A *sharp* curette is next introduced and the *entire mucous membrane* of the uterus systematically scraped out until the harsh grating sound and feel of the curette as it passes over the tissues informs us that the submucous and muscular layers have everywhere been reached. A curettement of the uterus, as may be gathered from the above, to me means an *abrasio mucosæ totalis*—an entire removal of the mucous membrane. Nothing less than this do I consider satisfactory or sufficient. The curettement can be still more satisfactorily accomplished by having an assistant draw lightly on the tenaculum forceps grasping the cervix. This releases the operator's left hand, the index finger of which can be passed up the vagina along the outside of that portion of the uterus we are curetting. This finger forms an excellent *point d'appui* to the curette within the uterus, and thus aids materially in rapid and thorough work. One or twice during the progress of the curettement, and again at its close, the uterus is thoroughly washed out with 1:2000 sublimate solution. There are very few combinations of gynecological operations into which curettement does not with advantage enter.

FIG. 9.



Double-edge lance-shaped knife.


*Trachelorrhaphy*.—My method of performing this operation differs in no wise from that usually employed, except that I use a lance-shaped knife instead of the scissors, to remove such tissue as may be

required both in this operation and in amputation of the cervix. I find, however, that where combined operations are called for, amputation of the cervix is much more frequently indicated than trachelorrhaphy. On consulting my records for the past two years I find that I have performed three times as many amputations of the cervix as trachelorrhaphies.

*Amputation of the Cervix.*—The modification of Simon and Marckwald's operation adopted by Skene of Brooklyn, and so well described and pictured by the latter in his treatise on the *Diseases of Women*, 1889, page 345, leaves little or nothing to be desired, and I practise it strictly as there depicted, with only one exception. Instead of embracing the cervix above the seat of amputation with an elastic ligature to control hemorrhage, I secure the latter object by passing a curved needle armed with a catgut ligature around the circular artery high up on each side of the cervix. The ligatures are drawn tight and allowed to remain until removed by absorption. I was led to adopt this procedure after two or three unpleasant experiences with secondary hemorrhage after the employment of the elastic ligature, and have since had no further trouble in this direction. When perineorrhaphy enters into the combination with trachelorrhaphy or amputation of the cervix, I prefer to use sutures of absorbable chromicized catgut (Doederlein, "Resorbbares Chromsaureskatgut," *Centralbl. f. Gyn.*, 1890, p. 534), or those prepared from the tendon of the tail of the kangaroo, for the latter two operations. Otherwise, I prefer to sew the cervix with silkworm-gut. In work on the cervix the Hagedorn needle and the tenaculum forceps above described have been found especially serviceable, the latter in lieu of the tenaculum ordinarily used. It never slips its hold until released by the operator.

*Anterior and Posterior Colporrhaphy.*—The limits of the vaginal wall to be removed are fixed by four toothed sponge-holders; the tissue to be

FIG. 10.



Toothed sponge-holder.

removed is rapidly circumscribed and cut at the same time by a sharp-pointed scissors, one point of which, after piercing the mucous membrane of the vagina, is made to traverse along the connective-tissue plane between the vagina and the bladder or rectum. The segment of vaginal wall thus circumscribed is now peeled *entirely* from the underlying bladder or rectum, following the connective-tissue plane as a guide. In this lies the secret of success in both operations, as by doing so we reach vascular parts which will unite firmly after suture. The timid or inex-

perienced operator will fail right here, removing the vaginal wall in part of its thickness only, the deep layers of the vagina presenting raw surfaces ill adapted to firm union. I prefer to close the denuded surface thus made with buried kangaroo or chromicized catgut suture in tiers, and have thus far never failed to secure full primary union. I have tried and abandoned the Stoltz or purse-string method described by Mundé (*Am. Journ. of Obstet.*, 1890, p. 268) as the "best" for cystocele. It is theoretically and practically incorrect, in that it shortens the vagina in its length as well as in its circumference, a thing it is rarely, if ever, desirable to do.

*Perineorrhaphy.*—The method invariably employed is that described by the author in a paper entitled "A New Method of Suture in Perineorrhaphy," published in the *Am. Journ. of Obstet.*, October, 1890. I there reported ten cases, all of incomplete laceration. Since then I have operated upon twenty-seven cases more, five of which were complete tears into the rectum, making thirty-seven cases in all. In every single one of them I obtained primary union and a perfect result at the first operation.

*Shortening of the Round Ligaments*—is performed after the author's method as described in the *New York Medical Journal*, October 11, 1890. After an experience with the method now embracing fifty-one cases, I am more pleased with it than ever, both as regards the immediate and ultimate anatomical and therapeutical results. The only modification in the operation as described is a slight one in the method of suture. I now close the canal and secure the ligament by buried silkworm sutures embracing the cut fascia of the external oblique muscle and the ligament; uniting the superficial fatty layer and skin by a running suture of catgut. I would here like to emphasize one point only, a disregard of which will surely lead to disappointment: shortening of the round ligaments is neither alone nor in combination a suitable operation for prolapsus uteri. The sole indication for the operation is a non-adherent retroverted uterus with normal-sized, non-adherent tubes and ovaries, and then only when the symptoms are plainly referable to the retro-displacement. I have within the past six months, however, in two cases of adherent retroversion with normal-sized appendages, released the uterus from its adhesions under narcosis, after the method of Schultze (without a laparotomy), and secured the uterus in anteversion by shortening the round ligaments.

*Ventro-fixation of the Uterus.*—I will describe the operation as I perform it in adherent retroversion, and in combination with other operations for prolapsus uteri, leaving out of account those cases in which it is performed in the course of laparotomy for other conditions—diseased adnexa, and so forth.

An incision four or five centimetres long is carried through the abdomi-

nal wall in the median line anteriorly between the umbilicus and pubes, the patient being in the Trendelenburg posture. Two fingers are then introduced, the pelvis is explored, and the uterus, if adherent, is liberated. The anterior surface of the uterus is next grasped with the tenaculum forceps at a point on a line with and midway between the origin of the Fallopian tubes, and the uterus brought forward to and sustained behind the abdominal incision. Three silkworm sutures are next passed embracing fascia, muscle, peritoneum, and a section of the anterior uterine wall two or three centimetres wide and six to eight millimetres deep. One suture passes on a level with the origin of the tubes, the second below, and the third above that level. Two or three silkworm sutures embracing fascia, muscle, and peritoneum are inserted to close the balance of the deep parts of the abdominal wound. The tenaculum forceps is removed and the anterior face of the uterus between the points of entrance and exit of the three sutures is scarified by scraping off its peritoneum. All the silkworm sutures are now tied, cut short, and buried by closing over them, with running catgut suture, the skin and superficial fat. The author has performed ventro-fixation as above described for retroversion and prolapsus twenty-one times, exclusive of nearly an equal number of cases in which it was performed in the course of laparotomies undertaken for the relief of other conditions. All have recovered, and I know of none in which the uterus has again become retroverted or prolapsed, although a number of my cases are over three years old.

*Nephrorrhaphy.*—An incision extending from the twelfth rib to the crest of the ilium is carried through the posterior abdominal wall along the outer edge of the quadratus lumborum and erector spinæ muscles until the peri-renal fat is reached. This is drawn out of the wound until all slack around the kidney is taken in, and the redundancy is cut off with scissors. In doing this care must be exercised not to drag up and open the peritoneum near the lower pole of the kidney. The capsula propria of the kidney is thus exposed and is incised mesially, along the length of the convexity of the kidney, to the extent of seven or eight centimetres. This incision in the capsula propria should involve the lower half of the kidney rather more than the upper, as it is desirable to elevate the kidney as much as possible beneath the ribs while mooring it to the posterior abdominal wall. The incised capsula propria is peeled off from the kidney substance to the extent of 1.5 centimetres on either side of the incision along its entire length, and is reflected like the lapel of a coat, thus laying bare quite a large area of raw kidney surface. From four to six silkworm sutures are passed, embracing the muscles and fascia of the abdominal wall, the cut edges of the fatty capsule, the reflected as well as the still adherent capsula propria, the kidney substance itself, to the extent of including all the portion stripped

of capsule to a depth of six or eight millimetres from the surface. A drain composed of eight or ten strands of silkworm-gut is laid along the raw kidney tissue at the bottom of the wound, the ends of the drain emerging at either angle of the wound. The silkworm sutures are tied, cut short, and buried by closing the superficial fat and skin over them with running catgut. Usual antiseptic dressings.

I have performed nine nephrorrhaphies for movable kidney after the above method, my first operation bearing date of February 6, 1890, and do not know of a kidney so fixed becoming subsequently movable.

*Suture Material.*—The materials used for suture play an important part in combined gynecological operations, and may, therefore, well claim a moment's attention. I use for various purposes silk, silkworm-gut, catgut, tendons from the tail of the kangaroo, and chromicized catgut.

Silk is used only for suture of intestine, and as a retractor in abdominal section, either lip of the wound being pierced and drawn outward by a piece of heavy silk.

Silkworm-gut is used in perineorrhaphy, and in operations upon the cervix invariably when perineorrhaphy is not performed at the same sitting, and sometimes even when it is. As a buried interrupted suture it is used for the following purposes: To close the canal, and anchor the ligament in the operation for shortening the round ligaments; to unite fascia, muscle, and peritoneum in abdominal section; to attach the kidney to the muscular and fibrous structures of the abdominal wall in nephrorrhaphy; to secure the uterus to the deep structures of the abdominal wall in ventro-fixation. In bundles of from six to ten strands it forms an excellent material for drainage in Alexander's operation, nephrorrhaphy, and occasionally as a drain for the excessively thick fatty tissue of the abdominal wound in laparotomy. Its non-absorbability, strength, and insusceptibility to change constitute excellent qualities where secure and lasting closure of the firmer deep tissues and fixation of solid organs are required. It is as aseptic as silver wire, and as easily manipulated and tied as silk.

Catgut in suitable sizes is used for all ligatures, and as a running suture loosely applied to hold together the superficial fat and skin in wounds of those tissues. Silkworm-gut in interrupted buried sutures to close the firmer deep tissues, and catgut loosely applied to unite the superficial fat and skin, form the most satisfactory method of closure of wounds such as the gynecologist is required to make.

I have used kangaroo tendon quite extensively for some months past, but fail to see that it possesses any advantages over chromicized catgut. The latter, prepared as resorbable chromicized catgut, after the method of Doederlein, is superior in every way, cost included, to kangaroo tendon.

COMBINED GYNECOLOGICAL OPERATIONS.—Coming now to the subject proper of the various combinations of gynecological operations, they may properly be divided into two general classes:

1. Those combinations into which a laparotomy does not enter.
2. Combinations of which a laparotomy forms part.

The first class embraces, as far as the writer's own practical experience goes, curettement, amputation of the cervix, trachelorrhaphy, anterior and posterior colporrhaphy, lateral colporrhaphy, perineorrhaphy, shortening of the round ligaments, and nephorrhaphy.

The combinations of this class perhaps most frequently called for are curettement and amputation of the cervix or trachelorrhaphy, and the combination of these with perineorrhaphy. These combinations should always be easily performed within the hour—I have done them repeatedly in half the time—and the writer holds that it would be gross injustice to a patient at the present day to submit her to two sittings for their performance. Indeed, an operator claiming to be an expert should, as a rule almost without exception, be able to perform any combination of operations in this first class that may be required in the individual case, excluding only those combinations into which shortening of the round ligaments enters, within an hour and fifteen minutes. The operation for shortening the round ligaments—really a double operation—properly performed, requires from twenty to forty-five minutes, and may even, in case of unusual difficulty in finding and isolating the ligaments, be protracted a little beyond the latter limit.

The combination of operations of the first class next most frequently called for in the writer's experience, is curettement, amputation of the cervix or trachelorrhaphy, and shortening of the round ligaments. This combination I have performed fourteen times and never required above seventy-five minutes. In one additional instance a perineorrhaphy was added to this combination without exceeding the time-limit just named.

Next in frequency come the two following combinations: 1st. Anterior colporrhaphy and colpo-perineorrhaphy; 2d. Amputation of cervix, shortening of round ligaments, and perineorrhaphy. I find on my records memoranda of three of the first and four of the second combinations performed during the past two years. The time required for the first combination averaged thirty, that for the second combination seventy-five minutes. In one additional instance a trachelorrhaphy, in a second an amputation of the cervix, and in a third a curettement were added to the first combination, all performed within the hour.

Nephorrhaphy for movable kidney entered into combination with operations enumerated under the first class three times. Once it was combined with curettement for chronic endometritis and catarrhal salpingitis. A second time it was performed at the same sitting with curettement and trachelorrhaphy. In both instances I finished within

the hour. On a third occasion curettement, shortening of the round ligaments, and nephrorrhaphy were performed together in one hour and twenty minutes.

There is no excuse for a mortality in any required combination of operations included in the first class. Perfect asepsis secures against infection, and the good judgment, alertness and skill of the operator should insure his patient against the risks of prolonged anæsthesia and accidental dangers.

The indications for the various combinations of operations of the first class are given by the various combinations of pathological conditions existing in the particular case, and it is perhaps not too much for a woman who at the present day places herself under the care of a specialist in gynecology for operation to expect that all operative procedures required in her case, provided a difficult laparotomy be not among the number, be performed at one sitting. Indeed the modern woman worthy of the times may soon demand this as a matter of course.

I am not quite prepared to make the same positive statement in regard to combinations into which a difficult laparotomy enters, although I believe we are rapidly approaching this point, and that further improvements in the technique, including that of laparotomies, will soon enable us, as a rule, to perform at the same sitting all operations, including abdominal section, that may be required in any given case. The Trendelenburg posture has helped us along a great way in this direction.

Perhaps the most frequent, as well as the simplest, of the combinations into which an abdominal section enters is the combination of curettement with salpingo-oophorectomy for diseased tubes and ovaries. This combination, rationally so often called for by the coexistence and interdependence of endometritis and salpingitis in their various forms, has been quite freely discussed of late, more especially at the meetings of the New York Obstetrical Society. The consensus of opinion among prominent gynecologists is almost unanimous that the two operations are, as a rule, required. The only difference of opinion seems to be as to whether they should be performed at the same sitting, and if so, whether the curettement should precede or follow the salpingo-oophorectomy. My own rule has been to do the curettement first, even when the presence of pus in the pelvis has been positively diagnosticated, being careful to do the curettement with the uterus *in situ*, *i. e.*, without dragging down the organ.

The abdomen is then opened, the diseased parts removed, and the operation completed by a final irrigation of the uterine cavity with 1 : 2000 sublimate solution, to remove any infectious matter that may have come down from the tubes into the uterus during the manipulations within the abdomen. I have proceeded thus in quite a number of instances and have never had cause to regret doing so. I prefer this

order to doing the laparotomy first, closing the abdomen, and taking the chances of internal hemorrhage by slipping of an intra-abdominal ligature during the subsequent curettement.

In addition to the combination of curettement with removal of diseased appendages, I find on my records two cases of fibromata uteri in which I combined curettement with removal of the normal adnexa.

Among the combinations of abdominal sections with other operations, hysterorrhaphy or ventro-fixation of the uterus figures very prominently. I leave out of account here those cases in a which a laparotomy is the only operation performed, and in which, after extirpation of diseased appendages, or removal of a tumor, etc., the uterus is fastened to the anterior abdominal wall in closing the latter.

The most frequent combination of hysterorrhaphy is with curettement. Indeed, I would lay it down as a law that curettement should *always* precede laparotomy for ventro-fixation of an adherent or non-adherent retroverted uterus, just as it should *invariably* precede shortening of the round ligaments. The condition of the endometrium in retroversion as well as retroflexion always calls for a curettement.

I have on my records two cases in which a badly lacerated cervix coexisted with retroflexion of an adherent uterus, the appendages being apparently normal. In one of them a trachelorrhaphy, in the other an amputation of the cervix, was performed at the same sitting with curettement, severing of adhesions, and hysterorrhaphy.

*Prolapse operations.* We next come to the important class of plastic operations for prolapsus uteri, partial and complete, into any and every combination of which operations ventro-fixation of the uterus should, as a rule to which there can hardly be an exception, always enter.

I find upon my records notes of nine combined operations for prolapsus uteri, upon eight patients, one of the patients being operated upon twice. In all but one of these cases the prolapsus was complete, forming the so-called procidentia uteri, the uterus and vagina being completely outside of the body between the thighs.

The conditions existing in the case of incomplete prolapsus called for the following combination of operations: Curettement, anterior colporrhaphy, ventro fixation of uterus and colpo-perineorrhaphy, which were performed at one sitting within the hour, and resulted in a lasting cure of the descensus uteri.

The case of complete prolapsus operated upon twice occurred in a virgin, and was associated with, and due to, tubercular peritonitis with ascites. I have already reported the case in full, in a paper on "Tubal and Peritoneal Tuberculosis," published in the *Transactions of the American Gynecological Society*, 1891, and shall therefore not enter into further details here.

In three cases the complete prolapsus and its associated conditions



called for the performance at one sitting of the following operations: Curettement, amputation of the cervix, anterior colporrhaphy, ventro-fixation of the uterus, and perineorrhaphy. In each of the three cases the five operations were performed within seventy-five minutes, and the women all remain cured; the first of the three cases, however, having been operated on only a little over a year ago.

In another case, also of complete prolapsus in a nullipara, I started out to do the same series of five operations just reported upon, but changed my mind during the course of the operation, and performed double lateral colporrhaphy instead of anterior colporrhaphy and colpo-perineorrhaphy, the other operations being the same as in the other three cases. This was my first experience with lateral colporrhaphy, and, owing to this fact probably, the combination demanded one hour and fifty minutes. The result, however, has been equally as gratifying as in the other cases.

In another case of complete prolapsus, previously operated upon without success by a very distinguished confrère, the following combination, requiring one hour and fifty minutes, succeeded in effecting a cure: Curettement, anterior colporrhaphy, posterior colporrhaphy, perineorrhaphy, and ventro-fixation of the uterus. The changes produced in the various tissues by the unsuccessful previous operations were responsible for the undue length of time required for the successful combination of operations.

Finally, I have to report a failure in combined operations for complete prolapsus uteri. It was my first case, a lady of fifty, and after performing curettement, amputation of the cervix, anterior colporrhaphy, and perineorrhaphy, I proceeded to shorten the round ligaments for the purpose of sustaining the uterus from above. Just here a double mistake was made, which I wish to record for the benefit of those who may not have had a similar experience. The first mistake was to do Alexander's operation for prolapsus. Shortening of the round ligaments is *emphatically* not a proper operation, singly or in combination with other operations, for prolapsus uteri, partial or complete. *The* indications for shortening the round ligaments are given in prolapse of the non-adherent tubes and ovaries, and *par excellence* in retroversion of the non-adherent uterus, the appendages being normal, although perhaps displaced. The second mistake was in expecting to find the round ligaments in a woman who had passed the menopause, after which period in a woman's life the round ligaments atrophy and undergo fatty change with the uterus, only in a more pronounced degree. Of the fifty-one cases in which I have operated for shortening the round ligaments, this is the only one in which I failed to find the ligament, as well as the first and last case in which I attempted to perform the operation in a woman past the menopause. To return, however, to the case—

it proved a complete failure. Had I supplemented the plastic operations below by a ventro-fixation of the uterus, I feel confident, from the balance of my experience in this direction, that I would have scored a success.

It is just this—with this one exception—satisfactory and successful experience with plastic operations for the cure of complete prolapsus uteri which compels me to regard total extirpation of the uterus for the cure of prolapsus as uncalled for and unjustifiable under ordinary conditions. By ordinary conditions I mean those in which the prolapsed uterus is neither the seat of a neoplasm, nor, without containing a neoplasm, itself so increased in size that it may not be reduced to about the normal size of the organ by means of an amputation of the cervix. This fact, moreover, must be borne in mind, that in aggravated cases of complete prolapsus, such as I have reported above, even total hysterectomy is insufficient in itself to cure, but to be efficient must, as a rule, be supplemented by various plastic operations upon the vagina and vulva.

It may be proper to add that the wounds of the various operations entering into combination in the above cases of complete prolapsus all healed by primary union in each instance.

A rather complicated combination of operations I have reported in a case presented to the New York Obstetrical Society. As the case is described in full in the *New York Journal of Gynecology and Obstetrics*, April, 1892, p. 379, I will here only outline it: *Suppurating intra-ligamentary cystoma; unilateral chronic pelvi-peritonitis; secondary salpingitis and appendicitis; extensive laceration of cervix, and of perineum through sphincter. Curettement; trachelorrhaphy; removal of cyst, tube, and appendix vermiformis at one sitting; recovery.* I will merely add that three months later the patient returned for perineorrhaphy for complete tear through sphincter, which operation has been successfully performed. I might cite additional instances of laparotomies for various conditions combined with plastic operations, all successful, were there any special object in doing so.

As regards the mortality of combined operations into which a laparotomy enters, the death-rate will depend to a very great extent upon that of the special intra-abdominal operative interference called for. Thus, when ventro-fixation of the uterus forms the only intra-abdominal procedure, no matter how many simultaneous plastic operations are performed in combination with it, the mortality should be *nil*. It becomes quite a different matter, however, when, for instance, curettement and laparotomy for puerperal pyosalpinx or intra-peritoneal puerperal abscess are called for in the same case. The mortality of the laparotomy then becomes the determining factor, and is, of course, not lessened—nor, in my estimation, increased—by the accompanying curettement. Of the

entire number of cases in which the author has performed combined operations he has lost but one, a case of retained secundines, septic endometritis, puerperal pyosalpinx, and intra-peritoneal abscess, *i. e.*, an extreme, almost necessarily fatal case of puerperal sepsis, in which but a week ago I curetted the uterus, removed the pus tubes, and emptied the intra-peritoneal abscess at the same sitting. Had I performed the laparotomy without the curettement, the result would have been the same to the patient; the author's mortality in combined operations, however, would have remained where it was a week ago, *i. e.*, at *nil*.

Lest I may be suspected of never having had a failure in combined operations, I will conclude this paper by reporting *all* the failures, complete and partial, that I have had:

*Failure No. 1.* A case of retroversion of the adherent uterus, with laceration of the hypertrophied cervix, called for curettement, amputation of the cervix, and ventro-fixation of the uterus. After finishing the curettement, in doing the amputation of the cervix, repeated hemorrhage required the removal and reinsertion of all the cervical sutures three different times in succession. So much time (nearly an hour) was lost in this, and in securing the bleeding vessels, that I considered it imprudent to prolong the anæsthesia sufficiently long to add the laparotomy. The latter was successfully performed two weeks later.

*Failure No. 2.* Curettement, amputation of the cervix, and shortening of the round ligaments were called for in this case. After performing the two former operations, and isolating and drawing out both round ligaments, the right round ligament in the final pull was torn out of the uterus. Both Alexander wounds were closed, and ventro-fixation of the uterus immediately added. The patient made a good recovery.

*Failure No. 3.* The same combination, *plus* a perineorrhaphy, was called for as in the case just related. In performing the Alexander the left round ligament was pulled out of the uterus, and, as in the previous instance, ventro-fixation was immediately substituted for shortening of the round ligaments. Uneventful recovery.

These two cases, and the one already reported in this paper, where I failed to find the ligaments in a woman past the menopause, embrace *all* the disagreeable experience which I have had with the operation for shortening the round ligaments.

As in combined gynecological operations the time element is of such great importance, it may be proper to state that wherever the time of an operation has been mentioned in this paper it has always been reckoned from the first incision to the tying of the last suture.

In conclusion, the author would refer to the dearth of literature dealing comprehensively with the subject of combined gynecological operations. The only publication, the title of which indicates an attempt at a systematic treatment of the subject, which he has met with, is a paper by Mundé ("Combined Operations in Gynecology," *New York*

*Medical Journal*, May 18, 1889), the scope of which is, however, more limited than that of the present paper.

SUMMARY.—The tendency of modern gynecology is to progress in a surgical direction.

The uncertainties and unreliability of other methods of treatment as compared with the results obtained by surgical measures are proverbial.

With the rapid strides forward of surgical gynecology, this contrast is daily becoming more accentuated.

Increased confidence in results growing from increased experience and progressive skill will incline the individual operator more and more to trust to surgical resources.

Many cases require more than one gynecological operation to effect a cure.

All gynecological operations required in a given case should at the present day, as a rule almost without exception, be performed at the same sitting. The patient has a right to expect this from the expert claiming to possess the highest degree of operative skill. That this will be the standard of the near future the author does not doubt.

Success in combined gynecological operations presupposes first of all perfect asepsis and a not too prolonged anæsthesia. The duration of the latter need but very rarely exceed one and a half hours even in the most difficult cases.

Other things necessary are the requisite degree of operative skill and dexterity, sufficient and efficient assistance, a perfected technique of the various operations attempted, and an instrumentarium suitable for rapid work.


Combined gynecological operations may be divided into two general classes:

1. Combinations into which a laparotomy does not enter.
2. Combinations of which a laparotomy forms part.

The expert operator should be able to perform any required combination of operations of the first class within the time-limits of safe anæsthesia.

The same statement holds good of the combinations of operations of the second class into which a *simple* laparotomy enters. When a *difficult* laparotomy forms part of the combination the patient's interests may occasionally be better served by operating at two sittings.

There is no excuse for a mortality in combined operations of the first class. The mortality of combinations into which a laparotomy enters will depend upon that of the special intra-abdominal operative interference required.



# The American Journal OF THE MEDICAL SCIENCES.

MONTHLY, \$4.00 PER ANNUM.

WITH 1892 THE AMERICAN JOURNAL OF THE MEDICAL SCIENCES enters upon its seventy-third year, still the leader of American medical magazines. In its long career it has developed to perfection the features of usefulness in its department of literature, and presents them in unrivalled attractiveness. It is the medium chosen by the leading minds of the profession on both sides of the Atlantic for the presentation of elaborate Original Articles; its Reviews are noted for discernment and absolute candor, and its Classified Summaries of Progress each month present an epitome of medical advances gleaned by specialists in the various departments. According to unquestionable authority, "It contains many original papers of the highest value; nearly all the real criticisms and reviews which we possess, and such carefully prepared summaries of the progress of medical science and notices of foreign works that from this file alone, were all other publications of the press for the last fifty years destroyed, it would be possible to reproduce the great majority of the real contributions of the world to medical science during that period."

## The Medical News.

WEEKLY, \$4.00 PER ANNUM.

THE practical value of THE NEWS is proved by its continually increasing subscription list. Every method of conveying serviceable information is utilized. Leading writers, teachers, and practitioners furnish original articles, clinical lectures, and brief practical notes; hospital physicians and surgeons detail the latest approved methods developed under their enormous opportunities; progress is gleaned from the best journals of all civilized nations; a special department is assigned to important abstracts requiring ample space for adequate presentation; able editorial writers deal with important questions of the day; medical literature is impartially reviewed; society proceedings are represented by the pith alone; correspondence is received from medical men in position to know all occurrences of medical importance in the districts surrounding important medical centres, and matters of interest are grouped under news items. THE NEWS, in short, is a crisp medical newspaper, a necessity to every practitioner. Its sphere is different from and complementary to that of the ideal medical magazine, THE AMERICAN JOURNAL. To lead every reader of either to prove for himself the value of the two combined, the commutation rate has been fixed at the rate of \$7.50 per annum.

### The Year-Book of Treatment for 1892

Gives a classified summary and review of the real advances in treatment made during 1891, in all departments of the science of medicine. Price \$1.50; or in combination with either or both the above journals, 75 cents. *Ready early in 1892.*

### The Medical News Visiting List for 1892

Published in four styles: Weekly, dated, for 30 patients; Monthly, undated, for 120 patients per month; Perpetual, undated, for 30 patients weekly per year; Perpetual, for 60 patients weekly per year. The first three styles contain 32 pages of important data and 176 pages of assorted blanks; the 60-patient perpetual consists of 256 pages of blanks. Price, each, \$1.25. In combination with either or both above periodicals, 75 cents. Or, JOURNAL, NEWS, VISITING LIST and YEAR-BOOK, \$8.50. Thumb-letter index for VISITING LIST, 25 cents extra.

LEA BROTHERS & CO., PUBLISHERS, PHILADELPHIA, 706 & 708 SANSOM STREET.