

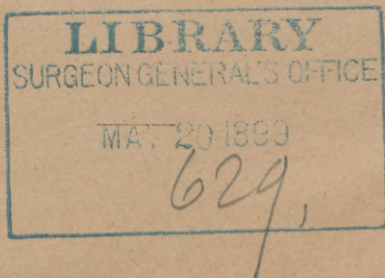
JACOBI (A.)

DR. S. TYNBERG'S PYGOPAGUS.

BY

A. JACOBI, M.D.

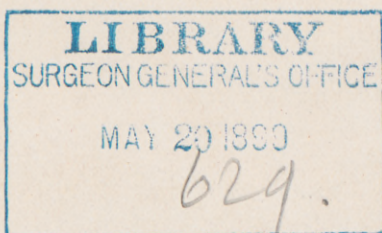
New York.

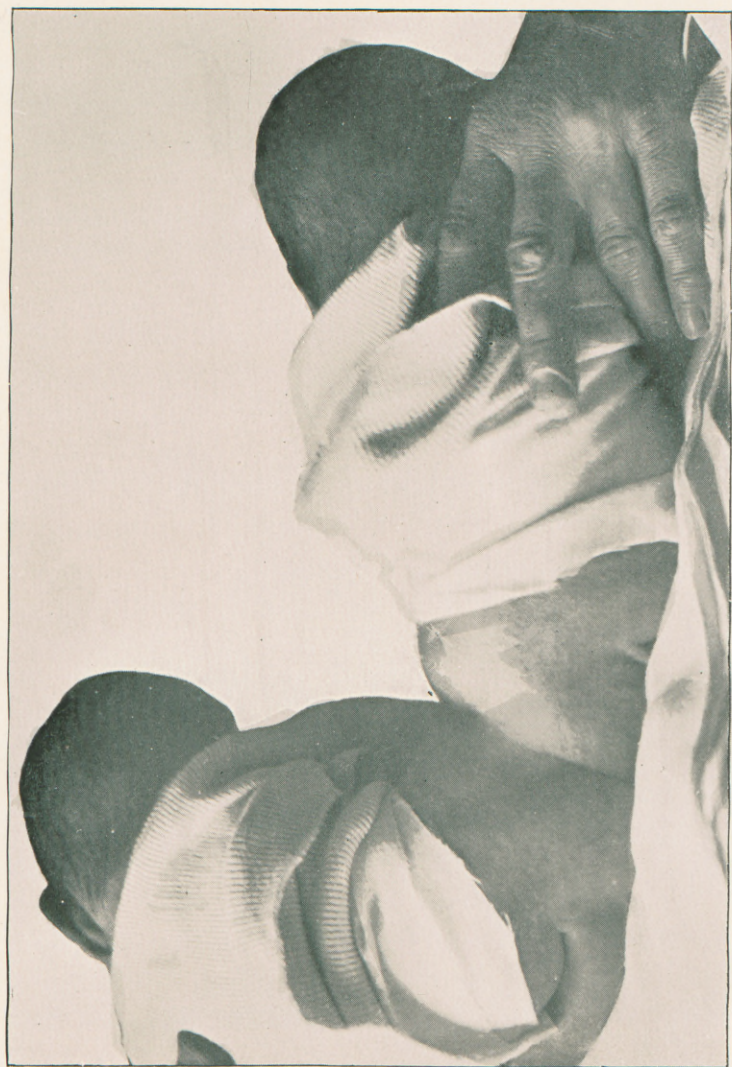

FROM

ARCHIVES OF PEDIATRICS,

October, 1895.





DR. S. TYNBERG'S PYGOPAGUS.*

BY A. JACOBI, M.D.,

New York.

Two female children were born April 15th, 1895, in 342 East Forty-second street, New York, in the presence of Dr. Sigmund Tynberg, with whose name the newcomers ought to be handed down to posterity. Confinement was easy, the head of one fœtus being soon followed by the lower extremities of the other, and the rest of the joined twins. The placenta was single, also the cord which divided into two branches two inches from its velamentous insertion. The twins are united below the third sacral vertebra, the sacra are united on one side, so that the babies can lie almost alongside each other; and one side, or posture, may be called front, the other back. The diameter of the juncture is about one and one-half inches. The backs of the children are straight, the upper sacral vertebræ are distinct, the lower and the coccyx are single. From one side (the anterior) the finger presses in to a great distance; not so on the opposite side. On the former the tubera ischii are very marked. There are two vaginæ, two clitorides, two urethræ, (the children do not micturate simultaneously), four labia minora, but only two majora which surround the two sets of genital organs.

There is one anus, but the rectum is double, has at

* Read before the American Pediatric Society, Virginia Hot Springs, May 29, 1895.

least a septum; two silver probes introduced do not touch each other. The babies begin their efforts to defecate simultaneously.

Tickling on the soles of the feet of one produces no effect on the other child. They live a separate life. One cries in the night and sleeps in the daytime, the other follows opposite rules. The mother looks pale and worn in proportion.

Pulse in one foetus 122, in the other 126, both in the upper and lower extremities. Both babies are thriving.

In the following I shall give a brief outline of the history of pygopagus, which will show that Dr. S. Tynberg's case is the fourteenth on record.

Amb. Paré (*Opera Paris*, 1582, p. 734) has two cases:

CASE I.—Two girls were born 1475, at Verona, “sibi dorso ab imis humeris et nates usque arctissime cohaerentes.”

CASE II.—“Anno dom. 1486, ad Hildebergam in Agri Palatini pago Robarchio (Rohrback, near Heidelberg), gemelli duo nati sunt dorsibus cohaerentes et hermaproditi ambo.” (Males with a high degree of hypospadias.)

In both cases a fair part of the vertebral columns, besides the sacra, appear to have been in common. The latter case is also mentioned by Licetus, *de Monstris*, Amst., 1665, p. 80.

CASE III.—Treyling's case is found in *Acta Phys.-Medica Acad. Cæsareæ Leopoldino-Carolinæ*, *Nat. curios. exhibentia Ephemerides*, Tome V. *observ.*, 133, p. 445.

“Gemellæ mediantibus ossibus coccygis sibi invicem connatæ” were born 1700, in Kolndorf, Krain, Austria. A Vienna surgeon tried to separate them with a medicinal caustic. The girls lived but four months. Every organ was normal but the coccyx, which was common to both. The rectum was double, but the anus single.

CASE IV.—Helena and Judith, the Hungarian girls, were born Oct. 26th, 1701, and died when twenty-two years old (Torkos in *Philos. Trans.*, vol. 50, part i, 1757,

p. 311; *Werther disputatio med. de monstro Hung.* Lips, 1707. Joh. Mich. *Eccardus Diss. Kiliae*, 1709. Geoffroy St. Hilaire.

They could walk forwards and backwards, but slowly. Anus was common, it lay between the right thigh of one and the left of the other. Vulva was single.

Defecation was simultaneous, micturition was not. Judith became hemiplegic and had convulsions, also hysterical attacks. Helena never suffered. One had pertussis, the other was spared. Menstruations differed in time, amount, and symptoms. Judith was taken sick, and both died after a fortnight, Helena having a slight fever and frequent coma. The iliac arteries and veins communicated in the pelvis.

The sacra combined from the second vertebræ downwards. Vulva and anus in common. Urethra single.

CASE V.—C. F. Wolff in *Acta Acad. Scientiarum Petropol. pro anno 1778*. P. i, p. 41.

Twer, Russia, 1778. Children (sex not mentioned) lived two months.

Half of the pelvis were united, from upper margin to coccyx. Anus was in common. No other data.

CASE VI.—Barkow (*Monstra animalium duplicia per anatomen indagat.*, Lips., 1828) describes two femal fœtuses born at full term.

Perineum is common. There are two anuses separated by a septum. Three labia majora; four minora, two of which were larger (the posterior ones), two smaller. Each fœtus has a large and a small one. Vaginæ are separated by a septum. There are two urethræ and two cords. The sacrum is single below the first vertebræ; instead of the bone below, there is but a strong ligament. One fœtus had a large diaphragmatic hernia. Each had but one kidney. One had but one umbilical artery. The two cords were combined in the sacral canal. No nerves, however, originated in this combined part.

CASE VII.—Normand (*Bull. de la Faculte de Medecine*

de Paris, 1818, No. 1) reports his "Observation sur deux jumeaux accolés dos à dos."

A woman of thirty years had two children previously. The pygopagus had four nates, one large scrotum, four testicles, one penis, one anus, one urethra, one placenta, and one cord, with two branches.

Meckel (*Müller's Arch.*, 1850) says that two cords have been observed only in fourteen cases of parietal and frontal adhesion, and in the Hungarian sisters. Also in the cases of Barkow, and Licetus (Amb. Paré). One of the (male) children was one and one-half inches longer than the other. Extremities, however, were equal. They died on the ninth day.

CASE VIII.—Molitor (*Beob. u. Abh. aus d. Gebiete d. ges. prakt. Heilk. v. oesterreich. ärzten*, 5, Wien, 1826) reports a female pygopagus.

There were one placenta, one cord, with two branches; one anus, one urethra. The infants were joined from last lumbar vertebræ to coccyx, and partial union existed between the ossa ilium. The twins were of unequal size, lived twenty-five days, and died in convulsions. No autopsy.

CASE IX.—Chrissie and Millie, born in North Carolina, in 1851.

One of the earliest descriptions is that by Ramsbotham. The children were then five years old. The union had a circumference of sixteen inches, and extended from below the first sacral vertebræ to the coccyx. There is union of the right half of the sacrum of one, and the left of the other infant. There are four tubera, one anus below the coccyx, one blind depression laterally. The single rectum is large, no septum within reach. There are two clitorides, two hymens, two vaginæ, two urethræ. Only two labia majora. The symphyses are distinctly separated. The genital organs are at some distance from each other.

The children can kiss each other; one rests on her back, while the other is on her side. They walk well, but

not alongside each other. One may be awake when the other sleeps. They are hungry at different times. Pulse is not synchronous. Purgatives take effect only on one. Menstruation is synchronous. Defecation is synchronous, but Münter reports that they can hold their feces separately.

(Virchow in *Berl. Klin. Woch.*, 1873, No. 9. Tardieu *Bull. de l'Acad. de Med.*, 2 Serie, Tome III., *Seance* 20th, 1874.)

On the union there is a zone of some centimetres with common sensations. If one be touched, a sensation of something going on is felt by the other girl, but no localization is possible. While the radial pulse is not synchronous, the pulse of the arteries of the feet is, which proves a union of the aorta in the pelvis before branches are given off to the lower extremities.

CASE X.—Joly and Peyrat (*Bull. de l'Acad. de Med.*, 2 Serie, Tome III.) relate the female pygopagus born in January, 1869, in Mazères, France; one died after ten hours, the other after twenty.

One of them had a spina bifida. There were two cords and two placentæ, one vulva, one vagina, clitoris, hymen, urethra, anus. The connection of the two bodies reached probably from the first or second sacral vertebræ downwards.

CASE XI.—The Bohemian sisters, Rosalia and Josefa Blazek, born January 20th, 1878, were still exhibited in Vienna about the latter part of 1892. Breisky, in Prague, and Marchand, of Breslau (*Br. ärztl. Zeitsch.*, 1881, No. 10) furnished descriptions. Their mother was twenty-two years old, and had a female child before.

The faces are turned to one side so that there is a virtual front and back. The girls are well developed, both physically and mentally. Very careful examinations were never permitted. The pelves are connected throughout the sacra. There are two gluteal regions. Probably the two spinæ posteriores of the ossa ilium are amalgamated. There is one set of labia majora, but two vaginæ;



urethra is single, but vulva appears more triangular. The skulls are asymmetrical.

CASE XII.—Two female foetuses of the ninth month are described in a pamphlet by Friedrich Adolph, of Frankfort-on-the-Main.

Placenta single; cord single up to twenty-four cm., then two branches are given off of forty-five and fifty cm. in length. Total weight of the two foetuses 4380.0 grammes. They are turned to one side so that it is possible to speak of front and back. There are slight differences in the lengths of the several extremities.

Head asymmetrical. One of them has a large encephalocoele of the occiput. Labia majora in common. Sacrum is common from the second vertebræ downwards. Coccyx is single.

The right os ilium of one foetus and the left of the other are connected, by cartilage above, by fibrous material below, so there is a common incisura ischiadica. The anatomical appearance at the autopsy is such that there probably was no adhesion and conglutination, but a primary formation of but a single sacrum and coccyx.

The sacs of the spinal dura mater of both foetuses connect above the sacrum, and are single in the canalis sacralis. Inside there is but one cord.

In one foetus the left umbilical artery did not come from the hypogastric, but directly from the aorta. The lower part of vena cava was double (through persistency of the vena cardinalis). As foetus No. one had but one hypogastric artery, the right being absent, so foetus No. two was without the left. Instead of them there was a large communicating vessel. Foetus two had no umbilical vein. Thus circulation was, similarly to that in the acardiacus, established through the liver of one foetus. Vulva in common, triangular. Labia minora united. One præputium and frenulum clitoridis. Clitoris not well developed. Two vaginae; two hymena; two urethrae; two bladders; two uteri. One of the four kidneys is low down in the pelvis. Recta are double, but united immediately above the anus.

CASE XIII.—Marchand (*Beitr. z. pathol. Anat. u. allg. Pathol.*, xvii., p. 1, 1895. Quoted in *Schmidt's Jahrb.*, 1895, No. 6) reports a female pygopagus

born dead in the eighth lunar month, after version and difficult extraction, the heads, however, following with facility the extraction of the four upper extremities.

The mother had three previous confinements and one (four months) miscarriage. Union takes place in lower dorsal and pelvic region. The two foetuses are turned to one side so as to present a common quasi anterior aspect. Foetus one (left) is forty-seven cm. long, foetus two (right) forty cm., and has a large occipital encephalocele. Their common weight is 4380 grammes.

There is a common placenta, 650 grammes, of a size twenty-three by eighteen cm. Cord is very thick, its insertion somewhat lateral, single to a distance of twenty-four cm., double afterwards. A branch of forty-five cm. supplies the smaller foetus, the other of fifty cm., the larger one. Each of these branches has but two blood vessels, one artery and one vein. The two arteries join into one just before the insertion of the cord in the placenta. The coccyx and the larger portion of the sacrum, up to the second sacral vertebræ, are common to both foetuses. There is union between the sacra, and the left os ilium of foetus one and the right of foetus two. The two other ossa ilium are moveably united at their posterior margins. This union is cartilaginous above, fibrous below. The lower part of the spinal dura mater is common. The lower part of the cord of foetus one is arched and joins the smaller one of foetus two, in this way it enters the sacral canal and forms the filum terminale. There is no actual cauda equina. The two sympathetic nerves join in the pelvis, at the juncture of the vertebral bodies, thus there is a common sympathetic innervation of the pelvic organs. There is a similar union of the vascular systems. The right termination of the aorta of foetus one does not form an umbilical artery, but runs into the left terminal branch of the aorta of foetus two. In the same way there is a direct connection between the two cardinal veins of both foetus one and two. The two recta join below and have but one anal aperture, but a small incomplete fistula at the anterior margin of the united anterior labia suggests a second anus. Urinary and sexual organs are double, only the vestibule is single.

Autopsy on Dr. Tynberg's case, made under the supervision of Prof. H. Biggs:

The children died on September 11th, 1895, the left child dying eight hours before the right.

Left child—The abdominal cavity was considerably distended, post-mortem discoloration being more marked than in the right. Both children were markedly emaciated, with considerable abrasions around the external genitals. The length of the left child was 48 centimetres; that of the right 50 centimetres. The large intestines, especially the transverse colon, were found markedly distended. From three to four drachms of clear, straw-colored fluid escaped from the abdominal cavity. The mesentery of the transverse colon was relatively very long. The liver extended slightly below free border of ribs and occupied whole of concavity of diaphragm of both sides, the larger mass being on the left side; the suspensory and round ligaments were situated about one centimetre to left of median line and extended to right and upward of diaphragm. The diaphragm was in the fifth intercostal space of right, and sixth of left side. The stomach lay beneath and in front of the large left lobe. It was very small. The mesentery of caecum was unusually long and free and the sigmoid flexure large. Abdominal organs were otherwise normal in position and character. Uterus, ovaries, bladder and rectum appeared normal from abdominal aspect.

Right child—Stomach and liver normal. Large intestine somewhat distended; omentum long; liver extending to free border of ribs. Stomach markedly greater than in left child. Pelvic organs normal in position and character. Between the pelvic cavities there was only fascia and peritoneum; the lower ends of dura mater spinalis communicated, both being very much dilated; the spinal cords *not* fused. The bond of union was at lateral masses of sacrum, the latter being unusually developed. It was ligamentous and cartilagenous in character and easily cut through. Dura mater sacs communicated through a space corresponding to the opening in the sacral canal. External genitals could be separated without injury to either.

Each child had its own complete generative organs, and each its distinct circulatory apparatus. The anus was common to both, but was largely situated in the right child. About one-half centimetre above the anus was a well-developed antero-posterior septum, also more closely identified with the right child, and thick enough to form a perfectly normal rectum for each. The cords did not communicate. The cord of the left child was normal; that of the right extended into the sacral canal.

ARCHIVES OF PEDIATRICS

EDITED BY

FLOYD M. CRANDALL, M. D.,

Adjunct Professor of Pediatrics in the New York Polyclinic, etc.

This is the only English publication devoted exclusively to diseases of infants and children.

It contains the best work of the best men for the general practitioner.

It is practical.

It makes an annual cyclopædia of Pediatrics, carefully indexed, of inestimable value for constant reference.

Volume begins with January.
\$3.00 a year in advance.

Subscriptions may begin at any time.
Send for sample copy and catalogue.

BAILEY & FAIRCHILD, Publishers,
24 Park Place, New York.