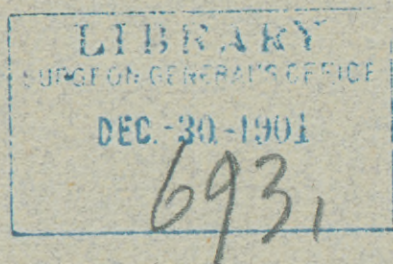


# KELLY (H.A.)

THE DISSECTION AND LIBERATION OF THE SPHINCTER ANI  
MUSCLE FOLLOWED BY ITS DIRECT SUTURE IN CASES OF  
COMPLETE TEAR OF THE PERINEUM, WITH A SPLINTING  
SUTURE PASSING BETWEEN THE OUTER AND INNER  
MARGINS OF THE MUSCLE.

BY H. A. KELLY, M. D.,

*Gynecologist-in-Chief, The Johns Hopkins Hospital.*







THE DISSECTION AND LIBERATION OF THE SPHINCTER ANI  
MUSCLE FOLLOWED BY ITS DIRECT SUTURE IN CASES OF  
COMPLETE TEAR OF THE PERINEUM, WITH A SPLINTING  
SUTURE PASSING BETWEEN THE OUTER AND INNER  
MARGINS OF THE MUSCLE.

BY H. A. KELLY, M. D.,

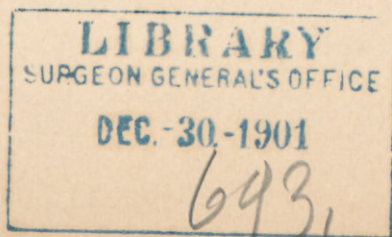
*Gynecologist-in-Chief, The Johns Hopkins Hospital.*

Although great progress has been made in gynecological plastic surgery within the past twenty years, there have been few or no changes in the treatment of complete perineal tears, that is, those which extend through the external sphincter ani.

The common symptom of a complete tear of the perineum is the lack of a control over the functions of the bowel, characterized by the involuntary escape of feces and gases. These sequelæ, however, are not invariably present in the same degree in all cases, and there is a diversity among them varying all the way from the entire loss of function on the one hand to perfect control on the other.

Some surgeons, reasoning upon supposedly physiological grounds, have gone so far as to assert that it is impossible for a woman with a divided sphincter to exercise any control whatever over the bowel function; I know, however, from repeated clinical evidences that perfect function may sometimes persist; it becomes therefore necessary to discover some satisfactory explanation of the facts rather than to deny them.

I would divide the cases of complete tear, to be investigated from this standpoint, into two groups. First, those in which the tear barely extends through the sphincter and goes no further, and, second, those in which the sphincter ends are separated by a well-defined interval of a centimeter or more,





In the first of these groups, where the muscle is only just divided and the ends lie close together, the cicatrization which follows the injury is a conservative effort on the part of nature, and soon results in the approximation of the ends of the muscle, knitting them firmly together, with only a plug of scar tissue between. In this event the muscle is no longer, in a true sense, a sphincter, as it cannot contract from all directions towards a central point, but is compelled henceforth, by the break on one side and the interposition of a plug of unyielding connective tissue, to contract up to the scar as a more or less fixed point, and this it does with greater or less efficiency. This peculiar effect produced upon the sphincter by the interpolation of a mass of scar tissue was pointed out many years ago by Hildebrandt.

The second group relates to those cases in which the sphincter ends are not bound together; I have at present under my care a patient with a complete rupture of the perineum, with deep, perfectly marked sphincter pits, separated by the entire breadth of the anal orifice, with a relaxed everted vaginal outlet and a uterus in descensus and retroflexion, and yet she has absolute control over fecal movements, whether formed or liquid, and is never disturbed by involuntary escape of gases. What is the explanation of this fact?

A careful physical examination shows that the patient has perfect voluntary control over the internal sphincter muscle, extending from the external sphincter about 2 cm. upwards.

The tonic contraction of the internal sphincter and its response to a voluntary effort can be most readily tested *in propria personâ*. If the tip of the finger is well oiled while sitting in a warm bath and inserted about an inch into the bowel while slightly bearing down to relax the sphincter, then, upon causing a voluntary contraction, a prompt response on the part of the internal sphincter will be noticed. When not voluntarily relaxed, the internal sphincter is in a state of tonic contraction guarding the orifice, while the external sphincter is not always contracted.

I believe, therefore, from repeated clinical observations that the tonic control exercised over the bowel functions resides rather in the internal sphincter than in the external, and that the external sphincter muscle is a provision against an emergency



and is intended to form a temporary, powerful supplement to the internal sphincter.

The external sphincter is of further use in the act of defecation, in breaking the fecal column at intervals, so tending to prevent prolapsus recti by creating a pause in the act and allowing time for more material to pass down into the rectum before the renewal of the straining.

This physiological fact explains the reason why, when the external sphincter ends lie close together and the internal sphincter is therefore uninjured, continence is always preserved.

I would add, too, to this category of manifest sphincter injuries, a much larger group of cases in which, owing to the fact that control over the bowels is retained, as well as owing to the natural, uninjured appearance of the anus, suspicion is disarmed, and the surgeon, even when he is brought into such close contact as is involved in the performance of a perineal operation, fails to recognize the fact that the sphincter ends are divided. I cannot sufficiently emphasize the importance of this observation, and therefore reiterate my conviction that many women have torn sphincters which are never discovered.

When the ends of the external sphincter muscle are separated by any considerable interval in a recent tear, then the internal sphincter is also torn, and, the wider the separation of the external sphincter ends, the greater the tear into the bowel and therefore of the internal sphincter above. What is true of the recent injury is true *a fortiori* several months later, when a wide tear is drawn down to a narrow line and an interval of 1 cm. between the pits may represent a rupture 3 cm. in depth. It is therefore to this tear of the internal sphincter that the loss of control over the bowel functions is due.

OPERATION.—The prevailing operation in this country is the Emmet, which I need not describe in detail as it is so well known. The operations practiced in Europe for the most part are of a similar nature, or flap-splitting or Hegar's method. The important principle in the Emmet procedure consists in the application of a series of sutures, to an area thoroughly denuded, first closing the bowel, then radiating out from the bowel, over the skin and onto the vaginal surfaces. Emmet further lays great stress upon a tension suture entering and emerging at points outside of and well behind the external

sphincter ends and traversing the septum, for the purpose of supporting and keeping all the fibres of the sphincter ends together. Dr. Emmet told me on one occasion that the devising of this suture cost him more thought than almost anything he had done in gynecology.

Although this operation, as well as the others mentioned, when well carried out, succeeds admirably in many instances, it still leaves much to be desired in that there does remain a residuum of failures, and a considerably larger percentage of cases in which the function is so imperfect at first that we are obliged to wait weeks or months for the patient to gain a satisfactory control, and sometimes in this latter group there are women who will tell you that when their bowels become loose they always find their clothes more or less soiled, while they are also apt to be uncertain about the control of gases.

In order to meet the various objections to the operation as practiced at present, I have devised several procedures based upon the physiological principles dwelt upon above; the first important point is the dissection and liberation of both ends of the sphincter muscle, after which they are sutured together with buried cat-gut sutures, end against end.

I can perhaps best emphasize the importance I wish to give this step by citing the first case in which I was led to operate in such a way.

CASE I.—The patient was brought to me in Dec., 1897, by Dr. J. A. Sexton, of Raleigh, N. C. She had had six previous operations performed for complete tear of the recto-vaginal septum, and upon inspecting the parts I found perfect union throughout, a pathologically small well-closed anus, and a far better result in the external appearance than is often secured in cases which are deemed successful. In spite of appearances, however, she had no control over the function of the bowel, and the gases escaped audibly at all times, and formed movements were discharged at once without the slightest ability on her part to restrain them (Fig. 1).

I was disinclined from my examination to do anything further to this patient, after all she had passed through, doubting whether I could improve her condition, but through Dr. Sexton's kind insistence I felt at last forced to make at least an earnest effort to better her state. So I operated Dec. 8, 1897, determined to make a clean dissection of the external sphincter, even, if necessary, going



so far as to lay the entire muscle bare, so as to make sure of bringing its ends into apposition, and leaving the end of the bowel encircled by a good muscular ring, if one could be found in the neighborhood.

I began the operation by making a semilunar incision with its convexity directed towards the symphysis, half way round the anal orifice and about 1 cm. from the anal margin (Fig. 1). As the dissection through the scar tissue was carried into the perineum, the edges of the incision were drawn in opposite directions, exposing a wide crescentic area. I found now that the sphincter could be beautifully demonstrated anatomically, and that the right end lay nearly in the normal position, but fixed in the median scar, while the left end lay at least  $2\frac{1}{2}$  cm. distant from the right end, and was attached to the tuberosity of the ischium (Fig. 2). After laying bare and freeing 2 cm. of each of the ends, I then trimmed off the scar tissue so as to expose fresh red muscular bundles, which I then united with three interrupted buried cat-gut sutures, simply transfixing the sphincter muscle 5 or 6 mm. from the cut ends. Two buried sutures were also used in the septum in the deeper fat layer of the wound, and the skin wound was finally closed with fine silk sutures (Fig. 3). The result was a perfect union and greatly improved control of the bowel from the first. I examined the patient again two months later, and passing a finger a short distance into the rectum and grasping the sphincter between finger tip and thumb could distinctly isolate it on all sides, and on telling her to contract the muscle I could feel that it was perfect throughout and under complete control.

I do not know of any other instance in which with an apparently well-formed anal orifice the sphincter muscle has been laid bare and the separated ends freed from their attachments and then joined by buried sutures.

Following the initiative of this case, I at once incorporated the dissection, isolation and separate suture of the sphincter muscle as an essential part of the technique of all my operations for complete tears, intending in this way to insure the bringing of the sphincter into the field as well as the exact union of its parts, end to end.

CASE II.—The next case was one of the classical sort, a secondary operation for complete tear where the parts had well cicatrized.

She was operated upon towards the end of February, 1898. She had had a complete tear of the perineum in consequence of a forceps labor conducted by myself in the preceding December; the immediate suture failed, and since that time she had had no control whatever over the bowel function. In place of the perineum there

was a boat-shaped cicatrix extending from two lateral prominences marking the former position of the fourchette, extending back to the anus. The recently cicatrized tissue fairly marked out the extent of the original tear in somewhat diminished form. I proceeded by denuding the vaginal sulci and the lateral surfaces as usual. I then exposed the sphincter ends by turning down a triangular flap of uninjured skin lying in front of the anus (see Fig. 4), catching the ends in their pits one at a time, pulling them up and out a little, and snipping with blunt-pointed scissors on all sides of the eminence until each sphincter muscle stood dissected out with perfect distinctness about 2 cm. beyond the surrounding tissue. On lifting the ends up the pull on the posterior part of the sphincter could be distinctly felt with the thumb and forefinger grasping the margin of the anus. The exposed ends were then denuded of the film of scar tissue covering them and brought evenly together with interrupted cat-gut sutures; the flap which was turned down over the bowel during the dissection was then brought up over the sphincter, and the rest of the wound closed as usual. The result was a perfect control over the function of the bowel from the very first, leaving nothing to be desired in respect to function, and the patient has now, a year later, absolutely normal control.

CASE III.—In my third case I was obliged to follow a somewhat different procedure, as the sphincter pits were not well enough marked for me to be sure of their identity. After making the usual denudation I then made two incisions parallel to the sides of the anus and extending downwards from the denuded area about  $1\frac{1}{2}$  cm. on either side (see Fig. 5). On pulling apart the tissues and dissecting inwards, the sphincter muscle was then clearly exposed, freed from its bed, and the ends cut off (Fig. 6). The rectal part of the tear was now closed by interrupted sutures applied on the rectal side down to the sphincter area, and a short distance out onto the skin surface (Fig. 7). The sphincter ends were then denuded and brought together with buried interrupted cat-gut sutures passed through them, after which the rest of the wound was united as usual (Fig. 8), and the para-rectal incisions carefully closed with interrupted cat-gut sutures.

Since then the following cases given in abstract have been operated upon in my clinic by Drs. Russell, Ramsay and myself.

CASE IV.—B. D., married, age 23, white.

*Diagnosis.*—Complete tear of perineum.

*Operation.*—Restoration of ruptured recto-vaginal septum.

The patient has been married five years and has had two children and one miscarriage. The first labor was difficult and instrumental,



at the second the child was still-born, while one month previous to admission, the miscarriage had taken place at four months.

Ever since the birth of the first child, three years ago, she has had a descensus of the womb, with bearing-down pains in the abdomen, pain in the back and headache, all of which symptoms have been worse during the past 3 months, the prolapse now being marked. The bowels move regularly every day.

*Examination* under ether showed: Extensive tear of recto-vaginal septum, through sphincter ani and up left sulcus, the tear apparently extending one inch into rectum.

*Operation* by Dr. Kelly, March 12, 1898. The usual Emmet denudation was made, and, in addition, the sphincter ends were dissected and pulled out on either side, 3 cm. on right and  $2\frac{1}{2}$  cm. on left, clear of all surrounding tissue. About 3 mm. of the ends were cut off to remove the white scar tissue and to present an even muscular surface; the ends were then sutured directly together with 4 cat-gut sutures and dropped and buried.

The septum was first united down to the sphincter, after which the sphincter was united, and then the remaining portion of bowel and finally the vagina and perineum. A silkworm-gut tension suture was inserted behind the sphincter ends but not so far posteriorly as usual. Duration of operation, 35 minutes.

*Convalescence* was uninterrupted; the healing was *per primam* and the result perfect; the patient had perfect control of the bowel from the very first. Maximum temperature  $98.8^{\circ}$  (2d day). Discharged well April 2, 1898.

CASE V.—F. G., married, age 26, white.

*Diagnosis*.—Retroflexio uteri; tear of the perineum, extending through the sphincter ani.

*Operation*.—Suspensio uteri; restoration of ruptured recto-vaginal septum.

The patient on admission complained of pain in the bladder and misery in the back. She had been married seven years; had had three children and no miscarriages. All three labors were difficult, the first two were instrumental, and in both these the outlet was lacerated with no attempt at subsequent repair. The last child was born two years ago.

The bowels were extremely constipated; she had hardly any control over them, especially as regards flatus.

*Examination* under ether showed: Outlet greatly relaxed; complete tear of perineum, extending through into bowel, the sphincter pits being distinct on either side; uterus in retroflexion.

*Operation* by Dr. Kelly, April 13, 1898.—Denudation in sulci and on lateral walls of vagina as usual, extending down to rectum and laterally to sphincter pits; ends of sphincter dissected out and

caught with forceps; rectum brought together in the usual way by interrupted cat-gut sutures, tied on the rectal side; ends of sphincter muscle freshened and brought together with 4 cat-gut sutures; a deep silkworm-gut tension suture was also inserted behind the sphincter ends; rest of closure in usual way. Uterus suspended in usual way. Time of complete operation, 75 minutes.

The *convalescence* was marked by a partial breaking down of the perineal incision, with some suppuration, but the perineum was well lifted up, and introduction of finger into rectum showed good sphincter action, except anteriorly, while the patient seemed to have good control over her bowels. The maximum temperature was 100° (on the 7th day). The patient was discharged May 10, 1898.

*Subsequent note*, Aug. 27, 1898.—Result of perineal operation is fair; some bulging of anterior vaginal wall, and pressure upon it and upon uterus causes discomfort. Sphincter ani has apparently its full power. Since leaving the Hospital the patient has improved in general health and is free from her old trouble, except some pain in the back and painful micturition.

Cystoscopic examination showed that the bladder was inflamed and infected, especially about the region of the trigonum, while the urine showed a great number of pus cells and a small amount of albumen.

CASE VI.—L. E., married, age 30, white.

*Diagnosis*.—Complete perineal tear.

*Operation*.—Restoration of ruptured recto-vaginal septum.

*Marital history*.—Married four years, two children and two miscarriages. The first labor, three years ago, very difficult, although not instrumental; the patient was lacerated, and the laceration was repaired, but not successfully; the second labor, one year ago, was not difficult.

Since birth of first child, she has had prolapse of uterus after standing for some time, the uterus returning to its place on lying down. Has absolutely no control over her bowels and but little over urination. Feels as if bladder prolapsed with the uterus. The patient suffers with dragging pain in the back and loins. All these symptoms have been worse since the birth of her last child.

*Examination*.—Complete tear through perineum and sphincter ani muscle, about one inch of the bowel being seen. Uterus in ante-position, low down in pelvis. Outlet greatly relaxed.

*Operation* by Dr. Russell, April 28, 1898.—Tear extended 3½ cm. beyond sphincter into bowel. Sphincter ani ends were dissected out free; the mucous membrane was united above the sphincter by interrupted cat-gut sutures; the ends of the sphincter were then united directly with 4 cat-gut sutures, 1 tension silkworm-gut suture going from side to side through the skin and the septum. The



outlet was then restored in the usual manner. Time of operation, 50 minutes.

The *convalescence* was uninterrupted; the bowels were well moved on the fourth day; the wound healed perfectly; the sphincter ani has good power, and the patient has perfect control of her bowels.

The patient's maximum temperature was 100° (2d and 7th days). The patient was discharged May 20, 1898.

CASE VII.—M. B., age 32, married, white.

*Diagnosis*.—Large retroflexed uterus with descensus; lacerated cervix; complete tear of vaginal outlet with concealed tear of sphincter ani.

*Operation*.—Trachelorrhaphy; restoration of ruptured recto-vaginal septum; suspension of uterus.

*Married* 13 years; has had three children and one miscarriage; all three labors were prolonged and very difficult, and the perineum was badly torn each time, the worst tear being at the last delivery, three years ago. No one of the labors was instrumental.

Since the birth of her second child, six years ago, the patient has had dragging and bearing-down pains in the lower abdomen, aggravated by walking or climbing, with progressively increasing loss of strength and loss of weight. Micturition has been increased in frequency and is occasionally painful.

The bowels are generally regular, but, since the birth of the last child, she has had difficulty in controlling the fecal movements whenever the bowels are loose.

*Examination*.—Uterus is enlarged and retroflexed. The vaginal outlet is so relaxed that the cervix is visible. A tear is seen extending up the median line into the rectum about two cm. in length. Slight lateral indentations indicate the possible position of the sphincter ends and this is verified by palpation or stimulation; the sphincter retracts on all sides except in front. The lips of the cervix are everted and congested.

*Operation* by Dr. Kelly, June 18, 1898.

Dilatation and curettage with the removal of abundant endometrial detritus. The lacerated cervix was repaired next, and then the vaginal outlet, including the sphincter ends; after the denudation of the wound area the sphincter ends were dissected and drawn out to the extent of 1 cm. Some scar tissue was then cut off the ends to make them square and fresh. The rectal side of the tear was then closed with six cat-gut sutures down to the sphincter ends; the ends were then pulled out and held so, while a *silkworm-gut suture was passed through the skin, through one sphincter end across the septum and out through the opposite sphincter end and through the skin again*. The sphincter ends were then accurately approximated by three cat-gut sutures. The rest of the operation was performed in the usual way.

The uterus was also suspended through an abdominal incision. Time of complete operation, 55 minutes.

The *convalescence* was uninterrupted; the healing was perfect; the vaginal outlet was well lifted up, with the cervix in good position as well as the uterus and the patient had perfect control of her bowels. Maximum temperature 99.8° (third day). Patient was discharged July 16, 1898.

CASE VIII.—E. N., married, age 47, white.

*Diagnosis*.—Multiple cervical polypi. Polyp of posterior vaginal wall. Rupture of recto-vaginal septum.

*Operation*.—Removal of polypi; amputation of cervix; repair of perineal tear.

*Marital history*.—Married at 18, seven children (oldest 25 years, youngest 5 years). Always had normal labors and was never attended by a doctor.

*Menstrual history*.—For the past six months has had frequent hemorrhages until a few (5 to 6) weeks ago, since then no flow at all. Associated with the hemorrhages were pains in legs and pelvic regions, which have continued up to the present time, occasionally associated with "colicky" pains in left hypochondrium. Bowels were usually regular up to the time of the hemorrhages, since which time they have been constipated. Micturition has increased somewhat in frequency of late. Urine is negative.

*Examination* under ether showed: Outlet gaping; complete tear of recto-vaginal septum, sphincter pits being definitely marked on both sides, with a bridge of scar tissue holding the ends of the muscles together. Several cervical polypi; one polyp of vagina; uterus enlarged, but in ante-position.

*Operation* by Dr. Ramsay, June 19, 1898.—Removal of vaginal polyp; amputation of cervix with its attached polypi; the denudation of the complete tear was made in the usual way to the sphincter pits; the ends of the sphincter muscle were caught, drawn out and dissected free. Cat-gut was used to draw together the bowel above the sphincter; the sphincter ends were then brought together with three cat-gut sutures, with a silkworm-gut suture *through the muscle* and the septum to relieve tension. The closure of the rest of the wound was performed in the usual way. Time of entire operation, 90 minutes.

The *convalescence* was uninterrupted; the healing was per primam, while by rectal examination the sphincter ani muscle could be felt contracting all around. The patient complained slightly of some pain in the left inguinal region which was relieved by enemata of starch water and fluid extract of Hamamelis. The maximum temperature was 100° (on 2d day). Patient was discharged well on July 20, 1898.



CASE IX.—Mrs. C. H., married, age 36, white.

*Diagnosis.*—Complete perineal tear ; relaxed vaginal outlet.

*Operation.*—Restoration of ruptured recto-vaginal septum.

The patient has been married 16 months and has had one child, born 15 weeks ago ; she was in labor three days, and the delivery was finally completed by instrumental interference, during which she was badly torn, both at outlet and cervix ; an unsuccessful attempt was made to repair the septum. Since the childbirth she has had severe pains in back and pelvis, with partial loss of control of the bowels, especially marked when the movements are loose. As a rule however the bowels are constipated.

*Examination* under ether showed: Outlet much relaxed, with a tear through the recto-vaginal septum. Sphincter pits are easily seen, the one on the left side being pulled  $2\frac{1}{2}$  cm. from the position in which it is usually seen (apparently by the transversus perinei muscle). Uterus in ante-position and freely movable.

*Operation* by Dr. Kelly, June 27, 1898.—On palpation sphincter ani muscle felt easily posteriorly and laterally but not anteriorly. A verticle cut 1 to 1.5 cm. long exposed the sphincter ends. The sphincter was dissected out, the ends pulled out to the extent of 2 cm. and splinted by a *silkworm-gut suture passed through the muscle and up through the septum* and left untied for the present. The vaginal wound was closed, doing away with the relaxation; the rectal tear was closed and then the silkworm-gut suture was tied and the sphincter ends united by four cat-gut sutures, with two silkworm-gut sutures to perineum above and the rest cat-gut, making good closure throughout. Time of operation, 38 minutes.

The *convalescence* was uneventful until July 10, when, on the removal of the external stitches, although the wound had apparently healed well, the sphincter held well, and the patient apparently had perfect control of the rectum, it was found that there was a recto-vaginal fistula, the fistulous opening being around the internal vaginal suture on the left side. On the removal of this a good deal of soft fecal matter oozed through the opening, through which a sound 3 mm. in diameter could be passed.

This of course necessitated a *second* operation, which was performed on July 14, 1898. The sphincter was found to have held well ; the fistula was just within the vagina and opened into the rectum about  $1\frac{1}{2}$  cm. within the anus. The sphincter was first dilated, and through the sphincter the rectal opening of the fistula was found ; its edges were now pared and freshened on the rectal side ; the vaginal side was then freshened in the same way. The rectal mucosa was closed with fine silkworm-gut sutures, with the knots turned into the bowel, and the vaginal opening was closed in the same way, with the knots toward the vagina. A rectal plug was then inserted.

The *convalescence* from this second operation was uneventful, except for the difficulty in moving the patient's bowels. Perfect healing took place, and the fistula was obliterated. The maximum temperature was 101° (sixth day after first operation). The patient was discharged on Aug. 2, 1898.

The patient was readmitted Sept. 9, 1898. She complained of pain at stool, which had been present ever since her discharge from the Hospital, with discharge of liquid material at times; the sinus seeming to heal for a day or two and then at stool to break down again.

*Examination* under ether showed: The sphincter ani muscle forms a *complete* ring around the anus, with normal radiating lines surrounding the orifice; while a sinus, slightly to the left of the median line in the perineum, opens just within the sphincter muscle; extending also 1½ cm. up in the recto-vaginal septum.

*Operation* by Dr. Russell, Sept. 14, 1898.—The sinus and the indurated tissue about it were dissected out; the opening in the rectum was enlarged by paring the edges and was then closed by five cat-gut sutures, passed on the rectal side. A few buried cat-gut sutures were also introduced on the perineal side. The perineal incision was then closed with interrupted silk worm-gut and cat-gut sutures. The *convalescence* was uninterrupted, the healing was perfect, the temperature never rose above 99°, and closure was complete. The patient was discharged Oct. 7, 1898.

CASE X.—C. C., married, aged 38, white.

*Diagnosis*.—Relaxed vaginal outlet. Rupture of sphincter ani muscle.

*Operation*.—Dissection and direct union of the ends of the sphincter ani. Resection of the relaxed outlet. Curettage of cervix.

*Marital History*.—Has been married 15 years. Has had four children, no miscarriages. All the labors were extremely protracted and difficult. The first and fourth labors were instrumental; the third child was still-born. After the birth of the first child she had convulsions. At her last labor she was badly torn, the tear extending to the anus, but no attempt at repair was made. Phlegmiasia alba dolens complicated her last puerperium. The first child is fourteen years old, the last (if living) would be two. The laceration mentioned above has never troubled her. The bowels are perfectly regular and under control, while there is an increase in the frequency of micturition.

*Examination* under ether showed: Tear of perineum through sphincter muscle and 1 cm. into the bowels above; the ends of the muscle widely separated and connected by a narrow band of scar tissue; a slight bilateral laceration of cervix; uterus of normal size and in anteposition.



*Operation* by Dr. Russell, August 1, 1898. The operation was performed in two steps.

(1) A semilunar incision was made at anal orifice at junction of skin and mucosa, the flaps were dissected back and the ends of the sphincter ani muscle exposed; the mucous membrane was united by cat-gut sutures, and then the muscle ends were drawn together and sutured with five cat-gut sutures. The primary incision was then united from side to side.

(2) The relaxed vaginal outlet was then resected in the usual way. Time of entire operation, 50 minutes.

The *convalescence* was only interrupted by the inability of the patient to void her urine and the consequent necessity of catheterization for the first week, followed by a mild cystitis, relieved by vesical irrigations.

The maximum temperature was 100° (on the second and eighth days). The wound in the rectum healed per primam; perfect union of the sphincter muscle was obtained, with perfect control of the rectum. There was a slight infection of one of the vaginal stitches. The patient was discharged well, September 1, 1898.

CASE XI.—Mrs. C. W., married, aged 43, white. Private hospital.

*Diagnosis*.—Complete tear of the perineum.

*Operation*.—Repair of the complete tear. Dissection and direct suture of the sphincter ani.

The patient has been married 23 years and has had six children, the youngest three and a half years old, and one miscarriage in 1890.

She was badly lacerated at her first confinement, when the delivery was instrumental (22 years ago); this was repaired by Dr. Helmuth, in 1891, and the perineum was ruptured again at the birth of her last child, three and a half years ago.

She complains of general poor health, frequent attacks of diarrhoea, and especially of an escape of gas from the vagina; she has also noticed fecal matter in the vagina; and often has great difficulty and sometimes entire inability to control the movements of the bowel.

*Examination* showed: The vaginal outlet torn through and the sphincter ends widely separated; the perineum boat-shaped, with much scar tissue between the vaginal and rectal openings, and the injury to the sphincter ends might easily be overlooked; the sphincter ends marked by pits two cm. apart.

*Operation* by Dr. Kelly, November 22, 1898. Denudation as usual, removing scar tissue over sphincter ends and freshening the torn septum, extending up both right and left vaginal sulci. In including the sphincter ends, *the incisions marking out the area for denudation were made differently from the rule by*

*cutting about three mm. away from the pits.* This was done so as to give the sphincter a wider berth, so that when the sphincter ends were united by buried sutures they would not lie so close to the skin surface as they would if the incision was made close to the ends. Both sphincter ends were caught with forceps, pulled up and dissected out with a pair of blunt scissors until they appeared about one and a half cm. long above the surface. The glazed white ends were then cut off, and the rest of the denudation completed, and the bowel above freed from the recto-vaginal septum.

The rectal rent was then closed by fine interrupted silk sutures passed on the rectal side, *entering and emerging on the mucosa about one cm. from the margin of the cut.*

After closing the rectal rent, *the sphincter was united by two cat-gut sutures and splinted by silkworm-gut sutures entered about one and a half cm. back of the edge of the cut in the anal margin, and carried up through the septum, piercing the sphincter both on entering and emerging.* Another suture was passed well behind this first one, up through the septum outside the sphincter as recommended by Emmet.

The skin margin was very carefully closed up over the sphincter, and the rest of the wound in vagina and perineum united as usual, *extreme care being taken not to leave any dead spaces.* The intelligent patient had perfect control over the sphincter from the first, and at once recognized the great difference in her condition. She made a prompt recovery and returned home entirely well.

The one remarkable and constant fact specially noted after each of these operations was the immediate sense of restored power which was discovered by the patient as soon as she was well over the effects of the anesthesia; there was a sense of natural control over the function of the bowel which had been absent since the injurious confinement.

In conning the literature of this subject I have discovered several interesting references which have a direct bearing upon the method described. In the first place Dr. R. L. Dickinson,\* has pointed out in an admirably clear paper devoted to the study of recent injuries to the sphincter ani, the important fact that the rupture of the muscles crossing the pelvic floor, in common with the external sphincter, is never median. The tear takes the direction of least resistance and avoids the aponeurotic web where the structures interlace in the middle

---

\* Amer. Gyn. and Obst. Jour., May, 1895.



line, breaking through laterally and severing the transverse perineal muscles and the sphincter well to one side. Out of sixteen cases ten were on the right, six on the left side, while another involved both sides of the sphincter. A close examination will always reveal an asymmetry, and not infrequently one end of the sphincter is found hanging out free on one side of the rupture, while the opposite side presents a deep pit from which it has been torn out. At the bottom of this pit is the other sphincter end. With the changes which take place during the period of cicatrization and contraction, well delineated by Kuestner and Leopold, this asymmetry is reduced to a minimum so that there finally remains but a slight obliquity in the level of the sphincter ends as a small index of a large difference earlier in the history of the case.

In these recent tears Dr. Dickinson with good surgical judgment used buried cat-gut sutures to bring the sphincter ends together; he says: "Two buried cat-gut sutures carried through the free hanging end of the muscle and then down into the pit to catch the hidden end, draw the parts into accurate apposition. The rest of the injury is then repaired as usual."

Sawaisky in an inaugural dissertation published in St. Petersburg, 1895, describes a method of treatment employed in Prof. Lebedeff's clinic in six cases of complete rupture. The recto-vaginal septum was first split as in performing a flap operation, and then after extending the wound sufficiently up onto the vulva the ends of the sphincter were caught and united with an interrupted suture, after which the major part of the wound was closed with a continuous cat-gut suture, and the closure was completed with four deep and two superficial sutures.\*

In an article by Leopold and Wehle †, a method of uniting the sphincter is described by which two or three sutures are passed through the skin close to the sphincter, brought out in the sphincter pit and re-entered on the sphincter on the opposite side to reappear on the skin surface at a point corresponding to the point of entrance. By this means the sphincter ends are approximated with far greater accuracy and with a degree

---

\* See reference in Frommel's Jahresbericht, Vol. 7, p. 202.

† Geburtsh. u. Gynaek., Bd. 2, Leipzig, 1895, p. 307.

of certainty unknown in the old operation; this is practically the same method I have been practising myself for a number of years past.

Dr. George E. Shoemaker, in a personal letter received January 14th, 1899, states that he operated upon a tear of the sphincter ani muscle in June, 1893, which was referred to briefly in the *Medical News* of September 22d, 1894. Two previous operations, both unsuccessful, had been performed on the patient for the same trouble which had originated in 1891. Dr. Shoemaker's operation was begun by making a curved incision from over one sphincter end across to the other. The sphincter muscle ends were then dissected out and clearly defined, after which they were caught up by a strong cat-gut suture which included only the two sphincter ends. The rectal wall was closed in the usual way and the Emmet intra-vaginal denudation completed, two reinforcing worm-gut sutures being passed through the sphincter, each beginning far out on the skin at the side and ending at a point opposite.

The operation was entirely successful and the patient secured perfect control of the bowel.

Since this operation Dr. Shoemaker states that he has used this method repeatedly with entire satisfaction.

In a brief but suggestive paper Dr. R. G. LeConte\* describes the direct suture of the sphincter ends by means of a buried cat-gut suture passed after the fashion of a tendon suture; the sphincter ends are hooked up and drawn forward and freshened either by cutting off a small portion with the scissors or by fraying the ends well with a knife, as already advised by previous operators who have insisted on freshening the sphincter ends as essential to secure good union; two cat-gut sutures are then applied one on each side of the sphincter muscle, and two more on the opposite side; when the opposed sutures are tied the sphincter ends are approximated. Dr. J. M. Baldy skillfully carried out Dr. LeConte's suggestion with remarkable success upon a patient who had been twice previously operated upon with an unsuccessful result each time.

My own method of treating the sphincter is similar to those detailed, in so far as the muscle is united directly end to end by

---

\*Amer. Jour. of Obst., June, 1895.



means of buried interrupted cat-gut sutures, and I would prefer passing single sutures directly through the muscle to the use of tendon sutures, for the reason that the simple interrupted suture buries less foreign material, and it is therefore less liable to infection, lying as it does close under the skin.

The first essential point of difference between my own method and those of previous operators lies in a carefully conducted denudation, giving the sphincter a wider berth, so as to separate it from the skin surface, after all the parts have been brought into apposition, by a greater interval. This is done to make the burial of the cat-gut sutures a safer procedure.

The next important point is the dissection and liberation of the sphincter ends until one, or one and a half centimeters or even more are pulled out free on each side. This has not been proposed before. The ends are then cut off so as to remove the scar tissue and three interrupted cat-gut sutures passed through them so as to be ready to bring them snugly together at the proper time.

The rectal wound is then completely closed by a series of interrupted sutures passed close together so as to make it impossible for any minute particles of fecal matter to press between the stitches and cause an infection. This closure is carried down and over the anus onto the skin area, and then, only after this step is satisfactorily completed, are the sphincter ends brought together and the buried cat-gut stitches tied. Another point which I wish to urge, which differs from any previous proposition, is the passage of a silkworm-gut tension suture directly through the substance of the sphincter muscle half way between its outer and inner borders. The purpose of this suture is to take the tension off from the buried cat-gut sutures during the healing process. I prefer this to the Emmet tension suture which is passed well behind the sphincter ends on the skin surface, because my suture acts more directly and does not tend to make the anal orifice so small; it is therefore easier to secure earlier and regular defecation.

I have dwelt thus far upon the method of securing immediate union of the external sphincter muscle; it is my desire now in conclusion to insist upon the importance of paying equal attention to securing accurate approximation of the internal sphincter muscle. Indeed, if I would establish any comparison

between the two, I would attribute more importance to the accurate union of the internal sphincter than to that of the external. This must be effected in the following manner: One or two fingers are passed into the torn bowel and the thin septum is brought slightly forward, while with a knife or a pair of scissors the operator splits the septum on its mucous margin and then dissects upwards and inwards, separating the vagina and its columna from the septum in such a way as to isolate the rectum in front and on the sides. By taking a little care and observing the tissues closely, the bowel with the muscle is easily set free, and if the dissection is well done the internal sphincter fibres will be clearly recognized on both sides.

After all the scar tissue is removed the internal sphincter is then united by a series of interrupted fine silk sutures entering and emerging on the mucous surface of the bowel about a millimeter from the edge of the cut. These sutures are passed and tied from above downwards from one and a half to two mm. apart; in a case recently operated upon I used as many as sixteen of them before the bowel was closed down beyond the external sphincter.

I believe it is best to reinforce these rectal sutures by two or three cat-gut sutures buried in the septum above them and grasping the muscular coat of the bowel, that is to say, the internal sphincter, and drawing it together over the line of union established by the first set. After doing this the external sphincter is brought together as described above, and the remaining perineal and vaginal portions of the wound united as described in the text-books. The utmost care must be taken throughout not to leave any dead spaces in the septum or about the buried sutures.

After such an operation it is my practice to open the bowels at least every other day by giving a warm oil injection through a soft catheter.

NOTE.—I have received a communication from Dr. J. M. Baldy, of Philadelphia, under date February 9, 1899, in which he refers in detail to his own practice of suturing the sphincter muscle directly in the following language:

“As to the method I am using, at first I made a partial ligation of both ends of the muscle, after dissecting them out and freeing them for a quarter of an inch from all attach-



ments. After securing the muscles with catgut the balance of the operation was performed like Emmet's. I found in several cases that the ends of the muscle sloughed—one case resulted in a cure, another did not, and I had to do it over. Consequently I changed the method to a simple suture of the ends as I would suture the ends of anything else, ligating as it were only one side, so as to give more security in holding the ends together, and at the same time save the chance of cutting of the muscle circulation and producing a slough. Then I finish as an Emmet, passing the lower sutures (silkworm-gut) through the sphincter far below the points of union so as to take off all tension from the catgut in the muscles.

When I get a very tight sphincter (or anus) I slip a small subcutaneous knife into the tissue at the posterior margin of the anus and sever as many of the sphincter fibres posteriorly as it is necessary to allow me to stretch the anus sufficient to give a free opening—that is, enough to allow the easy passage of my thumb. I always stretch the torn sphincter before beginning any denudation or dissection whatever.

The patients have sure and absolute control before they leave the Hospital. It is a big improvement over the old methods.”





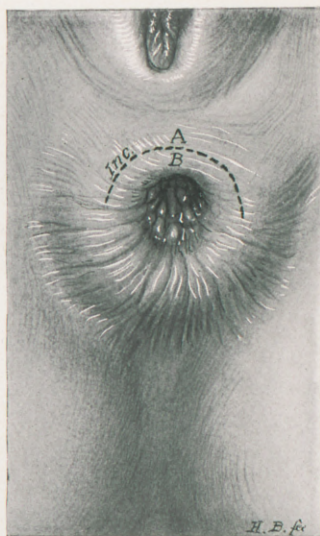

FIG. 1.—Showing the natural appearance of orifice after six attempts to restore the sphincter and secure control over the bowel function. The dotted line shows where the incision was made to expose the sphincter ends. A and B are pulled apart as shown in the next figure.

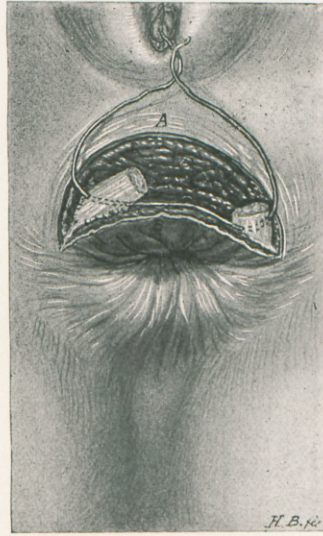


FIG. 2.—Shows the sphincter ends as they were found on pulling flap A up and flap B down. The right end lay near the median line and the left displaced attached close to the tuberosity of the ischium. One of the catgut sutures in place ready to bring sphincter ends together.



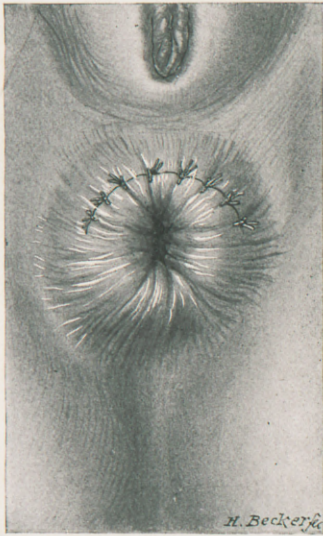


FIG. 3.—Appearance after the union of the sphincter ends and the closure of the skin wound, with interrupted silk sutures.

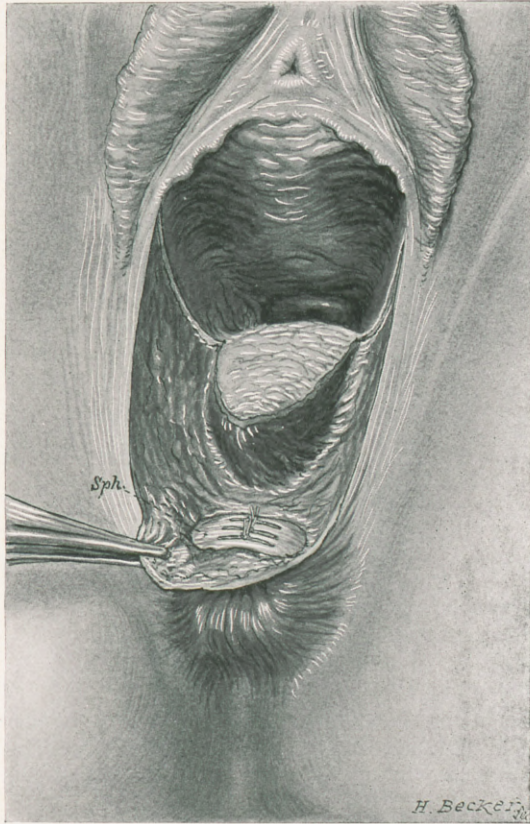


FIG. 4.—Showing skin flap held down and sphincter ends united by 3 interrupted catgut sutures. This was a case of deep injury of the sphincter without tear of the skin over the anus and without a tear into the lumen of the bowel.



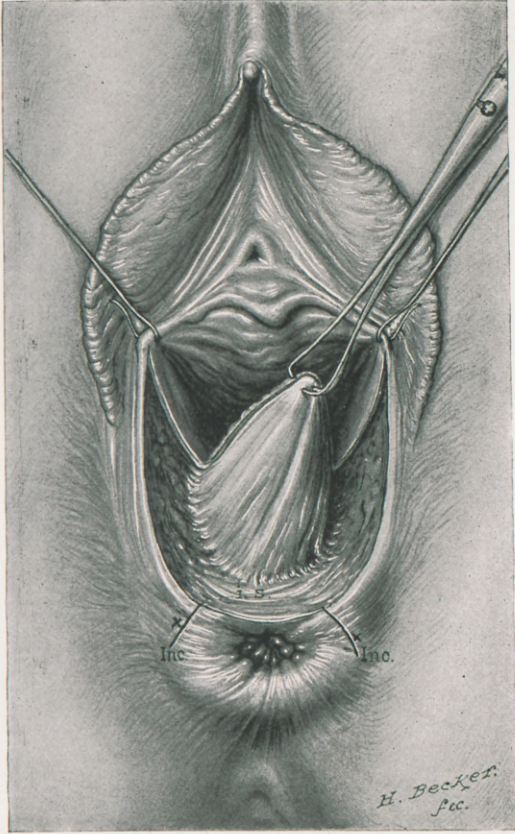


FIG. 5.—The denudation on vaginal and perineal surfaces. The tongue of tissue in the middle lifted up and dissected loose from the internal sphincter (i. s.). The denudation does not, however, expose the external sphincter, which is in this case laid bare by the two incisions (Inc) parallel to the anal orifice.

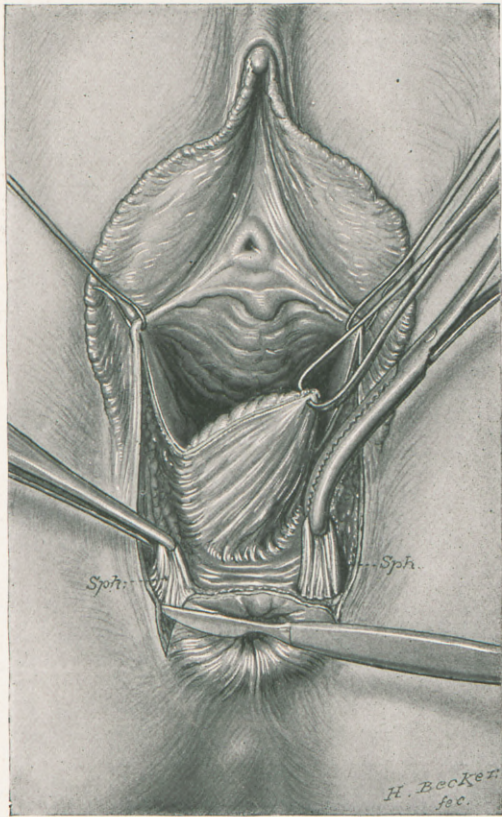


FIG. 6.—The incisions made as shown in Fig. 5 and the sphincter ends bared by dissection.



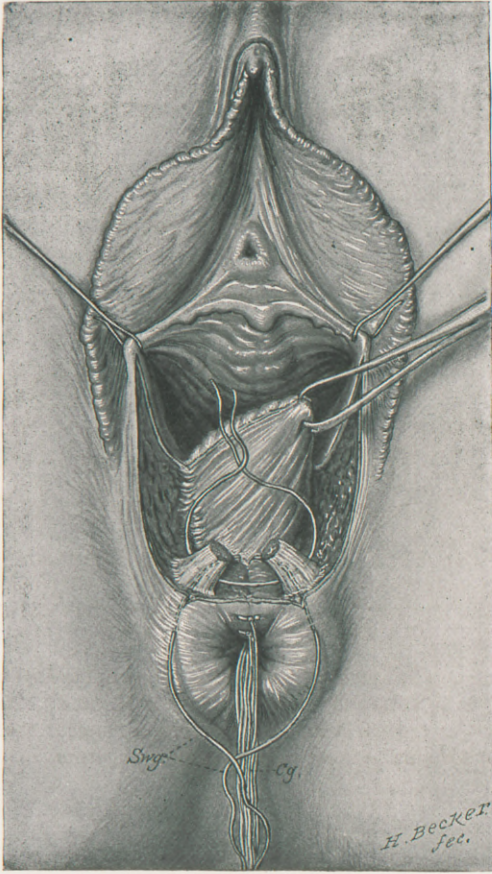


FIG. 7.—Denudation completed and rectal sutures tied, uniting the internal sphincter and radiating out into the skin surface.

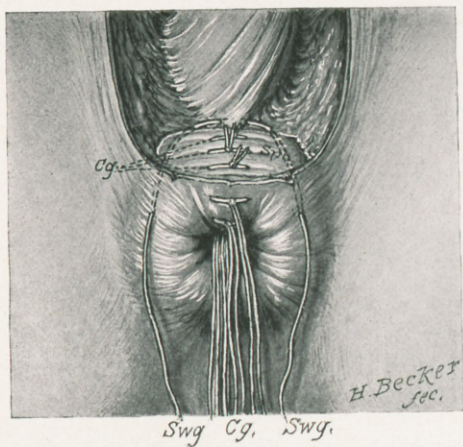


FIG. 8.—The rectal sutures all in place and the sphincter (Sp) ends united by 3 buried catgut sutures. A silk-worm-gut tension suture passes through the centre of the sphincter muscle up around through the septum.





