

EDEBOHLS' (G. M.)

*With Compliments of the Author.*

Inversion of the Vermiform  
Appendix.

BY

GEORGE M. EDEBOHLS, A. M., M. D.

Professor of Diseases of Women, New York Post Graduate  
Medical School;  
Gynecologist, St. Francis Hospital;  
Consulting Gynecologist, St. John's Hospital.

—  
REPRINTED FROM THE

AMERICAN JOURNAL OF THE MEDICAL SCIENCES.

June, 1895.







## INVERSION OF THE VERMIFORM APPENDIX.<sup>1</sup>

BY GEORGE M. EDEBOHLS, A.M., M.D.,

PROFESSOR OF DISEASES OF WOMEN, NEW YORK POST-GRADUATE MEDICAL SCHOOL; GYNECOLOGIST,  
ST. FRANCIS' HOSPITAL; CONSULTING GYNECOLOGIST, ST. JOHN'S HOSPITAL.

The two methods at present in vogue of dealing with the stump in the operation for appendicitis are far from being surgically ideal and perfect.

In the first of these methods the appendix is simply ligated at or near its base, and cut away on the distal side of the ligature. Whether all the coats of the appendix, or the muscular and mucous, or the mucous alone, be included in the ligature, the resulting stump contains mucous membrane until recently within the lumen of the intestinal canal, now suddenly transplanted into the peritoneal cavity. In no other operation of which the writer has knowledge is this condition intentionally brought about. To minimize the obvious danger of infective peritonitis, the stump of the appendix is treated in a variety of ways with a view to its disinfection, such as the actual cautery, the application of caustics and strong antiseptic solutions, etc. In whatsoever manner treated, however, the stump remains as an excrescence upon the peritoneal surface of the caput coli, with the chances of adhesion to neighboring coils of intestine, as well as the other undesirable possibilities pertaining to all stumps left within the peritoneal cavity. A case where septic peritonitis and death followed slipping of the ligature applied in this way is known to the writer.

FIG. 1.

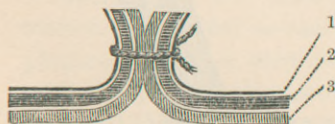


FIG. 1.—Simple ligation of appendix; stump free in peritoneal cavity. 1, peritoneum; 2, muscularis; 3, mucosa.

FIG. 2.

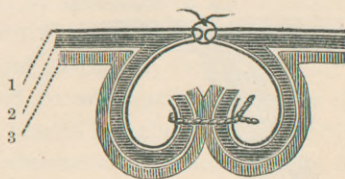


FIG. 2.—Ligation of appendix with depression of stump; stump bottled in a recess of peritoneal cavity. 1, peritoneum; 2, muscularis; 3, mucosa.

The second method attempts to overcome the disadvantages of leaving a pedicle free in the peritoneal cavity by depressing the

<sup>1</sup>Read before the Medical Society of the State of New York, February 5, 1895.

ligated stump of the appendix and covering it over by appropriate suture of the contiguous peritoneum. This second method, although superior to the first, also has its evident drawbacks. That part of the depressed stump on the distal side of the ligature, which is simply bottled up in an artificial recess of the peritoneal cavity, is liable to necrosis, with secondary infection of the peritoneal sutures covering it in, and possible further extension of the infection. The danger remains the same when the peritoneum has been stripped back before ligating and sinking the stump.

To get rid of the drawbacks and dangers attending ligation of the appendix, with its resultant stump, the writer has devised and practised inversion of the appendix. The idea and practice are, as far as he knows, original with him. In view of the apparent simplicity of the conception, however, he should not be greatly surprised to learn that he had but furnished an additional illustration of the truth of the adage "nothing new under the sun."

The term inversion of the appendix sufficiently explains itself. It consists in inverting into the lumen of the large intestine either the entire appendix, or any part thereof remaining attached to the caput coli; so that the appendix, or what remains of it, instead of being free in the peritoneal cavity, is now free within the lumen of the bowel. The mucous lining of the appendix thus inverted becomes its external coat, and its former serous covering lines the new lumen, along the whole extent of which it lies in contact with itself. The mouth of the inverted appendix, on the peritoneal aspect of the caput coli, is closed by suture to prevent reinversion of the inverted appendix.

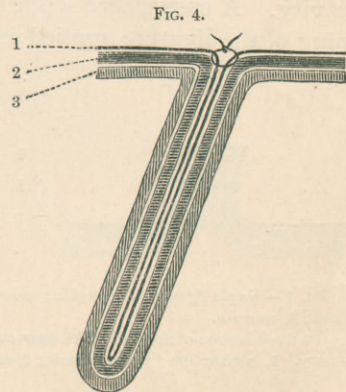
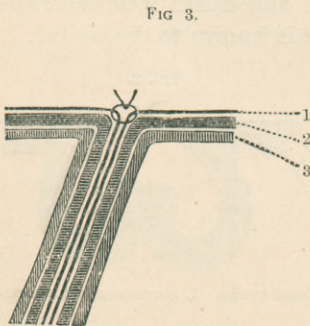


FIG. 3.—Inversion of stump of appendix, *without ligation*; peritoneal mouth closed by suture. 1 peritoneum; 2, muscularis; 3, mucosa.

FIG. 4.—Inversion of entire appendix; peritoneal mouth closed by suture. 1, peritoneum; 2, muscularis; 3, mucosa.



Inversion of the appendix not only excludes ligation of the appendix, but becomes the rival of the latter in every case in which the ligature can be legitimately applied. It merely becomes a question, in a given case, whether the whole appendix, or only the stump left after amputation of a greater or less part of its distal portion, shall be inverted.

In some cases of acute gangrenous appendicitis, where the gangrene affects the very root of the appendix and often even contiguous portions of the walls of the caput coli, neither ligation nor inversion of the appendix is applicable. Whenever the disease, however, has spared the vitality of a greater or less portion of the appendix next to the caput coli—and this occurs in the great majority of cases of acute appendicitis—then inversion of the stump without ligation is practicable, with one possible exception only. That is in cases in which it may be difficult to sew the mouth of the inverted appendix *in situ*, and in which it is at the same time unwise to disturb the relation of the parts so as to render the origin of the appendix more accessible. Under such conditions simple ligation may be preferable.

In chronic appendicitis inversion of either the whole appendix or of the stump of the appendix is practicable in all cases in which ligation with or without depression of the stump has heretofore been employed. If the whole appendix be pretty uniformly thickened, the entire organ should be inverted without opening its lumen at any point. If unequal thickening, or stricture of the appendix with distention of the distal end, should prove a mechanical obstacle to inversion of the entire appendix, then the stump left after amputation of the distal end should be inverted *without ligation*. The fecal fistulæ following operations for chronic appendicitis, in which ligation of the appendix has been practised, might have been averted by inversion of the appendix.

Inversion of the normal appendix is so simple and easy a matter, and withal in itself so devoid of danger, that the writer is prepared to go a step farther and to advocate inversion of the normal appendix whenever for any reason the abdomen is opened, provided the site or length of the abdominal incision renders the appendix easily accessible. There are those among our best surgeons who, under the conditions just stated, advocate ligation and removal of the normal appendix. How much more does their logic apply to inversion of the entire appendix as contrasted with ligation and ablation. Inversion of the normal appendix requires less than five minutes for its performance, and is absolutely free from risk, the appendix not being opened, and no choked-off



stump containing dangerous mucous membrane being left in contact with the peritoneum.

The technique of inversion of the appendix, though apparently a simple matter, may profitably occupy our attention for a moment. The writer first attempted inversion of the appendix a year ago, and succeeded at the first trial in inverting, without previous ligation, the proximal half of the appendix after amputation of the distal half. This was in a case of chronic appendicitis. In his next two cases of chronic appendicitis he attempted to invert the entire appendix, and failed. Recourse was now had to the cadaver and the following technique elaborated. By means of it the writer has succeeded in easily inverting, *without ligation*, two stumps left after amputation of the distal part of the appendix—once in a case of acute and once in a case of chronic appendicitis. In the latter amputation was called for, because the distal half of the inflamed appendix was too thick to pass through the lumen of the inverted proximal half. Inversion of the entire appendix he has performed six times. One normal appendix was inverted entire on the occasion of a celiotomy undertaken for the total extirpation of a fibromatous uterus. The remaining five were cases of chronic appendicitis associated with movable right kidney, the frequency of which association the writer believes he was the first to call attention to. ("Notes on Movable Kidney and Nephrorrhaphy," *Amer. Journ. of Obstet.*, February, 1895.)

Inversion of the entire appendix is practised as follows: After freeing and lifting the appendix, the meso-appendix is tied with catgut close to the base of the appendix. The meso-appendix is then separated from the appendix in the line of connection of the two, it being undesirable to invert any fat with the appendix. The excess of meso-appendix beyond the ligature is cut away, and the appendix cleanly freed from all surrounding tissues down to its origin from the cæcum. A strand of fine silk or chromicised catgut is next passed through the peritoneal investment of the caput coli, either above or below, and as close as possible to the point of the origin of the appendix. This strand is used to close the peritoneal mouth, after inversion of the appendix, by a running Lembert suture. Or, the strand of fine silk or catgut may be passed subperitoneally around the base of the appendix and be tightened, after inversion of the appendix, as a purse-string suture. The author has employed both methods and both suture-materials, and prefers the Lembert suture of chromicised catgut, No. 0 or 00.

The strand thus inserted becomes the landmark in inversion of



the appendix. The assistant gently grasps the caput coli with the index-finger and thumb of either hand just above and below the origin of the appendix. The hole through which the appendix is to be inverted thus comes to lie between the fingers and thumbs of the assistant. The operator seizes the appendix near its base with thumb-forceps and inverts first the proximal part of the appendix. The portion inverted is held in by a finger of the other hand, or by a second forceps, while the first forceps grasps anew another portion of the appendix and pushes it in after the first, and so on till the tip of the appendix is pushed inside of the peritoneal mouth. The assistant is now relieved from further duty. The operator grasps the lips of the opening through which the appendix has disappeared with the forefinger and thumb of one hand. With the fingers of the other hand he feels for and grasps the now half-inverted appendix through the coats of the caput coli. Appropriate manipulation of the semi-inverted appendix, consisting chiefly of gentle stripping or milking of the appendix in a direction from its origin towards its free end, will soon convert the semi-inversion into complete inversion. The exact moment of accomplishment of the latter is readily recognized by the fingers. Closure of the peritoneal mouth by a few Lembert stitches completes the little operation, which can be done in less time than is required to describe it. That further experience will lead to improvement in the above technique is probable; closure of the peritoneal mouth by suture to prevent reinversion can *possibly* be dispensed with after inversion of the *entire* appendix.

When the stump of an appendix is to be inverted the portion it is desired to remove is first amputated. The open mouth of the appendix is closed by an appropriate clamp-forceps. With the aid of the latter the appendix is then inverted, the forceps withdrawn, and the peritoneal mouth closed by Lembert suture. The suturing should, for evident reasons, be more carefully performed when the opened appendix has been inverted than when the appendix has been invaginated *entire* and *uncut*.

The bowels may be moved after inversion of the *entire* appendix at the pleasure of the individual operator.

What becomes of the inverted appendix? The writer freely confesses to a feeling of indifference as to its fate. Whether it maintains its organization, or sloughs and passes off with the feces, the inverted appendix is for its wearer no longer a source of danger. The danger from an appendix lies in the fact that it contains a mucous membrane, or a mass of lymphoid tissue, sub-

ject to inflammation and practically unlimited swelling, inside a firm, unyielding, muscular, fibrous and peritoneal coat. These conditions are changed as soon as the appendix is turned inside out and the mucous coat becomes the external layer. Theoretically it should slough, in part at least, as its chief blood-supply is cut off when the meso-appendix is ligated.

In conclusion the writer would respectfully submit the following propositions :

1. Inversion of the stump of the appendix should be substituted for ligation in all cases of acute appendicitis in which it can be applied.

2. In chronic appendicitis either the entire appendix or its stump should be inverted, preference being given to inversion of the uncut appendix whenever practicable.

3. In all cœliotomies undertaken for the relief of conditions other than appendicitis the normal appendix, if readily and safely accessible, should be inverted entire.

NOTE.—In April, 1895, over two months after the above paper was read, and while the manuscript was in the hands of the publisher, Dr. R. H. M. Dawbarn read a paper before the New York Surgical Society on the subject of appendicitis. In this paper he described *inversion of the stump of the appendix*; exactly the procedure advocated above, although Dr. Dawbarn's technique varies somewhat from my own. Correspondence with Dr. Dawbarn has elicited the fact that he first performed inversion of the stump of the appendix in April, 1891, As my own first case bears date of January 30, 1894, priority in *inversion of the stump of the appendix* clearly belongs to Dawbarn. Neither Dr. Dawbarn nor myself knew of each other's work in this direction until the reading of Dr. Dawbarn's paper, and the discussion thereon, brought out the foregoing facts.

In his letter to me, Dr. Dawbarn writes: "I can see no sense in ligating the stump-end at all, if it is going to be inverted, any more than I should think of tying a string around a wound in a gut before inverting its edges and using Lembert sutures. The analogy is perfect."

As to *inversion of the entire, uncut appendix*, Dr. Dawbarn, whose researches into the literature of the subject have been much more extensive than my own unhesitatingly ascribes to me priority. He himself has never performed inversion of the entire appendix, nor has he found any mention of the matter in medical literature.

59 WEST 49th STREET.