


HEKTOEN (L.)

Compliments of *al*
L. Hektoen.

THE VASCULAR CHANGES OF
TUBERCULOUS MENINGITIS, ESPECIALLY
THE TUBERCULOUS ENDARTERITIS

BY
LUDVIG HEKTOEN



FROM
THE JOURNAL OF EXPERIMENTAL MEDICINE
Vol. I, No. 1, 1896

THE VASCULAR CHANGES OF TUBERCULOUS MENINGITIS, ESPECIALLY THE TUBERCULOUS ENDARTERITIS.

By LUDVIG HEKTOEN, M. D.,
CHICAGO.

PLATE VIII.

(From Prof. Chiari's Pathological Institute in Prague.)

THE pathogenesis of tuberculous meningitis presents many questions of interest.

The favourite point of localization of the specific granulations of this frequent and intense process about the arteries, especially the Sylvian; the manner of primary invasion of the bacilli and of their secondary diffusion; the presence or absence of a mixed infection—these are some of the interesting problems that merit consideration.

In this article it is proposed to study somewhat in detail the histogenetic vascular changes in the leptomeninx in tuberculous inflammation, on account of their interest from the purely histological aspect and also of their possible significance as regards the mode of infection.

First it will be advisable to consider in general the various routes by which the infection may take place in tuberculous meningitis. Then it will be in order to introduce the more important statements in the literature concerning the arterial changes in the disease in question and their relation to the mode of infection. Upon this basis will be developed the results obtained by the bacteriological and histological examination of a number of instances of tuberculous meningitis, and also from certain, as yet unfinished, animal experiments.

The development of our knowledge concerning tuberculous meningitis is, naturally, very closely connected with that of tuberculosis in general.



The descriptions by Coindet* and Papavoine of the minute nodules characteristic of the tuberculous form of meningitis called attention forcibly to the question of the genesis of these peculiar elements. In the course of years the opinion gradually formed that the miliary granulations stood in some relation to the caseous masses nearly always found somewhere in the body of those dead from "water on the brain." Often tuberculous meningitis was, so to speak, only a part of a general miliary tuberculosis which Buhl, in 1872, characterized as an infectious and resorption disease, the miliary nodules bearing the same relation to the caseous foci as the metastatic abscesses of pyæmia to the primary pus focus.

Taking the accumulated facts into consideration, and especially the constant distribution of the tubercles along the pial vessels, the occasional limitation of the process to one definite arterial territory, together with the well-nigh constant presence of caseous masses somewhere in the body, Huguenin, writing in 1878, found the conclusion warranted that tuberculous meningitis usually originated from embolism by way of the blood of an unknown agent contained in, and most likely the cause of, the older tubercular lesions. This conclusion received material support by his finding perforation of a softened caseous focus into a pulmonary vein in an instance of general miliary tuberculosis with tuberculous meningitis.

Koch's discovery of the tubercle bacillus, and Weigert's conclusive anatomical demonstration of the routes of entrance from local areas of tubercle, subsequently furnished the direct and positive proof of what was generally believed to be the case from the circumstantial evidence mentioned.

The consideration of the mode of entrance of the tubercle bacillus in the meninges and the relation of tuberculous meningitis to tubercle elsewhere have, as already indicated, received much attention, and a large number of observations bearing on this point may be found in the clinical and statistical studies of Seitz, Hensch, Demme, Müller, Wortmann, Rieder, Medin, Reinhold, Northrup,

* The references to the literature are arranged at the end of the article and in alphabetical order, according to the names of the authors.

Klöttsch, Neumann, Simon, and others. Suffice it to say that it is the general belief that in nearly all instances of tuberculous meningitis the invasion occurs by way of the blood, which may become infected, as shown by Weigert and others, from local tuberculosis, either directly from extension to the walls of veins or of large arteries, or indirectly through the lymph stream.

Often tuberculous meningitis is a terminal event in cases of extensive infection with the formation of multiple, chronic, and caseous foci and the diffuse eruption of miliary granulations in various organs, so that while it is perhaps no longer possible to trace any exact sequence of events, yet there can be no doubt of the originally hæmatogenous nature of the general infection. But many cases also occur in which the meningeal infection develops in connection with local circumscribed, often latent, foci in the lymph glands, the lungs, the pleura, the bones and joints, the skin, etc., and in these instances the blood is also held as the carrier of the bacilli, although a few authors attribute this rôle to the lymphatics in certain special cases. Babes thinks that when the peribronchial or retropharyngeal glands are especially involved, then the bacilli may reach the brain by retrograde transport in and along the lymphatics.* Hübbsen assumes the same route in one case of tuberculous meningitis occurring in connection with primary tuberculosis of the peribronchial lymph glands. Demme has an example of a probable lymphogenic pial infection from tuberculous rhinitis.†

Acute tuberculous meningitis following old foci in the brain, the spinal cord, and the skull or spinal column, is, of course, most likely due to a direct infection of the lymph spaces of the internal meninges. The inflammation, commencing in the vicinity of the point of origin, may become diffuse by dissemination of the bacilli through the cerebro-spinal lymph vessels (Ziegler); in addition a local dissemination through the arteries might also occur.

Concerning the occasional instances of so-called "spontaneous"

* The plexus jugularis profundus runs along the deeper vessels in the neck to the base of the brain, where it receives lymph from the cranial cavity.—Gegenbaur.

† The subarachnoid space communicates with the mucous membrane of the nose.—Stöhr.

or "primary" tuberculous meningitis, it can confidently be said that but very rarely, if at all, has the anatomical investigation been thorough enough to exclude all the primary hidden foci that may have been present as the origin of a hæmatogenous invasion. And yet the possibility of a primary meningeal tuberculosis (without the presence of an old focus) can not be denied. The demonstration by Straus of virulent tubercle bacilli in the nose of nine seemingly healthy persons out of twenty-seven examined, certainly warrants the suggestion that in some way tubercle bacilli might, under exceptional circumstances, such as after trauma (Demme, Coats*), be imported into the subarachnoid space, and thus cause a leptomeningitis in the same manner as appears to be the origin of many cases of non-metastatic cerebro-spinal meningitis.

Perhaps tubercle bacilli might also enter the pia from the middle ear, in which Kossel found them in a nursling.

Under all circumstances, the hæmatogenous origin of tuberculous meningitis (which is not the result of direct infection of the lymph vessels from chronic foci in the nervous system) must be regarded as the general rule, and all other possible modes of infection as exceptions of uncommon occurrence.

In accordance with the etiological considerations referred to in the preceding pages, the distribution of the tubercles along and upon the vessels in tuberculous meningitis is usually spoken of as a matter of course, as the direct result of the import of the bacilli by the blood; but, as may be seen from the usual descriptions of the morbid anatomy of this process, it can not be said that the exact relations of the vascular changes to the primary localization of the bacilli is very clearly understood. Indeed, it will very soon become clear that, notwithstanding significant isolated observations and also important special studies, such as those from Rindfleisch, Cornil, Guarnieri, and others, yet the changes in the arteries, as well as in

* Coats, in an instance of tuberculous meningitis developing after trauma, found tubercles in an organized dural clot. There were no tubercles in any other part of the body. The route of the infection is not discussed.

the veins, in tuberculous meningitis have in reality not been systematically studied in all their bearings.

It is well to begin the review of the literature concerning the arterial changes in tuberculous meningitis with one or two citations about arterial tuberculosis in general.

Orth states that until recently it was thought that the media and the intima were so immune from tuberculosis that they were never attacked either primarily or secondarily, but that newer investigations show that the intima may proliferate and form giant cells as well as tubercles independently of adventitial changes.

Ziegler teaches that tuberculous arteritis may come from infection by the blood, and that in tuberculous organs the arterial walls may be invaded by bacilli, giving rise to tubercle or to more diffuse inflammation and proliferation resulting in thickening of the wall that may end in caseation with thrombosis or rupture.

Among the first to study closely the histology of the miliary tubercles in the pia was Rindfleisch, who found the larger arteries the seat of a unilateral swelling, while the smaller presented spindle-shaped thickenings, all of which he believed were due to changes that originated in the adventitia.

Virchow writes that, generally speaking, it is easy to convince oneself that not the vessels, but the ground substance forms the matrix for the tubercles in the adventitia of smaller pial arteries.

Huguenin calls particular attention to his having observed that the miliary tubercles in tuberculous meningitis develop not only outside the blood vessels, but also from the endothelial lining of their interior, and that tubercles may perforate the vessel wall from within as well as from without.

Danforth, in 1878, concludes that the lesions peculiar to tuberculous meningitis are confined to the smaller blood vessels of the pia, and that they are always exterior to the tunica interna, and therefore have no structural relation to the circulating blood.

Lancereaux says the miliary granulations take birth in the lymphatic sheath of the blood vessels, most frequently at the

point of bifurcation, being produced by multiplication of the nuclei and the cells which enter into the composition of the adventitia.

Baumgarten agrees with Brodowski, Cornil, and Kiener that occasionally the endothelium may proliferate in tuberculosis of the arteries of the pia mater, but this is usually not extensive, and in fact an exception rather than a rule.

Arnold observes that he has found tubercles in the intima of larger vessels, and cites the similar observations of Ponfick in regard to the thoracic duct, of Weigert as to the pulmonary veins, and of Cornil in connection with the vessels of the pia, but concludes that it is impossible at the time of his writing to determine whether any of these vascular changes bear any relation to the spread of the tuberculous process or not.

Guarnieri studied the histological changes in twelve cases of tuberculous meningitis. Besides adventitial changes, the exudate, infiltration into nerves, and a hyaline degeneration of the vessel walls, he also demonstrated quite constant changes in the media and in the intima. The intima presented semilunar or circular accumulations of round and epithelioid cells in a granular substance between the endothelium and the elastic lamina so that the lumen was more or less narrowed. He found no giant cells in this proliferation, and but few tubercle bacilli compared to the number outside the arteries. This endarteritis, present also in the spinal pia and in the interior of the brain, was always accompanied with an older periarteritis and mesarteritis, the muscle fibres disappearing from the infiltration of round and epithelioid cells which frequently formed accumulations outside of the elastic layer. Guarnieri regards the changes as going from without inward.

Cornil, in 1880, found not only the usual adventitial changes, but also special changes in the intima which he characterized as an endarteritic or endophlebitic tuberculosis. Between the endothelium and the media of the arteries was a series of layers of voluminous cells, flattened by mutual compression, and among them cells with two to four nuclei as well as veritable giant cells with fifteen to

twenty nuclei. There was no marked production of limited nodules, but rather a uniform proliferation.

Cornil and Ranvier reproduce this description with the appropriate drawings in their *Manuel d'Histologie* of 1881.

Cornil and Babes describe, in addition to the tuberculous endarteritis of Cornil, the presence of tubercle bacilli in the endarteritic granulations, in the thickened and caseous walls, and in the interior of thrombosed arteries and veins, and they give several figures illustrating these observations.

While Cornil and Babes lay much stress on the active part taken by the vessels in the histological changes, yet they do not emphasize the relation of such changes to the route by which the bacillus enters the leptomeninx. In another communication they express the opinion that the spread of the bacilli through the blood is proved by finding them in or near the vessels.

Huettenbrenner, in examining the brain of a boy who died from basilar meningitis, found, among other changes, a typical tubercle with giant cells and caseation in the intima of a basal artery. The tubercle was located between the endothelium and the media, there was no oblique perforation of the vessel, and Huettenbrenner regards this as a primary intimal tuberculosis from direct implantation of the bacilli.

Rindfleisch teaches (in the last edition of his text-book) that the secondary localization of the tubercle bacillus which leads to a disseminated or general miliary tuberculosis occurs upon the smaller vessels, and that the classical place for studying the resulting tuberculous vasculitis is the basal arterial system of the brain, especially the sheath of the Sylvian arteries, whose adventitia will show the miliary granulations. In these cases the internal coats become secondarily involved and infiltrated with tubercular proliferation. On cutting open such a vessel longitudinally, one finds, in place of the familiar folds in the intima and the transverse striation of the muscular fibres, a sharply circumscribed defect occupied by tuberculous granulation tissue.

Rindfleisch has repeatedly found places in which it appeared to

him as though the epithelioid cells originated from the muscular fibres and not from emigrated leucocytes, and he has a figure entitled "Muscular fibres which appear to be changing into tubercle cells." In other words, Rindfleisch regards the secondary localization of the bacilli as occurring in the adventitia of the vessels.

Birch-Hirschfeld states that the bacilli are assumed to reach the pia through embolism, and then to spread diffusely through the lymph spaces. The vessels certainly partake in the inflammation, but the changes consist rather in a diffuse cell infiltration than in the formation of tuberculous nodules.

Hirschberg studied three cases of tuberculous meningitis which presented focal symptoms before the appearance of the usual clinical manifestations. In two of these cases there was an endarteritis as well as an endophlebitis, with tubercle bacilli, giant cells, and caseation. The vascular process, older than that near by, is consequently regarded as the immediate source of the pial infection, the blood carrying the bacilli from the endarteritic focus. Hirschberg did not find any point at which the process had broken through the endothelial lining which covered the intimal proliferation; nevertheless, this must have occurred, because in one case the peripheral, smaller arteries, though quite normal, were filled with granulation cells instead of with blood.

The source of the endarteritic infection is not discussed, but it is evident that the bacilli did not penetrate the arterial wall from without inward, but must have come with the blood.*

Ziegler observes that tuberculous meningitis is usually metastatic, but it may originate from adjacent structures. The tubercles may

* Of a somewhat different origin is the endarteritis described by Weintraud in the case of a man with pulmonary and laryngeal phthisis, who was taken with sudden nervous symptoms pointing to a local brain disease, but after eight days a fatal tuberculous meningitis supervened.

Microscopically, the intima of the arteries in the older tuberculous meningeal foci was concentrically thickened on account of the accumulation of spindle- and star-shaped cells lying in a homogeneous and fibrillary ground substance. There were occasional giant cells with traces of degeneration, but no tubercle bacilli, no tubercles, and no distinct caseation in the intima.

Weintraud declines to consider the disease of the intima as the primary process from which the meningeal infection followed, but he regards the endarteritis as secondary to a

develop anywhere in the pia, but the vessel walls are often involved to a marked degree, so that the structure is no longer recognisable on account of the caseation and the thrombosis.

Hamilton writes that the tubercles lie in the trabeculæ of fibrous tissue between the pia and the arachnoid, and that a small artery is generally found embedded in their substance or lying at their side.

The actual facts, gathered from this review of the literature concerning the arterial changes in tuberculous meningitis and their relation to the commencement of the process, may be summarized as follows:

The general opinion seems to be that the bacilli, carried by the blood, are localized in the arterial adventitia. The resulting process may invade the media and the intima, and the whole or a part of the wall may become caseous (Rindfleisch, Ziegler, Birch-Hirschfeld, Lancereaux, Guarnieri).

An endarteritis is also described whose relation to the other changes may vary. Some regard it as secondary (Guarnieri and Baumgarten), either due to direct extension or induced indirectly and somewhat in the same manner as chronic perivascular processes, tubercular or otherwise, call forth an obliterating endarteritis, a typical example of which Weintraud describes in a tuberculous pia.

Others regard the endarteritis as primary (Huguenin, Huettenbrenner, Cornil, Hirschberg), as due to the direct implantation of tubercle bacilli from the blood (Cornil, Huettenbrenner), and as the immediate source of the general infection of the pia (Hirschberg).

Concerning the histological technic used in this study, it is necessary to say simply this: That the paraffin-embedded pieces were cut into perfect series of sections from 5 to 10 μ in thickness, and that

latent meningitis in circumscribed cortical districts and as identical in its nature with the endarteritis obliterans of Friedländer, which may result from chronic inflammatory changes in the neighbourhood of vessels. Weintraud cites Rindfleisch, Friedländer, Baumgarten, Cornil and Guarnieri as having observed this or a similar form of endarteritis accompanying tuberculosis in the pia as well as elsewhere.

According to Guarnieri, Marchiafava, in 1876, directed attention to an angiitis obliterans in chronic tuberculosis of the lungs, the brain, and the testicles.

the ordinary staining procedures were employed after affixing the sections to the slide with the water-albumin method.

In all cases the examination was directed especially to the arteries, particularly those in the Sylvian fissures.

The serial-section method presents obvious advantages that are indispensable in a study of this kind. Without perfect series of sections the relations of the arterial and the venous changes and of the extravascular and the intravascular changes to each other could not be clearly and perfectly understood in all the details.

CASE I.—From Prof. Ganghofner's Pædiatric Clinic: Boy, five years old.

Clinical Diagnosis.—Basilar meningitis (miliary tuberculosis?); diffuse bronchitis; tuberculosis of the left elbow joint and of the cervical lymphatic glands. Section twenty-four hours after death (April 11, 1895).

Anatomical Diagnosis.—Basal and spinal tuberculous meningitis; chronic tuberculosis of the right lung, of the peribronchial lymph glands, of the cerebellum, of the right zygoma, of the left elbow joint, of the cervical and mesenteric lymphatic glands; bilateral fibrinous pneumonia; decubitus.

The body is 103 centimetres long, very emaciated. In the sacral region a 4-centimetre-large bed sore; about the left elbow joint are several fistulous openings that lead to rough bone. Over the right zygomatic arch opens a sinus that also leads to dead bone. The neck is thin, the thorax flat, and the abdomen retracted.

The skull is 51 centimetres in horizontal circumference, the inner surface being slightly roughened and the sutures somewhat loose. The dura is tense. The pia over the base contains a light turbid fluid, and around the vessels of the Sylvian fissures are numerous gray miliary granulations; here the exudate is more gelatiniform. The same changes are found about the arteries of the corpus callosum. On the upper surface of the cerebellum the meshes also contain miliary and submiliary nodules. The convolutions are flattened, and all the ventricles are dilated with turbid serum. The ependyma of the lateral ventricles is almost confluent. The brain substance is soft and moist. Along the anterior margin of the left cerebellar hemisphere is a caseous nodule, one cubic centimetre in size, which substitutes part of the cerebellar cortex, and is connected with the pachymeninx.

The nasal cavities are normal; the lining is covered with yellowish mucus. The thymus and thyroid glands are of usual size. Many of the

cervical lymph glands are caseous. The right lung is universally adherent; the left is free. In the pleural adhesions over the right lung are numerous small caseous masses. The right lung is pale; in the lower part of the upper lobe is a cavity 2 centimetres in diameter, with caseous and fibrous walls; in the vicinity are caseous nodules. In both the lower lobes the parenchyma is hepatized without caseation. The heart is of normal size, the valves thin. The peribronchial glands are in part caseous.

The abdominal organs show no pathological changes, but the mesenteric glands are in part caseous.

The spinal pia is infiltrated with turbid serum, especially in the dorsal part, and contains many miliary nodules. The spinal cord is normal.

Bacteriological Examination.—Several cover-glass preparations of the meningeal exudate show no tubercle bacilli or other micro-organisms, and a glycerin-sugar-agar plate from the same exudate remained sterile after fifteen days in the incubator. Cover-glass preparations from the nose contain a large mixture of various bacteria, and among the numerous colonies on the plate cultures from the nasal muco-pus a staphylococcus staining with Gram's method seems the most prominent. In addition, cover glasses from the superior meatus on the left side contain a few tubercle bacilli.

Cover glasses from the pneumonic districts in the lungs show diplococci that take the Gram stain in rather small numbers.

Histological Examination.—The internal meninges present the usual changes, consisting of diffuse as well as more circumscribed cell infiltration, with comparatively many giant cells and occasional districts of caseation, and also much fibrinous exudate (Weigert's fibrin stain), all of which seems to be more marked at the base and in the beginning of the Sylvian fissures.

The caseation and the giant cells seem most pronounced in and around the adventitia of the smaller arteries, and quite frequently the infiltration and the caseation involve the entire media, either at only one point, or around the whole circumference of the vessel for a short distance longitudinally. In such instances there is usually more or less proliferation in the intima between the endothelium and the elastic lamina, but the latter usually remains intact. This invasion of the media with thickening of the intima is strongly

marked at the periphery of the older focus in the cerebellum. The accumulation of cells between the endothelial lining, which is well preserved, and the elastic layer usually consists of large epithelioid cells, with but occasional small lymphocytes and multinuclear leucocytes. Distinct tubercles and giant cells were not found upon the intima, and the changes in the external coats of the arteries usually seem older than those in the internal. Many of the smaller arteries are diffusely infiltrated and caseous, being, so to speak, directly transformed into tubercles. The main stem of the left Sylvian artery presents, at a point where it is free from adventitial changes, a nodular accumulation of lymphocytes and cells with multiform nuclei upon an intact intima.

The veins are frequently the seat of a marked infiltration which always seems to proceed from an artery or from changes in the neighbouring tissue; it is not unusual to find giant cells in the venous walls lying almost next to the blood stream. In one place a vein becomes the seat of two foci of circumscribed infiltration apparently by extension from a diffuse arteritis in two neighbouring arteries; the masses of granulation cells project into the lumen of the vein and become capped with thrombotic masses.

The internal meninges of the spinal cord show considerable exudation and infiltration which extends out into the nerve roots. In the arteries only the adventitia is usually involved, but the veins are often the seat of a diffuse proliferation with many giant cells; in some places the vein wall becomes very considerably thickened, and the lumen much narrowed. The walls of the minute arteries may be diffusely infiltrated. In addition to the giant cells—which are present in very large numbers and are remarkable for their size, the number of the so-called nuclei often reaching above one hundred, and the arrangement of the latter in the granular mass of the cell body forming at times a high wall at the periphery of the cell, at other times a heap in its centre or at one pole—three distinct kinds of cells are to be distinguished in the areas of proliferation: namely, small, round cells with comparatively large nuclei which stain deeply, and with a very small cell body (small lymphocytes);

and large cells of circular form, with relatively small nuclei and a finely granular, almost homogeneous cytoplasm (epithelioid cells—lymphatic cells, Metschnikoff); and, finally, cells with polymorphous or fragmented nuclei found wherever caseation is going on.

Tubercle Bacilli.—These are easily demonstrable in large numbers in the old focus in the cerebellum and in the adventitial proliferation in both the brain and the cord. In sections from the cortex of the central convolutions bacilli are also present in small numbers in the interior and in the wall of small arteries with inflammatory changes. Bacilli were also found in the media and in the interior of small arteries with changed walls in the spinal pia.

CASE II.—From Prof. Ganghofner's Pædiatric Clinic: Girl, seven and a half years old.

Clinical Diagnosis.—Tuberculous meningitis. Section eighteen hours after death (April 20, 1895).

Anatomical Diagnosis.—Tuberculous meningitis; chronic tuberculosis of the peribronchial lymphatic glands, of the brain, the thyroid gland, the lungs, the liver, the spleen, the kidneys, the stomach, and the intestines.

The body is 103 centimetres long, of feeble build, and greatly emaciated. The rigor mortis is slight. The hair is brown, the pupils equal, the neck thin, the thorax flat, and the abdomen retracted.

The skull is 48 centimetres in horizontal circumference; the sutures are somewhat loose. The dura is tense; the dural sinuses contain fluid and clotted blood. The pial vessels are full of blood; at the base, especially about the optic chiasm, is much turbid, serous fluid; along the vessels of the pia, both at the base and over the surface, are numerous miliary tubercles lying in fibrinous exudate. The brain substance is moist and soft, especially near the ventricles, which are much dilated with turbid fluid. Here and there the cortex of both hemispheres of the brain contain caseous nodules about the size of a pea, which are connected with the pia. The nasal mucous membrane is covered with thick yellow mucus.

The thymus gland is of usual size. The thyroid is rather large, and contains numerous areas of caseous infiltration.

The laryngeal and tracheal mucous membrane is covered with yellow mucus. Both lungs contain numerous yellowish-white nodules, some as large as a pea. In the peribronchial lymph glands are caseous and calcareous masses. The pericardium contains a tablespoonful of serum. The heart is of usual size, and its valves are thin. The liver contains numerous caseous nodules up to 0.5 centimetre in diameter, with softened, bile-

stained centres. The spleen is somewhat large, and contains caseous masses. The kidneys contain a few scattered miliary tubercles. The genital organs are normal. In the stomach are found occasional caseous nodules as large as a split pea, some of which present ulceration on the mucous surface. In the inferior ileum and in the cæcum are caseous nodules and also small ulcers. The pancreas and the adrenals are normal.

Bacteriological Examination.—The cover glasses from the meningeal exudate contain a few staphylococci and occasional tubercle bacilli.

Plate cultures show, after thirty-six hours, three pinhead-sized, grayish, round colonies of staphylococci that stain with Gram's method, present a thick, grayish-white growth on slanting agar, liquefy gelatin, and make bouillon turbid.

The cover glasses from the nose contain a mixture of various bacteria, staphylococci being present in large numbers. Tubercle bacilli are not found.

Plate cultures from the upper as well as from the lower meatus contain mostly staphylococci identical with that from the meningeal exudate.

Histological Examination.—In this case the changes are very intense, as marked by the dense cell infiltration and by the extensive degeneration. Giant cells are frequently present, especially in the peri-arterial and para-arterial foci and in the walls of veins. The inflammation in places involves the superficial layers of the brain cortex and extends also inward in the perivascular tissue of the intracerebral vessels. In many places the peri-arterial infiltration and caseation is accompanied by a hyaline degeneration of the media, whose inner layers, especially, then present a homogeneous, structureless appearance, the intima usually showing some subendothelial proliferation. The wall of the left Sylvian artery presents at one point a circumscribed infiltration, most marked in the adventitia and the outer layers of the media, but reaching the intima. Farther out in the Sylvian fissure there is quite a marked subendothelial proliferation in the large arteries with but slight if any changes in the media or the adventitia; the elastic layer remains intact, and there

are no tubercles or giant cells upon the intima. The arteries occasionally contain thrombi, in which may be accumulations consisting essentially of multinuclear leucocytes.

The smaller arteries are often diffusely involved and changed into small tubercles. Circumscribed and diffuse infiltration into the walls of large as well as small veins, with frequent giant cells, is everywhere seen (Plate VIII, Fig. 6). From the serial sections it is easy to trace the affection of the veins to invasion from the neighbourhood.

Tubercle bacilli are present in very large masses in the peri-arterial tuberculous infiltration; they are also found in smaller numbers in the walls of the smaller arteries.

CASE III.—From Prof. Ganghofner's Pædiatric Clinic: Girl, four and a half years old.

Clinical Diagnosis.—Tuberculous meningitis. Section fourteen hours after death (April 21, 1895).

Anatomical Diagnosis.—Basilar and spinal tuberculous meningitis; chronic tuberculosis of the peribronchial lymph glands, of the brain, and of the fourth and fifth lumbar vertebræ; miliary tuberculosis of the lungs, the liver, and the spleen; lobar pneumonia; multiple cartilaginous exostoses.

The body is 92 centimetres long, of feeble build, and much emaciated. The rigor mortis is slight. The hair is light, the neck thin, the thorax long, and the abdomen retracted. There are a large number of cartilaginous exostoses in the vicinity of the lines of ossification in nearly all parts of the body.

The skull measures 47·5 centimetres in its greatest horizontal circumference. It is thin, the inner surface is a little rough, and the frontal suture is persistent. The dura is somewhat tense. The pia is hyperæmic, and its meshes contain much thick exudate, especially at the base and in the beginning of the Sylvian fissures. Along the vessels, as well as elsewhere, are numerous miliary and submiliary nodules. The ventricles are dilated and filled with turbid serum. The brain substance is swollen and moist, the convolutions being greatly flattened. In the left cuneus and in the centre of the left first temporal convolution are caseous nodules, each the size of a pea. In both the cerebellar hemispheres are found several nodules up to 0·5 centimetre in diameter. In the pons above the left locus cæruleus is also a small nodule; in the same section there is a caseous mass 0·5 centimetre large in the ventral portion of the right half of the pons.

The mucous membrane of the nose, the pharynx, and the larynx is pale. The thyroid and thymus glands are of usual size. The lungs are hyperæmic and œdematous, and contain numerous miliary tubercles. The left lower lobe is hepatized. In the bronchi is considerable muco-pus. The peribronchial lymph glands are caseous. The heart is of usual size, the valves thin. The liver and the spleen contain miliary tubercles. The stomach, the intestines, and the genito-urinary organs are normal. In the left psoas muscle is a large abscess which occupies the entire extent of the muscle; in the fourth and fifth lumbar vertebræ are found areas of caries. The spinal pia is hyperæmic, infiltrated with serum, and here and there are miliary tubercles.

Bacteriological Examination.—Cover glasses from the meningeal exudate contain isolated tubercle bacilli. Plate cultures from the meningeal fluid remain sterile.

Tubercle bacilli are not found in the mucus from the nose.

Histological Examination.—In the Sylvian fissures the changes are very intense, the vessels being embedded in the diffuse infiltration and the dense fibrinous exudate. The media of the larger arteries is usually diffusely infiltrated, the lumen frequently thrombotic, and along the tunica elastica is a layer of various kinds of cells with detritus and nuclear fragments, the endothelium being absent. The perivascular infiltration is in process of degeneration, and this extends into the media and at times through the entire wall.

In other places there is a well-marked peri-arteritis and mes-arteritis with more or less hyaline degeneration in the media and with accumulations of leucocytes upon an intact endothelium.

The veins show, as usual, extensive tubercular infiltration into the walls; in one place a polypoid mass of granulation cells projects from the wall into the lumen; in another place the sections of a large vein present a circumscribed infiltration into the wall, which appears to be undergoing disintegration, so that the internal surface presents an appearance that might be referred to as a tuberculous ulcer. Giant cells are frequent in the walls of veins, rare in arteries.

Tubercle bacilli are found in large numbers in the more recent areas of proliferation. The character of the tissue is no sure indication as to the presence of tubercle bacilli, which are easily demon-

strable in large numbers in one place and difficult to find or absent in another, the histological appearances being the same in both.

In a small artery in the Sylvian fissure, which presents a circumscribed proliferation at one point, tubercle bacilli are found in the lumen of the vessel next to the intima. Tubercle bacilli are also present in the wall, and free in the lumen, of a small infiltrated vein of the pia over the central convolutions of the left side.

CASE IV.—From Prof. Ganghofner's Pædiatric Clinic: Girl, ten months old.

Clinical Diagnosis.—Tuberculous meningitis. Section eighteen hours after death (April 24, 1895).

Anatomical Diagnosis.—Basilar and spinal tuberculous meningitis; chronic tuberculosis of the peribronchial glands, the pericardium, the liver, the leptomeninx, the brain, and the cranium.

The body is 70 centimetres long, well nourished, with livid discolorations posteriorly. Rigor mortis present. The hair is blond, the pupils equal, the neck short, the thorax oval, and the abdomen slightly distended. The skull measures 42 centimetres in horizontal circumference; it is of usual thickness; the sutures are loose; the large fontanelle is 4 centimetres large. In the right inferior quadrant of the left temporal bone is an area, 2 centimetres square, in which the bone is infiltrated with caseous material which invades the periosteum and the pachymeninx. In the sinuses of the dura is fluid blood. The pia does not contain much blood; at the beginning of the Sylvian arteries and the arteries of the corpus callosum are several pea-sized nodules in the pia which extend into the cortex; in addition there is much serous and gelatiniform exudate, and also numerous miliary nodules along the vessels of the Sylvian fissures as well as elsewhere. The brain substance is pale, quite soft, especially around the dilated ventricles, where it is almost confluent. The fourth ventricle is also somewhat dilated. The lining of the nose is covered with thick mucus.

The trachea contains fluid from the stomach. The thymus and the thyroid are of normal size. The lungs are not adherent; slightly cedematous. The epicardium is thickened, and contains single and conglomerate caseous nodules as large as grains of wheat; at the upper part of the pericardium are adhesions between its two layers. The heart is of usual size, the valves thin, the muscle pale. The peribronchial lymph glands are enlarged and in part caseous.

The liver contains caseous nodules, as large as a pea, with softened centres. The spleen is of usual size. The kidneys are pale, the bladder

and genitalia normal. The mucous membrane of the stomach is softened in the pyloric region. The intestines are normal. The mesenteric glands are enlarged but not caseous. The spinal pia contains numerous small tubercles.

Bacteriological Examination.—Cover-glass preparations from the meningeal exudate do not contain tubercle bacilli or other bacteria, and plates with the same material remain sterile at the end of three weeks in the thermostat. No tubercle bacilli were found in the nose.

Histological Examination.—The larger arteries at the base, such as the Sylvian and the arteries of the corpus callosum, show the most intense involvement of the entire wall in infiltration and caseation, so that the structure of the arteries is no longer recognizable. The elastic layer seems to remain distinct the longest. This extensive affection of the wall is accompanied with similar violent changes in the neighbourhood. Upon the internal surface of the arteries occur frequent nodular accumulations of cells and detritus, covered with fibrin, but the degeneration is so advanced that one can not distinguish between possible miliary tubercles and parietal leucocytic masses.

At a point where the tuberculous process is not so intense the left Sylvian artery proper presents a small, sharply circumscribed perforation filled with granulation tissue, and the changes in the intima are certainly as old at this point as those in the adventitia. The walls of the adjacent smaller vessels usually show a total hyaline degeneration with thrombosis.

In the Sylvian fissures the changes are also very marked; the infiltration into the adventitia and the media is usually accompanied with endarteritis, the media remaining at times nearly normal, at times becoming homogeneous and hyaline. The subendothelial proliferation usually appears most marked at the points of bifurcation of the arteries.

In some places the entire segment of an artery may be totally necrotic. The veins present infiltration and caseation in the same high degree as the arteries. The meningeal process frequently involves the subjacent cortex.

The old foci in the pia and the subjacent cortex are marked by the presence of a very large number of large giant cells and by severe vascular changes.

In many places the spinal leptomeninx shows a sparse infiltration, especially of epithelioid cells, into the lymph spaces, the walls of the veins, and the arterial adventitia. The number of large giant cells is considerable; they sometimes lie in the venous wall next to the lumen. The giant cells here present an appearance as though they were formed by the arrangement of nuclei in a homogeneous or finely granular mass that sends prolongations in all directions out among the adjacent cells.

Tubercle bacilli are present in large masses in the wall of the Sylvian artery and in the arterial adventitia elsewhere.

CASE V.—From Prof. Ganghofner's Pædiatric Clinic: Girl, eight years old.

Clinical Diagnosis.—Broncho-pneumonia; miliary tuberculosis. Section nine hours after death (April 26, 1895).

Anatomical Diagnosis.—Chronic tuberculosis of the peribronchial lymphatic glands of the right pleura and lung; universal subacute tuberculosis; tuberculous meningitis; subcutaneous emphysema.

The body is 166 centimetres long, of slender build, and much emaciated. The hair is brown; the pupils equal. In the left supraclavicular fossa is subcutaneous emphysema that extends into the left axillary space; there is emphysema of less degree in the left supraclavicular fossa. The abdomen is somewhat retracted.

The skull measures 47 centimetres in its horizontal circumference. The dura is tense; its sinuses contain fluid and clotted blood. The pia over the forebrain is hyperæmic and oedematous; at the base, and especially along the arteries of the corpus callosum, are groups of millet-seed-sized and larger caseous nodules; here and there upon the convexities are occasional small yellowish masses around the vessels. The convolutions are flattened, the ventricles dilated with lightly turbid serum, the ependyma softened. The thymus contains many miliary nodules. The thymus is small.

The right lung is totally adherent to the chest wall, and in the adhesions are many miliary tubercles and caseous nodules; in the lung parenchyma are similar masses. The left lung is free, the cut surface displaying miliary nodules. The pericardium is adherent to the right visceral pleura, and contains a tablespoonful of clear serum. The heart is of normal size, the valves thin.

The peribronchial glands are enlarged and in part caseous. In the liver, the spleen, and the kidneys are many miliary tubercles. The stomach, the intestines, and the genital organs are normal.

Bacteriological and Histological Examination.—Cover-glass preparations from the meningeal exudate contain only tubercle bacilli, which are present in large numbers. The bacilli occur most frequently in the interior of large, roundish cells, at times singly, at times in groups of four, six, ten, or more. Occasionally a bacillus is found lying directly across or upon the nucleus of the cell, but usually the bacilli occupy the cell body.

These large cells are very numerous. They usually have but one nucleus, but cells with two or more nuclear bodies occur. Many such cells containing bacilli are necrotic; frequently the nucleus is split up into irregular fragments or replaced by round masses of varying size—karyolysis; detritus masses of the shape of disintegrated cells are seen, and among the remnants may lie tubercle bacilli.

Free tubercle bacilli, singly, but oftener in heaps or groups, are also found.

In addition to apparently well-preserved as well as disintegrating cells, the meningeal fluid contains chromatin masses of varying size and shape, and also leucocytes with polymorphous nuclei.

Glycerin-sugar-agar plates made with the meningeal fluid remain sterile. The nose could not be examined.

Serial sections through the smaller caseous masses in the pia over the convexity present the following appearances: Through the degenerated centre run one or two arteries whose adventitia and media are infiltrated and caseous, sometimes homogeneous and hyaline, the intima being the seat of a slight subendothelial proliferation, the lumen frequently thrombotic. Sometimes small hyaline masses occur in the intima. The arteries are surrounded on all sides by caseous material in which lie scattered fragments of nuclei and polynuclear leucocytes. The walls of the adjacent veins are invariably infiltrated; often the lumen is partially or wholly occluded by thrombotic masses whose interior present foci of leucocytic infiltration.

The process also involves the upper layers of the subjacent cortex. Toward the periphery of such a mass or tubercle the adventitia is more loosely infiltrated with large and small cells, the media usually quite normal, but the intima usually showing some subendothelial proliferation. Giant cells were not found in these areas; Weigert's fibrin stain demonstrates considerable fibrin in their peripheral parts. The neighbouring lymph spaces are loosely filled with epithelioid cells, much like those found in the meningeal exudate, and contain free and intracellular tubercle bacilli in large numbers.

Circumscribed, minute, tuberculous foci are also found in the interior of the brain without any demonstrable connection with the larger vessels.

The arteries of the corpus callosum and their branches present the following appearances: The lumen is more or less occluded with thrombotic masses that often contain large accumulations of leucocytes. The endothelial lining is either absent or the cells lie loose and disarranged. Frequently the internal wall presents nodular masses of cells, which penetrate the elastic layer and invade the media in a semicircular manner, the whole presenting a tubercle one half of which extends into the lumen, the other half into the wall of the artery; the centre of such masses is usually caseous, but in one or two instances distinct giant cells are present.

At one point the flattened artery is totally occluded by a large mass of cells and detritus in which lie several quite well-preserved, multinucleated giant cells; at the side of the mass that borders upon the main lumen of the artery lie several endothelial cells.

Around this intravascular process the arterial wall presents diffuse inflammatory and degenerative changes which at times render the structure indistinct. Corresponding to such foci in the arteries are diffuse and extensive changes in the surrounding tissues which invade the cortex, but the only giant cells found are those in the intravascular tubercles. The walls of the smaller vessels that are embedded in such masses are totally caseous or hyaline.

From older foci the process seems to extend along in the ad-

ventitia of the arteries, and at times a circumscribed invasion of the media may occur.

The sections removed from the series of these large arteries for the purpose of demonstrating the tubercle bacilli did not happen to include any extensive intravascular changes. Bacilli are present in enormous numbers in the wall of as well as outside the arteries. Frequently dense heaps or masses of bacilli are found that are recognisable as violet spots (Ehrlich's method) with a low power.

CASE VI.—From the Medical Clinic of Prof. Pribram: Man, aged forty-one.

Clinical Diagnosis.—Tuberculous meningitis; sero-fibrinous pleuritis; pulmonary emphysema; apical infiltration in the lungs; arterio-sclerosis; chronic alcoholism. Section twenty-four hours after death (May 17, 1895).

Anatomical Diagnosis.—Chronic tuberculosis of the lung apices; right tuberculous pleuritis; chronic tuberculosis of peribronchial lymph glands; universal miliary tuberculosis; basilar tuberculous meningitis; fibrous orchitis.

The body is 170 centimetres long, the bones are light, the muscles poorly developed, the panniculus adiposus slight. Diffuse posterior lividities. The hair is thick, brown; the pupils equal; the neck of medium length; the thorax rather flat, the right half larger than the left. The abdomen is prominent. The skull is thick, 56 centimetres in circumference. The dura is tense, the sinuses containing fluid blood. The vessels of the pia are filled with blood, the meshes are œdematous and infiltrated with clear serous exudate, and along and upon the vessels are numerous minute grayish-white nodules. The brain substance is moist, the ventricles somewhat distended with clear fluid.

The mucous membrane of the organs of the neck is normal but pale. The thyroid is apparently normal. The left lung is adherent; in its apex is an old scar. The right pleural cavity contains more than one litre of sero-fibrinous fluid, and both pleural layers are covered with fibrinous exudate and tubercles. The right lung is pale and compressed; in the apex is an old calcified cicatrix. In both lungs the bronchi contain mucus, the parenchyma being the seat of miliary tubercles. The pericardium contains a tablespoonful of fluid. The heart muscle is flabby and easily torn; the valves are thin; the aorta is smooth.

The œsophagus is normal. The peribronchial glands are large and caseous. The liver, the spleen, the kidneys, the pancreas, and the adrenals contain numerous miliary nodules. The testicles are hard, both layers of the

tunica vaginalis are adherent, and the parenchyma, especially in the right testis, is replaced by hard, white, fibrous tissue.

The stomach is dilated and contains many hæmorrhagic erosions; the ileum and the colon are normal.

Bacteriological Examination.—Cover-glass preparations from the meningeal exudate contain tubercle bacilli in small numbers. Other bacteria are not present.

Plate cultures from the exudate remain sterile after three weeks in the thermostat.

Serum and glycerin-agar tubes inoculated with a drop or two of the meningeal effusion develop slowly-growing cultures of tubercle bacilli. The nose could not be examined.

Histological Examination.—The tissues from this case presented astonishingly slight post-mortem changes, and proved an excellent material for the study of the vascular changes which involve the internal coats of the arteries to a remarkable degree.

More or less acute endarteritis is present in almost all the arteries, large as well as small. In the large arteries, such as the main stem of the Sylvian, the process is usually limited to one part or segment of the internal circumference of the vessel. In the medium-sized arteries the proliferation oftenest extends completely around the vessel, and the smaller arteries are frequently more or less completely occluded by the loosely arranged accumulation of cells in their interior. It is in the medium-sized arteries that the specific characters of the process are best studied.

The circumstance that the endothelium is unusually well preserved renders it easy to recognise that the proliferation is invariably subendothelial. It is only under the special circumstances to be mentioned that the endothelial lining is absent. When the cell proliferation completely fills the lumen of the vessel, then the endothelial lining will be found in the central part, at times disarranged and rolled together, at other times undisturbed.

The endarteritic proliferation is made up of cell layers of varying thickness. Large round or oval cells with comparatively rather small nuclei are the most numerous and predominating elements.

Smaller cells with large, deeply stained nuclei and cells with polymorphous or fragmented nuclei are also occasionally present. In some places one meets with cells containing three or four nuclei, as well as with multinucleated giant cells, and this outside of the more typical tubercles to be described (Plate VIII, Figs. 1 and 2).

Generally speaking, there is no very distinct intercellular substance; in some places a fibrinous and granular exudate is present in small quantity, especially in the deeper layers of the more advanced proliferation.

A well-preserved endothelium composed of a single row of typical endothelial cells limits the inflammatory proliferation on one side and the elastic layer (or the media) limits it on the other. There are absolutely no signs in the endothelium or disturbances of its arrangement which would indicate any active changes on its part. The nuclei of the endothelial cells are not swollen and present no appearances indicative of karyokinesis.

At times the elastic layer is invaded by cells, and an infiltration of variable degree takes place in the media and in the adventitia, but one can also examine large series of sections without finding any changes in the elastic tunic, the media, or the adventitia. Then again an unchanged media may intervene between the endarteritic and the familiar peri-arteritic infiltration. In the smaller arteries the elastic layer may be completely absent. Usually the arteries are not thrombotic.

At frequent intervals the more uniform and diffuse proliferation that has been described is intensified, as it were, by the formation of more or less distinctly nodular cell masses in which may be found giant cells and caseation. It is over such caseous intimal tubercles that the endothelium may be absent (Plate VIII, Fig. 4). The cells in such tubercles apply themselves firmly to the arterial wall and appear closely packed together. The multinucleated giant cells usually occur in the centre of the little nodules; round about are epithelioid and small cells, and, as caseation becomes marked, more polynuclear leucocytes appear.

Close study of the beginning of this subendothelial, intimal pro-

liferation shows that at first one or two cells appear in the intima here and there. A little later minute nodular accumulations of epithelioid cells have formed which lift the endothelium away from the intima, so that the endothelial lining presents a series of longitudinal folds corresponding to the subendothelial cell masses. The cells in such places present many evidences of proliferation in the shape of cells in the act of division, cells with two nuclei, and cells with more or less indistinct but nevertheless unmistakable karyokinetic nuclear figures.

Any other disarrangement of the endothelium in these places than the mechanical one described is usually not observed, and the elastic layer and the media are unchanged.

The elastic lamina underneath the tubercles may be quite intact, more or less infiltrated with cells, exudate and detritus, or entirely and sharply perforated as if a hole had been punched in it. Sometimes exudate may lift the ends of the perforated layer away from the media (Plate VIII, Fig. 4).

Corresponding to the tubercles, the media and the adventitia may be quite normal, or they may show infiltration and caseation of all grades of intensity.

Cell masses with as well as without giant cells or caseation may occur in the intima of arteries where there are no other changes, either intravascular or extravascular, but this is not common.

The walls of veins, large and small, show diffuse and circumscribed infiltration, but without giant cells.

The extravascular changes proper in this case consist of moderately extensive diffuse, as well as more circumscribed, infiltration, with but little caseation and no giant cells. These changes are usually better marked in the pia itself than in the arachnoidal layer.

There were no foci found in the interior of the brain substance.

Tubercle bacilli are found in very small numbers in the intimal tubercles; but in many sections through such masses, including the giant cell, the search for bacilli was entirely in vain. Many small, round, and rod-shaped intracellular granules were found that retained

the stain like the bacilli. In one place bacilli were found in the elastic layer, but occasional bacilli were found in the diffuse intimal proliferation.

Bacilli were also found in the infiltrated walls of veins, and, in larger numbers, in the peri-arterial infiltration.

CASE VII.—From the Psychiatric Division of Dr. Zastera: Woman, aged twenty-six.

Clinical Diagnosis.—Melancholia, intestinal and pulmonary tuberculosis. Section thirty-six hours after death (May 29, 1895).

Anatomical Diagnosis.—Tuberculous cerebro-spinal meningitis; chronic tuberculosis of the peribronchial lymph glands, of the lungs, the liver, the spleen, and the kidneys. Tuberculous pleuritis.

The body is 167 centimetres long and quite emaciated. Rigor mortis is present. The hair is light; the pupils equal and wide; the visible mucous membranes pale; the neck is thin; the thorax long and flat. The dura is tense, and the sinuses contain liquid and clotted blood. The pial vessels are full of blood, and the meshes are distended with turbid serum, especially at the base about the beginning of the Sylvian fissures. Along the vessels, principally those in the Sylvian fissures, are many small gray nodules; on close examination some nodules appear to be situated in the walls of the vessels. The brain substance is moist and soft; the convolutions are flattened; the ventricles are filled to dilatation with turbid serum, the ependyma being softened.

The mucous membrane of the nose and of the pharynx is covered with yellow, viscid mucus. The thyroid is of normal size. The pericardium is empty, the heart small and brown. The right pleura is covered with fibrinous exudate, in which are miliary nodules, and in the cavity is about one litre of clear serum. In both lung apices are circumscribed tubercular foci. The peribronchial lymph glands contain caseous masses. In the liver are caseous nodules which have a softened, bile-stained centre. The capsule of the spleen contains caseous masses. The kidneys are small, smooth, and pale brown; in the interior are scattered small yellowish nodules. The genito-urinary mucous membranes are normal. The stomach, the intestines, the pancreas, and the adrenals are normal. In the spinal pia are occasional miliary granulations and some infiltration with turbid serum.

Bacteriological Examination.—Cover-glass preparations from the meningeal exudate contain tubercle bacilli often in heaps of four to six, and usually free. No other bacteria are present.

Plate cultures from the exudate remain sterile at the end of some

days in the thermostat, but blood-serum tubes present pure growths of tubercle bacilli.

The injection of 0.3 cubic centimetre of ventricular fluid through a small trephine opening into the subarachnoid space of a rabbit produced in two weeks a solitary tubercle 0.8 centimetre large in the subjacent brain with meningeal adhesions, accompanied with great emaciation, but without fever; there was no meningeal exudate and no admixture of other bacteria.

Cover-glass preparations from the nasal muco-pus contain staphylococci, streptococci, diplococci, and occasional tubercle bacilli.

Histological Examination.—The arterial changes in this case present many points of interest that may be summarized as follows: The serial sections through pieces of the Sylvian arteries, including the tubercles that seemed to sit in the arterial wall, show a distinctly circumscribed and focal infiltration of all the layers of the wall, with some caseation and considerable thickening of the intima underneath the endothelium (at times this is absent), often accompanied with a sharp, punched-out perforation of the elastic layer and a more or less precisely circumscribed infiltration in the media, the adventitial changes being at times marked, at times very insignificant, or even entirely absent (Plate VIII, Fig. 5). Now it happens that in such foci as these there may be a distinct outward bulging of the vessel wall corresponding to the infiltration in the media, the ends of the elastic lamina being turned outward on each side of the perforation, the whole representing to some extent a minute aneurism in which the arterial wall is more or less completely substituted by tuberculous granulation tissue. Many such peculiar foci are found not only in the branches in the Sylvian fissures, but also in the arteries of the convexity. In some places only the innermost portions of the granulation tissue (the part between the ends of the elastic lamina and in the intima) is caseous; giant cells are not present. Rupture with hæmorrhage of any such perforating focus was not found.

Isolated intimal masses of cells without changes in the media or in the adventitia are also found, and at times they show distinct caseation; some doubtful giant cells are also seen.

Furthermore, the vessels present a marked endarteritis both with as well as without changes in the other walls, leading often to a more or less complete occlusion of the lumen. Occasionally the subendothelial intimal proliferation breaks through the elastic layer and spreads out between this and the media.

A smaller series of sections through the cerebellar cortex includes a focus of endarteritis in a large vessel. As is usually the case, it is distinctly subendothelial, and the cells are mostly large and round with some scattered lymphocytes. A distinct intercellular substance is not observable. At the point where most marked it produces occlusion of one part of the lumen; here the cells of the endothelial layer meet each other in the centre of the vessel. There is a very slight infiltration with some hyaline degeneration in the inner layers of the surrounding media with barely perceptible peri-arterial changes. There are occasional cells with two to four nuclei, but no distinct giant cells.

In places where the changes are diffuse the smaller arteries are totally infiltrated, caseous, or hyaline. The walls of the veins are usually extensively infiltrated, and at times the lumen contains thrombotic masses. In the spinal pia there is some infiltration into the arterial adventitia and into the walls of veins; there are no special changes in the intima of the arteries.

In all the sections from this case the only indications of giant cells observed after vigilant search were certain irregular masses with many nuclei in the intravascular foci. Tubercle bacilli were found in small numbers in the intimal proliferations, and somewhat more numerous in the extravascular granulation tissue.

CASE VIII.—From the Medical Clinic of Prof. Pribram : Woman, aged twenty-four.

Clinical Diagnosis.—Tuberculous meningitis; lumbar spondylitis. Section twelve hours post mortem (June 12, 1895).

Anatomical Diagnosis.—Obsolete tuberculosis of the peribronchial lymph glands; chronic tuberculosis of the second and third lumbar vertebræ; psoas abscess; universal subacute tuberculosis; tuberculous meningitis.

The body is 160 centimetres long, of feeble build and poor nourishment. Pale lividities posteriorly. The neck is narrow and long. The chest is flat and narrow. The abdomen is retracted.

The skull is thin, 50 centimetres in horizontal circumference. The dura is tense and in the sinuses is fluid blood. In the meshes of the pia, especially about the base, but also over the upper surface of the brain, is a turbid, sero-fibrinous exudate. Along the Sylvian arteries on both sides are innumerable minute, grayish, semi-transparent nodules, which appear to sit partly upon, partly in the walls of the vessels. Similar nodules are also found along the vessels of the convexity, the choroid plexuses, and in the floors of the lateral ventricles, but in much smaller numbers. Upon the left half of the brain are a few a little larger and yellowish masses in the pia of irregular form which extend into the brain substance.

In the thyroid gland are numerous miliary nodules. Both lung apices are slightly adherent. Throughout the pulmonary parenchyma of both sides are distributed numerous minute yellowish nodules of equal size. The heart is small, its muscle dark red, the valves thin.

The peribronchial lymph glands contain calcareous and fibrous masses. The capsule and the parenchyma of the liver contain numerous nodules which are also found in the spleen and in the kidneys. The genital organs, the stomach, the intestines, the pancreas, and the adrenals are without any special changes. In the bodies of the second and third lumbar vertebræ are caseous masses, and in the right psoas major muscle is a small abscess. The spinal cord and its membranes are without any changes.

Bacteriological Examination.—Cover-glass preparations from the meningeal exudate contain now and then single tubercle bacilli and no other micro-organisms.

Glycerin-sugar-agar plates inoculated with the meningeal exudate remain sterile after some days in the thermostat. Blood-serum tubes inoculated with the same exudate showed pure cultures of tubercle bacilli.

Histological Examination.—In some places, especially at the beginning of the Sylvian fissures as well as in the apparently somewhat older masses upon the surface of the left hemisphere, there is much fibrinous exudate and diffuse cell proliferation with caseation. Here the smaller arteries are diffusely and wholly caseous, at times hyaline. The so-called hyaline degeneration may involve the whole or part of the wall, usually the media, in the form of a homogeneous ring which stains a bluish-violet tinge with hæmatoxylin (Delafield's) and bright red with Van Gieson's stain. Hyaline masses of irregular shape are also found in the other coats of the vessels and in the

extravascular infiltration. The larger arteries frequently show a uniform and intense involvement of the adventitia and of the outer layers of the media; in the inner layers of the media the infiltration is at times diffuse, the cells being rather sparsely scattered about; at other times the infiltration is more focal and denser, with occasional cell accumulations between the elastic layer and the media. There is usually, but not constantly, a diffuse and pronounced subendothelial proliferation of large and small round cells, lying sometimes in a granular, sometimes in a slightly fibrillated matrix; frequently there are more nodular cell masses, in the centre of which is some degeneration, and also probable necrotic giant cells. Here and there the elastic layer is split up by infiltrating cells. Lymphoid tubercles with giant cells are also found upon the intima of the larger arteries, with but moderate general endarteritis, the media and the adventitia being the seat of a not very marked infiltration.

Further out in the Sylvian fissures the arteries present circumscribed nodular cell infiltration with some degeneration which involves all the coats in a fairly equal degree. More or less endarteritis is present here also. In the smaller arteries are observed focal intravascular and extravascular changes usually connected, as it were, by a mild infiltration through the media, but frequently entirely independent of each other.

Serial sections through minute masses in the pia over the brain surface show the cell mass to be connected with a small artery, one segment of its wall being completely involved in the tubercle, which seems to arrange itself in a concentric manner about this part of the vessel. Some slight and diffuse endarteritis is also present. In the centre of the tubercle the degeneration seems about as far advanced in the inner as in the outer parts of the wall involved, but at the periphery the degeneration is most marked in the peri-arterial infiltration.

The beginning of such foci as the last is probably illustrated in the small, circumscribed, subendothelial, intimal proliferations with giant cells accompanied with only slight infiltration into the media and the adventitia, and with the formation of epithelioid cells in the

peri-arterial lymph spaces, the intimal changes being by far the most pronounced which are occasionally found in the pial arteries of the convexity.

The veins are usually the seat of a diffuse infiltration; at times an apparent isolated endophlebitis is observed, but sooner or later such veins present points where the whole wall is involved.

Tubercle bacilli are present in some numbers in the endovascular foci, but most numerous in the peri-arterial infiltration.

CASE IX.—From the Psychiatric Clinic of Prof. A. Pick: Man, forty-six years old.

Clinical Diagnosis.—Delirium; meningitis cerebro-spinalis. Section ten hours after death (May 24, 1895).

Anatomical Diagnosis.—Chronic tuberculosis of the lung apices and of the peribronchial lymphatic glands; tuberculous meningitis; universal miliary tuberculosis.

Strongly built man with well-developed musculature, the body being 174 centimetres long. Rigor mortis strong. The pupils are equal, the thorax oval, and the abdomen retracted.

The skull is 56 centimetres in horizontal circumference, rather thick, and its internal surface somewhat roughened. The dural sinuses contain a moderate quantity of fluid blood. The internal meninges are rather pale; about the base the meshes contain turbid serum. Along the Sylvian arteries are numerous grayish nodules the size of millet seeds. Similar nodules are also present upon the upper surface of the cerebellum. The brain substance is moist. In the neighbourhood of the dilated ventricles, which are filled with turbid fluid, the substance is softened. The mucous membrane of the organs of the neck is pale. The thyroid is rather small. In the apices of both lungs are older caseous and calcareous masses, surrounded by dense cicatricial tissue. The parenchyma contains everywhere numerous miliary, grayish-yellow nodules. The peribronchial glands are partly caseous. The pericardium contains a small quantity of serum. The heart is of normal size, pale, the valves thin. The liver and the spleen are the seat of innumerable miliary tubercles. The kidneys are of usual size, and the cortex contains numerous miliary nodules. The genital organs, the stomach and the intestines, the pancreas, and the adrenals show no pathological changes.

Bacteriological Examination.—Cover glasses from the meningeal effusion contain a very few tubercle bacilli, but no other bacteria.

Glycerin-sugar-agar plates from the same exudate remain sterile. The nose could not be examined.

Histological Examination.—There is a moderately extensive extravascular infiltration, with some caseation, but no giant cells. The adventitia of the smaller arteries is diffusely and densely infiltrated with epithelioid cells and small round cells. At times the media remains normal, at other times it is infiltrated, but in this case there is no hyaline degeneration of the media observable. In these arteries there is also a diffuse subendothelial proliferation that sometimes nearly fills the lumen of the vessels. Small arteries diffusely involved and changed into miliary tubercles are also present.

In the medium-sized arteries there may be considerable endarteritis, occasionally leading to a nearly complete occlusion of the lumen, without changes in the other coats (Plate VIII, Fig. 3), except occasional foci in the periphery of the adventitia; then again the endarteritic changes may be associated with more extensive and dense adventitial proliferation.

The large arteries present occasional distinct tubercles located underneath the endothelium, which may be absent at but one point corresponding to which there is no thrombosis. Such a tubercle is usually accompanied with some endarteritis which extends half way or so around the vessel. At various points the cells of the tubercle may pass through the elastic lamina and infiltrate the media. In the adventitia there may be some proliferation corresponding to the tubercle, but only of slight degree. In places the subendothelial intimal proliferation commences with the formation of cells upon the elastic lamina; in some of these cells the nucleus is large and swollen; distinct karyokinesis is not found. In some places the larger arteries present a focal chronic thickening of the intima which takes no part in the acute changes.

The veins are usually the seat of circumscribed or diffuse infiltration that always is connected with neighbouring foci.

There were no giant cells in this case.

Tubercle bacilli were found in fair numbers in the peri-arterial infiltration and in the walls of small arteries.

Before considering the special arterial changes in this series of cases of tuberculous meningitis a few remarks concerning the bacteriological examinations are necessary.

Of the nine cases, but one presented a mixed infection due to a staphylococcus, which was present in small numbers in the meningeal exudate and gave rise to three colonies upon the plate cultures made from the fluid.

The microscopic examination does not indicate positively that the presence of this staphylococcus had any distinctly recognisable effects upon the intensity or the character of the inflammatory changes of the case in which it was found.

Very likely the meningeal infection by this staphylococcus took place from the nose, in the mucus of which were a large number of similar staphylococci. The possibility of a general infection of the blood from some other source than the nose can not be denied in the absence of decisive investigation on this point.

That only one case of nine should show a mixed infection is a little unexpected in view of the results obtained by Babes, who examined seventeen cases of acute tuberculous meningitis bacteriologically and found, in addition to the tubercle bacillus, twice the micrococcus lanceolatus, twice the streptococcus, twice staphylococci, and in two cases two separate varieties of pathogenic bacilli, making eight of the seventeen cases instances of mixed infection.

Pasquale also found and isolated the streptococcus pyogenes in one case of tuberculous meningitis and in one case of tuberculosis of the ependyma.

In five of nine cases a superficial examination of the mucus and muco-pus of the nose for tubercle bacilli by means of the staining method gave a positive result in two instances (Cases I and VII). The indications are, then, that a more thorough search, accompanied with inoculations into susceptible animals, would have given more numerous positive results.

The tubercle bacilli present in the two instances may have found their way into the nose from the tuberculous foci present in the lungs in both instances, or through inhalation from the outside (Straus), or from the meningeal exudate in which they are present in cases of tuberculous meningitis.

Gradinigo found in this disease tubercle bacilli in sections from the nerves that pass through the internal ear and also in the pharyngeal mucus in the neighbourhood of the openings of the Eustachian tube, and he considers that they pass out from the subarachnoid space by the route thus indicated.

In three cases cultures of tubercle bacilli were obtained by merely inoculating a drop or two of meningeal fluid upon glycerin agar or blood serum.

It is consequently easy to secure cultures of bacilli from the lesions of tuberculous meningitis. This is shown also by von Wunschheim, who obtained cultures three times out of five attempts by inoculating the small nodules of acute tuberculous meningitis directly on serum.

The results of the histological examination of the instances of tuberculous meningitis that have been detailed in the foregoing pages demonstrate that in every case extensive vascular changes of various kinds were present.

The fact that in the arteries not only the adventitia, but also the media, and even the intima, present frequent and marked tuberculous lesions, should naturally attract much attention.

The arterial tuberculosis presents itself for discussion not only from the essentially histological point of view, but requires consideration also with more particular reference to the mode of the invasion of the arterial wall, whether from within or from without, and to the relation in each instance of the arterial changes to the general meningeal infection.

With these problems in sight, the essential lesions of the various cases may be summarized in this general way:

Cases I, II, III, and IV are accompanied with one or more

chronic meningo-encephalitic foci. In Case I there is a caseous nodule one cubic centimetre large along the anterior margin of the left cerebellar hemisphere, and connected with the pachymeninx; in Case II are numerous pea-sized nodules in the cortex connected with the pia, and in Case III many larger and smaller caseous masses in the brain, cerebellum, and pons; in Case IV the beginning of the Sylvian arteries and of the arteries of the corpus callosum is surrounded by chronic meningo-encephalitic masses.

In the remaining instances larger chronic, tubercular foci are not present in the brain.

In all the cases there were multiple chronic, caseous masses in various parts of the body, the peribronchial lymphatic glands, for instance, being more or less involved in every case.

In three instances (III, VI, and IX) there was a general acute, miliary tuberculosis, and two other cases (V and VIII) presented a universal subacute tuberculousis.

In Cases I and III the proliferation and degeneration, as far as the arteries are concerned, involve principally the adventitia and the media. In some places there is a diffuse affection of the whole wall, and very frequently is this the case in the smaller arteries. Both present also some subendothelial, intimal proliferation, but the changes in the outer walls are, altogether, the predominating.

In Case II the Sylvian artery presents a circumscribed infiltration that reaches the intima, and the smaller branches in the Sylvian fissures are the seat of an endarteritis without marked adventitial or medial changes.

In Case IV the entire walls of the larger basal arteries are infiltrated and caseous, so that the structure is not recognisable, and degenerated cell masses are found upon the intima that may have been miliary tubercles. Otherwise a thorough examination fails to demonstrate intimal tubercles or giant cells in any one of these four instances.

In Case V, however, the arteries of the corpus callosum present distinct intravascular tubercles with diffuse infiltration, caseation and giant cells; extensive changes are present in the media and

the adventitia, as well as in the surrounding tissues. Small caseous masses in the pia are closely bound to the arterial walls.

In this case the gelatiniform, sero-fibrinous exudate characteristic of tuberculous meningitis was not present. Nevertheless, it does not seem quite correct to regard the process as a subacute miliary tuberculosis of the pia exclusively, because the turbid meningeal fluid contains many epithelioid cells, leucocytes, and also tubercle bacilli. The diffusion of the bacilli in the meningeal fluid may have occurred very shortly before death, and the gross inflammatory products may have been absent on this account.

In Case VI the intravascular changes are best marked (Plate VIII, Figs. 1, 2, and 4). They consist of a diffuse endarteritis that at times leads to occlusion of the lumen, especially in the smaller arteries. Giant cells and typical tubercles occur in the endarteritic districts. Isolated intimal tubercles are present. The diffuse intimal proliferation and the intimal tubercles occur as the only disease of the arterial wall as well as in association with changes of variable intensity in the other coats.

Cases VI, VIII, and IX are really identical as regards these lesions, the only differences being those of degree.

Case VII is characterized by sharply circumscribed infiltrations through the whole thickness of the arterial wall that often lead to small aneurismal bulgings (Plate VIII, Fig. 5). Only the innermost layers of this granulation tissue may show caseation. Isolated masses of cells, at times caseous, are also found upon the intima without any changes in the other walls. In addition there is present a diffuse endarteritis, at times associated with changes in the adventitia and the media, at times being the only lesion present in the whole arterial wall.

In Case VIII is an endarteritis with indistinct tubercles that show signs of caseation, associated with diffuse and extensive changes in the media, but there are also intimal tubercles with but slight alterations in the other walls, and the mode of origin of the minute granulations connected with the arteries of the pia over the convexity

can be traced with reasonable certainty to primary subendothelial proliferations in the intima which contain giant cells.

In Case IX are distinct intimal tubercles without giant cells but with caseation accompanied with a more diffuse endarteritis and slight infiltration of the media and the adventitia. In the smaller arteries are very diffuse changes.

In the sections from all the cases tubercle bacilli were present in small numbers in the intimal lesions, in the lumen of infiltrated veins and smaller arteries and their walls, and in much larger numbers in the adventitial proliferation. The infiltrated part of the Sylvian artery in Case IV contained bacilli in great numbers.

The demonstration of tubercle bacilli, free and intracellular, in the meningeal exudate in the majority of the cases has been considered.

In such cases as all of these under consideration at the present time the extensive and multiple tuberculous processes in various organs indicate clearly enough that tubercle bacilli must have gained entrance into the general circulation. This circumstance alone would be good reason for regarding the tuberculous meningitis as of a hæmatogenous origin. In addition, the extensive lesions of the arterial intima in all these cases, especially when studied in their relation to the changes in the other layers of the arterial wall, furnish direct anatomical evidence that bacilli were deposited upon the intima from the blood, and that the meningitis positively resulted from blood infection.

It is true that in the three first instances described distinct intimal tubercles with giant cells were not found, and that the changes in the adventitia and in the media of the larger arteries predominate over those in the intima, the latter consisting in the main of a more diffuse subendothelial proliferation. It might consequently be said that perhaps the chronic tuberculous masses in the brain and in the meninges, which were present, more likely furnished the source of the meningeal invasion in these cases.

In no one of the three cases, however, does the distribution of the characteristic lesions indicate that the meningitis developed from

the chronic cerebral foci. It matters not where the old caseous masses may be situated, the acute lesions, the miliary tubercles, and the exudate are found best marked around the arteries of the Sylvian fissures and of the corpus callosum. The meningeal changes do not radiate in all directions from the chronic foci, but they have that general distribution with the special predilection for the Sylvian arteries which is so characteristic of blood-borne infection.

When the intravascular changes in these cases are studied in the light in which such lesions are presented to view in the remaining instances, then it becomes plain that arteries, especially small ones, the entire wall of which is infiltrated and caseous, may just as well have been invaded from within as from without, and that an endarteritis which is not accompanied with very extensive changes in the media and the adventitia is most likely the primary arterial change. The occasional presence of tubercle bacilli in the lumen and in the wall of smaller arteries (Cases I and III) also point to infection by way of the blood.

The gross distribution of the meningeal lesions, then, the endarteritis present in all the three cases, though in varying degree, as well as the diffuse involvement of arteries, especially the smaller, afford substantial anatomical reasons for regarding the meningitis as of hæmatogenous origin, and the arterial changes presented as in part at least the direct result of this mode of invasion.

In Case IV the intense involvement of the large basal arteries in the chronic leptomeningeal process may be taken to indicate that the latter began in the arterial wall, but the local changes are in a measure too diffuse and the degeneration too far advanced to form any definite idea as to the exact order of the development of the lesions.

The situation of the chronic meningeal foci in this case, associated as they are with such diffuse arterial changes in the neighbourhood, suggests the possibility that these masses furnished at one and the same time the source for an arterial dissemination of the bacilli into the leptomeninx as well as of an infection of the pial lymph spaces.

In the remaining cases the arterial lesions indicate with great certainty that an invasion of the wall frequently occurred from within. While the wall in these cases also presents diffuse changes—changes that especially involve the adventitia, from which they may spread inward—there are also very extensive and important changes in which the intima plays the essential part (Plate VIII, Figs. 1, 2, 3, 4, and 5).

As already shown, tubercles in the intima may occur in association with more or less diffuse changes in the other coats, accompanied with an extensive endarteritis, or they may occur without any other changes of the arterial segment in the intima of which they are situated (Plate VIII, Fig. 4). Foci of granulation tissue that perforate the arterial wall more or less sharply also seem to begin in the intima (Case VII, Plate VIII, Fig. 5).

Associated with these typical tuberculous changes is an endarteritis that may occur independently or be connected with infiltration in the media and the adventitia. The presence of this endarteritis without changes in the other layers of the wall, but being confined to the internal surface of an artery throughout its entire extent,* shows conclusively that this very interesting form of intravascular lesion in tuberculous meningitis may be primary and due to inflammatory agents circulating in the blood (Plate VIII, Figs. 1, 2, and 3).

Bearing the fact in mind that such extensive and undoubtedly primary intimal lesions may be present in tuberculous meningitis, it will become exceedingly difficult, if not entirely impossible, to decide where the process may have had its point of origin in the case of more or less diffuse involvement of the arterial wall when associated with endarteritis.

On this account it would be unsafe to regard the changes of the arterial wall to proceed always from without inward, as Guarnieri concluded. Even the greater intensity and the apparently greater

* By means of the serial sections it was possible to establish the exact relations that the changes in the arterial wall may bear to each other when not too far advanced. The actual existence of an isolated intimal tubercle or of a limited focus of endarteritis, for instance, could only be demonstrated by means of serial sections of the whole extent of the artery involved.

age, as determined by degeneration, of lesions in the adventitia and the media can not be regarded as absolute criteria as to the point of primary attack of the arterial segment, because there is occasionally found a district of hyaline degeneration of the inner part of the media immediately underneath intimal foci that present but slight retrogressive changes, no other lesions of the wall being visible. Degeneration can consequently develop in the media secondarily to well-preserved adjacent foci of proliferation in the intima.

Invasion of the media and of the intima from without certainly occurs in tuberculous meningitis as well as elsewhere, as, for instance, in the lungs, and with great frequency. This is shown best by the presence of diffuse or circumscribed adventitial proliferation that gradually extends into the media and reaches the intima perhaps only at one point. In this way an endarteritis due to direct extension from without may arise and extend along in the intima.

It seems, however, that an endarteritis distinctly traceable from without rarely reaches the extent of the primary endarteritis. Intimal tubercles with giant cells were not found upon the arteries in which it could be shown with certainty that the process invaded the arterial wall from without. In connection with this, attention is called to the fact that in many cases the only giant cells found after vigilant search were those in the endarteritic foci.

Whether or not tuberculous processes confined to the adventitia can give rise to an acute intimal proliferation, without direct extension of the inflammation through the media, hardly needs discussion. Chronic inflammatory processes in the neighbourhood of arteries are often stated to call forth an obliterating endarteritis (see note, page 119). In acute tuberculous meningitis one very often observes extensive changes in the adventitia associated with proliferative changes of variable extent in the intima, the media remaining unchanged. Whether the changes in the outer and the inner layers bear any direct and intimate relations to each other under these circumstances must be left undecided for this one reason, if for no other—namely, the impossibility of excluding a direct hæmatogenous origin of the endarteritis. The same consideration applies to the obliterating,

subendothelial intimal proliferation observed by Weintraud in more chronic meningo-encephalitic tuberculous foci, and attributed by him, in accordance with the views of many writers, to influences acting upon the intima from without; the intimal lesions may have been caused by direct infection from the blood.

It is self-evident that following the total invasion of an arterial wall from without, a local diffusion of bacilli might occur in the corresponding branches with, perhaps, a secondary endarteritis due to implantation of the bacilli upon the intima. And of course the same manner of propagation may follow primary intimal foci. In either case a destruction of the endothelium would be most favourable for the admission of bacilli into the blood current, and at such times thrombosis may hinder the process from spreading in this manner.

The tuberculous endarteritis that has been described as occurring primarily and independently of changes in the outer arterial coats demonstrates that tubercle bacilli are implanted in the intima. The intact endothelium usually present shows that the bacilli must reach the subendothelial layer at once after passing through the endothelial lining.

Attention may be called to the fact that the arteries in the Sylvian fissures present probably the greatest degree of endarteritis. This fact may be accounted for by the favourable conditions offered by these vessels for the localization of the microbes. In other words, it would seem that to some extent the same conditions obtain in the localization of the bacilli as are so frequently observed to be operative in connection with the import of emboli into the brain.

The marked degree of primary endarteritis in the Sylvian arteries explains also, to some extent at any rate, the relatively greater development of the adventitial and extravascular changes in the Sylvian fissures than elsewhere.

The histological examinations show that the muscular coat of the large as well as the small arteries is the frequent seat of infiltration and caseation that may have their origin in the adventitia or in the intima, according as the invasion occurs from within or from without. Appearances indicating the origin of new cells from the muscle

fibres, which Rindfleisch is inclined to believe that he has observed, were not present in any of these instances, in all of which the medial changes seemed to be the result of a direct extension of the process in the adventitia or in the intima.

When the infiltration invades the media from the intima, the elastic membrane always presents evidences of a more or less direct destruction of its continuity (Plate VIII, Figs. 4 and 5). At times it is split up by invading cells that seem to be in the act of passing through it. When the process is further advanced it may present a sharply cut defect occupied by granulation tissue or by caseous material. At other times the elastic membrane as well as the inner part of the media undergo a peculiar hyaline degeneration underneath foci of proliferation in the intima. In Case VII, in which the arterial walls present numerous aneurismal bulgings at the seat of perforating foci of tuberculous infiltration, the ends of the perforated elastic layer are bent outward.

In the descriptions of the microscopical changes frequent reference is made to the infiltration and caseation of the whole wall, especially in smaller arteries, and to a more or less extensive hyaline degeneration whose favourite seat seems to be the media, but which may occur in any part of the vessel wall as well as in the extra-vascular infiltration. This hyaline degeneration was observed in the media as the only change in the whole wall in addition to focal or diffuse endarteritis.

This peculiar hyaline necrosis in tuberculous meningitis has been fully described by Guarnieri, according to whose opinion the hyaline substance represents the end products of degeneration in the tubercle cells, the muscle cells, and the exudate.

The pial arteries in tuberculous meningitis consequently present excellent opportunities for the study of hyaline degeneration which here seems to appear very rapidly under the influences of the acute inflammatory process.

In addition to the arterial changes, those in the veins merit attention (Plate VIII, Fig. 6). In all the instances the veins, large and small, show diffuse or circumscribed infiltrations of the walls that

invariably proceed from changes in the neighbourhood, as, for instance, in an adjacent artery. Giant cells frequently occur in the infiltrated walls often lying next to the blood stream. Caseation and disintegration are also found, and frequently the lumen is thrombotic. Tubercle bacilli are also present in the infiltrated walls.

No doubt general military tuberculosis may develop secondarily to tuberculous meningitis on account of a dissemination of tubercle bacilli from these extensive and constant lesions of the pial veins. Tedeschi found that a general infection occurs very rapidly after the subdural inoculation of rabbits and other animals with tuberculosis.

All authors emphasize the prominent part played by the adventitia in the formation of the tubercles and more diffuse infiltrations in tuberculous meningitis. It is in the lymph spaces of this layer of the arterial wall that the tubercle bacilli appear to find the most favourable conditions for rapid growth. Especially in the early part of the process large cells, often containing tubercle bacilli can be seen filling the adventitial lymph spaces. Some of these cells may be carried away with the lymph stream, and, as the cells fall to pieces, the bacilli are set free to start new centres of proliferation. Thus in Case V the presence of many bacilli in the epithelioid cells of the subarachnoid fluid, and also in similar cells in the lymph spaces about the arterial tubercles, shows most conclusively the manner in which the bacilli may be diffused in the subarachnoid space from adventitial foci.

It will, of course, be recollected that the lymph spaces of the adventitia of the arteries can be injected from the subarachnoid space (Stöhr).

Regarding the further evolution of the lesions of tuberculous meningitis, it may be said that the accumulation of exudate containing bacilli in the large lymph cisterns of Key and Retzius, in the Sylvian fissures, and at the base, is certainly most favourable for the development of extensive extravascular lesions in these localities.

The spread of the bacilli from the adventitial lymph spaces throughout the subarachnoid effusion may lead to a spinal leptomeningitis. The latter was present in four out of the five of these cases

in which the spinal cord was examined—namely, in Cases I, III, IV, and VII—and in all instances the arterial lesions pointed to a lymphogenous invasion. An infection of the spinal pia through the blood is, of course, possible, but in our cases the arterial lesions do not indicate that such was the case.

The cerebro-spinal fluid may also carry the bacilli into the lymph spaces of cranial as well as of spinal nerves, where they may cause an interstitial (tuberculous) neuritis, as shown by Schultze with reference to spinal nerves, by Kahler in case of the oculo-motor nerve, by Gradinego as regards the nerves that pass through the middle ear, and by Deutschmann in case of the optic nerves in rabbits, in which he produced experimental tuberculosis of the brain and its membranes.

From the subarachnoid space the bacilli may also find their way into the nose and the pharynx, as already pointed out.

The relation of the changes in the intima observed in these cases to the changes in the other coats has been explained. It has been emphasized that the intimal changes are of comparatively slight degree, and without definite tubercles or giant cells, in those places where it can be definitely shown that the invasion of the artery occurs from without; that in the case of total infiltration and caseation of an arterial segment no opinion can be formed as to the order of the development of the lesions; that intimal proliferation, often associated with giant cells, distinct tubercles, and caseation, and without extensive confusing changes in the media and the adventitia, is positive anatomical evidence of the implantation of bacilli (which may be present in these lesions) from the blood.

As already pointed out, Huguenin, Huettenbrenner, Cornil, and Hirschberg have also described similar intravascular tuberculous lesions in the pia, and have expressed practically the same views as the preceding concerning the signification of such lesions as regards the mode of infection.

Tuberculous changes in the intima which are susceptible of the sole explanation that they are the direct result of the import of the bacilli by the blood, were found more or less clearly marked in all the nine cases of this series, and in some cases—as, for instance, in

Case VI—the intravascular changes are almost as extensive and as pronounced as the extravascular.

The general conclusion is consequently warranted that in tuberculous meningitis of blood-borne infection an unexpectedly frequent and significant localization of the bacilli occurs upon the intima of pial arteries in addition to that in the arterial adventitia.

Experimental tuberculous meningitis has been studied by Deutschmann, who investigated the relation between miliary tuberculosis of the brain and its membranes and affections of the eyes after injecting tuberculous material underneath the skull of young rabbits; by Daremberg, who produced tuberculous meningitis by the injection of pure cultures underneath the skull of rabbits; and by Tedeschi, who injected tuberculous material into the cranial cavity and spinal canal of eighty-five animals of various kinds. In addition to producing a meningo-myelitis and a meningo-encephalitis as well as diffuse miliary tuberculosis, the last-named writer found that the inoculation of tubercle bacilli into the nervous centres of animals resulted in a marked increase of virulence on the part of the bacillus. This virulence became normal again after passing the bacilli through the body of guinea pigs.

Inasmuch as there were no experiments in which the attempt had been made to produce tuberculous meningitis in the manner in which the disease nearly always develops in man—namely, through arterial infection—a series of experiments with this object in view were commenced. These investigations are as yet incomplete; but as the results already obtained in a measure bear upon the conclusions expressed as regards the tuberculous endarteritis that has been described, the report of the following experiment may be introduced:

May 16, 1895. Injection of 0.1 cubic centimetre of a bouillon suspension of a glycerin-agar culture of tubercle bacilli into the left carotid artery of a large rabbit.

The carotid was ligated above and below the point of puncture.

Soon after the operation the animal began to emaciate. Shortly

before it was killed the media of the left eye became turbid; there was some pericorneal injection and turbid conjunctival secretion.

June 5th, 6 P. M., killed.

Section.—Pronounced emaciation. The media of the left eye turbid. There is no increase in the amount of cerebro-spinal fluid, and the pia mater is everywhere transparent and thin. Along the vessels of the convexity of the left hemisphere, especially over the posterior half, are numerous minute grayish nodules of varying size, the largest being perhaps one millimetre in diameter. There are no visible nodules in the pia over the right hemisphere, over the cerebellum, the bulb, or the base of the left hemisphere.

There are numerous miliary nodules in the liver and some in the spleen, but not in any other organs. The left carotid, being cut across between the two ligatures a little above the clavicle, shows that the ends are filled with a whitish granular mass. Immediately above the upper ligature the vessel is surrounded by a flat, oval caseous mass one centimetre in its greatest diameter.

Microscopic Examination.—After fixing in sublimate and staining on the slide with hæmatoxylin and carbol-fuchsin, sections through the meningeal nodules and the subjacent cortex show a dense infiltration of lymphoid cells around small granular masses, containing tubercle bacilli, which seem to occupy the interior of small arteries, the walls of which are entirely converted into granulation tissue. Sometimes the granular mass, including the bacilli, becomes infiltrated with nuclei and assumes an appearance not unlike giant cells. At the periphery of such nodules the lymph spaces are loosely filled with cells, but bacilli are seldom found except in the central part of the tubercles.

The interior of the left hemisphere contains a large number of minute foci of granulation tissue in which may be giant cells and tubercle bacilli, the latter embedded in granular masses.

The nodules in the liver are miliary tubercles. The ciliary body of the left eye contains miliary tubercles with giant cells located in the vicinity and about the arteries. The anterior and posterior chambers are filled with granular material.

This experiment shows that a meningeal and cerebral miliary tuberculosis can be produced in rabbits by injecting bacilli into the carotid—i. e., through direct hæmatogenous infection. The resulting tubercles develop in connection with the smaller arteries. In the experiment described the lesions were too far advanced to afford any definite observations as to the early histogenesis of the process.

In the foregoing has been described a tuberculous endarteritis the histogenesis of which presents several points of interest.

The histological appearances may be briefly recapitulated as follows: In addition to intimal tubercles there occurs a more or less extensive endarteritis, which reaches its greatest degree of development in the medium-sized or smaller arteries in which it frequently leads to great narrowing and almost complete obliteration of the lumen. That this endarteritis may be primary and not due to extension from the outside is readily shown by serial sections extending through endarteritic foci in which the arterial wall is otherwise normal (Plate VIII, Figs. 1, 2, 3, and 4).

In all well-preserved specimens the proliferation—which consists of epithelioid cells with but occasional lymphocytes and polynuclear leucocytes and, quite rarely, multinucleated giant cells (Plate VIII, Fig. 2)—is invariably subendothelial, the cell layers lying between the elastic lamina and the intact but loosened and elevated endothelium (Plate VIII, Figs. 1, 2, and 3). Frequently characteristic intimal tubercles develop in this proliferation, and as they become caseous the endothelium over them may disappear (Plate VIII, Fig. 4).

In the early stages the endarteritis presents itself in the form of small nodular accumulations of cells that present unmistakable signs of active proliferation underneath an intact endothelium, which is lifted up into folds. In many places the subendothelial cells penetrate the elastic membrane and invade the muscular coat to a greater or less extent.

Similar appearances, though less marked, are found in arteries that are invaded by cell infiltration from the adventitia.

The subendothelial intimal proliferation may present caseation

and hyaline degeneration. Only occasional tubercle bacilli are found in and among the epithelioid and other cells.

The endothelial cells remain entirely passive and present no appearance of active proliferation, the lining being mechanically lifted away, as it were, by the increasing cell accumulation underneath. At times the endothelial lining becomes disarranged, especially when the endarteritis is very marked.

The origin of the epithelioid cells that in the main constitute the subendothelial proliferation is a question of great interest.

Nearly all the authors that have described endarteritic changes in tuberculous meningitis refer to these cells as the results of multiplication on the part of the endothelium. Huguenin, Guarnieri, Brodowski, Baumgarten, Hirschberg—all seem to take this view.

Baumgarten, in his classical research upon the histogenesis of tubercle, also refers to certain changes in the intima in experimental pulmonary tubercle as due to endothelial proliferation.

Metschnikoff assigns to the endothelial cells an active rôle in the formation of hepatic and pulmonary tubercle.

This is not the place to enter into a detailed discussion of the origin of epithelioid cells in general. The views of Baumgarten and of Metschnikoff are familiar enough. The recent studies by Kostenitsch and Wolkow and by Borel of the development of experimental tubercle treat of the various phases of this question with considerable minuteness of detail.

While it is evident that the morphology of the epithelioid cells in the endarteritis of tuberculous meningitis can not explain their nature or declare their derivation, it seems that their origin from the endothelial cells can be positively excluded on account of the condition of the endothelial lining itself. Were the epithelioid cells in question produced by proliferation of the endothelial cells, then the endothelial lining would be disarranged, and the subendothelial proliferation would no longer be limited on the side of the lumen by a single layer of typical endothelial cells that show no signs of multiplication whatsoever. The division of a single endothelial cell into two would certainly result in some displacement of the dividing cell

with reference to the other cells in the endothelial lining. Baumgarten's figure of a young metastatic tubercle in the lung shows, on the other hand, like the sections of the tuberculous endarteritis, an artery with a mass of epithelioid cells between an unbroken and unchanged row of single and typical endothelial cells and the elastic layer. Near by is represented karyokinesis in what may be the unchanged endothelium, but the karyokinetic figure may also be in a subendothelial connective-tissue cell.

For these reasons it may be concluded that the endothelial cells take no active part in the production of epithelioid cells in tuberculous endarteritis; on the other hand, it would seem that the endothelial cells remain not only passive, but even resistant to the bacilli and their products, because the lining remains intact and unbroken until the proliferation almost fills the entire lumen. When caseation occurs, however, then the endothelial cells disappear.

As already stated, the bacilli must apparently pass through the endothelium and into the subendothelial layer of connective tissue, which, from the early appearances of the endarteritic proliferation, most likely gives rise to the epithelioid cells.

CONCLUSIONS.

1. In tuberculous meningitis there is a tuberculous endarteritis characterized by the formation of intimal tubercles and a diffuse subendothelial, intimal proliferation due to implantation of tubercle bacilli from the blood. From the endarteritis the infiltration may spread into the muscular coat and the adventitia, and the whole wall may undergo caseous and hyaline degeneration.

2. Tuberculous proliferation in the adventitia may invade the media and the intima, and the whole wall of the arterial segment may undergo degeneration.

3. The veins are constantly the seat of more or less extensive infiltration, which always results from adjacent extravascular or arterial foci.

4. The epithelioid cells of the subendothelial, tuberculous intimal

proliferation are most likely derived from the subendothelial layer of connective tissue and not from the endothelial lining.

There remains the pleasant duty of expressing the warmest thanks to Prof. Chiari for his constant aid and advice during the progress of the work embodied in this article.

DESCRIPTION OF PLATE VIII.

Fig. 1.—Subendothelial proliferation of epithelioid cells without any changes in the other coats. Note the intact endothelium. From Case VI. Zeiss, Obj. E, Oc. 4.

Fig. 2.—Subendothelial intimal proliferation with multinucleated giant cell. The media and the adventitia are normal, and the endothelium is intact and unchanged. From Case VI. Zeiss, Obj. E, Oc. 4.

Fig. 3.—Subendothelial proliferation leading to almost complete occlusion of the lumen of a medium-sized artery without any changes in the muscular or adventitial layers, the endothelial lining being visible in the centre of the vessel. From Case IX. Zeiss, Obj. A, Oc. 4.

Fig. 4.—Diffuse endarteritis with small intimal tubercle; at *a*, multinucleated giant cell; underneath the tubercle there is perforation of the elastic lamina and beginning slight infiltration into the media; otherwise the media and the adventitia are quite unchanged. The endothelium, which is present over the diffuse intimal proliferation, is absent over the tubercle, which is undergoing caseation and covered with a finely granular thrombotic mass. From Case VI. Zeiss, Obj. A, Oc. 2.

Fig. 5.—Caseous intimal focus which has caused perforation of the elastic layer, the ends of which are bent outward, and infiltration into the media and the adventitia, the whole having a slight resemblance to a small aneurism. Note the commencing subendothelial intimal proliferation in the opposite wall of the artery. From Case VII. Zeiss, Obj. E, Oc. 2.

Fig. 6.—Focal tuberculous infiltration with giant cell into and through the wall of a vein with secondary thrombosis, the process being due to extension from the neighbourhood. Case II. Zeiss, Obj. C, Oc. 4.

LITERATURE CITED IN THE TEXT.

Arnold.—Beiträge zur Anatomie des Miliartuberkels. Virchow's *Archiv*, Bd. lxxxvii, p. 145, 1882.

Baumgarten.—Ueber gummöse Syphilis des Gehirns und Rückenmarks, namentlich der Gehirngefäße, und über das Verhältniss dieser Erkrankungen zu den entsprechenden tuberculösen Affectionen. Virchow's *Archiv*, Bd. lxxxvi, p. 206, 1881.

Baumgarten.—Ueber Tuberkel und Tuberkulose, Berlin, 1885, p. 77.

Babes.—Sur les associations bactériennes dans la tuberculose. *Annales de l'Inst. de Path. et de Bact. de Bucarest*, ii, 1890, p. 279.

Babes et Cornil.—Note sur les bacilles de la tuberculose et sur leur topographie dans les tissus altérés par cette maladie. *Journal de l'anat. et de la physiol.*, 1883, xix, p. 456.

Birch-Hirschfeld.—Lehrb. der pathol. Anatomie, III Aufl., 1887, p. 221.

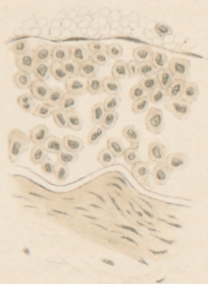

FIG. 1.

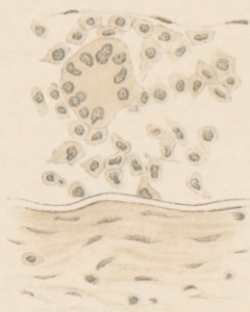


FIG. 2.

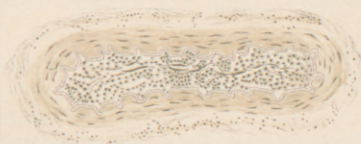

FIG. 3.

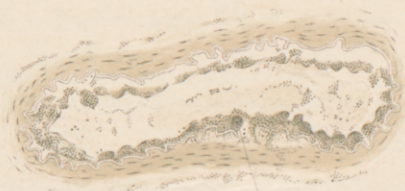

FIG. 4.

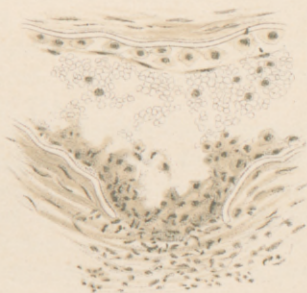


FIG. 5.



FIG. 6.

Borel.—Tuberculose pulmonaire expérimentale, *Ann. de l'Institut Pasteur*, 1893, p. 593 ; Tuberculose expérimentale du rein, *ibid.*, 1894, p. 65.

Brodowski.—Ueber den Ursprung sogen. Riesenzellen. *Virchow's Arch.*, lxxiii, p. 125, 1875.

Buhl.—Lungenentzündung, Tuberkulose, und Schwindsucht, München, 1872.

CoinDET.—Quoted by Huguenin, v. Ziemssen's Handbuch, xvi, 1, p. 484, 1878.

Coats.—A Case of Tuberculosis in an Organized Blood-Clot on the Dura Mater. *Journal of Path. and Bact.*, vol. i, p. 460, 1893.

Cornil.—Contribution à l'étude de la tuberculose. *Journal de l'anat. et de la phys.*, xvi, p. 313, 1880.

Cornil et Babes.—Les bactéries, 2d ed., 1885, p. 695.

Cornil et Ranvier.—Manuel d'Histol. path., 1881, i, p. 681.

Demme.—Quoted by Klebs, *Allgem. Path.*, 1887, I Theil, p. 223.

Demme.—Beiträge zur Kenntniss der Tuberkulose des Kindesalters. 26 Bericht des Jennerschen Kinderspitals in Bern, 1888.

Danforth.—A Typical Case of Tubercular Meningitis. *American Quarterly Microscop. Journal*, 1878, quoted by Earle, *Chicago Med. Journal and Examiner*, 1879, p. 11.

Daremberg.—Notes sur la méningite tuberculeuse expérimentale et la durée variable de l'évolution de la tuberculose. Études exp. et clin. sur la tuberc. Verneuil, t. i, 1887. *Centralbl. f. Bacteriologie*, Bd. iv, p. 526, 1888.

Gradinego.—Schmidt's *Jahrbücher*, 1892, Bd. ccxxxv, p. 276.

Guarnieri.—Note istologica sulla mening. tuberculare. *Arch. per le scien. med.*, vii, 1883.

Hamilton.—Text-book of Pathology, vol. ii, Part II, 1894, p. 571.

Hirschberg.—Abnorme Formen der Meningitis Tuberculosa. *Deutsches Arch. f. kl. Medicin*, xli, p. 528.

Huguenin.—Tuberculous Meningitis. V. Ziemssen's Handbuch, Bd. xvi, 1, p. 484, 1878.

Huettenbrenner.—Ueber einige Veränderungen der Gehirnrinde bei tuberculösen Entzündung der Pia Mater. *Prager Zeitschrift f. Heilkunde*, viii, p. 475, 1887.

Kossel.—Ueber Mittelohreiterungen bei Säuglingen. *Charité Annalen*, xviii, 1893.

Kostenitsch et Wolkow.—Recherches sur le développement du tubercule expérimental. *Arch. de médecine expérimentale et d'anatomie path.*, 1892, tome iv, p. 741.

Klöttsch.—Ueber die Verbreitungswege des tuberkulösen Giftes nach den Meningen bei Kindern. Inaug. Diss., Halle, 1889.

Kahler.—Ueber Wurzelneuritis bei tuberkulöser Basilarmeningitis. *Prag. med. Wochens.*, xii, p. 33, 1887.

Lancereaux.—Anat. Path., ii, 415, 1879-'81.

Metschnikoff.—Leçons sur la pathologie comparée de l'inflammation, Paris, 1892, 192.

Mügge.—Ueber das Verhalten der Blutgefäße der Lunge bei disseminierter Tuberkulose. *Virchow's Arch.*, Bd. lxxvi, p. 243, 1879.

Medin.—Tuberculous Meningitis in Small Children (Trans.). *Nord. med. Arkiv*, 1883, xv, No. 26.

Müller.—Sectionen bei tuberkulösen Kindern. *Münch. med. Wochenschrift*, 1889, No. 50.

Neumann.—Ueber die Bronchialtuberkulose und ihre Beziehung zur Tuberkulose im Kindesalter. *Deutsch. med. Wochenschr.*, 1893, Nos. 9–17.

Northrup.—Tuberculosis in Children. *Boston Med. and Surg. Journal*, February 5, 1891.

Nasse.—Beiträge zur Kenntniss der Arterientuberculose. *Virchow's Arch.*, Bd. cv, p. 173.

Orth.—Lehrbuch der path. Anatomie, Bd. i, p. 267, 1887.

Pasquale.—Ueber Streptokokken bei der tuberkulösen Infection. *Centralbl. f. Bacteriol.*, xvi, p. 114.

Papavoine.—Quoted by Huguenin, v. Ziemssen's Handb., xvi, p. 484, 1878.

Rieder.—Fälle von Meningitis Tuberculosa. *Münch. med. Wochenschr.*, 1889, Nos. 49 and 50.

Rindfleisch.—Der Miliare Tuberkel. *Virchow's Arch.*, xxiv, p. 571, 1862.

Rindfleisch.—Path. Gewebelehre, VI Aufl., 1886, p. 223.

Reinhold.—Klin. Beiträge zur Kenntniss der akuten Miliartuberkulose und tuberk. Meningitis. *Deutsch. Arch. f. kl. Medicin*, xlvii.

Straus.—Sur la présence du bacille de la tuberculose dans les cavités nasales de l'homme sain. *Arch. de méd. exp. et d'anat. path.*, 1894, p. 633.

Schultze.—Leptomeningitis acuta tuberc. cerebrospinal. *Virchow's Arch.*, Bd. lxxviii, p. 111, 1876.

Stöhr.—Gewebelehre, 1891, p. 120.

Seitz.—Meningitis Tub., Berlin, 1874.

Simon.—Du rôle de l'infection secondaire dans la path. de la meningitis tuberc. des enfants. *Rev. mens. des mal. de l'enfant*, 1893, xi, 249.

Tedeschi.—Untersuchungen über die Wirkungen der Inoculation der Tuberculose in die Nervencentra. *Centralbl. f. allg. Path. u. path. Anat.* Bd. iv, p. 497, 1893.

Virchow.—Die krankhaften Geschwülste, Bd. ii, 1864–'65, p. 639.

von Wunscheim.—Zur Frage der Gewinnung von Reinculturen der Tuberkelbacillen aus der menschlichen Leiche. *Prag. med. Wochenschr.*, 1892, No. 25.

Wortmann.—Beitrag zur Meningitis tuberc. im kindlichen Alter. *Jahrb. f. Kinderheilk.*, 1883, N. F., xx, 300.

Weintraud.—Pathogenese der Herdsymptome bei tuberc. Meningitis. *Zeitsch. f. kl. Medicin*, xxvi, 1894, p. 258.

Weigert.—Zur Lehre von Tuberculose und von verwandten Erkrankungen. *Virchow's Arch.*, Bd. lxxvii, p. 269, 1879.

Weigert.—Ueber Venentuberkel u. ihre Beziehungen zur Tuberkulösen Blutinfektion. *Virchow's Arch.*, Bd. lxxviii, p. 371, 1882.

Ziegler.—Spec. Path. Anatomie, 1895, p. 65.

