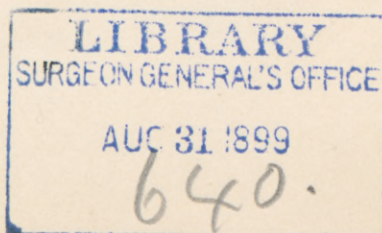


FURTHER OBSERVATIONS REGARDING THE
USE OF THE BONE-CLAMP IN UNUNITED
FRACTURES, FRACTURES WITH MALUNION,
AND RECENT FRACTURES WITH A TEN-
DENCY TO DISPLACEMENT.

By CLAYTON PARKHILL, M.D.,

OF DENVER, COL.

IN the history of our profession a very important chapter has been devoted to the fracture of bones. No subject, perhaps, has received more attention. No department of our art has demanded a more ready and accurate anatomical knowledge, or such finished mechanical skill. No surgeon, however accomplished, but has met with cases the treatment of which has taxed his ability to the utmost, and few with any extended experience, but have left monuments to their want of success. Many conditions, such as muscular action, interposition of tissue fragments, blood-clots, irregular, oblique, and multiple lines of fracture militate against accurate approximation of the fragments in fractures of the long bones. These may not only prevent adjustment in the reduction of the fractures, but also their sound and symmetrical union. Accurate adjustment and perfect fixation are the ends sought for in treatment. The numerous cases of pseudarthrosis and malunion show how inefficient the treatment has been. No result can be more mortifying to a surgeon than the failure to get union, and none can proclaim so loudly and persistently his lack of skill as a union with deformity. External appliances, in the way of splints and fixed dressings, such as plaster of Paris, etc., have formed the usual



procedure for the fixation of fractures with a tendency to displacement, until recent years. Even in compound fractures with large openings through the soft tissues, dependence has been placed to a very large extent upon these methods of treatment. Modern surgical technique should now be sufficiently perfect to warrant a bolder method when necessary, and the securing of accurate and permanent fixa-




FIG. 1.—Separate pieces of clamp.

tion of the fragments. In certain selected cases this should apply to simple as well as compound injuries.

The great number of mechanical appliances for securing fixation in cases of pseudarthrosis is sufficient in itself to show how imperfectly any of the methods have answered the purpose. These might, for convenience of study, be arranged in three classes.

In the first class we would put those which contemplate leaving the materials used for uniting the fragments perma-

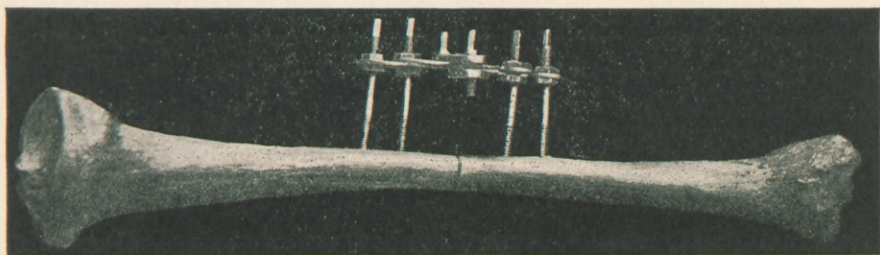


FIG. 2.—Side view of clamp in tibia.




FIG. 3.—Top view of clamp in tibia.

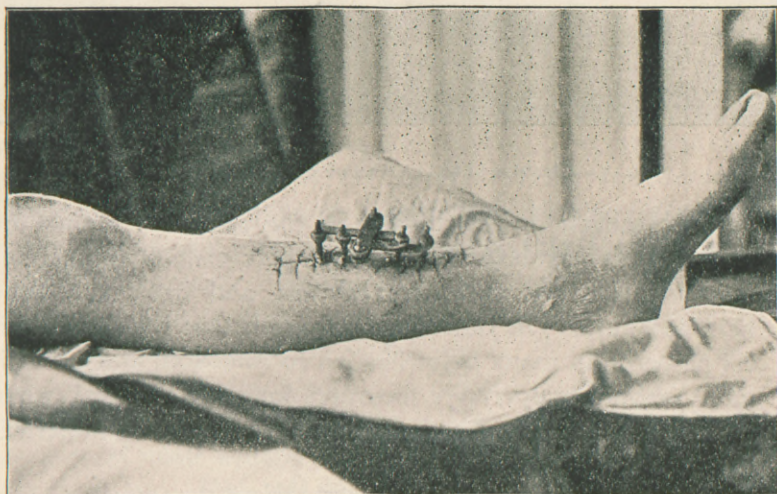

FIG. 4.—Appearance presented at first dressing, six weeks after application of clamp to a fracture of the tibia.

nently in place, either expecting them to become absorbed or ensheathed. In this category we would find the various forms of ligatures, such as catgut, kangaroo tendon, silk, and silver wire. The first objection that has been found to these is that they imperfectly fix the fragments, and dependence must be placed on external dressings. The second is that the non-absorbable materials not infrequently prove an irritant to the tissues, lowering their vitality, and leading to subsequent infection. This condition, in many cases, necessitates secondary operation for their removal, whether union be secured or not. In fact, save in exceptional cases, they act only as a stimulant to bone-production without either se-




FIG. 5.—Clamp applied to a fracture of the neck of the femur

curing fixation or retention. In the same list should be placed bone-ferrules; ivory, bone, and metallic plugs, for insertion into the medullary cavities, and ivory and bone nails and pins. The objection to these is that their mechanical presence in many cases has led to infection, and necessitated secondary operative measures for their removal, while at the same time the fixation of the fragments was imperfect and insecure.

In the second class should be placed those instruments which tend more accurately to fix the fragments, such as metallic nails and screws, and the instrument of Keetley,

which are of sufficient size to project beyond the soft tissues. These, if used in connection with the "stepped" method of resection of Langenbeck, making what is known in mechanics as the "fish joint," are sufficient to fix the fragments. When this method of resection is used, however, it is at the expense of the length of the bone, and if any other form of resection be used, lateral motion is not prevented, except by means of external appliances.

In the third class we would place the buried metallic screw, the metallic double staple of Gussenbauer, and the plate and screws of Agnew. All of these are open to the objection of necessitating secondary operation for their removal, even if union does take place.

I desire again to call attention to a method for the fixation of the fragments in recent fractures with a tendency to displacement, in ununited fractures after resection, and in fractures with malunion after resection, which I had the honor to bring before the profession in a paper read before the American Surgical Association at its last meeting in Washington. I desire to add a number of cases to those embodied in that report, together with the additional experience gained in their treatment. The instrument shown in Figs. 1, 2, and 3 is adapted for use in all parts of the femur, except the neck. The intermediate size is smaller and is adapted for the tibia, humerus, and patella. The smallest size is for use in the bones of the forearm, fibula, and clavicle. The instrument is simple in construction, easy and accurate of adjustment, and when properly used secures absolute fixation of the fragments. Neither lateral nor longitudinal motion is possible. It is of steel, heavily plated with silver, in order to secure the antiseptic action of this metal. It consists essentially of four shafts, each with a thread cut on the lower end, and also one near the upper end. The extreme upper end, however, is made square so that the shaft may be governed by a clock-key. Two sets of curved wing plates are attached to these shafts, the longer pair corresponding to the outer ones and the shorter pair to the inner. Each wing plate is

fixed to its shaft by two nuts running upon the upper thread, one above the plate and the other below, for accuracy of adjustment. When in position one wing plate overlies the other in each half of the instrument, and when clamped, the pair lie side by side. They are fastened together by a steel clamp with a screw in each end. These screws and shafts are controlled by the same clock-key, and the nuts by a small wrench. The parts composing the apparatus are shown in Fig. 1.

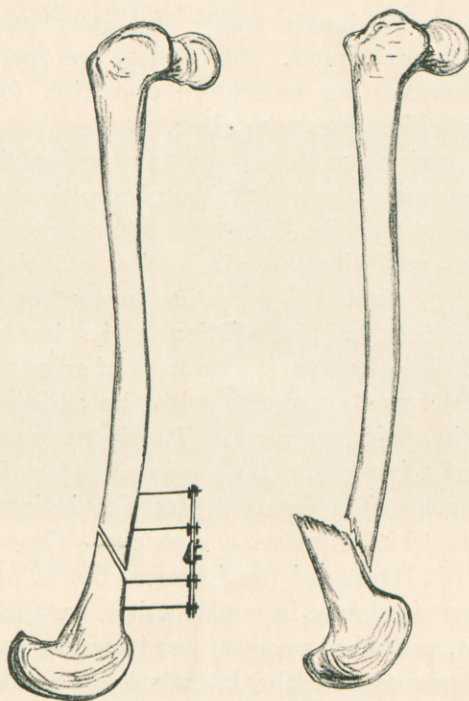


FIG. 6.—Pseudarthrosis of femur.

Any method of resection of the bony fragments which may be found desirable in the particular case may be used. The transverse is probably the most easy of execution and generally the most desirable. The periosteum may or may not be separated from the fragments. In the forearm and in the leg, if one bone is intact while its fellow demands operation, it should be shortened to a corresponding degree, and

clamped in a similar manner. Each fragment is drilled transversely to the longitudinal axis of the bone, and a small steel pin is thrust into the first hole, while the second is being drilled in order that they may be made parallel. The distance these holes should be from each other and from the ends of the fragments should be determined by the bone under operation, and the size of the clamp to be used. The

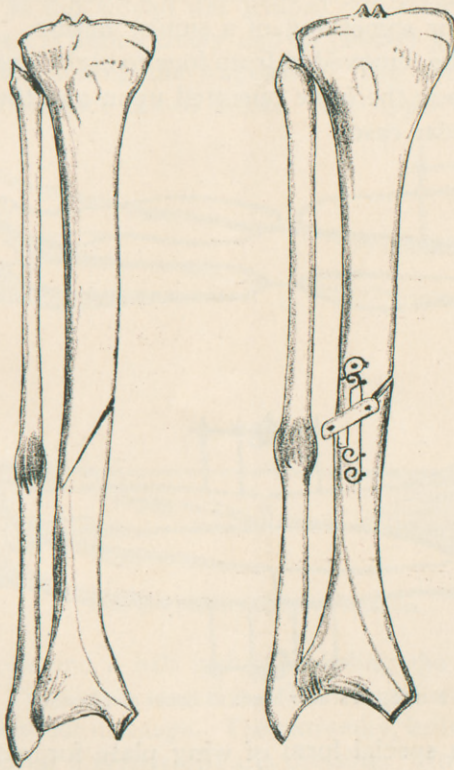


FIG. 7.—Fracture of leg with delayed union in tibia.

drill selected should be a trifle smaller than the shaft of the instrument, in order that the threads may take a firm hold on the bone. The shafts are screwed in place by means of the clock-key. This is more rapidly accomplished by means of the clock-key attachment fitted to a Langenbeck brace. The shafts being in place, their corresponding wing plates are

adjusted and fixed by means of their nuts. While the fragments are held in accurate apposition the wing plates are clamped together. The instrument is long enough to project through the incision in the soft tissues, in order to allow for the accurate suturing of the wound between the shafts and also for the interposition of a dressing. When possible the wound should be sutured without drainage. The part operated upon should be enclosed in a fixed dressing of plaster of Paris, or something of a similar nature. The instrument should be removed in from four to eight weeks (Fig. 4), depending upon the bone operated upon and the conditions of the particular case.

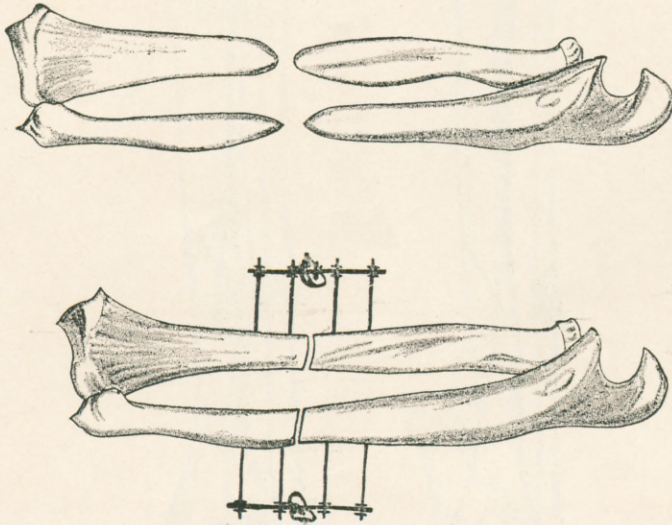


FIG. 8.—Pseudarthrosis of bones of forearm.

I made a special form of wing plate for patellar cases, but find it is unnecessary. By reversing one wing plate in each half of the instrument adapted for the humerus and clamping the plates longitudinally while the shafts are inserted in the form of a quadrangle every indication is met.

I have also a special form of clamp which I believe will be useful in fractures of the neck of the femur. (Fig. 5.) It has not been tried, however. It would seem to fix the head of the bone more accurately than any other instrument.

The following is a brief abstract of the histories of the cases upon which this instrument has been used.

CASE I.—(Operator, Parkhill.)—W. S., aged nineteen years, was sent from Walsenburg to St. Luke's Hospital, Denver, November 20, 1894. Pseudarthrosis of the right humerus as the result of a gunshot fracture eleven months previous. An open infected wound communicated with the upper fragment. On November 22 this wound was scraped out, removing all the infected tissue. It healed kindly, and on January 3, 1895, the clamp was used for uniting the fragments. The bones were found separated a distance of two inches. The upper fragment had a

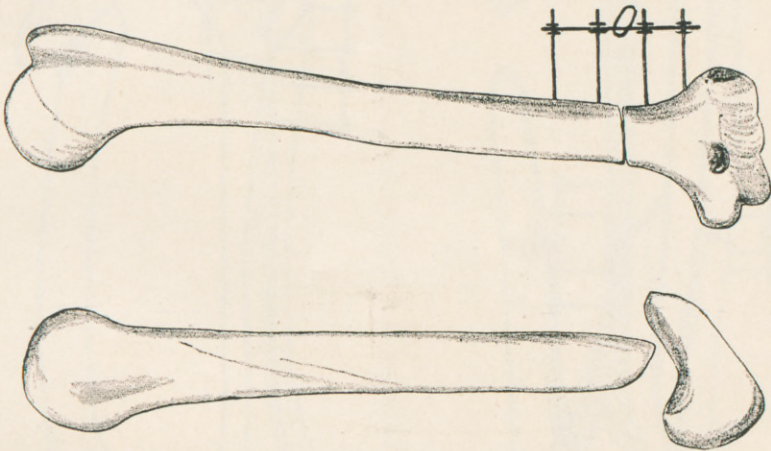


FIG. 9.—Pseudarthrosis of humerus.

length of one and a half inches, including the head, and was very soft. Transverse resection. The wound was closed about the clamp without drainage. The extremity, including the chest, was enclosed in a plaster-of-Paris dressing. No reaction. The dressing was removed February 7, 1895, when the wound was entirely healed. No infection. The clamp screws were lifted out without force. The sutures were removed. A dressing and cast applied. This was removed at the end of four weeks. Perfect union was observed.

CASE II.—(Operator, Parkhill.)—M. M., aged forty years, was sent from Victor, Col. Pseudarthrosis of nine months' standing, at the junction of the lower and middle thirds of the right

femur. There was great deformity with retrodisplacement of the lower fragment, customary in such fractures. Operated July 7, 1896. An anterior section of the soft tissues showed the lower end of the upper fragment resting upon the anterior surface of the lower. No attempt at osseous union. A large amount of fibrous tissue was removed with the scissors. The oblique ends of the fragments were freshened by means of the rongeur and Volkmann spoon. A large size femur clamp was applied.

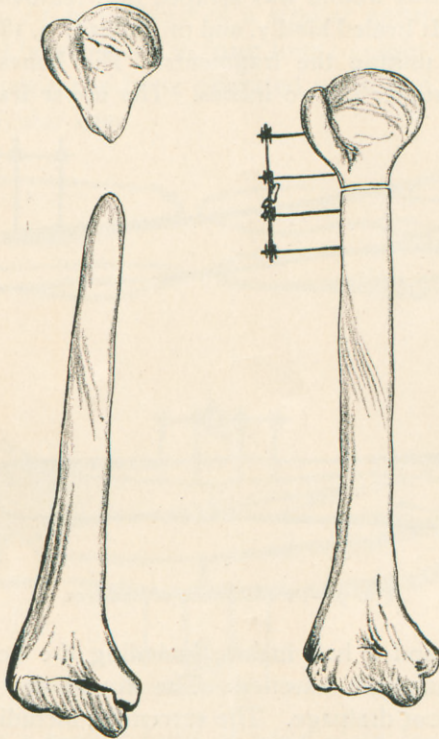


FIG. 10.—Pseudarthrosis of humerus.

Wound sutured about clamp without drainage. Sterilized dressing applied, and extremity enclosed in plaster of Paris. No reaction from operation. Dressing removed at the end of eight weeks. Perfect union of fragments. No infection of wound. Small dressing applied and plaster-of-Paris splint for three weeks longer. Present condition: Perfectly useful extremity.

CASE III.—(Operator, Parkhill. Delayed union.)—Dr. S. J., aged twenty-six years, on July 1, 1896, suffered oblique fracture

of both bones of the leg, at the junction of the lower and middle third, in a run-away accident. Temporary dressing in a fracture-box. Later, when the swelling had subsided, in plaster of Paris. At the end of six weeks some evidence of union, but far from perfect. Very impatient to secure union and get about his work. Operated August 15. Considerable amount of new osseous

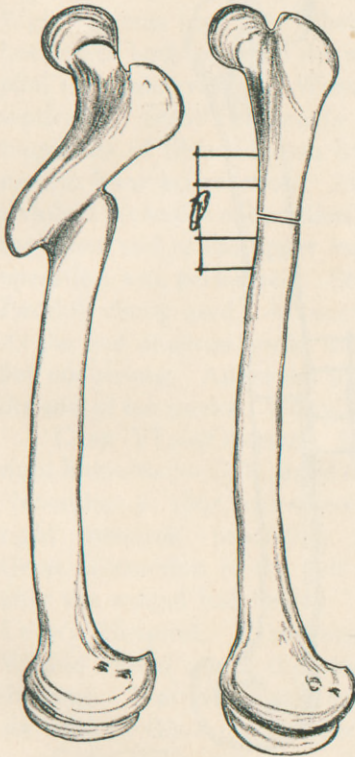


FIG. 11.—Malunion of femur.

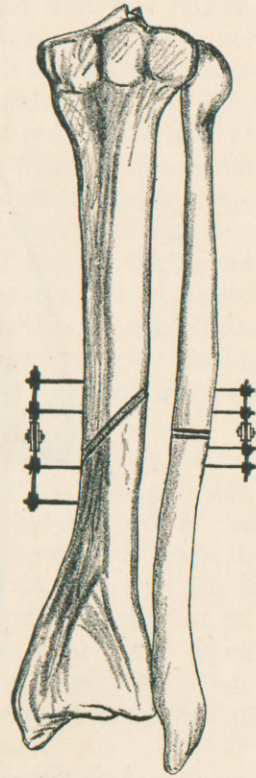


FIG. 12.—Nonunion of fracture of tibia; resection of fibula.

tissue filling the gap between the fragments. Also some fibrous tissue. Latter removed with a Volkmann spoon. Fragments drawn into accurate apposition and secured by a clamp. Wound sutured about clamp without drainage. Antiseptic dressing. Leg enclosed in plaster of Paris. No reaction. Clamp removed at the end of five weeks. No infection. Perfect union. Antiseptic dressing applied. Was given crutches. Perfect result at this time.

CASE IV.—(Operator, Parkhill.)—A. S., aged twenty-three years. Pseudarthrosis of both bones of the forearm as the result of a gunshot injury received in Utah, eight months previous. Sent to operator from Aspen, Col. Admitted to St. Luke's Hospital, August 12, 1896. Operated August 14. Fracture in the

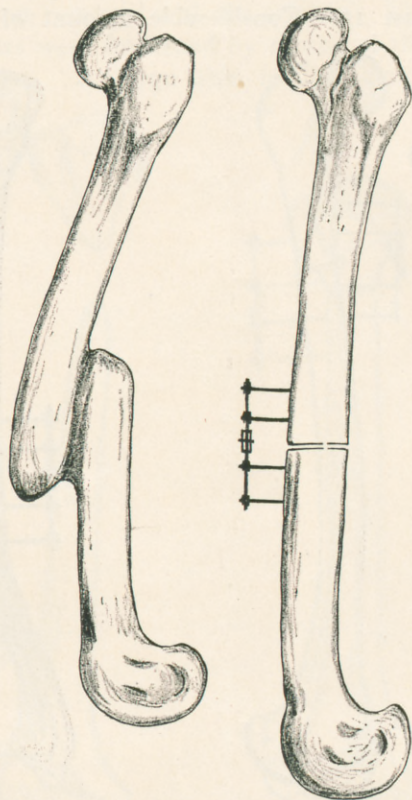


FIG. 13.—Malunion of fracture of femur.

middle of the forearm. Fragments separated about one inch. Large amount of fibrous tissue between the bones. Transverse resection of all the fragments so as to secure a symmetrical forearm. A small clamp used for each bone. Wound sutured about clamp without drainage. Antiseptic dressing applied. The forearm enclosed in plaster-of-Paris splint. No reaction. Dressing removed at the end of six weeks. Clamps taken out. No infection. Good union of both bones. Small antiseptic dressing applied. Forearm placed in anterior metallic splint. When seen,

two months later, had regained considerable amount of motion in the fingers, and the hand promised to be a very useful one.

CASE V.—(Operator, Mager. Recent fracture with a tendency to displacement.)—A. D., aged thirty-two years, a traveling salesman. Steady drinker for some years. On December 24, 1895, while driving in the mountains, the horses became frightened and ran away. He was thrown from the buggy. Right leg was caught in wheel, causing compound comminuted fracture of both bones in the middle third. Admitted to the hospital the same evening. Wound cleansed mechanically and antiseptically. Small fragments of bone removed. Resection of fragments of tibia. Union by silver wire. Aside from normal aseptic fever no reaction. At the end of a week, during sleep, a violent muscular contraction broke the wire and again fractured the lower end of the upper fragment. On January 5 the second operation was performed. Second resection of upper fragment. Parkhill clamp used. Antiseptic dressing. Plaster-of-Paris cast. At the end of seven weeks the dressings were removed. Union, but not strong. Antiseptic dressing reapplied. Perfect union at the end of ten weeks. Useful extremity.

CASE VI.—(Operator, McNaught. Pseudarthrosis of the right humerus.)—G. B., aged thirty-five years. Railroad accident. November 2, 1895, car-wheel passed over upper fourth of the right humerus, producing compound comminuted fracture. Great destruction of the soft tissues and bone. Lack of union after the wound had healed. Operated February 2, 1897, at St. Luke's Hospital. Transverse section. Parkhill clamp used. Wound closed about the clamp without drainage. Antiseptic dressing. Plaster-of-Paris cast. Clamp removed at the end of six weeks. Good union, with useful extremity.

CASE VII.—(Operator, McNaught. Pseudarthrosis of the left humerus one and a half inches from elbow-joint.)—H. H., aged sixty years. Operated May 21, 1896. Parkhill clamp used. At the end of six weeks the clamp was removed. Good union. Discharged from hospital. The night following discharge the patient, in a drunken spree, refractured the arm. The following November again presented himself for treatment, requesting that the same instrument be used. Clamp applied, and at the end of six weeks perfect union was obtained.

CASE VIII.—(Operator, Freeman. Pseudarthrosis of the left humerus.)—A. C., aged thirty-five years. Eighteen months

previous to operation received comminuted fracture of the left humerus at the junction of the upper and middle thirds. In May, 1896, admitted to Arapahoe County Hospital, Denver. Fibrous union and a small sinus. Operated by surgeon on duty.

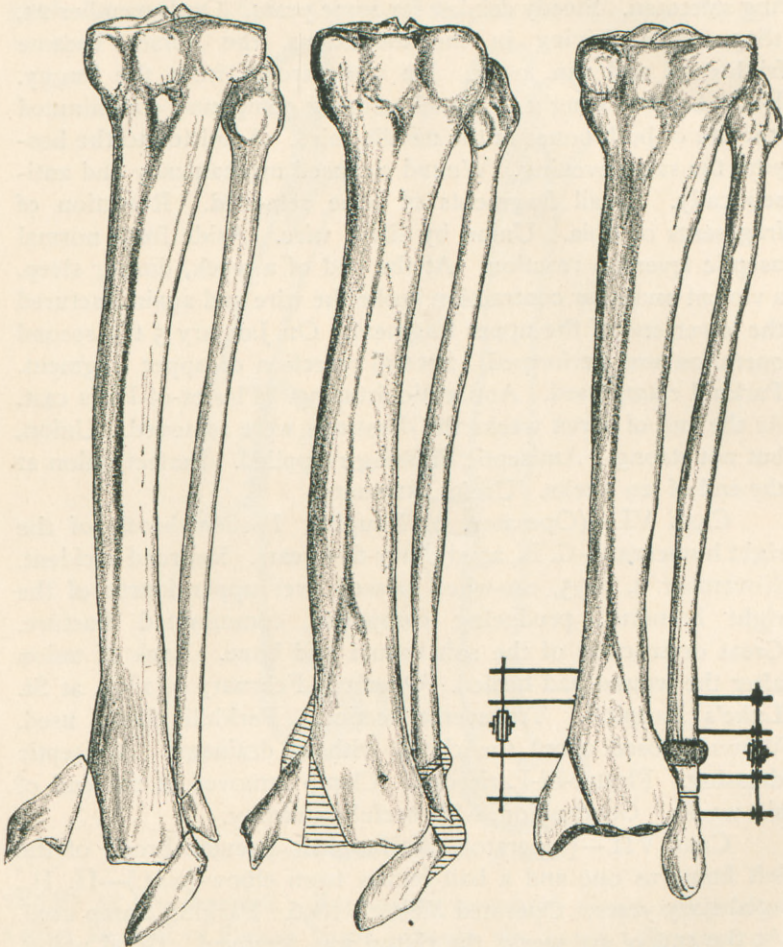


FIG. 14.—Fractures of bones of leg, involving ankle-joint, united in deformity.

Resection of ends and suture by silver wire. Failure. Operated September 30, 1896. Ends again resected and united by Parkhill clamp. Upper fragment of shaft not more than one-quarter of an inch in length. Practically nothing but head of bone remaining.

Clamp applied, size for femur instead of humerus, so that application was difficult. Much oozing from the wound. Impossible to entirely check it. This necessitated frequent changes of dressing for considerable length of time. Infection lasting about three weeks. Clamp removed November 3. Perfect union with motion at shoulder-joint. Patient could place hand to top of head. Useful extremity.

CASE IX.—(Operator, Parkhill.)—W. M., aged thirteen years. Malunion of the left femur of about ten months' standing, fracture having occurred at junction of upper with middle third. Upper fragment tilted upward and outward. Lower fragment united with it at an angle producing great deformity and much shortening. Operated February 5, 1897. Anterior incision. Fragments separated with difficulty by means of saw and chisel. Transverse section of ends. Extremity extended, and a gain in length secured amounting to an inch or an inch and a half. Clamp applied. Wound sutured about instrument without drainage. Antiseptic dressing and entire extremity and pelvis enclosed in plaster cast. Dressing removed at the end of seven weeks. Perfect union and perfect symmetry of bone. No infection. A light dressing with external and posterior light splint. Dressing taken off at end of nine weeks and splints removed. Was given crutches and is now walking on extremity.

CASE X.—(Operator, Parkhill. Pseudarthrosis.)—O. O., aged twenty-eight years, has led a dissipated life and been a more or less heavy drinker until two years ago, when he contracted syphilis. Since that time he has been a periodical drinker. He has had practically no treatment for syphilis. On the 30th of March, 1897, he sustained a fracture of the left tibia at the junction of the lower with the middle third, in a railroad accident in the State of Washington. Non-union. First operation June 18, 1897. Oblique fracture from above downward and forward. Space between the fractured ends filled with dense fibrous tissue. Fragments freshened with scissors and Volkmann spoon. Clamped. At the end of six weeks the instrument was removed. No union. Operated the second time on September 28, 1897. Resection of the tibial fragments with saw in the line of fracture; corresponding portion of the fibula removed. Clamp adjusted in each bone. Wound sutured without drainage. Extremity enclosed in a plaster cast. First dressing made and clamp removed

at the end of seven weeks. Perfect union of both bones. No infection.

CASE XI.—(Operator, Parkhill. Malunion.)—R. H., a healthy miner who had been a hard drinker. Left femur fractured in the middle third by the kick of a man posteriorly, on May 7, 1897, at Creede, Col. Treated in that city. Was in splint five

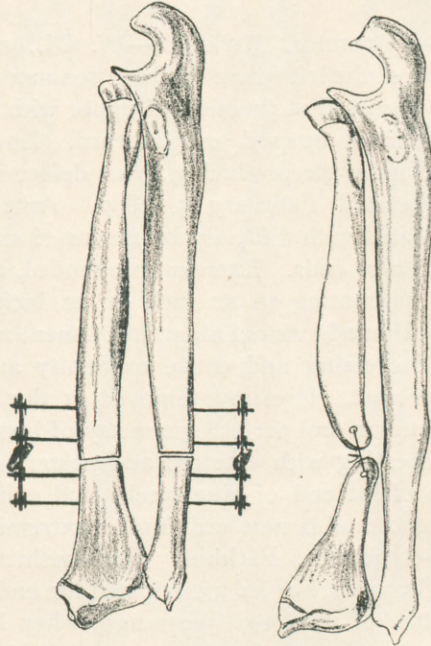


FIG. 15.—Pseudarthrosis of radius.

weeks. On presenting himself, in October, union was firm but with deformity, the upper fragment overlying the lower and overriding at least three inches. The thigh bowed anteriorly and externally, crippling him seriously. Operated October 29. Anterior incision. Fragments separated with great difficulty, by means of a chisel and mallet. Ends resected transversely. Strong extension made on extremity and a gain of at least two inches in length was secured. Clamped in place. Extremity including the pelvis enclosed in an external dressing of plaster of Paris. Wound was dressed at the end of a month. Light grade of infection found, probably due to imperfect preparation of the thigh for operation. Instrument removed at the end of forty days. Good union secured without deformity.

CASE XII.—(Operator, Parkhill. Malunion.)—Mrs. S., aged forty-six. Fracture of both bones of the left leg by a fall from a wagon, August 3, 1897. Treated at her home at Buffalo Park, Col. In splint three weeks. On presenting herself to operator, union was found with great deformity, the foot being inverted and resting upon its outer border. Operated November 6, 1897. Incision on the inner surface of the tibia discovered that there had been an oblique fracture from below upward and inward, splitting off the inner malleolus with a small portion of the adjoining articular surface of the tibia, the fracture line extending upward to a distance of about one and a half inches. The fracture united with great deformity. An incision over the fibular side of the ankle showed a multiple fracture of the lower end of the fibula. These fractures had united, but with the outer malleolus displaced strongly inward. Resection of each bone, and replacement of fragment in normal position. A clamp used for each bone. Three shafts of each clamp fixed in the upper fragment and one in the lower. Sutured without drainage. Extremity enclosed in external dressing of plaster of Paris. Clamp removed December 18, 1897. Good union with perfect symmetry. No infection.

CASE XIII.—(Operator, Parkhill. Pseudarthrosis.)—C. McC., aged fifty-eight. Fracture of right radius at junction of the lower with the middle third March 1, 1897. Treated in splints at Cripple Creek, Col. Non-union. Operated in Cripple Creek in June, 1897. Fragments wired with silver. Failed to unite. Presented himself to operator early in November with pseudarthrosis. Operated November 13. Incision over the outer margin of the radius. Fragments resected transversely. Incision over the inner margin of the ulna, and removal of three-fourths of an inch of bone, making a symmetrical forearm. Clamp used in each bone. Sutured without drainage. Extremity enclosed in external dressing of plaster of Paris, reaching above the elbow-joint and fixing the forearm at a right angle. Clamp removed December 28. Good union with perfect symmetry.

CASE XIV.—(Operator, McNaught. Recent fracture with displacement.)—W. W., aged thirty. Received a fracture of the patella while mounting a moving train, September 11, 1897. The fracture was probably due to muscular action, as he recollects no injury. The fracture was transverse. He was treated on an

Agnew splint, and apparently good union was obtained. Was discharged from the hospital on December 2, 1897. Slipped on the icy pavement the same day and refractured the patella. Returned to the hospital and was operated December 10. The fragments were found separated about one inch, the fractured surfaces freshened by the Volkmann spoon and cutting forceps. The Parkhill clamp applied, the shafts being inserted into the fragments in the form of a quadrangle. Perfect apposition. Wound closed without drainage. Progress until the present time uneventful. Good union obtained.

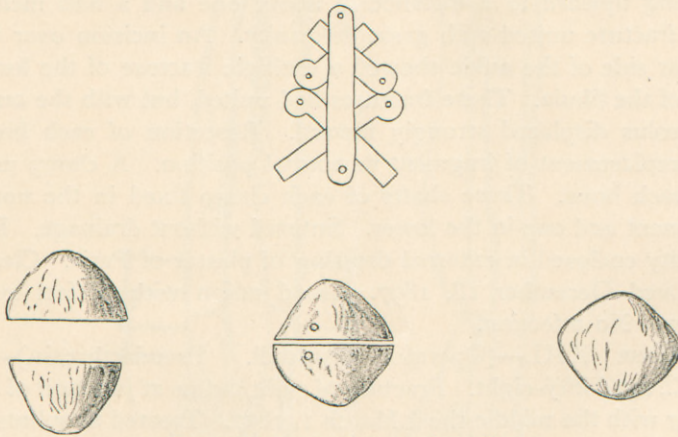


FIG. 16.—Recent fracture of patella.

We claim for this instrument:

- (1) That union has been secured in every case in which it has been used, as against 56 per cent. of cures by all mechanical means, according to the statistics of Bruns and Gurlt.
- (2) That it is easily and accurately adjusted.
- (3) That it prevents both longitudinal and lateral motion between the fragments.
- (4) That the presence of the shafts in the bone stimulates the production of osseous tissue.
- (5) That nothing is left in the tissue that might reduce their vitality or lead to pain and infection.
- (6) That no secondary operation is necessitated.

