



CARNOCHAN (J. M.)

Remarks on double Capital
amputations x x x x x





REMARKS

ON

DOUBLE CAPITAL AMPUTATIONS,

WITH TWO CASES AND PLATES.

By **J. M. GARNOCHAN, M. D.**

Professor of the Principles and Operations of Surgery in the New-York Medical College, Surgeon to the State Emigrants' Hospital, &c.

[From the New-York Medical Gazette, April, 1853.]

The Surgeon is at times called upon to perform more amputations than one upon the same individual. Cases of this kind are met with on the field of battle, but they may also occur in civil practice. It is not uncommon for two or more limbs to be injured by accidents occurring on railways; the passage of the wheels of any heavy vehicle may implicate more than one limb beyond the reach of curative art; mortification, either spontaneous or traumatic, may bring about the same result; as may also strumous or other constitutional disorders, affecting many of the joints simultaneously, or attacking the tissues of the abdominal or thoracic members on both sides of the body. Under such circumstances, life can only be saved by primary or secondary amputation of the diseased or mutilated limbs.

I shall here record two successful cases of double amputation of the inferior extremity, where I pursued a plan of operating, differing, as far as I know, from any heretofore practised. In one case, I severed both legs below the knee, in immediate succession; and then with a tenaculum in each hand, I proceeded to pick up the bleeding vessels, right and left; the ligatures being simultaneously applied on either side by my assistants. In the other case, I performed Hey's operation on the foot of one side, and Chopart's operation on that of the other, following the same plan.


In double amputations, the constitutional effect of the succession

of one shock upon another is necessarily a cause of anxious solicitude. Pain, when prolonged beyond a certain point, will exhaust the vital energies of the system, and may actually be, singly, the cause of death. To avoid this possibly fatal prostration of the nervous energy, and enable the patient to rally from the shock of the first amputation, Bèclard and Dupuytren advise that a certain interval of time should be allowed to elapse before the second is performed. Thus Dupuytren, in a case of double amputation below the knee, delayed the removal of the second leg fully one half hour. It is obvious, however, that there must be a limit beyond which delay would be improper, and that, therefore, the occurrence of reaction, which itself cannot be predicated with certainty, is not a criterion to be relied upon, for the guidance of the Surgeon in proceeding to the amputation of the second limb.

The introduction of Anæsthetic agents into medicine has modified, in many instances, the several steps of surgical operations. In conditions requiring double amputations of the members, they must now be regarded as especially serviceable. I have had extensive opportunities of observing the effects of chloroform in operations, and am convinced that the time during which a person can be safely subjected to its influence is a question for grave consideration. Chloroform evidently acts primarily upon the cerebro-spinal system of nerves, but it may reach that part of the nervous system which presides over the functions of organic life and so cause paralysis of the heart and death.

Where two members have to be removed, if the operations are performed in the ordinary manner, a double dose of chloroform must be administered. So far as the anæsthetic agent is concerned, the patient is thus subjected to a risk twice as great as in single amputations. Impressed by these considerations, I propose to convert the double operation into one, by severing the limbs in immediate succession, as soon as the anæsthetic influence is produced. By this proceeding, the patient need not be in the anæsthetic state, longer than a few seconds. In the cases referred to in this paper, thirty-five seconds, was the time I occupied in removing the two limbs, at the place of election below the knee-joint; sixty-one, in severing the left foot by Hey's operation, and the right by Chopart's operation; as noted by Dr. Francis King, of North Carolina, who was present.

I subjoin the relation of the two cases upon which I operated, and of which a record was kept by the House Surgeons, Drs. A. K. Smith and Thompson. The wood cuts will show the character and appearance of the stumps, when cicatrization was completed.



Double amputation of the leg at the place of election.

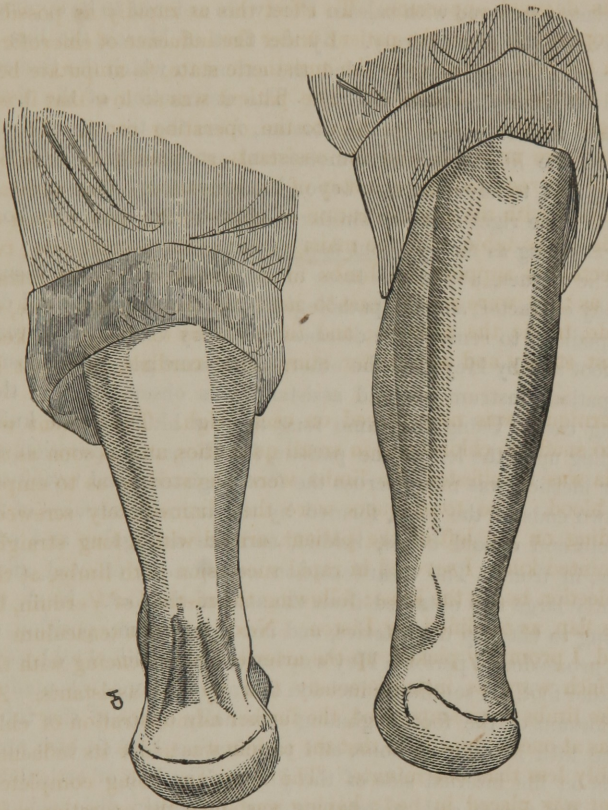
Case 1. Henry Ottling, tanner, German by birth æt: 39, entered the State Emigrants' Hospital, 14th February, 1851. Some days prior to his admission, he had been exposed to extreme cold and wet, the result of which was sphacelus of both legs. He was brought from Catskill, where he had been employed, in that condition, to the Hospital, almost in a dying state; the mortification extending half way up, in front on either leg, and slanting backward and downward to the lower part of the calf. When first seen after his admission, he was laboring under extreme prostration, delirium, with a pulse feeble and scarcely to be counted, hiccough, cold surface, and the other constitutional symptoms, denoting the presence of extensive gangrene. Under such circumstances, it was not thought expedient to remove the diseased limb immediately. Cordials and stimulants, were pre-

scribed; and the system was supported by nourishment, as far as the condition of the stomach would allow. On the fourth day, the constitutional symptoms became more favorable; the delirium had abated, and the system had rallied. At this juncture, the disposition to the extension of gangrene having ceased, the removal of the sphacelated limbs was deemed opportune. To effect this as rapidly as possible, it was proposed to place the patient under the influence of chloroform, and upon the first evidences of the anæsthetic state, to amputate both limbs, in immediate succession. The patient was so low that it was not thought proper to remove him to the operating room. The instruments were arranged and the assistants so placed as to afford readily the aid required, at each step of the operation. One assistant was entrusted with the administration of chloroform; two, placed on either side of the table, with the management of the tourniquets; two were directed to support the limbs to be removed; two to retract the flaps as they were made; one to hand the instruments; one, on either side, to tie the arteries; and three others to sponge, to keep the patient steady and administer stimulating cordials, as might be needed.

A tourniquet was now placed on each thigh. The patient was allowed to snuff the chloroform in small quantities, and as soon as the anæsthesia was manifested, the limbs were elevated so as to empty them of blood. The tourniquets were then immediately screwed; and, standing on the left of the patient, armed with a long straight-backed pointed knife, I severed in rapid succession both limbs, at the place of election below the knee; following the method of Verduin, by the single flap, as modified by Liston. Next, taking a tenaculum in each hand, I promptly picked up the arteries; commencing with the larger, which were as instantaneously tied by the assistants. As soon as the limbs were amputated, the further administration of chloroform was at once stopped; so that the patient was under its influence, considerably less than one minute. The dressings being completed, the patient was placed in bed; having sustained the operation well, without suffering much additional prostration or losing more than a few ounces of blood.

During the following two weeks, cordials, opiates, tonics and nourishment were administered, carefully and assiduously, and at their expiration, the prospects of the patient began to brighten. The pulse became less frequent and fuller; food was borne better and relished; the nervous system became more tranquil; and the vital energies, generally, showed signs of recuperation. From this time forward, with the exception of a slight transient diarrhœa, no complica-

tion, local or general, interfered with the healing and cicatrization of the stumps. Both progressed nearly equally towards cure; and on the forty-second day after the operation, the patient was in a condition to be discharged from the Hospital.



Double amputation.

Hey's operation.

Chopart's operation.

Case 2. In the following case of double amputation, Hey's operation was performed upon one foot, and Chopart's, upon the other.—Vide plates.

Pat. Henly, laborer, æt: 25, was admitted to the Emigrants' Hospital, 10th February, 1852. Four days previous to his admission, both of his feet were attacked by sphacelus, induced by exposure, while working on the canal near Trenton, New Jersey. He was

in a condition of great prostration, and exhibited the constitutional symptoms usually accompanying gangrene. The feet and adjacent parts were discolored and tumefied beyond the ankle. The extent to which the sphacelus would extend could not be accurately determined.

The patient was put upon appropriate constitutional remedies, and cataplasms smeared with balsam Peru were ordered to be applied, so as to envelop the feet entirely. By the first of March, the line of demarcation formed, and revealed the extent to which the tissues were deprived wholly of their vitality. The destruction of the tissues of the left foot extended, on the dorsum, from the toes to half an inch beyond the line of the tarso-metatarsal articulation, and on the sole of the foot, to about an inch beyond the metatarso-phalangeal articulation. The right foot was similarly affected; the sphacelus, however, not extending as far by about half an inch.

The tissues, above the lines of demarcation, having resumed a healthy character, and the pathological condition permitting, I deemed it expedient to remove the diseased parts by Chopart's operation on one foot and by Hey's, on the other. The same general disposition of the patient, instruments and assistants was observed as in the preceding case. Using the same long narrow blunt-backed knife, and standing upon the left of the patient, for Chopart's operation, a semilunar incision was made across the foot, beginning and terminating at the two ends of the joint, formed by the articular surfaces of the calcaneum and cuboid bones, behind, and the astragalus and scaphoid bones, in front. The disarticulation was speedily effected, and a sufficiently large flap obtained from the sole of the foot. Next, without waiting to take up the arteries, and not changing my position, I forthwith proceeded to perform Hey's operation, as modified by Lisfranc, on the other foot. A semilunar incision down to the bones was made across the dorsum of the foot, beginning externally opposite the tuberosity of the fifth metatarsal bone, and terminating half an inch more forwards on the internal side of the joint. The line of articulation between the tarsus and metatarsus was promptly disjoined, and the operation finished, by forming the flap from the plantar aspect of the foot.

The diseased parts once removed, the administration of chloroform was discontinued. The arteries were now picked up by tenacula, held in either hand, and tied by the assistants. The tourniquets were then removed, and the dressings for both stumps being completed, the patient was conveyed to bed. From this time, the healing process went on kindly and without complication; and in six weeks after the operation the patient was able to walk about. It may be remarked

that the stump resulting from Hey's operation, became entirely cicatrized one week earlier than that resulting from Chopart's operation. The patient is now pursuing his vocation as a ferryman on the East River.

