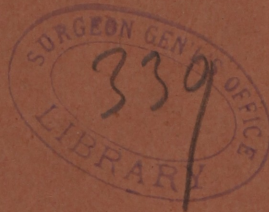


2
E/173
Warren (J. Mason)

WARREN (J.M.)

HYPERTROPHIC ELONGATION
OF THE
CERVIX UTERI.

By J. Mason Warren, M.D.



6 A A M

HYPERTROPHIC ELONGATION OF THE CERVIX UTERI OF TWENTY-SIX YEARS' STANDING,

WITH


PROJECTION OF THE ENLARGED OS BEYOND EXTERNAL ORGANS; ULCERATION; HEMORRHAGE; OPERATION, FOLLOWED BY COMPLETE CURE.

By J. MASON WARREN, M. D.,

SURGEON AT MASSACHUSETTS GENERAL HOSPITAL.

A VERY elaborate work, with plates, has lately been published in Paris, by M. Huguier, on a disease described under the above title, showing its distinction from simple engorgement and prolapsus of the uterus, with which it has heretofore been confounded. A most remarkable case of this disease has been published in the *Boston Med. and Surg. Journal* of Dec. 4, 1862, by Henry A. Martin, M.D., Surgeon U. S. Volunteers. Other operations for this disease have been performed, in this country, by Dr. Gardner and Dr. Sims, but in none of their cases did the extent of the disease at all compare with that recorded by Dr. Martin. The following case came under my notice about a week after the record of the case of Dr. Martin had been made public. It fully sustains the anatomical description of the disease as given by Huguier in his very interesting and important work. It also shows how unsafe any surgical procedure would be, based on the idea of a simple enlargement of the os and cervix uteri, without taking into view the very remarkable displacements of other organs which occur in the course of the disease when it has proceeded so far as to be projected to any extent beyond the labia. I now proceed to the relation of the case.

Mrs. S., 56 years old, and of rather a delicate constitution, was married about 27 years ago; shortly after her marriage she took a long voyage, and suffered severely from sea-sickness, followed by a miscarriage which



was attended by some hemorrhage and followed by extreme prostration. About a year after these events she was confined with her first child after a tedious labour; this was followed by some prolapsus of the womb. During a subsequent pregnancy the prolapsus was relieved, but after the birth of the child it was reproduced in a greater degree than before, and from that time to the present, she may be said to have been continually suffering from her present affection. When I first saw her the os uteri was enlarged and projected between the external organs, irritating all the neighbouring parts, and giving rise to constant embarrassment in locomotion. The brain also, to a considerable extent, was sympathetically affected, and for a number of years she had been scarcely ever free from a sense of weight and pain in the head. Under the skilful care of Dr. Sims, of New York, after all other mechanical treatment had failed, she had a year of comparative comfort from the use of a gilt-winged pessary, which supported the uterus and prevented the external projection of the tumour. This, however, ultimately failed of its effect. For some months before I first attended her, she had been confined to her room, both from the irritation of the disease, causing great difficulty of progression, and from great debility, caused by repeated and severe hemorrhages from an ulcer of about the size of a quarter of a dollar, situated near the end of the tumour, and similar to the ulcerations noticed in such cases by M. Huguier. The tumour seemed to be of an erectile character, having periods of increase and diminution of size, the former state being accompanied by an effusion of blood from its face.

Being unwilling to operate on a case of this description out of town, and without having first fully investigated it, I advised her to come to Boston for treatment in a private room at the Mass. Gen. Hospital. The following was her condition at this time. She was quite pale and thin, and so feeble as scarcely to be able to move about the room. The tumour presented the following appearance. It was from three to four inches long, and about four inches in circumference at its extremity, and at its base covered by mucous membrane, which from long exposure had, to a certain extent, assumed the character of skin. On the under and back part of the tumour, near its end, was the opening of the os, into which the finger could be introduced to the extent of from two to three inches. A probe passed about two inches farther. At the base of the external tumour was the meatus urinarius. A catheter introduced into the bladder took a downward direction, and its point could be felt half way down the tumour. * Of course there was no cul-de-sac of the vagina in front, but behind the tumour the finger could be introduced to a depth of from two to three inches. On exploring the rectum by the touch, the finger could be hooked downwards into the peritoneal cul-de-sac, which was dragged down by the tumour to a distance of about two inches external to the cavity of the pelvis. The uterus could be felt, as a body, of about the thickness of the thumb, and an inch and a half long, in the natural position of that organ. It will be seen, from the above description, that by any operation for removing all the tumour which projected between the labia, about a third or a half of the bladder, and a considerable portion of the peritoneal cul-de-sac would be included in the incisions. The operation was performed as follows on the 18th of November, 1862, the patient being first prepared for it by two or three days' rest. Her physicians, Drs. Cox and Mack, of Salem, and Dr. Cabot, of Boston, giving efficient aid. The patient being etherized, the legs bent as in the operation for lithotomy, the extremity of the tumour was firmly seized by strong hooked forceps, and drawn down-

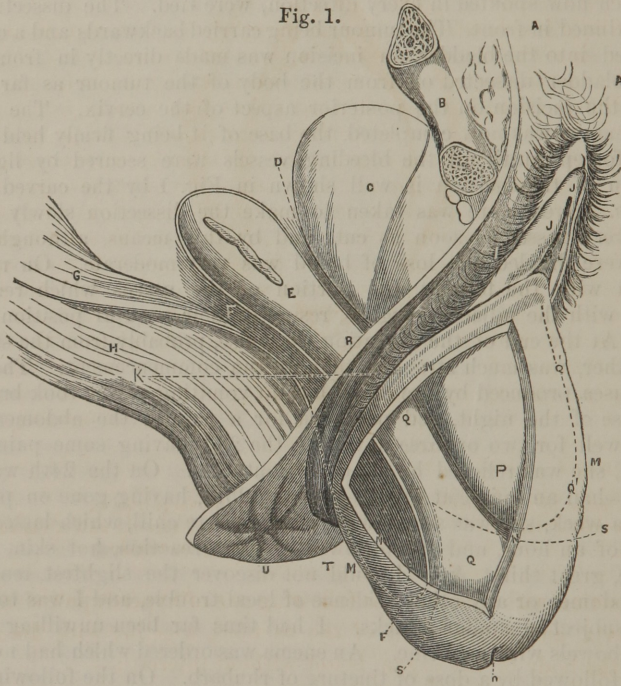
wards and forwards. An incision was made in the back part of the tumour about two inches from its extremity, and just in front of the peritoneal cul-de-sac, which was marked by the finger hooked down into it from the rectum. This investment being dissected backwards, the enlarged cervix was cut into about an inch higher up, until its cavity was opened. Large vessels, which now spouted in every direction, were tied. The dissection was now continued in front. The tumour being carried backwards and a catheter introduced into the bladder, an incision was made directly in front of it and the bladder dissected off from the body of the tumour as far as the level of the incision on the posterior aspect of the cervix. The section of the tumour was now completed, the base of it being firmly held by the hooked forceps until all the bleeding vessels were secured by ligatures. The form of the incision is well shown in Fig. 1 by the curved dotted lines s. s. Great care was taken to make the dissection slowly and to secure every vessel as soon as cut, and by this means, although many vessels were divided, the loss of blood was very moderate. On relaxing the hold with the forceps, the portion of the uterus which remained, together with the adjacent organs, resumed their natural position in the pelvis. At the end of the operation the pulse, probably from the stimulus of the ether, was much stronger than at the commencement. There was some nausea produced by the ether, but no vomiting. She took brandy in the course of the night, and paregoric for a pain in the abdomen. All went on well for two or three days; on the 23d, having some pain in the abdomen, she was relieved by a hot fomentation. On the 24th was comfortable—had an opiate at night. On the 25th, having gone on perfectly well for a week, she was seized with a very severe chill, which lasted three-quarters of an hour, and was followed by great reaction, hot skin, intense headache, great thirst, &c. I could not discover the slightest tenderness of the abdomen or any other evidence of local trouble, and I was told that she was subject to similar attacks. I had thus far been unwilling to disturb the bowels with medicine. An enema was ordered which had no effect, and was followed by a dose of tincture of rhubarb. On the following day, the 26th, she was wholly free from fever, and the medicine having not yet operated, a dose of infusion of rhubarb was given with the effect of producing two dejections. After this she began to take solid food. On the 1st of December she had another chill, which was relieved as before. An examination at this time, with the speculum, showed the surface, from which the tumour had been removed, contracted to the size of a quarter of a dollar; two or three ligatures which still adhered were taken away. About four weeks after the operation the patient was able to walk about, and was completely relieved of all irritation about the pelvic organs, which were now retained in their natural positions. The pain and feeling of weight in the head, which had oppressed her so long, had passed off as if a cloud had been swept away. She returned home about the middle of December, and I had the satisfaction of seeing her entirely cured about two months later. During the latter part of her stay at the hospital, she was kept on as full diet as she could bear, and porter and spirits were given freely, with the effect of relieving the very anæmic condition under which she laboured when she entered the house.

This case is interesting from the perfect cure of a complicated and rare disease of many years' duration, and from the operation being the only one, so far as I know, that has been done in Boston, and with the exception of

Dr. Martin's case, which has been already referred to, the only one done in this vicinity.

I have heard from this lady within a few days (Oct. 10, 1863), nearly eleven months after the operation, in a condition of almost perfect health.

Fig. 1.

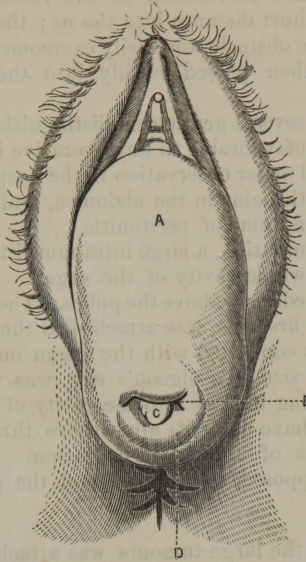


- A. Mons veneris.
- B. Right portion of symphysis pubis severed through obturator foramen.
- C. Upper portion of bladder lying behind the pubes.
- D. Anterior cul-de-sac of the peritoneum.
- E. Body of uterus.
- F. Posterior cul-de-sac of the peritoneum.
- G. Peritoneal coat of rectum forming posterior wall of the posterior cul-de-sac.
- H. Rectum.
- I and J. Labia majora and minora.
- K. Right genito-crural fold.
- L. Meatus urinarius.

- M, M. Anterior and posterior walls of vagina.
- N, N, N. Opening made through outer wall of tumour to show the relations of the parts within.
- O. Os uteri.
- P. Base of the bladder forming part of the tumour.
- Q, Q. Elongated and hypertrophied cervix uteri.
- Q', Q'. Outline of lower part of bladder.
- R. Body of uterus also elongated.
- S, S. Dotted line showing the course of the incisions.
- T. Perineum.
- U. Anus.

The accompanying wood-cuts (Figs. 1 and 2) are copied from the work of M. Huguier, and are as good a representation of the present case as if taken from the actual subject—with this exception, that in Fig. 2, which represents the front view of the tumour, the anterior lip of the os uteri projected considerably beyond the lower so as to hide the orifice. The ulceration described was on the lower and back part of the tumour near the end.

Fig. 2.



- A. Projection made by the bladder through the anterior wall of vagina.
 B. Os uteri.

- C. Mucous discharge from os.
 D. Posterior and superior wall of vagina brought down by the tumour.

In connection with this case, the following one of hypertrophic elongation of the cervix, and enlargement of the os uteri, together with fibrous tumours of the body of the organ, is not without interest:—

A widow lady, 48 years old, and the mother of one child, came under my care at the Massachusetts General Hospital on the 16th of May, 1863. Fifteen years ago she discovered a small tumour in the left side of the abdomen, which gradually increased in size, and was attended with a sensation of weight and bearing down, but without acute pain. Fourteen years ago she had a paralytic attack of the left side of the body, from which she partially recovered. Profuse flooding had occurred several times during the four or five months immediately preceding her admission to the hospital, and had materially diminished her strength. She experienced much difficulty in passing urine, a fact easily explained by the displacement of the uterus and surrounding organs.

She was a good deal emaciated, but had a fair pulse and was able to take some exercise out of doors every day. The abdomen was enlarged, and of a conical form, from the presence of a tumour of about twice the size of a cocoanut. An elongated tumour, nearly three inches long, and of about the same circumference, projected between the labia. This tumour, which might at first sight have been mistaken for a simple prolapsus of the vagina, consisted in reality of the elongated and hypertrophied cervix and os. The meatus urinarius opened upon the upper and front part of the tumour. The boundary between the tumour and the coats of the vagina was marked by wrinkles of the mucous membrane. A careful exploration of the abdo-

men disclosed two tumours, one above the other, which together filled the cavity of the pelvis, and encroached on the rectum. Simpson's sound could be passed but a short distance into the os; the finger was arrested at the os internum, but the obstacle was easily overcome by the use of a sponge tent, and the finger then passed readily into the small cavity of the organ.

A consultation with several gentlemen distinguished in the obstetric art resulted in a decision unfavourable to any operative interference.

The patient remained under observation in the hospital about a fortnight, when she was seized with pains in the abdomen, and died in the course of the next week, with symptoms of peritonitis.

On post-mortem examination, a large intra-mural tumour was discovered, obliterating nearly the whole cavity of the organ. This was the tumour which had been felt immediately above the pubes. The second tumour, which had been felt above the first one, was attached to the exterior wall, directly over the other, and was connected with the organ only by a small pedicle. A third tumour, of the size of a pigeon's egg, was found near the upper part of the cervix, making its way into the cavity of the uterus, and might probably, after a time, have made its appearance through the os, and thus have come within reach of a surgical operation. The external tumour proved, as had been supposed, to be the os and the greatly elongated and hypertrophied cervix.

The fact that one of the large tumours was attached to the uterus by a pedicle scarcely larger than a goose-quill, is interesting as showing how easily certain uterine tumours may be removed by the operation of hypogastric section. The external tumour, that is, the hypertrophied os and cervix, had there been no other disease to forbid it, might have been removed as in the case just related.

