

FENGER, (C.)

al

A

WITH COMPLIMENTS OF
CHRISTIAN FENGER,
269 LA SALLE AVENUE
CHICAGO.

NEW KOLPOPLASTIC

OPERATION FOR ATRESIA

OR

DEFECT OF THE VAGINA.

BY

CHRISTIAN FENGER, M.D.,
OF CHICAGO, ILLINOIS.



REPRINTED FROM THE

TRANSACTIONS OF THE AMERICAN SURGICAL ASSOCIATION,

MAY 14, 1887.

PHILADELPHIA:

WM. J. DORNAN, PRINTER.

1887.

A

NEW KOLPOPLASTIC

OPERATION FOR ATRESIA

OR

DEFECT OF THE VAGINA.

BY

CHRISTIAN FENGER, M.D.,
OF CHICAGO, ILLINOIS.



REPRINTED FROM THE
TRANSACTIONS OF THE AMERICAN SURGICAL ASSOCIATION,
MAY 14, 1887.

PHILADELPHIA:
WM. J. DORNAN, PRINTER.

1887.

A NEW KOLPOPLASTIC OPERATION FOR ATRESIA OR DEFECT OF THE VAGINA.

BY CHRISTIAN FENGER, M.D.,
OF CHICAGO, ILL.

WHEN an atresia of the vagina, whether congenital or caused by inflammation or injury, is somewhat extensive, the common experience has been that, although dilatation, even up to full size, is usually comparatively easy, it is difficult to keep the new-formed canal from retracting; the constant use of the glass plug for this purpose is such an inconvenience that the patient will most often get tired of its use, and leave it out whereby the atresia will recur.

Where the atresia is limited, forming as it does in some cases a thin perpendicular septum only, it requires but crucial incisions and a little subsequent dilatation. In such cases there is no difficulty, because there is mucous membrane enough to cover entirely the canal.

But in extensive atresias, where mucous membrane is wanting, it is, so to speak, contrary to the laws of physiology, that a canal formed by violence in uncovered connective tissue, should not retract. When such a canal is not covered with skin or mucous membrane, and not constantly kept open, either by mechanical appliances from without, or a constant evacuation of secretion from within, there is nothing to prevent the canal from ceasing to exist as such. This is the law for fistulous canals all over the body, and must hold good for a new-formed canal in the place of the vagina as well.

There are, however, many cases on record in which even extensive atresias of the vagina after gravidity have shown, at the time of delivery, a remarkable softening of the walls and dilata-

tion, so as not to cause the expected impediment to the delivery of the child. It is not unlikely that the succular and softened condition of the external genitals found toward the end of pregnancy is able not only to counteract the effects of the retraction but even to permit of a certain permanency of cure. Breisky remarks in this respect as follows:¹

“The artificial dilatation of more extensive stenosis in non-pregnant women by means of sponge tents, dilators, and other mechanical means, is usually partial and insufficient, and the success of only short duration. Amussat’s operation of rapid dilatation with blunt instruments, as the handle of the scalpel and the fingers, is not any more efficient.

The first to propose to obviate these difficulties was Heppner, of St. Petersburg, who, in 1872,² made the following proposal when operating for congenital absence of the vagina: he made an H-shaped incision at the place of entrance, and having loosened an anterior and posterior flap, and made a vaginal canal in the usual manner, by dilatation with blunt instruments, he turned the two flaps into the new-formed canal, and secured them in position with sutures. Heppner’s plan of operating has never had many followers, because the flap thus made must necessarily be too short for the more extensive defects of the vaginal canal.

Credé, in 1883,³ tried to remedy this difficulty by taking a sufficiently long and broad flap of skin from the labium majus (Fig. 1). In his introductory remarks he says: “It is remarkable how often it is reported that the result of the usual operation for atresia was nil, or insufficient.” In a case of acquired stenosis of the vagina caused by chronic ulcerative vaginitis—the usual method of blunt dilatation had been tried in vain by renowned gynecologists. Credé, therefore, decided on a plastic operation, as follows: he loosened the left labium majus from

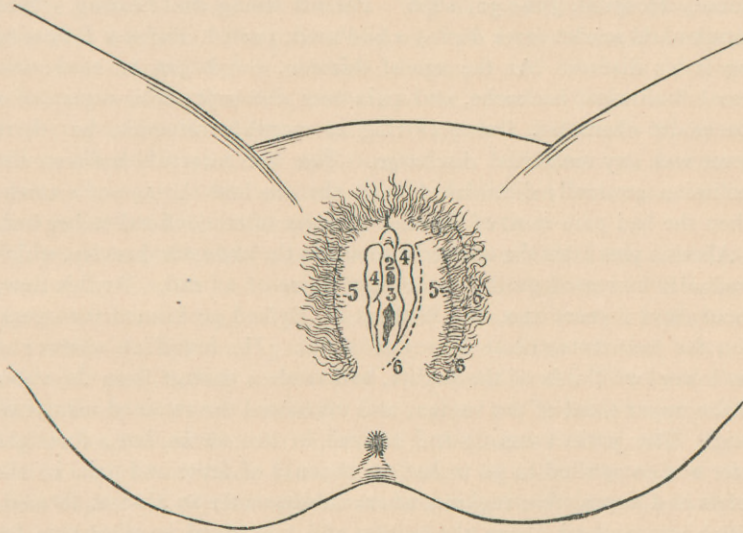
¹ Billroth and Lücke: Chirurgie, part Gynäkologie, die Krankheiten der Vagina, p. 57.

² Petersburger Medicinische Zeitschrift, 1872, p. 552.

³ Archiv für Gynäkologie, 1883; Bd. 22, H. 2, S. 229 (Heilung der Stenosis Vaginæ durch Einnähen eines Hautlappens).

above downward, leaving the base of the flap behind the vagina and in the left half of the perineum. The flap was 12 cm. long and 6 cm. broad, and when planted on the dilated vagina, and united by sutures to the cervix, it healed without difficulty and

FIG. I.



1. Clitoris; 2. Urethra; 3. Defective vagina; 4. Labia minora; 5. Labia majora; 6. Incision for flap, consisting of left labium majus and its surrounding skin on the outside, and of the skin of the perineum.

relieved the patient from her sufferings, consisting of dysmenorrhœa, pelvic pain, and a discharge which corroded the external genitals, so as to cause constant pain and irritation. He states that three weeks after the operation the vagina was sufficiently large and the patient suffered no pain, that the hairs on the flap implanted caused no disturbance, and the patient, who was fifty years of age, was restored to comfort.

Last year, a case of extensive atresia came under my care, in which the usual methods of treatment had proved entirely inefficient. I consequently had to resort to some plastic operation.

It appeared to me that even Credé's perfected method did not meet all the requirements, inasmuch as the use of a single flap

would not be likely to be sufficient to cover the walls of a canal like the vagina; further, it seemed to me desirable to have the vagina covered, not with skin, but with mucous membrane, if possible. To this end I operated in the following manner:

E. N., twenty-seven years of age, came under my care in Cook County Hospital, June 30, 1886. Parents living and healthy. Had measles and scarlet fever during childhood, partial deafness following the latter disease. At the age of thirteen, she began to have menstrual molimina, backache, and pain over the suprapubic region of a spasmodic character, and occurring at monthly intervals, but there never was any menstrual discharge. The free intervals between the molimina gradually diminished until she reached the age of sixteen, when she had pain most of the time and was often confined to her bed.

About a year later she noticed a tumor in the abdominal cavity, which gradually increased until it attained the size of a head. At this time, about eleven years ago, Dr. William H. Byford performed the operation for hæmatometra at Mercy Hospital. He found an absence of the lower two-thirds of the vagina, and made a passage from the vulva to the upper third of the vagina, and evacuated the retained menstrual fluid. The patient was up and around in two weeks, but a fortnight later was compelled to go to bed on account of fever and pain in the pelvis and suprapubic regions, where subsequently an abscess formed, which was opened above the pubes, and continued to discharge for several months. The menstrual flow did not appear until about a year and a half later, when it came on at regular intervals. It was always scanty and lasted only a few days.

For the last three months it has grown still more scanty, and the spasmodic pains have recurred in the back, down the thighs and in the pelvis so severely, that she is hardly able to get about. The last menstruation appeared in May, 1886, with hardly an appreciable flow.

Present condition.—Patient is healthy looking, well nourished, complains of pain in the pelvis and suprapubic region. Above the pubes on both sides are several nodular retracted cicatrices remaining from the abscess openings of years ago. Pressure at this point causes pain, but no distinct tumor can be felt. The external genital organs present the following conditions: The mons veneris and labia majora of normal shape and size covered with the usual amount of blonde hair. The clitoris is normally developed and so are the labia minora, the upper half of the latter being about a square inch in size. The exter-

nal orifice of the urethra is in the normal position about half an inch below the clitoris. Instead of the usual introitus into the vagina there is a shallow funnel-shaped depression consisting of hard cicatricial tissue with a smooth surface and not covered with mucous membrane. The apex of the funnel at the depth of one-half to three-quarters of an inch presents a narrow opening through which only a very fine probe can be passed in about two inches. Digital exploration in the rectum reveals at a depth of two to two and one-half inches a round body the size of an orange, slightly movable, the upper end of which the finger could not reach. Knowing nothing of the exact condition at the time of the operation for hæmatometra, I supposed this tumor to be the uterus dilated by retained menstrual blood. Diagnosis: Atresia of vagina from congenital absence of the latter and retraction of the passage formed at the operation for hæmatometra.

I performed the usual operation for atresia of this kind, as recommended by Emmet and almost all other gynecologists, in the following manner: On August 3d, the patient was anæsthetized, brought on the table in lithotomy position, the surroundings of the external genital organs having been shaved and disinfected. The hard cicatricial tissue at the entrance to the vagina was dissected away with scissors, a grooved director inserted in the narrow canal, and slight bilateral incisions made inward, sufficient to admit the end of the index finger. A urethral sound was now introduced into the bladder and held by an assistant and the left index finger introduced into the rectum. The opening into the vagina was now dilated with the right index finger, alternating with the metal handle of the scalpel. When the dilatation had extended inward about two inches, two ounces of pale pink muco-purulent fluid escaped and I could introduce a finger into the sac, which had thick rigid walls and a corrugated rough inner surface. The canal, which now admitted the finger, was dilated without difficulty outward to both sides, the loose connective tissue between the rectum and bladder offering very little resistance to the dilatation, until a transverse diameter of two inches was obtained.

Exploration through the rectum by the left index finger while the right index finger was in the sac and pulled the latter downward, showed above and behind the sac a small body about the shape and size of a virgin uterus. The tissues of both parametria were somewhat thickened and rigid so that I was not able to palpate the tubes and ovaries. As it was thus evident that the sac described above was the dilated upper portion of the vagina, I decided to enlarge the entrance

sufficiently to permit the passage of a glass plug up to the vaginal portion of the uterus.

Two Simon's specula were then introduced and showed a narrow entrance into the now empty sac. This entrance we were obliged to widen by radiating incisions through the thick wall, before a glass speculum an inch and a half in diameter could pass into the sac. Digital exploration at the uterine end of the sac failed to show any distinctly shaped vaginal portion of the uterus.

The hemorrhage during the operation was not very considerable. The wound cavity was irrigated with bichloride of mercury 1 : 4000 ; iodoform rubbed into the walls ; a glass speculum introduced and held in place by a perineal antiseptic dressing.

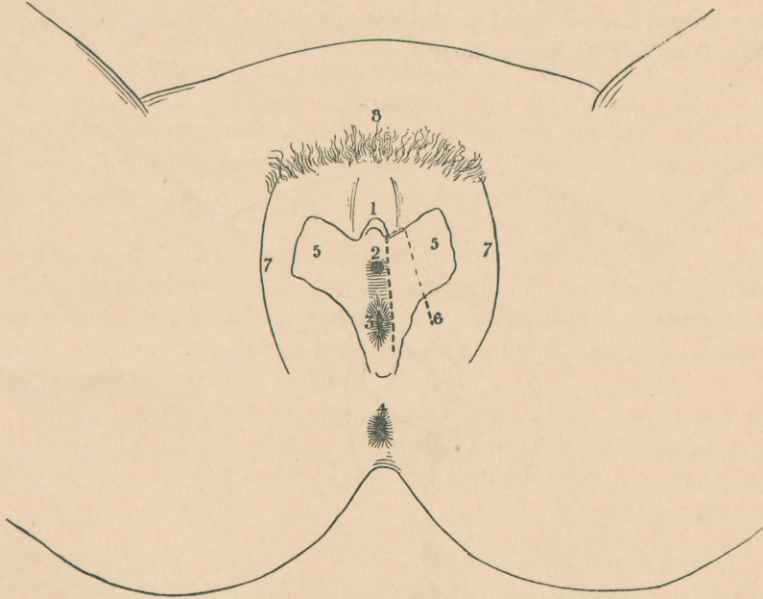
The patient was kept in bed for two weeks, no high temperature, pain, or inflammation following the operation. In the fourth week the menses came with a medium amount of discharge but no pain or other difficulties. During this period the glass plug was removed. At the end of the period, when the tube had been out for five or six days and the time had come for its reintroduction, I found that the new formed vaginal canal had already retracted so as to admit only the index finger, and the introduction of a larger glass plug caused her unbearable pain. I was therefore compelled to anæsthetize her, and repeat the forcible dilatation, which was accompanied by some hemorrhage, before I could introduce a glass plug of the same size as before.

This difficulty recurred at every subsequent menstrual period. I consequently determined to perform a plastic operation, with the expectation that if I could get a vaginal canal covered with skin and mucous membrane, the retraction would not recur. As Heppner's proposed flaps could be only comparatively short and entirely insufficient for a canal of this length, and as Credé's unilateral or posterior flap did not seem to me to fill the indications, at least, so far as cohabitation is concerned, I resolved to try to use the labia minora, which in this patient were normally developed, for the bilateral flap operation.

This I performed on October 26th, assisted by Drs. Van Hook, Davis, Black, and the surgical staff of internes in the hospital. The menses had just ceased. The patient was prepared in the usual manner and placed upon the operating table in the lithotomy position. The contracted vagina was dilated as usual to its full size, and the smooth part of the cicatricial surface freshened by scraping with the sharp spoon, and thoroughly irrigated by bichloride solution. The labia minora

were now loosened by incisions (as shown in Figs. 2 and 3); namely, a medial incision along the entrance to the vagina, upward along the

FIG. 2.



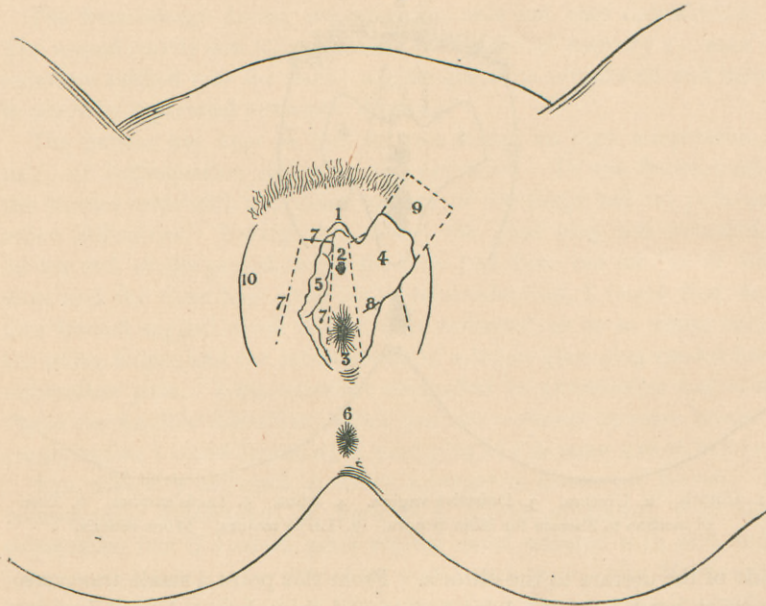
1. Clitoris. 2. Urethra. 3. Defective vagina. 4. Anus. 5. Labia minora. 6. Line of incision to liberate the labia minora. 7. Labia majora. Mons veneris.

side of the urethra to the clitoris. From this point a small transverse incision out toward the labia majora and from here a lateral incision carried downward, backward, and outward, so as to form a base for the flap one and a quarter inch in diameter at the lateral portion of the perineum. The whole of the labium minus was then loosened from the underlying muscles, forming a flap an inch and a half long. The upper quadrangular portion of the labium minus was then split lengthwise and the anterior or medial surface turned upward and outward (as shown in Fig. 3). By this procedure the flap was lengthened about an inch. The labium minus thus divided was in its upper part almost transparent and so thin that I was somewhat afraid it would lose its vitality from insufficient blood supply. My fears, as it afterward proved, were groundless.

Both labia minora having been prepared in the same manner, the

two lateral flaps thus formed were turned into the new-formed vagina. The upper borders were stitched to the lateral margins of the cervical portion of the vagina and the long lateral borders of the flaps secured by a few chrome catgut sutures to the tissue of the lateral wall of the new-formed vaginal canal, anteriorly and posteriorly, so as to prevent them from folding longitudinally.

FIG. 3.



1. Clitoris. 2. Orificium ext. urethræ. 3. Fistulous opening through the cicatricial tissue of the defect of vagina. 4. Left labium minus laid against the labium majus. 5. Right labium minus in situ. 6. Anus. 7, 7, 7. Line of incision for lateral (labial) flap of skin. 8. Part of incision dividing the labium minus so as to unfold it. 9. The unfolded labium minus. 10. Labium majus.

The vaginal cavity was now irrigated, thoroughly rubbed with iodoform, and packed with iodoform gauze. The loss of substance at the place of the transplanted flaps was without difficulty united by securing the movable skin of the labium minus by sutures to the mucous membrane at the place of the median incision. A flexible rubber catheter was left permanently in the bladder and an iodoform dressing placed over the vulva.

The after-treatment was uninterruptedly aseptic, and a week later

when the iodoform dressing was removed, complete union by first intention was found to have taken place, and the flaps were alive and everywhere adherent. Vaginal and external iodoform gauze dressings were applied for another week and then a glass plug an inch in diameter was introduced. This was replaced a week later by a plug an inch and a quarter in diameter, and still later by one an inch and a half in diameter, which was introduced and kept in for several hours daily during the following months. At the subsequent menstrual periods during which the plugs have been left out, there has been no appreciable retraction of the vagina, and after the period the patient has been able to introduce the plug without either pain or hemorrhage.

The patient kindly consented to come before the Gynecological Society for examination, and the members of the Society were able to convince themselves that this new-formed vagina is wide, elastic, smooth, and covered with mucous membrane of some secretory power.

There can be no doubt that a plastic operation for atresia of the vagina is superior in its results to the old method of simple dilatation without transplantation of skin and mucous membrane on the wounded surfaces. It is desirable to have the walls of the new-formed vagina as similar to a normal vagina as possible. If a covering of mucous membrane, as from the labia minora, can be had, it is preferable to a flap of skin from the adjacent parts.

It is possible that cases of defect of the vagina may be complicated by defect of the external genital appendages, and that no labia minora exist. In such cases I recommend a bilateral flap of skin as preferable to Credé's unilateral flap. But in cases in which the nymphæ exist, a bilateral flap formed of them is preferable, can be had of sufficient size, and be used with almost perfect results.

