

Stowell (T. B.)

Compliments of the Author,

THE


TRIGEMINUS NERVE

IN THE

DOMESTIC CAT (FELIS DOMESTICA).

By T. B. STOWELL, Ph.D.

Read before the American Philosophical Society, May 21, 1886.





The Trigeminal Nerve in the Domestic Cat (Felis domestica).
By T. B. Stowell, Ph.D.

(Read before the American Philosophical Society, May 21, 1886.)

The importance of the study of comparative neurology may be argued from the standpoint of anatomy, physiology, pathology and biology.

The value attached to such study depends largely upon individual bias, arising from education or from the end to be served by such knowledge.

Admitting that physiology may determine or suggest anatomical relations which otherwise would be obscure, it is none the less true that morphology must precede physiology; knowledge of structure forms the basis of knowledge of function. It may be added that human physiology, so called, is almost entirely comparative physiology; isolated experiments, independent of those performed upon animals exclusive of man, cannot establish law.

The influence of the nervous system upon function, and the complexity of physiological experimentation arising from this cause, are familiar to every laboratory student of this subject.

These considerations are a sufficient apology for the present "Study of Nervus Trigeminalis" as a contribution to comparative neurology.

Reasons for the selection of the domestic cat have been stated elsewhere (Anatomical Technology, p. 55, v. Bibliography, 33). The study of N. Vagus (The Vagus Nerve in the Domestic Cat, 27) and the present study cannot fail to convince that in general plan, and even in detail of structure and distribution, the nervous system of the cat forms a desirable basis for comparative neurology, and possesses special advantages as a preliminary to anthropotomic neurology.

The writer is not aware that any one has published the details of the distribution of the trigeminal nerve in the domestic cat. He regrets that he has not been able to obtain Swan's work (29), in which are described the cranial nerves of the jaguar.

He cannot reconcile the wide discrepancy between the origin, distribu-

tion, etc., of this nerve in American cats, and the origin, etc., as published by Mivart (18, p. 271).

The ectal origin has been described by Wilder (33, 34).

Most of this work was done in the anatomical laboratory of the Cornell University, where special facilities are afforded for original research.

Preparation: The cats were injected with the "starch injection mass" (Anatomical Technology, 2d ed., p. 140-141, 34). Brains were dissected "recent" and "hardened in alcohol;" there are advantages peculiar to each for tracing the ultimate distribution of nerve-filaments. Dissections were verified from both kinds of specimens. For preliminary examination, it is suggested that the student begin at the foramina of exit and trace peripherad; this will avoid confusion in identification and the inadvertent severing of anastomotic filaments. A more thorough dissection can subsequently begin with any of the peripheral rami—*e. g.*, *N. digastricus* or *N. auriculo-temporalis*—and proceed centrad.

NERVUS TRIGEMINUS.

Synonymy: *Nervus trigeminus*; *N. divisisus seu gustatorius*; *N. quintus, seu tremellus, seu mixtus, seu sympathicus medius, seu sympathicus medius, seu anonymous, seu innominatus*; *Par trigeminum seu quintum nervorum cerebralium, seu trium funicularum*; *Trifacial*; *The fifth pair of nerves.*

This nerve presents the following characters, viz:

General Characters: The constancy of its characters and the striking resemblance, even of details, to the human trigeminus; the size—it is the largest of the cranial nerves; the analogy to the spinal nerves—the origin and the double function refer this nerve to that class of cranial nerves which admits of ready comparison with the spinal nerves (this homology is incomplete, by reason of the unequal distribution of the sensory and the motor filaments); the two roots, the larger is ganglionic, the smaller is without ganglion; these root functions are sensory and motor respectively.

To the ganglionic or sensory division is referred the sensibility of the face, cheek, forehead, external ear (*auris ectalis*), *pili tactiles*, *vibrissæ*, eye (*conjunctiva*), teeth, lips, mouth, nose, dorsum of tongue; the non-ganglionic or motor division is distributed chiefly to the muscles of mastication; to these functions may be added the influence of this nerve upon the glands (*parotid, submaxillary, sublingual, lachrymal, buccal* (?)), and its undetermined action upon the middle ear.

There are several ganglionic masses ectad of the cranium which sustain intimate relations with this nerve. Each of these ganglia seems to communicate with a motor, a sensory and a sympathetic root or nerve, and thence to distribute filaments to structures more or less contiguous.

Physiological Characters:

1. Simple nerves of sensation.
2. Mixed or myelic nerves.

3. Nerves of common sensation with a specialized function and with motor filaments.

4. Nerves which directly or through their relation with N. sympathicus indirectly control or modify glandular secretion.

It is unsatisfactory to attempt to classify the function of N. tensor tympani and the filament to the tentorium cerebelli.

DESCRIPTION.

Origin: The study of the entocranial portions of the trigeminus nerve includes the description of the ental (deep) and the ectal (apparent) origins of both portions.

The ental origin has not been satisfactorily determined. Preliminary work based upon Mondino's Golgi's perchloride of mercury method (Journal of Royal Microscopical Society, N. S. V., Part 5, p. 904, 16) indicates a method for the solution of this difficult problem.

The method for tracing nerve-tracts in the brain and spinal cord as published in Brain, Vol. viii, p. 86, may prove serviceable in this connection.

The impracticability of positively establishing the relations of the two roots without serial transverse sections leaves the ental origin involved in obscurity; the following general relations, determined under a magnifying power of 15-20 diameters, may serve to indicate the wide-spread origin of this nerve, and also the necessity of making serial sections along a considerable portion of the neuron.

The fasciculi, by whose confluence the nerve-trunks are formed, may be designated the

Proximate roots: From morphological considerations alone it would be natural to treat this nerve as having two roots, the motor and the sensory.

Radix motoria: The motor root generally—not invariably—consists of two packets, the dorsal or cerebellar, and the ventral or epicælian.

The fasciculi of the dorsal root often lie free of the pons, or they interdigitate with the pons; they may be traced along with medipeduncular fibres to the cerebellum; the motor root frequently contains fibres from the pons.

The larger or ventral root generally lies wholly free of the pons (some of its fibres may interdigitate with the pons). It forms the caudal border of the emarginate pons, and may be traced caudad of the prepeduncle to the floor of the epicæle, about 2 mm. laterad of the meson, at which point the fibres bend abruptly ventrad.

The two-fold origin of this root is suggestive of difference of function.

Radix sensoria: The sensory root seems to have a four-fold origin; these roots, by virtue of their course, may be named cephalic, dorsal, caudal and ventral roots respectively. *Rx. cephalica* may be traced with some radical fibres of the prepeduncle into the floor of the epicæle, and thence cephalad to the region of the opticus.

Do not these fibres suggest an ental origin similar to the anthropotomic

origin demonstrated by Meynert (28, p. 732 *et seq.*) and by Spitzka (26, The Central Tubular Grey, p. 72)?

Rx. dorsalis is apposed to the medipeduncle, and is traceable with it into the cerebellum.

Rx. caudalis extends parallel with the meson to a region of the metencephalon just caudad of the olive.

This considerable fascicle points to an ental origin several mm. caudad of a transection through the caudal border of the pons, and in the region of the olive.

Rx. ventralis: The fourth radicle comes from the epicule in the same region as the ventral root of *Rx. motoria*; its course is laterad, and lies caudad of the medipeduncle, and ventrad of the medipeduncle and prepoduncle.

Ectal Origin: There is some variation in the ectal origins of this nerve in different animals. This variation may be referred to the variation in general configuration of the brain, and does not prevent homologization.

"When the pons is less developed than in man, the nerve (trigeminus) is attached behind (caudad of) that part between it and the trapezium of the medulla oblongata" (30, Vol. ii, 270).

Wilder summarizes as follows: "In the cat the nerve is always nearer the caudal than the cephalic border of the pons." "Sometimes the entire nerve passes just caudad of the pons, which is then usually somewhat emarginate at that point." "Sometimes, perhaps more often, some of the fibres of the nerve interdigitate with those which form the caudal margin of the pons" (33).

As already indicated, the proximate roots by their confluence form two nerves with distinct ectal origins, but which are intimately related in their distribution.

Radix motoria (*Rx. mtr.*), the smaller of these nerves, lies upon the mesal border of *Rx. sensoria*. It is a slender ribbon-like packet composed of 6-9 funiculi; it sustains this general relation for about 5 mm.; near the cephalic border of the pons it crosses the ventral surface of a large flattened ganglion, *G. gasseri*, q. v., and finds its exit with *N. mandibularis* through the oval foramen. Its distribution is given with *N. mandibularis*.

Radix sensoria (*Rx. sn.*), the larger and ganglionic nerve, takes its ectal origin from the proximate roots which lie chiefly caudad of the pons. The caudal border of the nerve is not infrequently in a line with the caudal border of the pons, but this relation is occasioned by the emarginate border of the pons against which the nerve-trunk rests.

In the examination of the brains of *Felis leo* and *F. concolor* (one of each) and *F. domestica* (a large number), in the museum of Cornell University, I have not found a single instance in which any fibre of the pons passes wholly caudad of the trigeminus. Only a few of the fibres of the cephalic border of *Rx. sensoria* ever interdigitate with the pons, and this condition does not exist in the majority of brains examined. In some of the brains hardened in alcohol a few filaments from the pons seem to be

continuous with Rx. sensoria. In injected brains the sensory root is separated from the motor by an arteriole, a small twig from A. basilaris inferior.

In one instance a fascicle from the trapezium crossed the base of the trigeminus in such relation as to be easily mistaken for fibre from the pons. The emargination of the pons may have led to a misconception of the freedom of origin of this root. In one case cited by Wilder (unpublished) a fascicle from the cephalic surface of the sensory root passed centrad near the middle of the pons.

Summary—Ectal Origin: 1. Fibres of the pons are found caudad of the lateral and cephalic moiety of the motor root.

2. Sometimes the motor root is entirely free of the pons.
3. The entire motor root never penetrates the pons.
4. The sensory root never penetrates the pons.

GANGLION GASSERI.

Synonymy: *Ganglion gasseri*; *Ganglion gasseri*; *G. gasserianum*; *G. semilunare*; *Moles gangliiformis*; *Intumescencia gangliiformis seu semilunaris*; *Tonia nervosa Halleri*; *Ganglion of the fifth nerve*, etc.

Description (Fig. G.): At the cephalic border of the pons the sensory root is involved in a large flattened ganglion; this ganglion is lodged in the fossa upon the dorsal surface of the basi-sphenoid bone caudad of the foramen ovale, Fm. rotundum and Fm. lacerum anterius; the lateral angle is covered by the ventral wing of the osseous tentorium; the tentorium cerebelli is intimately related with the dorsum of G. gasseri, and is with difficulty separated from it. The ganglion is a flattened, irregular body 8 mm. long by 4 mm. wide; the cephalic border is trichotomous, and gives origin to the principal rami of the sensory root; the mesal border is nearly straight, and is in contact with the processus clinoides; the lateral border is crescentic, and is characterized by a peculiar enlargement at its caudal extremity; this eminence is the origin of the first rami of the trigeminus; one ramus (Pe) enters the hiatus Fallopii, and gives origin to several funiculi, by which it is related with the facial nerve through three canals in the petrous portion of the temporal bone, and also with the glosso-pharyngeal and vagus nerves (through foramen jugulare). From the lateral angle of the eminence a filament (Tn) is given to the tentorium cerebelli; it lies apposed to the petrosal ramus ectad of the facial nerve.*

Upon its ventral surface G. gasseri is in relation with the motor root, and also with the large petrosal nerve which proceeds from the geniculate ganglion (this nerve follows the aqueductus fallopii, emerges from the hiatus fallopii, crosses G. gasseri and joins the vidian nerve just centrad of the vidian canal).

* This can be best demonstrated by exposing the base of the brain, by the removal of the basioccipital and basisphenoid bones, and then with nippers and arthrotome (34, pp. 63. 66), gradually removing the petrous portion of the temporal bone. This will expose the tortuous canal with the included nerves.

The mesal border of *G. gasseri* is contiguous with the oculomotorius (iii) upon its venter, and with the trochlearis (iv) upon the dorsum. The cephalic border is involved more or less in a dense rete arteriale from *A. carotidea externa*, and receives filaments from the adjacent plexus sympathicus carotideus.

ECTOCRANIAL RAMI.

Ectad of the cranium the trigeminus is represented by three nerve-trunks and their respective rami. These trunks may be regarded as offsets of the Gasserian ganglion; they leave the cranium by distinct foramina. By virtue of distribution, they are named *N. mandibularis*, *N. maxillaris* and *N. ophthalmicus*. (Fig. Man. Mx. Oph.)

NERVUS MANDIBULARIS.

Synonymy: *N. mandibularis*; *Inferior maxillary branch*; *Mandibular nerve*.

General Characters: This is the lateral ramus of the trigeminus; it is also the largest and widest in distribution. The motor root (*Rx. motoria*) is given exclusively to this trunk just peripherad of the Gasserian ganglion—hence its varied character and two-fold function. It supplies sensory and motor structures and glandular organs. Its rami are distributed to the integument of the ear, the cheek and the chin; to the vibrissæ, the labial papillæ, the teeth and gums of the mandible, the sensory organs upon the dorsum of the tongue; to the muscles of mastication and to the salivary glands.

Special Description: *N. mandibularis* is the lateral offset of the Gasserian ganglion; just peripherad of the ganglion it is joined by the motor root (*Rx. mtr.*) of the trigeminus; peripherad of this union the motor and the sensory fibres require physiological rather than morphological identification; its foramen of exit is the foramen ovale; peripherad of the cranium the trunk divides into six or more rami, which require separate descriptions:

N. temporo-auricularis: *Superficial temporal*; *temporal cutaneous*.

Origin: This nerve takes its ectal origin at the foramen ovale; it is the lateral ramus of the nerve-trunk. (Fig. Tmp. aur.)

Course: It is first directed ventro-laterad, entad of the muscles and the *A. carotidea externa*; it lies close to the zygomatic process; at the ventrad border of the process it bends dorsad over the process, and lies caudad of the *A. temporalis externa* and entad of the submaxillary and the parotid glands. The general course is toward the cephalic border of the external ear (*auris ectalis*). Entad of the parotid gland it divides into two principal rami, which, by reason of general direction, are designated cephalic and caudal.

Communicating Rami and Relations: Just caudad of the zygomatic process this trunk gives a small twig to the mandibular articulation; it sustains relations with the otic ganglion by a slender fascicle which may

be regarded as the root, or one of the roots, of the ganglion; it also joins the facial nerve, and gives filaments to the base of the ear (cartilago auditorius). Dorsad of the meatus auditorius the auriculo-temporal nerve lies entad of the parotid gland; in this region its course is entad of the facial nerve, with which nerve it assumes plexiform relations (Fig. Tmp. Fac.). *A. temporalis* lies between *N. tmp. aur.* and *N. tmp. fac.*; ramuli (*N. N. parotidei*) enter the substance of the gland (*Gl. par.*). Near the middle of the gland the auriculo-temporal nerve divides into cephalic and caudal rami (Fig.).

N. tmp. aur. cephalicus becomes a distinct nerve at the cephalo-dorsal angle of the parotid gland. Its course is toward the eye until it reaches the zygomatic border of the masseter muscle, when it follows the border of the muscle to the angle of the mouth. It anastomoses freely with *N. temporo-facialis* (Fig. Tmp. fac.), which lies upon the ectal surface of the masseter muscle just dorsad of the Stenon's duct, and terminates in the plexus at the angle of the mouth, plexus labialis (*Pl. lab.*). It sends filaments to the integument between the eye and the base of the ear (*auris ectalis*), to the cheek ventrad of the eye, to the vibrissæ, the dorsal lip, and to the papillæ on the ental surface of the lip and to the mucosa in the region of the premolar teeth (Fig. p. m.).

N. tmp. aur. caudalis is distributed chiefly to the external ear; it may be traced with the terminal arterioles of *A. temporalis*, along the cephalic border of the ear; terminal filaments are given to the long hairs which line the helix (Fig. Pili); a considerable ramulus enters the meatus near the tragus (*tr.*), and descending centrad supplies the external meatus; other filaments are distributed to the frontal region. A small twig from the caudal border of this ramus just peripherad of the bifurcation of *N. tmp. aur.* anastomoses with the facial and terminates in the ventro-lateral border of the ectal ear and the hairs (Pili) between the lateral pocket and the tragus. This nerve does not appear to supply the dorsal surface of the external ear.

N. massetericus has its origin at the foramen ovale from the dorsum of the mandibular nerve (Fig. Mass.), in common with *N. temporalis internus* (*Tmp. int.*); 2 mm. peripherad of the common origin, this nerve becomes a distinct ramus; its course is dorsad for 8-10 mm., when it penetrates the masseter muscle and is directed to the caudal border of the malar muscle. Along its dorsal border it gives off 6-10 ramuli to terminate in the masseter muscle.

N. temporalis internus: The deep temporal has a common origin with the masseter, *q. v.* About 5 mm. peripherad of the origin an anastomotic filament connects these rami. The course of *N. tmp. int.* is dorsad and mesad of the temporal artery; it is therefore concealed by the artery when viewed from the side. About 8 mm. from its origin the ramus divides into cephalic and caudal ramuli (Fig.); these supply the fan-shaped temporal muscle; the length of the caudal ramulus is 45-50 mm.

N. pterygoideus externus: This small nerve has its origin from the

mesal border of the mandibular nerve (Fig. Pter. ext.): about 2 mm. from its origin it separates into three rami, which may be traced 8-10 mm. and then penetrate the pterygoid muscle, upon which muscle its terminal filaments ramify.

N. buccalis is a large nerve which separates from the mesal border of the mandibular nerve (Fig. Buccalis) just ventrad of the deep temporal. The first 5 mm. of its course is involved in the dense rete of the carotid artery; its direction is toward the caudal angle of the maxilla; it is apposed to the buccal artery, and lies between the pterygoid and the temporal muscles. It gives filaments to the mucosa of the mouth (Fig.), a few filaments to the malar border of the masseter muscle, and at the angle of the mouth it joins the plexus already named—Plexus labialis (Pl. lab.).

N. dentalis inferior together with **N. lingualis** form the principal rami or continuation of the mandibular nerve. It becomes a distinct nerve about 5 mm. peripherad of the foramen ovale. It lies ectad of the pterygoid muscle, and enters the foramen infradentale with the mandibular artery. It lies along the dental canal ventrad of the artery, and gives filaments to the teeth (Fig. m., p. m., canine, incis.) and to the cancellous interior of the mandible; a considerable fascicle continues peripherad through the mental foramen (Fm. men.); the terminal filaments anastomose with filaments of its platetrope.

N. mentalis is the continuation of the dental nerve peripherad of the mental foramen; it divides into several fasciculi, which anastomose in plexiform relations upon the ventral lip, the chin and the mucosa of the mandible. (**N. digastricus** and **N. mylo-hyoideus** join this plexus.)

N. mylo-hyoideus is given from the mandibular nerve about 10 mm. centrad of the infra-dental foramen; its course is apposed to the facial artery; it lies entad of the artery as it crosses the mandible. Ventrad of the mandible it gives an anastomotic filament to the facial; it continues 1-2 mm. mesad of the submental artery, and, following its arterioles, is distributed to the mylo-hyoid muscle.

N. digastricus is a branch of the mylo-hyoid, or it may be regarded as a branch of the mandibular nerve peripherad of the point where the mylo-hyoid nerve lies ventrad of the mandible. About 3-4 mm. peripherad of this origin it divides into cephalic and caudal rami (Fig.). The *cephalic ramus* is apposed to the submental artery, supplies the distal half of the digastric muscle, and terminates in plexiform relations with the mental nerve; the *caudal ramus* follows the digastric artery caudad about 10 mm., and supplies the digastric muscle as far as the angle of the mandible.

N. lingualis has a common origin with the dental nerve; 5 mm. peripherad of the foramen ovale it takes a distinct course mesad of the dental nerve; it lies ectad of the pterygoid muscle, apposed to a small arteriole just entad of the carotid and the dental arteries; 15 mm. peripherad of its origin it takes three courses:

- (1) The cephalic ramus, **N. pharyngeus** (Phar.), is distributed to the

pharyngeal mucosa and along the ental surface of the mandible to the symphysis.

(2) The middle ramus, the trunk proper, bends around the lateral border of the tongue, and enters its substance with the lingual artery 30 mm. proximad of the tip.

(3) The caudal ramus enters the lingual muscle with the lingual artery about 25 mm. caudad of the tip; this nerve seems to supply the muscle-fibre.

The middle and caudal rami assume plexiform relations; their numerous filaments generally accompany ramifying and anastomosing arterioles, and may be traced to the dorsum of the tongue; the caudal ramus sustains plexiform relations with the hypoglossal nerve. (XII.)

The lingual receives a considerable accession from the facial nerve, the chorda tympani (Fig. Chorda).

N. submaxillaris: Just mesad of the origin of the digastric artery this branch separates from the lingual nerve; it lies ectad of the artery apposed to Wharton's duct, which it freely supplies, and continues dorsad into the substance of the sublingual and submaxillary glands; it terminates in a small ganglionic mass, G. submaxillare (G. S. max.), near the origin of Wharton's duct. From this ganglion filaments may be traced to the substance of the gland.

Chorda tympani: This nerve is an anastomotic branch between the lingual and the facial. Its physiological action upon salivation, as well as its tortuous course, gives to it a special interest. It separates from the facial as this nerve emerges from the cranium at the ganglion geniculatum (intumescencia gangliformis); it returns a short distance in the canal of the nerve trunk, and enters a canal in the bulla; it penetrates the bulla, which it crosses dorsad, and enters the tympanum through a small foramen, iter chordæ posterius; it crosses the tympanum about the middle of the malleus, somewhat mesad of the bone, and emerges through a minute foramen, iter chordæ antierius, or the canal of Huguier, into the Glaserian (?) fossa, thence along the canal to the ectocranial foramen; as it emerges from the cranium it lies ventrad of the carotid and the pterygoid arteries and ectad of the pterygoid muscle; it joins the lingual nerve 5-10 mm. peripherad of the foramen ovale.

N. pterygoideus internus has a common origin with N. tensor tympani from the lateral border of the mandibular nerve just ventrad of the auriculo-temporal nerve (Fig. Pter. int.). It lies parallel with the lingual nerve for 5 mm.; it crosses the cephalic border of the external carotid artery, and accompanies the pterygoid artery; its course is entad of the chorda tympani, and supplies the distal portion of the pterygoid muscle.

N. tensor tympani: As the common nerve (V. supra) crosses the cephalic border of the carotid artery, N. tensor tympani (Fig. Ten. tym.) separates and bends around the ventral border of the artery, enters the otic ganglion, thence lies in the Glaserian fissure and terminates upon the

spherical tensor tympani muscle. This nerve does not seem to be incorporated with the ganglion.

G. oticum: *Otoganglium*; *G. auriculare*; *Auricular ganglion, Ganglion of Arnold*, etc. (Fig. Otic.)

Upon the tensor tympani nerve just dorsad of the carotid artery, at the hiatus fallopii, is a small pinkish ganglion, oval in outline, about 2 mm. in long diameter. It is related by anastomotic filaments with the sympathetic plexus (Sym.) around the carotid artery; with the auriculo-temporal nerve by a twig dorsad of the carotid artery (Fig. root); the artery appears to pass between the two roots (?) of the nerve, the ganglion being at their confluence. Two slender fascicles from the otic ganglion enter the hiatus fallopii and join the facial nerve. (Fig. Pe.)

NERVUS MAXILLARIS.

General Description: This is the middle ramus of the trigeminus; it is intermediate in size between the other rami; its course is immediately cephalad from the Gasserian ganglion through the foramen rotundum, the foramen of exit. The ectocranial trunk crosses the sphenopalatine space, lies along the infraorbital fossa, and penetrates the infraorbital foramen. In its course it is dorsad of the maxillary artery. The length of the trunk from the ganglion Gasseri to the foramen infra-orbitale is about 40 mm.

It supplies the integument of the forehead, cheek, dorsal lip, side of the nose; the vibrissæ, conjunctiva, lachrymal gland, maxillary teeth, palate, pharynx, and the membrane over the turbinated bones.

Detailed Description and Rami: N. maxillaris (Fig.), at the foramen of exit, is about 2 mm. in diameter; at its ganglionic origin, G. gasseri, it is somewhat intumescent; upon the ventral surface of this enlargement it receives a considerable filament from the large superficial petrosal of the facial. This anastomotic filament lies obliquely across the ventral surface of the Gasserian ganglion, and penetrates the rete carotideum to reach the nerve. The central 5 mm. of its ectocranial course is involved in a dense rete of the carotid artery and the carotid plexus, from which plexus it seems to receive filaments. The distribution of the nerve is given in the description of the rami.

N. orbitalis (Fig.) is the first ramus of the ectocranial trunk, and is given off at the foramen of exit; its course is dorsad, and extends about 2 mm., being involved throughout its course in the rete already described; it is the common origin of N. temporalis and N. malaris, q. v.

N. temporalis (Fig. Tmp.) is the caudal ramus of the orbital nerve; its general course is toward the post-orbicular process (processus post-orbicularis); 2-5 mm. peripherad of its origin it divides into cephalic and caudal rami.

R. cephalicus (Fig. Tmp. ce.), the larger ramulus, passes ventrad of the post-orbicular process, and is distributed to the conjunctiva and integument of the dorsal lid, and to the lachrymal gland; it sustains anastomotic relations with the palpebral nerve.

R. caudalis (Fig. Tmp. ca.), a small ramulus, passes caudad of the process, bends caudad, and terminates in the integument over the forehead; it anastomoses with the auriculo-temporal nerve.

N. malaris is the lateral ramus of the orbital; its course is direct to the malar foramen (a small foramen in the malar bone just dorsad of the cephalic end of the zygomatic process); it penetrates this foramen, lies in a groove entad of the orbicular muscle, which it perforates near the angle of the eye, and is distributed to the ventral lid and cheek over the malar bone (this is the subcutaneous malar nerve of anthropotomy); its terminal filaments reach the labial plexus.

N. palatinus cephalicus (Fig. Plt. ce.): About the middle of the rete carotideum three rami are detached from the ventral surface of the maxillary nerve; these remain in the sheath for several mm. The cephalic ramus (Fig. Plt. ce.) lies ventrad of the palatine artery and enters the palatine foramen (the dorsal end of the posterior palatine canal); it sends an anastomotic filament to *N. palatinus caudalis* (Fig. Plt.). Just centrad of the palatine foramen (Fig. Fm. plt. p.) a large accession is received from the spheno-palatine ganglion (Sph.).

(In some cases a fascicle from this nerve enters a small foramen just caudad of the posterior palatine foramen, and, following a canal in the palatine bone, joins the nerve at the posterior palatine foramen). Peripherad of this foramen (Fm. plt. p.) the nerve lies close to the hard palate, and joins the naso-palatine nerve at the anterior palatine foramen (Fm. plt. a.); it sends numerous filaments to the rugæ upon the roof of the mouth and to the adjacent mucosa.

G. spheno-palatinum (Sph.), *Ganglion of Meckel*: This ganglion is located just caudad of the palatine and the spheno-palatine foramina; its cephalic angles or prolongations enter these foramina (Fig.): it is flesh-colored, 6 mm. \times 2 mm., flattened, irregular in outline, the mesal border slightly concave; the lateral border is irregular by reason of the attachment of nerves; its roots are two large rami (*N. N. sph. plt.* Fig. root) of the maxillary nerve, which take origin just peripherad of the cephalic palatine nerve, and are included in the common sheath with that nerve for 2-4 mm.; the roots are inserted into the lateral angle of the ganglion about 1 mm. apart.

Relations: This ganglion (Sph.) is related with the maxillary nerve by two roots; with the carotid plexus (*N. sympathicus*) by two filaments (*Sym.*) from the caudal border between the roots and the vidian nerve; with the cephalic palatine by a large fascicle from the cephalo-lateral angle. It is the origin of the naso-palatine nerve (*N. plt.*) at the spheno-palatine foramen; the origin of *N. pharyngeus* near the vidian nerve; of *N. palatinus caudalis* at the lateral border caudad of the palatine foramen, and of *N. vidianus* at the meso-caudal angle.

N. palatinus caudalis (posterior): This nerve (Fig. Plt.) takes its origin from the lateral border of the spheno-palatine ganglion just centrad of the palatine foramen; its course is ventrad and caudad; 2-5 mm. from the

ganglion it divides into two ramuli, the shorter of which (Fig. cephalic) is distributed to the roof of the mouth caudad of the rugæ; the longer (Fig. caudal) bends caudad and supplies the soft palate to its caudal border; the caudal ramulus receives an anastomotic twig from *N. palatinus cephalicus*.

N. pharyngeus, a small nerve, has its origin from the spheno-palatine ganglion at the origin of the vidian nerve (possibly the nerve is an offset of *N. vidianus*); it supplies the pharyngeal mucosa (not shown in the diagram).

N. naso-palatinus is the principal offset of the spheno-palatine ganglion cephalad; it enters the spheno-palatine foramen (Fm. Sph.), lies upon the floor of the nares, passes ventrad through the anterior palatine foramen (Fm. plt. a.), and anastomoses with the cephalic palatine nerve (Plt. ce.). Numerous filaments from this nerve are traced in plexiform relation upon the membrane which covers the turbinated bones and the floor of the nares.

N. N. dentales caudales: Dorsad of the caudal angle of the maxillary bone a single filament is given off which penetrates the alveolus and supplies the molar tooth (Fig. m.); just cephalad, two considerable fasciculi (Dent. ca.) separate, lie along the infraorbital fossa, penetrate small foramina in the bone and terminate in the premolar teeth (Fig. p. m.); these dental nerves anastomose freely before they penetrate the bone, and also sustain a similar relation throughout the cancellous tissue of the alveoli; filaments of these ramuli join the cephalic dental nerve (dent. ce.).

N. dentalis cephalicus: Just caudad of the infraorbital foramen (Fig. Fm. inf. orb.) a considerable fascicle, *N. dentalis cephalicus*, penetrates the dental foramen (Fm. d.), together with an arteriole; it lies cephalomesad along a canal in the cancellous tissue of the maxillary bone, and gives nerve-supply to the canine tooth; it continues mesad until the terminal filaments anastomose with the nasal plexuses upon the turbinated bone in the region of the premaxilla. This nerve receives filaments from the caudal dental rami, and becomes considerably enlarged in the canal between the canine tooth and the foramen which leads to the prenares.

Is this enlargement the ganglion of Bochdalek? (Fig. B.)

N. infra-orbitalis is the continuation of the maxillary peripherad of the infra-orbital foramen (Inf. orb.). The nerve-trunk divides into a leash of terminal fasciculi.

N. labialis supplies the dorsal lip, the papillæ on its ental surface, the adjacent mucosa and the vibrissæ.

N. nasalis terminates upon the integument which covers the nasal cartilage.

N. palpebralis is distributed to the ventral lid and the conjunctiva as far mesad as the nasal duct.

N. lachrymalis takes a dorsal course around the orbit, and terminates in the lachrymal gland, where it anastomoses with the lachrymal nerve, an offset of the orbital (Tmp. ce.), q. v.

N. Vidianus is a ribbon-like offset of the meso-caudal angle of the sphenopalatine ganglion (Fig. Vidian); its course is caudad to the vidian canal. (The cephalic foramen of this canal is ventrad of the foramen lacerum anterius; the canal is 5-10 mm. in length. The caudal foramen opens upon the dorsum of the basi-sphenoid bone). It lies along the canal, and at the caudal foramen the entocranial nerve lies ventrad of the Gasserian ganglion, and sends filaments to the eustachian tube, to the pharyngeal mucosa, and becomes *N. petrosus superficialis major*, which relates it to the facial nerve through a foramen in the petrous portion of the temporal bone.

At the cephalic end, near the sphenopalatine ganglion, two filaments are given to the ophthalmic nerve; the nerve is related with the maxillary through filaments which join the nerve-trunk just peripherad of the rete carotideum.

NERVUS OPHTHALMICUS.

General Description: *N. ophthalmicus* (Fig. Oph.) is the mesal offset of the Gasserian ganglion; it is the smallest of the three nerve-trunks which proceed from the ganglion. The entocranial relations are with the trochlear nerve, which rests upon its dorsal surface (a tracer is required to separate the sheaths of these nerves); sometimes—not invariably—these nerves are related by anastomotic filaments with the oculo-motorius (III) along its ventral surface, and with the carotid artery by the rete carotideum which involves the nerve-trunk. The foramen of exit is the foramen lacerum anterius. The ectocranial relations are described in the distribution of the two rami, *N. frontalis* and *N. oculo-nasalis*. It is distributed to the integument of the forehead, dorsal lid, side and end of the nose, to the pili tactiles, to the conjunctiva, the lacus lachrymalis, and the membrane over the turbinated bones; to the trochlear and the ciliary muscles; to the lachrymal gland; to the dura mater. It communicates with the sympathetic nerve. Its function is largely sensory.

Special Description: The central 5 mm. of the ecto-cranial trunk is involved in a dense rete carotideum; about 3 mm. peripherad of the foramen lacerum anterius the trunk divides into two rami, *N. frontalis* and *N. oculo-nasalis*.

N. frontalis is directed dorsi-mesad, and bends around the caudal surface of the globe of the eye, lying ectad of the muscles; there are really two fasciculi in a common sheath; when upon the dorsi-meson of the globe the course is abruptly cephalad parallel with the meson to the musculus orbicularis palpebræ; before the nerve perforates the muscle, a considerable trunk, **N. supra trochlearis** (Fig. S-tro.), separates, and, following the supra-orbital ridge just entad of the fascia, it gives filaments to the dorsal lid, to the nasal duct, the angle of the eye (caruncula), and terminates upon the nasal integument; an anastomotic filament relates this ramus with the palpebral branch of the maxillary nerve. Peripherad of the point where *N. frontalis* pierces the orbicular muscle, it is known as

N. supra orbitalis (Fig. S-orb.). As this nerve crosses an arteriole 2-3 mm. peripherad of the muscle it divides into two terminal rami; the lateral ramus is directed laterad, and is given to the tactile hairs (Fig. Pili); the mesal ramus unites in plexiform relations with other rami over the forehead and the integument between the eyes. (I do not find a lachrymal branch to this nerve.)

N. oculo-nasalis (Fig. Nasalis) is the mesal ramus of the ophthalmic nerve; it is directed mesad upon the caudal surface of the globe; it lies entad of the rectus dorsalis muscle, ventrad of the ramus of the oculomotorius nerve (III.), which supplies the muscle, and dorsad of the optic nerve; it is apposed to the ophthalmic artery until it crosses the optic nerve; 8 mm. peripherad of origin at the lateral border of the rectus dorsalis muscle it sends 2-3 filaments (Rx. longa) 6 mm. long ventrocephalad to join the ciliary nerve (these nerves are probably the radix longa ganglii ciliaris of anthropotomy). Just laterad of the optic nerve a considerable fascicle crosses the ophthalmic artery and rests upon the dorsum of the optic nerve; this is **N. ciliaris longus**. It gives 3-5 filaments to the short ciliary nerve (cil. br.); about 2 mm. centrad of the globe the nerve divides into 5-8 small fascicles, which perforate the sclerotic coat and lie along the ental surface of this tunic (I have not satisfactorily demonstrated the termination). Opposite the mesal border of the optic nerve several filaments are given to the plexus carotideus (sympathicus, Fig. Sym.). The nerve-trunk, the caudal ethmoid (Eth. ca.), lies ectad of the mesal rectus muscle and entad of the trochlear; it enters the foramen ethmoideum caudale (Fm. eth. ca.) (posterius), accompanied by the arteria ethmoidea caudalis; entad of the foramen, filaments of the nerve are distributed (1) dorsad to the dura mater which covers the olfactory lobes (Olf.); (2) ventrad to the hypophysis (Hy.); (3) cephalad to the ethmo-turbinated bone (Tur.); (4) mesad to join the platrope (Plat.) in the meson, while the ramus (Fig. externus) continues in a canal or groove in the frontal and nasal bones just laterad of the meson to the nasal cartilage (Cil. nasalis), where it terminates in plexiform relations with other ramuli of the trigeminus and facial nerves.

N. infra trochlearis: Upon the dorsal border of the mesal rectus muscle the largest branch separates as the infra-trochlear nerve (Inf. tro.); this rests upon the ectal surface of the muscle entad of the trochlear muscle, and is directed cephalad to the border of the globe; 8-10 mm. peripherad of the origin this nerve gives off a filament which remains in the common sheath for some distance, and is distributed to the trochlear muscle (M. tro.) laterad of the "pulley;" the main nerve lies ventrad of the pulley, and is distributed to the conjunctiva (Cnj.) of the dorsal lid, the angle of the eye (lacus lachrymalis) and the side of the nose; it sustains plexiform relations with terminal filaments of the supra-trochlear nerve (S. tro.); centrad of the pulley a filament from the infra-trochlear nerve, together with the arteria ethmoidea cephalica (anterior), enters the cephalic ethmoid foramen (Fm. eth. ce.), and terminates upon the membrane over the turbinated bones.

GANGLION OPHTHALMICUM.

Synonymy: *G. ophthalmicum*; *G. semilunare*; *G. ciliare*.

Description: This small pinkish ganglion (Fig. G. oph.) is somewhat triangular in outline; just mesad of the lateral rectus muscle it rests by its base upon the ramus of the oculo-motorius nerve (III), which supplies the ventral oblique muscle, about 1 mm. peripherad of the origin of the ramus (this ramus does not seem to be incorporated in the ganglion). From the apex of the ganglion three filaments are sent cephalad to the globe; these lie ventrad of the optic nerve, and sustain plexiform relations with the long ciliary nerve (ciliaris) before they perforate the sclerotic tunic mesad of the optic nerve.

N. ciliaris brevis: The principal offset (Cil. br.) of the ophthalmic ganglion takes its origin from the apex of the ganglion and rests upon the lateral surface of the optic nerve; 3 mm. peripherad of the ganglion, at the point of contact with the optic nerve, it receives two filaments (radix longa) from the oculo-nasal nerve, and one or more filaments from the carotid (sympathic) plexus; along the side of the optic nerve it sustains anastomotic relations with the radix longa; 2-4 mm. centrad of the globe this nerve splits into 8-12 filaments, which perforate the sclerotic tunic around the optic nerve and lie along its ental surface (cf. N. ciliaris longus).

SUMMARY.

A. ANATOMICAL.

1. **Origin:** (a) Ental; not demonstrated.
 (b) Proximate roots; from the mesencephal, the cerebellum, the floor of the epicaele and the metencephal.
 (c) Ectal; *sensory root*, caudad of the pons; cephalic fibres sometimes interdigitate with the caudal fibres of the pons.
Motor root, near the caudal border of the pons, sometimes wholly free of it.
2. **Foramina of exit:** Fm. ovale; Fm. rotundum; Fm. lacerum anterius.
3. **Ganglia:** (a) Entocranial, *G. gasseri*, just centrad of the foramina of exit; upon the sensory root.
 (b) Ectocranial, *G. oticum*, in the Gasserian fossa; *G. submaxillaris*, in the submaxillary gland, near the origin of the Wharton's duct; *G. spheno-palatinum*, just caudad of the foramen palatinum and foramen spheno-palatinum; *G. ophthalmicum*, upon the oculo-motor nerve, between the lateral rectus muscle and the optic nerve.
4. **Relations of Ganglia:** (a) Entocranial; *G. gasseri*, with the facial through the petrosal nerve; with N. sympathicus through filaments to the carotid plexus.
 (b) Ectocranial; *G. oticum*, with the auriculo-temporal, the pterygoid (internal), the facial, the tensor tympani and the sympathetic nerves; *G. submaxillare*, with the lingual nerve; *G.*

spheno-palatinum, with the spheno-palatine, the palatine, the vidian, the cephalic palatine and the naso-palatine nerves; G. ophthalmicum, with the oculo-motorius and the ciliary nerves.

5. **Principal Rami:** respective origins; distributions:

(a) **Nerve-trunks:** N. mandibularis at G. gasseri.

N. maxillaris at G. gasseri.

N. ophthalmicus at G. gasseri.

(b) **Rami of N. mandibularis:**

N. temporo-auricularis: The origin is at the oval foramen; the distribution is to the ectal ear, the cheek, the vibrissæ, the dorsal lip; anastomotic filaments are given to the facial nerve and to the labial plexus.

N. massetericus: The origin is at the oval foramen, the distribution is to the masseter muscle.

N. temporalis internus: The origin is common with the masseter nerve; the distribution is to the temporal muscle.

N. pterygoideus externus: The origin is at the oval foramen; the distribution is to the pterygoid muscle.

M. buccalis: The origin is at the oval foramen; the distribution is to the masseter muscle, the mucosa of the mouth and the labial plexus.

N. lingualis: The origin is common with the internal dental nerve at the oval foramen; the distribution is to the tongue, the mucosa of the mouth; it sustains commissural relations with the facial nerve through the chorda tympani, and with the hypo-glossal nerve; it gives off a pharyngeal nerve.

N. dentalis: The origin is common with the lingual; it is distributed to the mandibular teeth, to the chin; it becomes the mental nerve peripherad of the foramen mentale.

N. mylo-hyoides: The origin is common with the dental nerve; the distribution is to the mylo-hyoid muscle.

N. digastricus is a ramus of the mylo-hyoid; it is distributed to the digastric muscle.

N. pterygoideus internus: The origin is at the oval foramen; the distribution is to the pterygoid muscle.

N. tensor tympani has a common origin with the pterygoid, and is distributed to the tensor tympani muscle.

Chorda tympani is a commissural ramus from the lingual to the facial nerve.

(c) **Rami of N. maxillaris:**

N. orbitalis: The origin is at the round foramen; the distribution is to the dorsal lid, the lachrymal gland and the integument over the temple.

N. malaris: The origin is common with the orbital; the distribution is to the cheek, the dorsal lid and the labial plexus.

N. spheno-palatinus is a ramus from the maxillary nerve 5 mm. peripherad of the round foramen; it is one of the roots of the spheno palatine ganglion.

N. palatinus cephalicus is a ramus of the maxillary nerve just peripherad of the spheno-palatine, and is distributed to the rugæ of the mouth and to the palate; it also anastomoses with the naso-palatine nerve.

N. palatinus caudalis is an offset of the spheno-palatine ganglion, and is distributed to the soft palate and the rugæ of the mouth.

N. naso-palatinus is an offset of the same ganglion cephalad to the turbinated bones; its terminal filaments anastomose with the cephalic palatine.

NN. dentales are given off from the maxillary nerve just dorsad of the alveoli, and, penetrating the bone, are distributed to the maxillary teeth.

N. nasalis, *N. labialis*, *N. palpebralis*, are terminal filaments of the maxillary nerve peripherad of the infra-orbital foramen, and are distributed to the side of the nose, to the papillæ and to the integument of the dorsal lip, the vibrissæ, the labial plexus and the ventral lid.

N. vidianus is a commissural nerve from the spheno-palatine ganglion to the facial nerve through the petrosal nerve, *N. petrosus superficialis major*.

(d) **Rami of *N. ophthalmicus*:**

N. frontalis: The origin is at the foramen lacerum anterius; the nerve becomes *N. supra-orbitalis* and *N. supra-trochlearis*; it is distributed to the forehead, the tactile hairs, the dorsal lid, the conjunctiva, the lacus lachrymalis and the side of the nose.

N. oculo-nasalis: The origin is at the foramen lacerum anterius; it becomes the infra-trochlear and the caudal ethmoid nerves.

N. ciliaris longus is a ramus at the border of the optic nerve; its termination is not demonstrated.

N. ciliaris brevis is a ramus from the ophthalmic ganglion; its termination is with the long ciliary nerve.

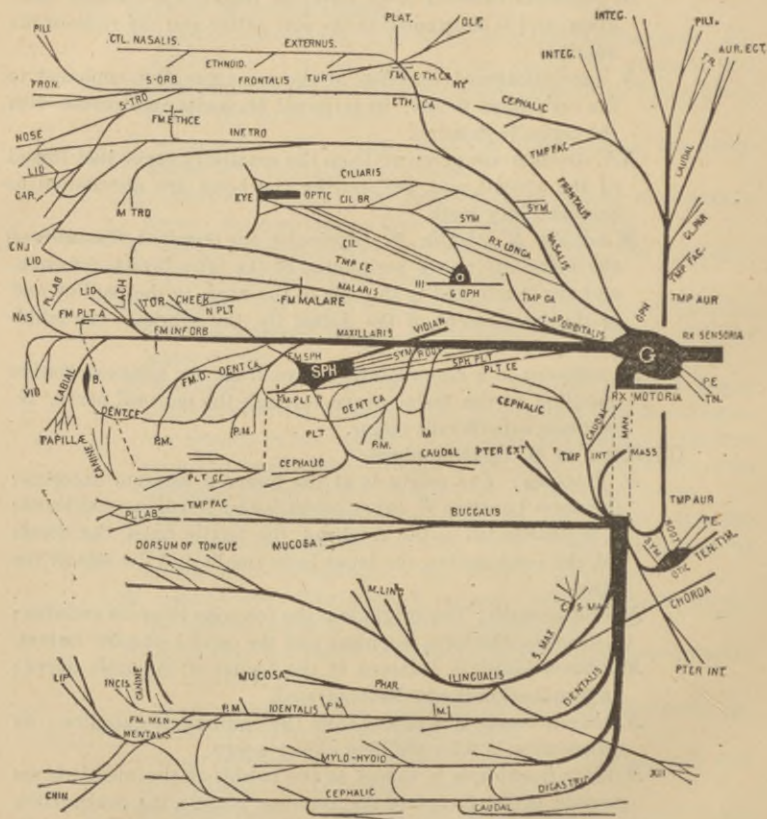
N. infra trochlearis, a ramus at the border of the mesal rectus muscle, is distributed to the trochlear muscle, the conjunctiva and the integument of the dorsal lid, the lacus lachrymalis and the side of the nose.

N. ethmoideus caudalis is the continuation of the trunk entad of the ethmoid foramen; it is distributed to the dura mater, to the turbinated membrane; it anastomoses with its platetrope, and becomes the *nervus externus*, which is given to the septum narium and to the nasal cartilage.

B. PHYSIOLOGICAL.

This nerve is chiefly sensory ; there are fibres from the motor root and from the sympathetic ganglia ; it is a nerve of the special sense, taste ; it sustains peculiar relations to glandular secretion in the lachrymal and salivary glands.

The indirect relation of this nerve with the facial, the glosso-pharyngeal and the vagus may have a profound pathological signification.



EXPLANATION OF ABBREVIATIONS USED IN THE DIAGRAM.

No attempt has been made to draw the diagram to a scale or to show relations in perspective. To avoid confusion it was thought expedient to represent even the same structure in different parts of the diagram—*e. g.*, the labial plexus and the eyelid.

III, N. oculo-motorius ; XII, N. hypoglossus ; Aur. ect., auris ectalis ;

B., ganglion of Bochdalek ; Ca., caudal ; Ce., cephalic ; Car., caruncula ; Cil., N. ciliaris ; Cil. br., N. ciliaris brevis ; Conj., conjunctiva ; Dent., N. dentalis ; Eth. ca., N. ethmoideus caudalis ; Fm. eth., foramen ethmoideum ; Fron., N. frontalis ; G., ganglion gasseri ; Gl. par., glandula parotidea ; G. s-max., ganglion submaxillare ; Hy., hypophysis ; Integ., integument ; Inf-tro., N. infra-trochlearis ; Lach., N. lachrymalis ; M., dens molaris ; Man., N. mandibularis ; Mass., N. massetericus ; M. ling., musculus lingualis ; M. tro., musculus trochlearis ; Nas., N. nasalis ; N-plt., N. naso-palatinus ; O., G. ophthalmicum ; Olf., nerve to olfactory lobe ; Oph., N. ophthalmicus ; P. M., dens premolaris ; Pter., N. pterygoideus ; Pe., N. petrosus ; Pili., tactile hairs of forehead and of ear ; Plat., the point in the meson where the ethmoid nerve joins its platetrope ; Pl. lab., plexus labialis at the angle of the mouth ; Plt., N. palatinus ; S-orb., N. supra-orbitalis ; Sph., ganglion sphenopalatinum ; S-tro., N. supra-trochlearis ; Sym., anastomotic filaments to N. sympathicus ; Ten. tym., N. tensor tympani ; Tn., nerve from G. gasseri to the tentorium cerebelli ; Tmp. aur., N. temporo-auricularis ; Tmp. fac., anastomotic filaments to the temporo-facial nerve, VII ; Tmp. int., N. temporalis internus ; Tur., filaments to the membrane over the turbinated bones ; Tr., filament to the meatus in the region of the tragus.

BIBLIOGRAPHY.

1. Allen, Harrison—A System of Human Anatomy, including its Medical and Surgical Relations. Pp. 812. Henry C. Lea's Sons & Co., Philadelphia.
2. Bourguery et Jacob—Anatomie de l'homme. Tome 3. Planches 38-39.
3. Chauveau, A.—Comparative Anatomy of the Domesticated Animals. Pp. 957. Illustrated. D. Appleton & Co., New York, 1873.
4. Claus-Sedgwick—Text-Book of Zoölogy. Pp. 967, 2 parts, illustrated. Macmillan & Co., New York, 1885. Translation of Claus's "Lehrbuch der Zoölogie."
5. Dalton, John C.—Human Physiology for Students and Practitioners. 7th ed., pp. 825, illustrated. Henry C. Lea., Philadelphia.
6. Dalton, John C.—Brain Sections. Topographical Anatomy of the Brain. 3 vols. Lea Brothers & Co., Philadelphia, 1885.
7. Encyclopædia Britannica. 9th ed. Vol. I, Anatomy.
8. Flower, William Henry—Diagrams of the Nerves of the Human Body. 3d ed. Presley Blakiston, Philadelphia, 1881.
9. Foster, N.—A Text-Book of Physiology. 3d ed., pp. 804. Macmillan & Co.
10. Foster, M., and Langley, J. N.—Practical Physiology. 4th ed., pp. 244. Macmillan & Co.
11. Gegenbaur, Carl—Elements of Comparative Anatomy. Pp. 645. Macmillan & Co.
12. Gray, Henry—Anatomy, Descriptive and Surgical. 10th ed. Henry C. Lea's Son & Co., Philadelphia, 1883.

13. Henle, J.—Handbuch der Gefäßlehre des Menschen. In drei bänden. Braunschweig, 1876.
14. Huguenin, G.—Anatomie des Centres Nerveux. Pp. 368. Paris.
15. Huxley, T. H.—Anatomy of Vertebrated Animals. Pp. 431. D. Appleton & Co., New York, 1878.
16. Journal of the Royal Microscopical Society. London and Edinburgh.
17. Martin, H. Newell—Human Body. Pp. 621, and Appendix. Henry Holt & Co., New York, 1884.
18. Mivart, St. George—The Cat: Introduction to the Study of Back-boned Animals. Pp. 557. Charles Scribner's Sons, New York, 1881.
19. Morel et Duval—Manuel de l'Anatomiste. Pp. 1152. Paris, 1883.
20. Owen, Richard—Comparative Anatomy and Physiology of the Vertebrates. 3 vols., pp. 2155. London, 1861-1868.
21. Quain—Elements of Anatomy. 2 vols. 9th ed. London, 1882.
22. Reichert, C. B.—Der Bau des Menschlichen Gehirns. Pp. 192. Leipzig, 1861.
23. Sappey—Anatomie Descriptive. Tome 3. Paris, 1879.
24. Schwalbe—Lehrbuch der Neurologie. Pp. 1026. Erlangen, 1881.
25. Smith, E. Noble—Descriptive Atlas of Anatomy. J. B. Lippincott & Co., Philadelphia, 1880.
26. Spitzka, Edward C.—The Central Tubular Grey. (Journal of Nervous and Mental Diseases, April, 1880.)
27. Stowell, T. B.—The Vagus Nerve in the Domestic Cat. (American Philosophical Society Proceedings, July, 1881.)
28. Stricker, S.—A Manual of Histology. Pp. 1106. William Wood & Co., New York, 1872.
29. Swan, Jos.—Illustrations of the Comparative Anatomy of the Nervous System. 4to. 1835. (Only known to me by title.)
30. Todd—Cyclopædia of Anatomy and Physiology. Vol. II. "Fifth Pair of Nerves."
31. Wilder, B. G.—Methods of Studying the Brain. The "Cartwright Lectures" for 1884.
32. Wilder, B. G.—Paronymy versus Heteronymy as Neuronymic Principles. 1885.
33. Wilder, B. G.—Note on the Ectal Origin of the N. Trigemini in the Cat. (Amer. Jour. Neurology and Psychiatry, I, 508.)
34. Wilder and Gage—Anatomical Technology. Pp. 575, illustrated, 2d edition. A. S. Barnes & Co., New York, 1886.

