

*Welch (W<sup>m</sup> H.)* With the Author's Compliments.  
*Br 1306*

AN

EXPERIMENTAL STUDY

OF

GLOMERULO-NEPHRITIS.

BY


WILLIAM H. WELCH, M.D.,  
BALTIMORE.

*presented by the author*

REPRINTED FROM THE

TRANSACTIONS OF THE ASSOCIATION OF AMERICAN PHYSICIANS,

JUNE 18, 1886.



PHILADELPHIA:

WM. J. DORNAN, PRINTER.

1886.



AN

EXPERIMENTAL STUDY

OF

GLOMERULO-NEPHRITIS.

BY

WILLIAM H. WELCH, M.D.,  
BALTIMORE.

---

REPRINTED FROM THE

TRANSACTIONS OF THE ASSOCIATION OF AMERICAN PHYSICIANS,

JUNE 18, 1886.

---



PHILADELPHIA:

WM. J. DORNAN, PRINTER.

1886.



## AN EXPERIMENTAL STUDY OF GLOMERULO- NEPHRITIS.

By WILLIAM H. WELCH, M.D.,

BALTIMORE.

---

OF the various processes which make up the pathological anatomy of Bright's disease, perhaps the two which at present awaken the greatest interest and the study of which promises the most fruitful results, are the changes which take place in the glomeruli and atrophy and necrosis of the epithelial cells in relation to interstitial changes. Not that by any means unanimity of opinion has been reached regarding other fundamental questions involving the relationship between the glandular, the interstitial, and the vascular lesions of Bright's disease, but the two processes named have acquired especial prominence within the last few years by the recognition of their frequency and importance.

Alterations of the Malpighian bodies, with which alone the present paper is concerned, were described with much accuracy and fulness by Beer in his excellent treatise on *The Connective Tissue of the Human Kidney in the Healthy and the Diseased State*, published in 1859, but until recently little attention was paid to his observations. Klebs, by his description in 1876 of the lesion to which he gave the name of glomerulo-nephritis, incited renewed investigation of this subject. During the last ten years processes embraced under the name of glomerulo-nephritis have been studied by Cornil, Hortoles, Friedländer, Ribbert, Nauwerck, and many others, but we owe to Langhans the most extensive and accurate observations on this subject.

A comparison of the statements of different writers concerning glomerulo-nephritis will show a wide diversity of views, not only as to the interpretation of the facts observed but as to the facts themselves. Without attempting a critical analysis of these divergent

views, the following summary of some of the conclusions of different observers will show this to be true.

At present little or no credence is given to Klebs's belief that the essential lesion of glomerulo-nephritis is proliferation of connective tissue cells which he supposed to exist between the capillaries of the glomerulus, although this belief still receives some support from the conception of Hortoles, and of Cornil and Brault, as to the connective-tissue nature of these intercapillary cells.

Langhans, in his publication in 1879, dwelt especially upon swelling, proliferation, and desquamation of the epithelial cells both of the glomerulus and of Bowman's capsule; whereas in his last article, published in 1885, he regards swelling and proliferation of the endothelium lining the glomerular capillaries as the primary and essential lesion of glomerulo-nephritis, as indeed of all forms of acute nephritis. Similar views are held by Friedländer and by Nauwerck.

Ribbert considers that the only changes are swelling and desquamation of the glomerular and capsular epithelium, changes which he regards as essential to all forms of acute and chronic Bright's disease and as answerable for many of the symptoms. He, as well as Hortoles and Cornil, refers the appearances described by Langhans as proliferation of the capillary endothelium to an accumulation of white blood-corpuscles in the capillaries.

Cornil and Brault assign an insignificant and inconstant *rôle* to changes in the epithelium of the glomerulus and of its capsule, and find the fundamental lesion of acute glomerulo-nephritis to be an exudation from the glomerular capillaries of inflammatory products composed of white blood-corpuscles, red blood-corpuscles, and an albuminous fluid.

On the other hand, Hortoles and Ribbert deny altogether the occurrence of emigration through the glomerular capillaries, basing this view on the failure to find leucocytes in the capsular space when their presence cannot be explained by emigration from capillaries adjacent to Bowman's capsule. In further support of their view they urge the peculiar structure of the capillaries of the glomerulus.

But it is not necessary to consume time in a further enumeration of the different views which are held upon this subject. Enough have been cited to show that there is room for much more investiga-

tion, as well as to bring out some of the leading points which require further study.

In the expectation that light might be thrown upon some of these doubtful points by experiments upon animals, I have made a study of the nephritis produced by acute cantharidin poisoning with especial reference to the alterations induced in the Malpighian bodies. I was led to select cantharidin because several experimenters with this substance have described in cantharidin nephritis notable changes in the Malpighian bodies, and because Cornil bases his description of acute glomerulo-nephritis chiefly upon observations of the kidneys of rabbits poisoned by cantharidin.

My experiments, which have not yet reached their completion, were made upon white rats and upon rabbits. A concentrated solution of cantharidin in acetic ether was used. I injected, subcutaneously, in rabbits usually from one-half to one centigramme of cantharidin, and in rats from one to three milligrammes. When a number of injections were made upon successive days smaller doses were used. The number of injections did not exceed five, and usually not more than two or three.

After the injection of a toxic dose the urine becomes diminished and finally suppressed; it contains albumen, hyaline casts, and a large number of leucocytes and red blood-corpuscles. The kidneys appear swollen, congested, and more succulent than normal.

The microscopical appearances in the rat's kidney will be first described. Here and there foci of infiltration with small round cells, doubtless emigrated white blood-corpuscles, can be found. They are most common around the veins at the base of the pyramid. They are often but not constantly present.

The epithelium of the convoluted tubes is in places normal in appearance, in other places it is swollen, and often the inner part of the epithelial cells is broken off and appears as a granular mass in the lumen of the tubes. Sometimes a large number of epithelial cells are devoid of nuclei, and have apparently undergone coagulation necrosis. In general, the convoluted tubes are wider than normal.

The most marked changes are to be found in the Malpighian bodies. In by far the greater number of these bodies there is between the glomerulus and Bowman's capsule a wide space partly or wholly filled with cells and granular material. These cells may be

round or oval, but they are usually polyhedral in shape. They are much larger than white blood-corpuscles, have granular protoplasm, and oval, vesicular nuclei. They are frequently arranged as a crescentic mass around the glomerulus.

Evidently we have here appearances such as have been often described as glomerulo-nephritis in the human kidney, and naturally one seeks for the same origin of these cells as that assigned for the cells similarly situated in human glomerulo-nephritis, namely, swelling and desquamation, and possibly proliferation of either the capsular or the glomerular epithelium.

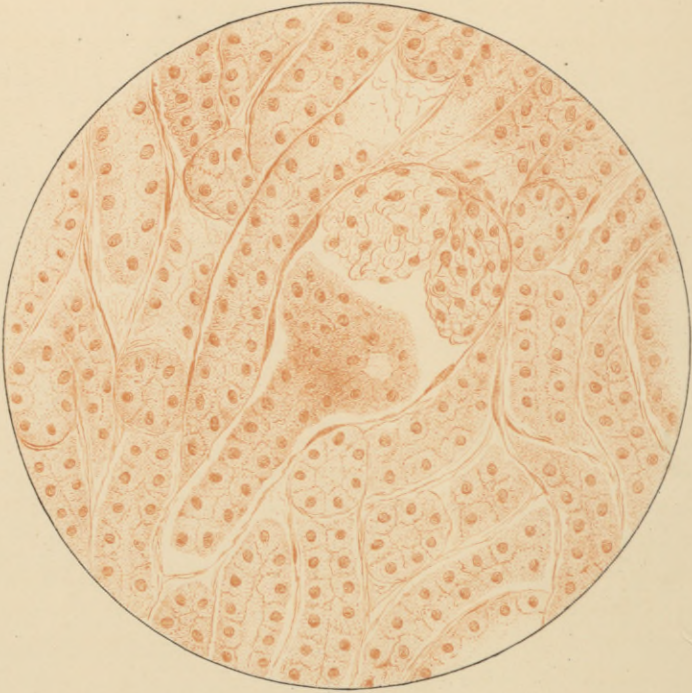The microscopical appearances in the rat's kidney, however, do not admit of this explanation. The epithelium lining the capsule of Bowman is often intact, and can be traced in its normal situation and with its normal appearances around the mass of cells occupying the capsular space. The glomerular epithelium may also preserve its normal position; more frequently it is somewhat swollen and granular, and it may desquamate. Such desquamated glomerular epithelial cells may be mingled with the cells free in the capsular space, but there are no appearances which justify the derivation of the majority of these latter cells from the epithelium of the glomerulus.

Both Cornil and Eliaschoff, whose descriptions of cantharidin nephritis are the best which I have found, and who experimented on rabbits, also came to the conclusion that the cells occupying the capsular space cannot be derived from either the epithelium of Bowman's capsule or that of the glomerulus. They argue that there remains but one other possible source, namely, emigration of white blood-corpuscles from the glomerular capillaries. They therefore consider the cells in question as white blood-corpuscles, of which the cell bodies and the nuclei are greatly swollen and altered by the action of the cantharidin or of the urine.

So far as the rat's kidney is concerned, this explanation of Cornil and of Eliaschoff cannot be admitted. These authors are in error in supposing that the cells occupying the capsular space, if not originating from the capsular or glomerular epithelium, must come from the capillaries. These cells may be derived also from the convoluted tubes in immediate communication with the Malpighian bodies, and that this is their origin, at least in part, in the cantharidin nephritis of rats can be proven, I believe, beyond question. The cells in the







Cantharadin Nephritis. White Rat.

A. Hoven & Co. Lith. Baltimore.

capsular space are identical in appearance with the epithelial cells of the adjacent convoluted tubes. The appearances presented on sections which show the communication between the capsular space and the corresponding convoluted tube hardly admit of any other interpretation than that which I have given. Here it can be seen that the mass of cells in the capsular space is in direct connection with the epithelium of the convoluted tube, and, what is especially demonstrative, there can frequently be found in this mass a group of cells arranged regularly in the form of a ring with a central space, just like the epithelium of a uriniferous tube. Without the explanation given, such an arrangement of the cells is, of course, very puzzling, especially when the Malpighian body is cut so as not to show the connection with the tube. The appearance is as if the epithelial cells lining the mouth of the uriniferous tube (or the neck of the capsule), together with the cells immediately adjacent, had been pushed mechanically into the capsular space. A similarity in appearance between the cells accumulated in the capsular space and the epithelial cells of the convoluted tubes, might be explained by the fact that under normal conditions the epithelium of the convoluted tubes may extend for a variable distance along Bowman's capsule. Such an extension of the tubal epithelium to the capsule is not particularly noticeable in the rat's kidney, and cannot be adduced to explain the peculiar appearances described. An inspection of a microscopical section or of a drawing will, I believe, leave no doubt as to the correctness of the interpretation which I have given. (See Plate.)

Observations concerning the passage of epithelial cells from the convoluted tubes into the capsular space, have been made by Kölliker<sup>1</sup> and by Argutinski.<sup>2</sup> While discussing the nature of the normal glomerular epithelium, Kölliker says :

"In hardened kidneys the epithelium of the convoluted tubes is not infrequently pressed up into the capsules, so that in many cases a membranous layer is formed which is arranged like a funnel around one end of the glomerulus."

Kölliker's observations relate, therefore, to artefacts produced by the action of the hardening fluid. In the cases of cantharidin

<sup>1</sup> Kölliker, *Handb. d. Gewebelehre*, Leipzig, 1867, p. 504.

<sup>2</sup> Argutinski, *Beiträge zur Normalen und Pathologischen Histologie der Niere*, p. 18. Inaug. Diss. Halle, 1877.

nephritis which I have studied, the accumulation of tubal epithelium within the capsules cannot be regarded as an artefact, for the same appearances can be seen in sections of the fresh kidney as in sections of kidneys hardened in Müller's fluid, chromic acid, Flemming's solution, picric acid, osmic acid, and alcohol. The change is, therefore, one which occurs during the life of the animal. The same appearances in the Malpighian bodies which I have observed in the cantharidin nephritis of white rats, have been described and figured by Argutinski as occurring in the embolic infarctions experimentally produced in dogs by injecting into the renal arteries plugs of wax. He also speaks of the possibility of producing the same change by forcible injection of fluids into the renal bloodvessels. He therefore assigns as the cause of this phenomenon the pressure exerted by dilated bloodvessels upon the convoluted tubes, whereby the protoplasmatic contents of the latter are forced upward into the capsular spaces.

The following are among the factors which may be adduced to explain the mechanism by which the cells in cantharidin nephritis make their way from the convoluted tubes into the capsular spaces: Obstruction of the uriniferous tubes, both in the cortex and in the pyramid, by desquamated and by necrotic epithelial cells, and by hemorrhages within the tubes, pressure upon the tubes from without by congested bloodvessels and by transuded serum, and cessation of the excretion of urine from the glomeruli. In consideration of these alterations in the kidney, it is comprehensible that swollen and desquamated epithelial cells in the beginning of a convoluted tube might find toward the capsular space the direction of least resistance.

There is, of course, no propriety in designating as glomerulo-nephritis the changes in the Malpighian bodies of the rat's kidney which have been described. The term glomerulo-nephritis, however, is one which is used with much latitude of significance, and embraces nearly all of the changes observed in acute nephritis in the Malpighian bodies and a large number of those found in chronic nephritis. Many of these changes are not proven to be inflammatory.

I am not able to say whether a process similar to that which I have found in the Malpighian bodies of the kidney of the rat poisoned by cantharidin, occurs also in the nephritis of other animals and of man. In the acute cantharidin nephritis of rabbits the capsular spaces

also contain granular material and cells, but the cells do not form such compact masses as in the rat's kidney, and more frequently undergo necrosis. I have not been able as yet to reach a positive conclusion as to the origin of these cells. To the descriptions which have been repeatedly given of the cantharidin nephritis of rabbits, I have to add the almost constant occurrence of necrosis of epithelial cells in certain tubes occupying the boundary zone of the pyramid and the medullary rays. These tubes appear to be the terminal portions of the proximal convoluted tubes (Endstückchen, spiral tubes). Hemorrhages within the tubes, particularly those of the pyramid, are not infrequent.

In human glomerulo-nephritis one is not generally at a loss to account for the crescentic mass of cells which frequently occupies the capsular space. The presence of these cells is accompanied with swelling and desquamation of either the glomerular or the capsular epithelium, usually of both, and these changes explain the accumulation of cells in the capsular space.

One of the leading objects in making these experiments on cantharidin nephritis was to determine whether changes were thereby produced in the glomerular capillaries. Friedländer, Nauwerck, and Langhans have called attention to the accumulation of cells in the interior of the glomerular capillaries as a frequent and important lesion of acute and of chronic nephritis. These cells they regard, for the most part, as proliferated capillary endothelial cells. Previous experimenters on nephritis make no mention of alterations in the glomerular capillaries, so far as I have been able to learn.

The technical difficulties attending the microscopical investigation of the glomerular capillaries are considerable. It is often desirable, as recommended by Langhans, that these capillaries should be injected with colorless gelatine, although when they are widely distended with cells, as in some instances of Bright's disease, such a procedure is not necessary. The sections of the glomeruli must be extremely thin, and this is best accomplished by embedding pieces of the kidney either in celloidin or in paraffin, in the latter case cutting the sections, of course, with the dry razor placed at right angles to the specimen.

In some cases of cantharidin nephritis no changes can be detected in the glomerular capillaries; in some instances, however, especially in

the rabbit, these capillaries contain a large number of small, darkly staining nuclei, readily distinguished from the larger and paler nuclei of the glomerular epithelium. These nuclei belong for the most part to spherical, granular cells, which I am inclined to interpret as white blood-corpuscles. Positive evidences of proliferation of the capillary endothelium could not be found. Changes in the capillaries comparable in degree to those observed in many cases of nephritis in human beings, I have not been able to find in experimental cantharidin nephritis.

The occlusion of the glomerular capillaries in acute and chronic Bright's disease by granular material and cells, has been most fully described in all of its histological details by Langhans. My own studies of human kidneys are essentially confirmatory of Langhans's descriptions.

Swelling of the endothelium, and accumulation of cells in the glomerular capillaries, are nearly constant lesions in acute scarlatinal nephritis. These changes in the capillaries may be the only marked lesions in the kidney, although, as a rule, there is more or less accumulation of lymphoid cells in the interstitial tissue. I have observed similar accumulation of cells in the glomerular capillaries in acute Bright's disease complicating typhoid fever, and in a number of cases of chronic Bright's disease. The changes in the capillaries are usually accompanied by other lesions of diffuse nephritis.

I would, however, call especial attention to certain cases of Bright's disease which usually pursue a subacute course, in which the accumulation of cells in the capillaries of the glomerulus is the predominant, and sometimes the only evident lesion. The following case may serve as an illustration.

The patient, who had had malaria, was the subject for two months of anasarca. The urine was scanty, albuminous, and contained casts. Death resulted from uræmic convulsions. At the autopsy there was found malarial pigmentation of the spleen and other organs, the heart was considerably hypertrophied, and the kidneys were large, the surface smooth, the capsule non-adherent, and the cortex swollen. The Malpighian bodies were large and pale. Upon microscopical examination of the kidneys, with the exception of the change about to be described, there was very little abnormal. The epithelial cells were normal. Only after careful search could a few patches of infiltra-

tion with lymphoid cells be discovered. The Malpighian bodies were rich in nuclei. The glomeruli filled completely the space enclosed by Bowman's capsule. The case seemed a puzzling one, until after the examination of very thin sections it was found that almost everywhere the glomerular capillaries were dilated, and contained a large number of cells, partly resembling white blood-corpuscles, but mostly larger, and of an endothelioid type.

Probably many pathologists have met with kidneys in which the lesions seemed entirely inadequate to explain the symptoms. Doubtless a certain number of these obscure cases belong to the class just described. It certainly is important that a careful examination be made of the condition of the glomerular capillaries.

It is not necessary to dwell upon the importance which attaches to the lesions of the glomerular capillaries which have been described. When one considers the physiological functions of the glomeruli, it is difficult to think of any lesion of the kidney more destructive of its functions than the occlusion of the capillaries of the glomerulus. It is more reasonable to refer the production of albuminuria to changes in the capillary walls of the glomeruli than to desquamation or other alteration of the glomerular epithelium. Certainly some swelling and desquamation of this epithelium are extremely common, even in cases without renal symptoms.

But while I am disposed to attach such importance to alterations of the glomerular capillaries, we are not justified in asserting, as has been done, that these changes constitute the primary and essential lesion of all cases of Bright's disease. The glomerular lesions are coördinate with the parenchymatous, the interstitial, and the other vascular lesions of diffuse nephritis.

As regards nomenclature, there is not much use in fighting against names which have gained currency, although the term glomerulitis seems to be more suitable than glomerulo-nephritis, and equally expressive. It is customary to include all of the changes of the Malpighian bodies which are not either atrophic or purely degenerative, under the name glomerulo-nephritis; but it is to be borne in mind that this term is used to designate a group of lesions belonging to diffuse nephritis, and not a disease by itself. I would suggest that the form characterized by an accumulation of cells between the glomerulus and Bowman's capsule be designated *desquamative glomerulitis*, and that

characterized by accumulation of cells, or other changes in the interior of the capillaries, be called *intra-capillary* glomerulitis, and this without prejudging the question as to the propriety of considering all of these changes as inflammatory.





