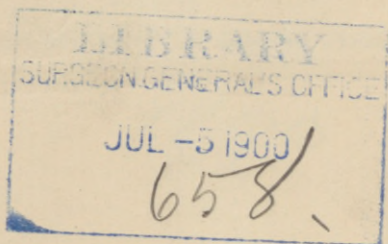



REPORT (A.) on the demon-
stration xxx



(a)

A REPORT
ON
THE DEMONSTRATION OF A NEW PRINCIPLE
IN THE TREATMENT AND CURE OF
PULMONARY TUBERCULOSIS.

1893



CONTENTS.

A VIEW OF STERLINGWORTH AND SURROUNDINGS..... Frontispiece.

PROEM.

A PREFATORY STATEMENT CONCERNING THE CURABILITY OF PULMONARY TUBERCULOSIS.

WM. J. McDOWELL, M. D.,

Late attending physician to the Baltimore Infirmary.
Late attending surgeon and chief of staff to the Presbyterian Eye, Ear and Throat Charity Hospital, Baltimore, Md., President of the Baltimore Medical and Surgical Society (1878), etc.

A CLINICAL REPORT OF FORTY-SEVEN CASES with Opinion on the Value of the Treatment and its results.

A. E. PERSONS, M. D.,

Late Professor of Materia Medica and Therapeutics
Niagara Medical College, Buffalo, N. Y.

THE DECISION OF INVESTIGATORS SELECTED TO SCRUTINIZE THE TEST AND RESULTS OF THE TREATMENT IN CERTAIN CASES AT STERLINGWORTH SANITARIUM IN MAY 1872.

(a) C. M. DANIELS, M. D.,

Buffalo, N. Y.

Surgeon of N. Y. L. E. & W. Ry.

(b) WM. J. CRONYN, M. D.,

Dunkirk, N. Y.

Late Surgeon United States Navy.

(c) JAS. E. WALKER, M. D.,

Lakewood, N. Y.,

Late of Buffalo, N. Y., and ex-President of the Hornellsville Medical and Surgical Association.

(d) MARVIN R. PALMER, M. D.,

Lakewood, N. Y.

Sterlingworth Inn
and Sanitarium.

Lakewood, N.Y.



A PRAEFATORY STATEMENT
CONCERNING THE
CURABILITY OF PULMONARY TUBERCULOSIS

In advancing the claim that Pulmonary Tuberculosis, even in its advanced stages, has now become as easily curable as any other chronic disease in our nosology, and even more so than most diseases of that class, the writer is fully aware that he is not only inviting the incredulity of his professional brethren, but that he is in danger also of bringing into serious question his competence as a scientific observer. But as this is a matter of the very utmost importance to the medical world, a solemn sense of duty impels him to announce the result of his investigations to the profession at large, even though he incur risks of the unpleasant sequelæ above alluded to. But, be that event as it may, the experience of the profession is absolutely certain, in time, to fully justify every claim herein set forth.

Nothing is impossible in a scientific sense, except that which is opposed to natural law, and there is no natural law which forbids the hope that tuberculosis may be transferred to the list of easily curable maladies.

There has been no undue haste in presenting this matter to the consideration of the profession, on the contrary it is now nearly four years since the author began his investigations on the subject, and it is more than three years since he cured his first case by the method of treatment hereafter to be described. Since this time case after case has been treated until, with an accumulated experience in about one hundred cases, he feels justified in claiming that **MORE THAN THREE FOURTHS OF ALL CASES OF PHTHISIS, TAKING ALL THREE STAGES TOGETHER, ARE PERMANENTLY CURABLE.**

In order to fully demonstrate the justness and accuracy of his observations from a scientific standpoint and, at the same time, as a necessary preliminary to the introduction of the new treatment into sanitarium

practice, he arranged, in the month of May last, to treat a number of test cases at the Sterlingworth Sanitarium, at Lakewood, on Chautauqua, N. Y. under the scrutiny of a commission of medical experts. This commission consisted of Dr. A. E. Persons, then Professor of Materia Medica and Therapeutics in the Niagara Medical College of Buffalo, N. Y., Dr. W. J. Cronyn of Dunkirk, N. Y., formerly of the United States Navy, and Dr. C. M. Daniels of Buffalo. The cases for the test were examined by these gentlemen, who although very skeptical as to the possibility of an achievement of the results claimed, nevertheless kindly consented to act. Specimens of the sputum were collected from each of the patients and were submitted to microscopic examination by Dr. Krause, Pathologist of the Niagara Medical College, and by Dr. Bradley Dorr, both of Buffalo, and the bacilli identified.

The principles involved in the treatment are as follows.

(1). Destruction of the bacilli and their spores by the production and maintainance of a change in their environment inconsistent with their continued existence.

(2). The prevention of sepsis and septic absorption by strictest attention to the most rigid principles of anti-sepsis—atmospheric, respiratory and gastro-intestinal.

(3). The promotion of the digestive, excretory and eliminative functions.

(4). Tonic and restorative treatment.

Inasmuch as respect for the laws of natural order and sequence would seem to demand that a statement of what has been accomplished should most properly precede the explanation as to how it was done, and as the story can be more properly, as well as more convincingly told by others, the author will for the present surrender the pen into other hands, reserving the discussion of the pathology and therapeutics of phthisis as the subject matter of a later article.

Wm. J. McDowell, M. D.

A CLINICAL REPORT
OF
47 CASES
OF
PULMONARY TUBERCULOSIS.

From June 1st 1892, to January 1st, 1893, forty-seven patients have been admitted to the Consumption Department of this Institution for treatment. In all these the symptoms and well marked physical signs of the disease were present. In most cases the sputum has been examined microscopically and tubercle bacilli found. Only forty of these cases have been included in the following analysis of test cases, since seven of the entire number remained under observation a few days only, and are numbered in the analysis as 1, 3, 6, 9, 12, 13 and 14. Of the forty cases remaining, nine have died, fourteen have been discharged, (eight apparently cured, two arrested and four unimproved), and seventeen are yet under treatment.

STAGES. Eleven, ($27\frac{1}{2}$ per cent) were in the second stage of the disease at the time of admission. Five of this number had all the physical signs of consolidation in both lungs, and in five the physical signs of cavities appeared during the process of resolution, but afterwards disappeared when the cavities had cicatrized. These include cases Nos. 6, 11, 17, 25, 26, 31, 36, 41, 42, 43, and 45, and the sputum of nearly all revealed tubercle bacilli on examination.

Fifteen ($37\frac{1}{2}$ per cent), were in the first half of the third stage at the time of admission, all having the physical signs of cavities, and several disease of both lungs. They embrace Nos. 5, 7, 15, 16, 22, 27, 28, 30, 32, 34, 35, 37, 40, 44, and 46.

Fourteen, (35 per cent), in the last half of the third stage, have not been perceptibly improved, some having died while undergoing treatment, or after they had been returned to their homes, and others were discharged as hopeless cases, although in nearly every instance life had been prolonged and many of the distressing symptoms alleviated. These include Nos. 2, 4, 10, 18, 19, 20, 21, 23, 24, 29, 33, 36, 39, and 47. Nine of these have already died, and the other five will probably not survive the next four months.

RESULTS OF TREATMENT. Seven apparently hopeless cases are not included because of the shortness of time they were under observation.

Twenty-three cases have been greatly improved, twelve of whom are apparently cured, while in the others the disease has been arrested. These amount to $57\frac{1}{2}$ per cent of the entire number.

Three cases now under treatment remain stationary, and the results can not be definitely determined at present. Two are in the third stage, and one in the second, but their physical condition is fair, and an arrest of the disease should result in every case, judging from the results obtained in other cases.

Since there is no present uniformity of opinion among medical men as to what constitutes a cure of tuberculosis, and sufficient time not having elapsed to demonstrate the permanency of results obtained, no attempt has been made to deduce a percentage of apparent cures. All patients discharged should be kept under observation for at least one year, and the sputum examined frequently for tubercle bacilli before satisfactory statistics can be formulated. The uniformity of results already obtained demonstrates most forcibly the value of systematic and rational therapeutics, and justifies the belief that an important advance has now been made in the treatment of pulmonary diseases. A careful study of the following records must convince all intelligent and fair minded physicians that the results thus far obtained in the treatment of this disease are more uniform than any heretofore reported. Pulmonary haemorrhage has never occurred in the Institution, although common among patients before admission. Improvement is generally noted during the first week, and continues uninterruptedly.

THE FOLLOWING LIST OF PATIENTS IS APPENDED FOR THE PURPOSE OF REFERENCE WHEN STUDYING THE ANALYSIS OF INDIVIDUAL CASES REFERRED TO BY NUMBER.

	NAME.	STAGE OF DISEASE.	TIME OF TREAT.	RESULT.
1	Chas. Swanson	Late third	Three days	Died.
2	Hugh McCulloch	" "	Seven months	Unimproved.
3	Clara Swanson	" "	Two weeks	" "
4	Jennie Kerns	" "	Fourteen weeks	Died at home.
5	Mary Norton	Early third	Four weeks	Apparently cured.
6	Mrs. L. Johnson	Late third	One week	Died.
7	Allen F. Leonard	Early third	Six weeks	Apparently cured.
8	Grace Evans	Late second	Three months	" "
9	William Cole	" "	Two weeks	Appar. improved
10	William Spoonery	Late third	Five months	Died at home.
11	John Seymour	Early second	Four weeks	Apparently cured.
12	W. G. Carson	Early third	Three days	Unimproved.
13	Mary Weatherly	Late third	Seven days	Died at home.
14	Mary Mack	" "	" "	Unimproved.
15	M. L. H.	Early third	Seven weeks	Apparently cured.
16	C. W. Juergens	" "	Eight weeks	Improved.
17	Frederick Clark	Late second	Seventeen weeks	" "
18	Edward Crowell	Late third	Five months	Unimproved.
19	Mary Quick	" "	" "	" "
20	Annie Madden	" "	One month.	Died.
21	Samuel Mitchell	" "	Seven weeks	" "
22	Herbert Tottle	Early third	Five months.	Much improved
23	Bertie Gardner	Late third	Four months	Unimproved.
24	Michael Garvey	" "	Two months	Died.
25	David Southerland	Acute phthisis	" "	Apparently cured.
26	Frank Ehrgott	Late second	Nine weeks	" "
27	Joseph Wyles†	Middle third	Five months	Much improved.
28	Edgar Barnes†	" "	" "	" "
29	William Davis	Late third	Four weeks	Died.
30	Alice Ingram†	Middle third	Five months	Undetermined.
31	William Mitchell	Late second	Seven weeks	Apparently cured.
32	Rebecca Hamill*	Middle third	Four months	Much improved
33	Geo. O'Conner	Late third	Two months	Died at home.
34	Jacob Pfeiffer*	Middle third	Eighteen weeks	Improved.
35	Maud Wood*	" "	Fifteen weeks	" "
36	Anna Nakath*	Late second	" "	Much improved.
37	John Rice*	Early third	Fourteen weeks	" "
38	Lillian Clark	Late third	Three weeks	Died at home.
39	Wm. Crittenden*	" "	Ten weeks	Unimproved.
40	Anna O'Donell*	Early third	Two months	Improved.
41	Jessie Kinsley*	Late second	" "	Improving.
42	Frank Norfield*	" "	" "	Much improved.
43	William McClean*	" "	Seven weeks.	" "
44	Margaret Spitzmiller*	Middle third	Six weeks.	Improved.
45	Lillian Briggs*	Early second	One month	" "
46	Mrs. J. F. Partridge*	Early third	Four weeks	Improving.
47	Mrs. J. F. Young	Late third	" "	Died at home.

The (* †) denotes patients still under treatment.

Case No. 1 Last part of third stage. Duration of treatment three days. Died. Disease of both lungs, ulceration of larynx, extensive destruction, organic disease of heart and kidneys, general anasarca and ascites. (Not included in the test cases).

Case No. 2 Late third stage. Duration of illness two years. Treated seven months. Discharged unimproved.

Age 29. American. Merchant. Father dead of consumption. Chronic catarrh of the stomach and intestines, catarrhal jaundice, cough with profuse expectoration, night sweats, great emaciation and weakness, very anaemic, extensive pleuritic adhesions on right side, upper half of lung consolidated and undergoing rapid softening, with a large cavity in same. Consolidation in left lung. Tubercle bacilli in sputum.

RESULTS OF TREATMENT. Gained about ten pounds in weight, strength increased, appetite and digestion improved, rales disappeared, cavity became dry, infiltration and consolidation diminished in both lungs. Subsequently had an acute exacerbation of diseases, former symptoms reappeared, lost flesh, and after prolonged treatment, was advised to return home, his condition remaining about the same as at entrance, except that life has been prolonged and further extension prevented.

Case No. 3 Last part of third stage. Duration of treatment two weeks. Returned home unimproved. Age 17. Swedish descent. Factory girl. Family history phthisical. History of chronic catarrhal affections. Duration of illness about one year and a half. Has lost considerable flesh. Cough with profuse expectoration, night sweats and general weakness. Consolidation of the upper third of the left lung which contains a cavity. Apex of right lung infiltrated. Ulceration of the larynx. Left the Institution with no apparent improvement. (Not included among the test cases).

Case No. 4 Latter part of third stage. Duration of disease two and a half years. Time of treatment fourteen weeks. Discharged as a hopeless case, and subsequently died at home. Age 26. Irish descent. Dressmaker. No phthisical history. Cough and profuse expectoration, fever, chills, night sweats, shortness of breath, catarrh of the stomach, great weakness and emaciation, pleuritic adhesions on right side, consolidation of middle lobe with cavity. Apex of left lung infiltrated. Tubercle bacilli in sputum. Patient sent by Dr. Laban Hazeltine, Jamestown, N. Y.

RESULTS OF TREATMENT. Gained about five pounds in weight, strength increased, appetite and digestion improved, cough and expectoration greatly diminished, night sweats disappeared. Subsequently became worse, part of the old symptoms reappeared. Advised to return home in about the same condition as when she entered. Life was considerably prolonged, but she died a few weeks after discontinuing the treatment.

Case No. 5 Early third stage. Duration of disease about two years. Time of treatment four weeks. Apparently cured. Age 34. Married and the mother of several children. Family history good. Has had occasional attacks of pneumonia and bronchitis nearly every winter for several years. She takes cold very easily and has not been strong for a long time. There is cough and expectoration every morning on rising, more or less fever, and occasional night sweats. Shortness of breath, and unable to exercise without coughing. At the time of her admission she was suffering from an acute exacerbation of her disease, and was unable to perform any of her household duties. Cough was almost constant with profuse expectoration, and she had lost considerable flesh. Pleuritic adhesions on left side, depression above and below the left clavicle.

broncophony, whispered pectoriloquy, bronchial and cavernous respiration increased vocal fremitus, pleuritic friction sounds, crepitant and mucous rales throughout the apex of the left lung. The right lung was more or less infiltrated throughout its upper half. Referred by Dr. M. R. Palmer, Lakewood, N. Y.

RESULTS OF TREATMENT. Rales rapidly diminished, cough and expectoration with shortness of breath gradually disappeared, and the general health was greatly improved. She returned to the cares of her family, and during the last six months has been taking in washing to assist in defraying expenses, while her health remains good up to this time. Microscopical examination of the sputum does not reveal the presence of tubercle bacilli.

Case No. 6 Late third stage. Duration of disease about five months. Duration of treatment one week. Died. Family history good. Age 31. Swede. Married. Generally healthy up to four years ago, when she had general dropsy with ascites. In January last she had an attack of La Grippe, followed by cough and profuse expectoration, night sweats, fever, shortness of breath, loss in weight and weakness. There was consolidation of the upper third of the left lung and a cavity in its apex. The upper portion of the right lung was also consolidated, and undergoing softening. The diagnosis was made of acute pulmonary tuberculosis of both lungs.

RESULTS OF TREATMENT. After being under treatment about one week, the symptoms and physical signs had greatly improved, but she became dissatisfied and returned home where she remained about two months. The disease continued to progress rapidly and she returned to the Institution, but lived only twenty-four hours after readmission. (This case is not included among those accepted as test cases).

Case No. 7 First half of third stage. Duration of disease three years. Under treatment six weeks. Apparently cured. Age 27. American. Cigar maker. Phthisical family history. Patient has had considerable cough and expectoration during the last three years with two pulmonary haemorrhages. Has profuse night sweats, chilliness, poor appetite, and digestion much impaired. Loss of ten pounds during the last four weeks, feels weak, tires easily, and his general health is rapidly declining. Shortness of breath and severity of cough prohibit active exercise. There is marked flattening of the right chest wall, depression above and below the clavicle, diminished respiratory movement, increased vocal fremitus, whispered pectoriloquy and increased vocal resonance. Marked dullness over the upper half of the right lung, prolonged expiration, bronchial breathing, cog-wheel respiration, with crepitant and mucous rales. The apex of the lung is undergoing softening, and there are distinct physical signs of a cavity already formed. There are also evidences of infiltration and consolidation in the middle third of the left lung. Numerous tubercle bacilli were found on microscopical examination of the sputum.

RESULTS OF TREATMENT. At the time of discharge almost all physical signs of the disease had disappeared, and the patient felt better than for several years. He had gained ten pounds in weight, cough and expectoration were very slight, and night sweats were entirely absent. Has been employed as a traveling salesman during the past five months with no evidences of a relapse up to the present time.

Case No. 8 Late second stage. Duration of illness, one and a half years. Under treatment three months. Discharged apparently cured. Age 20. American. Unmarried. Family history good. Health delicate during the last three years. Contracted a cold about a year and a half ago, followed by expectoration which has continued to grow worse up to the present

time. Had influenza in January last, since which her health has been rapidly declining. Feels tired and weak, shortness of breath on exertion, some pain in the upper part of left lung, appetite poor, has lost several pounds in weight and has some night sweats. Cough troublesome. Upper third of left lung completely solidified. Marked dullness, prolonged expiration, whispered pectoriloquy, bronchial breathing, pleuritic friction, crepitant and mucous rales. Evidences that the lung was beginning to undergo softening. Referred by C. M. Daniels, Buffalo, N. Y.

RESULTS OF TREATMENT. Symptoms and physical signs greatly improved. During the process of resolution necrosis of a small portion of lung occurred, giving well marked signs of a cavity. At the time of discharge cough and expectoration had nearly disappeared, the general health was greatly improved, and there was a marked increase in weight. A very small portion of the lung still showed evidences of her disease, but these have almost entirely disappeared, and her physician reports that she is well. The cavity has evidently cicatrized.

Case No. 9 Late second or early third stage. Duration of disease about two years. Under treatment two weeks. Condition somewhat improved. Physical signs of old pleuritic adhesions, chronic bronchitis and possible cavities. Patient became dissatisfied, and returned home before definite results had been obtained. (Case not included in the analysis of test cases.) Still living.

Case No 10 Late third stage. Duration of disease about five years. Under treatment five months. Died at home after discharge. At the time of admission he was extremely emaciated, and was so weak that he had to be supported to undergo the examination. There was distressing cough with profuse expectoration, exhausting night sweats, catarrh of the stomach and intestines so that he was unable to digest the simplest kinds of food. Constant diarrhoea from tubercular ulceration of the intestines, great emaciation, and the appearance of one who could live but a very short time. Pleuritic adhesions and flattening of the chest wall were extensive on both sides. There were well marked physical signs of cavities in both lungs with extensive consolidation in their upper part. The disease was so extensive that scarcely any normal vesicular breathing could be detected anywhere. Abundant tubercle bacilli were found in the sputum. Referred by Dr. A. A. Skinner, Ashville, Chaut. Co. N. Y.

RESULTS OF TREATMENT. In a short time cough and expectoration markedly diminished, cavities completely cicatrized, night sweats disappeared, digestion improved, diarrhoea subsided, strength and flesh increased, and all the physical signs of disease had been greatly changed. The patient was able to exercise moderately, and appeared much better, although the case was considered hopeless. Subsequently many of his old symptoms reappeared, and he began to decline. His vitality had been so much impaired that he was advised to return home as a hopeless case, although the condition of his lungs had apparently much improved.

Case No. 11 Early second stage. Duration of disease could not be determined. Under treatment about four weeks. Health completely restored. Age about 34. American. Unmarried. Engineer. Present illness existed about two months, although he was subject to attacks of bronchitis every winter and took cold easily. Has not been well for a long time, and decreased in weight about twenty pounds. Coughs and expectorates every morning on rising,

and sleep greatly disturbed on account of cough. Has chilly sensations, some fever, more or less perspiration constantly, shortness of breath on exertion and poor appetite. There is flattening of the chest wall, and diminished respiratory movement on the left side, increased vocal fremitus, pleuritic friction, increased vocal resonance over the left apex. Well marked dullness, mucous and crepitant rales and bronchial breathing in the upper third of the lung. Some infiltration in the apex of the right lung. At the time of his discharge all symptoms and physical signs of disease had disappeared. At present there is no cough or shortness of breath, and he has regained his normal weight. Has been employed at his trade during the last six months, and his health has steadily improved.

Case No. 12 Referred by Dr. A. E. Persons. Late second or early third stage. Duration of present illness about six months. Under treatment three days. Left the Institution voluntarily and without improvement. Age 50. American. Soap boiler. Family history good. Four years ago had an attack of nervous prostration which lasted about a year. Six months ago a cough began, since which time he has lost twenty pounds in weight. Much worse during the last few months. Appetite and digestion poor, coughs and expectorates freely on rising, feels weak and languid, has chilly sensations and fever. Physical appearance very good. Physical signs of consolidation and softening in the apices of both lungs. Tubercle bacilli very abundant in sputum. Did not believe he had consumption and left the institution. (Not included in the test cases).

Case No. 13 Advanced third stage. Duration of illness about two years. Treated seven days. Returned home voluntarily, where she died in about four months. History of case not taken. (Not included among the test cases). Referred by Dr. Laban Hazeltine, Jamestown, N. Y.

Case No. 14 Advanced third stage. Duration of disease about two years. Under treatment seven days. Returned home voluntarily unimproved. History not taken. (Not included among test cases). Referred by Dr. Hazeltine.

Case No. 15 Early third stage. Duration of disease two years. Time of treatment seven weeks. Discharged apparently cured. Age 25. Married. American. One brother dead of phthisis, possibly infected the patient. Two years ago noticed there was a gradual loss of strength and weight, hacking cough which finally became paroxysmal and greatly disturbed her sleep. Frequent attacks of pulmonary haemorrhage, mucopurulent expectoration, shortness of breath, chilliness, night sweats, fever and loss of appetite. Pulse 120. Temperature 101 to 103. Respiration 25 to 35. Weight 119. Diminished expansion on right side, depression above and below clavicle, increased vocal fremitus, dullness at apex, prolonged expiration, increased vocal resonance, crepitant and mucous rales and bronchial breathing corresponding to area of dullness. Cavernous or amphoric respiration in extreme apex of lung. Apex of left lung infiltrated. Referred by Dr. W. J. McDowell.

Diagnosis: Small cavity in extreme apex of right lung with consolidation and infiltration of its upper third. Slight consolidation and infiltration in apex of left lung.

RESULTS OF TREATMENT. Great improvement. Cough and expectoration, night sweats and evidences of cavity have disappeared. Scarcely any physical signs remained at time of discharge. Continues well six months after discharge, and weight has increased to 140 pounds.

Case No. 16 Referred by Dr. E. A. Persons. Early third stage. Duration of disease about eighteen months. Time of treatment eight weeks. Improved. Age 30. Printer. German-American. Married. Family history good. Has had cough and expectoration since illness began, loss in weight 18 pounds, shortness of breath, weakness, chilliness, fever, night sweats, and loss of appetite. Respiratory movement diminished on left side, chest wall flattened, depression above and below clavicle. Drooping of left shoulder, increased vocal fremitus. Dullness from apex to third rib. Whispered pectoriloquy, bronchophony, pleuritic friction, bronchial breathing and mucous rales in upper third. Apex of right lung gave physical signs of an old cavity. Tubercle bacilli in sputum.

Diagnosis: Consolidation of apex of left lung with the signs of softening. Apex of right lung consolidated. Pleuritic adhesions on both sides.

RESULTS OF TREATMENT. Great improvement in local symptoms and general health. Cough and expectoration greatly diminished. No fever. Shortness of breath greatly diminished. Gained nine pounds. Not cured, but disease apparently arrested; at present managing a cigar and candy store.

Case No. 17 Referred by Dr. C. C. Frederick, Buffalo, N. Y. Late second or early third stage. Duration of illness about one year. Under treatment seventeen weeks. Much improved. Age 31. English. Married. Stone cutter. Family history good. During the six months previous to his admission he had a troublesome cough with profuse expectoration, shortness of breath, pain in right side of chest, night sweats, loss of appetite, loss of fifteen pounds in weight, fever, rapid heart's action and was very much debilitated. Examination revealed pulse 100 to 120. Respiration 25 to 30. Temperature 101. There was complete consolidation of the right lung from the apex to the upper border of the fifth rib. Expansion was greatly diminished on that side, drooping of his right shoulder, increased vocal fremitus, extensive whispered pectoriloquy, bronchial respiration, crepitation, and signs of beginning of softening in the apex. Tubercle bacilli in sputum.

RESULTS OF TREATMENT. Improvement from the beginning. Cough and expectoration, night sweats and weakness disappeared. Appetite returned. Gained seven pounds in weight. Very little shortness of breath. At time of discharge nearly all physical signs of consolidation had disappeared. There still remained a small circumscribed spot of dullness in the apex of the lung. During the process of resolution a cavity had developed which afterwards cicatrized. Expansion of the right side of the chest much increased. General health good. Discharged November 5th, 1892, as much improved but not cured.

Re-examination Jan., 21st, 1893. Has had more cough and expectoration with chilliness and fever. Has lost three pounds in weight. Consolidation has not extended, but the necrotic tissue left in the apex of the lung at the time of discharge has sloughed out, leaving a fair sized cavity. Has been suffering from septic absorption. Remaining portion of lung healthy. Few tubercle bacilli in the sputum. Advised to remain under treatment until cavity heals. At present is doing much better, and prospects for a complete restoration are very favorable. (A subsequent report of this case will be made when he is again discharged).

Case No. 18 Referred by Dr. W. F. French, Hamlet, N. Y. Advanced third stage. Duration of illness two years. Time of treatment five months. Discharged unimproved as to his physical condition, but lungs better than when he entered. On admission he gave the history of annoying cough with profuse expectoration, chills, fever, night sweats, complete loss of appetite,

indigestion, diarrhoea, great emaciation, profound anaemia, jaundice, and great physical weakness. Age about 55. American. Farmer. Married. Family history good. At the time of admission his temperature was 102. Pulse 120. Respiration 30. Respiratory movement greatly diminished on both sides with flattening of chest wall and marked depression above and below clavicle. The lungs on both sides were bound down by old pleuritic adhesions. There was extensive dullness over the middle lobe of the right lung, and in the apex of the left. Physical signs demonstrated a large cavity in the middle lobe of the right lung, and consolidation of its upper half. The upper third of the left lung was also consolidated. Abundant tubercle bacilli in sputum. Lungs were rapidly breaking down, and his attending physician regarded the case as absolutely hopeless, with only a few weeks to live.

RESULTS OF TREATMENT. During the first two months a very perceptible improvement in the symptoms and physical signs was noted. Cough and expectoration greatly diminished, appetite returned, digestive disturbances were relieved, night sweats disappeared, and he began to put on flesh. He said that he felt as well as ever except that he could not endure as much. While on a visit home he caught a severe cold from which he never fully recovered. Chills and fever returned, cough and expectoration increased, and his health began to decline. A greatly enlarged liver was noted, and he was very much jaundiced. He returned home in somewhat better physical condition than when he entered, and much less consolidation of the lungs. The breaking down process had been arrested. Life had been prolonged, and many of his old symptoms alleviated. At the present time the disease remains stationary.

Case No. 19 Referred by Dr. Hamilton, Garland, Pa. Advanced third stage. Duration of illness five years. Duration of treatment five months. Discharged unimproved. Age 26. American. Dressmaker. Unmarried. Family history good. Has had cough and expectoration during the last five years. Has lost forty-five pounds in weight. Night sweats, chills and fever. Menstruation ceased six months ago. Very anaemic and emaciated. Can walk only a short distance without exhaustion; shortness of breath, rapid heart's action and digestive disturbances. Pulse 120. Temperature 101. Respiration 30. Tubercular ulceration of the larynx. Tubercle bacilli abundant in sputum. Extensive consolidation of the right lung with a large cavity in its apex. Apex of left lung contains a small cavity with consolidation of its upper third. Tubercular deposits disseminated throughout both lungs. Pleuritic adhesions extensive on both sides. Pulmonary expansion $1\frac{1}{2}$ inches. Spirometry 30 cubic inches. This case was one of chronic fibroid phthisis with numerous small cavities and laryngeal complication. She had traveled extensively and tried a variety of climates without apparent benefit.

RESULTS OF TREATMENT. During the first three months her condition markedly improved. Cough and expectoration diminished, night sweats disappeared, fever subsided and she began to put on flesh. Her strength increased so that she was able to exercise moderately without exhaustion. After an exposure on a damp day she caught a severe cold, had an acute exacerbation which nearly proved fatal. She gradually recovered from this attack, and was advised to return to her home in about the same physical condition as when she entered. The cavities were dry and there were no evidences of softening. Her condition remains about the same as when discharged one month ago.

Case No. 20 Advanced third stage. Duration of illness three years. Under treatment four weeks. Died. Age 26. Irish-American. Unmarried. Teacher. Family history generally good. Has had cough and expectoration during the last three years, has lost forty-two pounds in weight, has hoarseness, night sweats, shortness of breath, diarrhoea during the last year. Chills, fever and indigestion. Arrest of menstruation for eight months. Very anaemic and feeble. Physical signs reveal ulceration of the larynx, extensive consolidation and a large cavity in the right lung. Apex of left lung consolidated and containing a small cavity.

RESULTS OF TREATMENT. During the first three months her symptoms greatly improved. Cough and expectoration greatly diminished, night sweats ceased, diarrhoea stopped and digestion improved. Moist rales disappeared from the lungs, the cavities became dry. Previous to entrance patient had spent a year in southern California, Montana and Colorado. The destructive process had been so extensive and the blood so long charged with toxic substances, that the vital powers were reduced to the minimum, and she died from exhaustion. Tubercle bacilli in the sputum.

Case No 21 Advanced third stage. Stone cutter's phthisis. Duration of disease about five years. Under treatment seven weeks. Age 39. English. Married. Stone cutter. Father, mother and one brother died of phthisis. Cough and profuse expectoration. Night sweats. Very short of breath. Emaciation and weakness. Physical examination revealed the presence of a cavity in each lung with extensive pleuritic adhesions and consolidation. There was also organic disease of the heart and kidneys.

RESULTS OF TREATMENT. No marked improvement took place in the patient's condition, although some of the distressing symptoms were alleviated. He died suddenly and unexpectedly of syncope. The complications were such that the system of treatment could never have produced more than temporary relief.

Case No. 22 Early third stage. Duration of disease about one year. Under treatment about five months. Condition greatly improved. Age 20. Unmarried. Three members of his father's family phthisical. The patient had been somewhat irregular in his habits. Present illness followed an attack of pneumonia. Troublesome cough and profuse expectoration. Chilliness, fever, loss in weight thirty-five pounds. Very weak. Slight exertion followed by exhaustion. Appetite and digestion poor. Frequent headaches. There were physical signs of consolidation of the upper third of the right lung, and a medium sized cavity in its apex. Infiltration and consolidation in the apex of the left lung. Right side chest wall flattened, depression above and below clavicle, diminished respiratory movement, increased vocal fremitus, dullness from apex to fourth rib and to lower angle of scapula, whispered pectoriloquy, bronchophony, cavernous and bronchial breathing. Gurgling, mucous and crepitant rales, pleuritic friction. Left lung, prolonged expiration, bronchial breathing, whispered pectoriloquy in the apex. Temperature 102. Pulse 120. Respiration 28. Spirometry 110. Expansion $2\frac{1}{2}$ inches. Weight 98. Tubercle bacilli abundant in sputum.

RESULTS OF TREATMENT. Examined January 21st, 1893. Weight 114. Spirometry 160. Expansion $2\frac{3}{4}$ inches. Pulse averages from 90 to 100. Temperature ranges about normal, occasionally rises to 101 for a short time only. Respiration about 20. Cavity dry. No rales in either lung. No evidences of softening. Consolidation still present in the upper third of the right lung and slight infiltration in the apex of the left. Cavity contracting.

Chest wall more flattened, but expansion increased. Physical condition greatly improved. Can endure active exercise without exhaustion. Appetite and digestion good. Cough and expectoration greatly diminished. Tubercle bacilli still present in sputum, but their number is diminishing and character changed. Patient advised to remain in the Institution, although feeling perfectly well so far as his physical condition is concerned.

Case No. 23 Referred by Dr. A. E. Persons, Buffalo, N. Y. Advanced third stage. Duration of illness about eighteen months. Under treatment four months. Unimproved. Age 23. American. Unmarried. Stenographer. Cough and expectoration, fever, night sweats, disordered digestion, emaciation, weakness, shortness of breath and almost complete aphonia. There were pleuritic adhesions on both sides. Respiratory movement greatly diminished, but rapid. Physical signs of extensive consolidation of the right lung with large cavity in its apex. Consolidation of the left apex which contains a small cavity. There were numerous gurgling, mucous and crepitant rales in both lungs. Infiltration of the right lung extending from apex to its lowest part. Tissues rapidly breaking down and the ulceration had destroyed the vocal cords. The condition was one of chronic fibroid phthisis with tubercular deposits disseminated throughout both lungs. Spirometry forty cubic inches. Patient had spent several months in Nebraska but was not benefited by the climate. Tubercle bacilli abundant in the sputum. Family history phthisical.

RESULTS OF TREATMENT. The disease was arrested for a time, cavities became dry, and nearly all rales disappeared. Fever, chills and night sweats very much lessened. Strength increased and there was a slight gain in weight. Subsequently she had a relapse, and was advised to return home as a hopeless case. Her condition continues to be about the same as when she entered, although at present the disease remains stationary.

Case No. 24 Advanced third stage. Duration of illness about nine months. Under treatment two months. Died from exhaustion. Age about 30. Irish. Married. Prize fighter. Family history good. Distressing cough and profuse expectoration. Great muscular weakness. Emaciation, digestive disturbances, diarrhoea, chills, fever, profuse night sweats, aphonia and symptoms of approaching dissolution. There was complete consolidation of the left lung from apex to the lower border of the fifth rib, and the remaining portion was infiltrated with tuberculous deposits. The upper portion of the lung had been completely destroyed, leaving nothing but a cavity from apex to fourth rib. The disease progressed uninterruptedly to the end. Autopsy confirmed diagnosis, and revealed numerous deposits of tuberculous matter in right lung. The case was one of acute pneumonic phthisis with probable gangrene of the upper third of left lung.

Case No. 25 Acute phthisis, advanced stage. Duration of illness about four weeks. Under treatment two months. Apparently cured. Age 50. American. Married. Laborer. Family history good. Cough began four weeks before admission, grew rapidly worse, had chills, fever, sweatings, shortness of breath and rapid emaciation. At the time of admission he appeared very ill. His cough was almost constant and expectoration profuse, copious perspiration. Mental faculties dull, semi-conscious condition. Temperature 102. Pulse 130. Respiration 40. There was extensive dullness over both lungs, more marked over middle lobe of the right. Bronchial breathing, mucous and crepitant rales, and the physical signs of extensive infiltration of both lungs. During the first week he improved somewhat and the localized disease was better defined. The middle lobe of the right lung was

completely consolidated, and the upper third was infiltrated with tuberculous material. There was well marked cavernous breathing, and afterwards distinct cracked-pot sounds. Tubercle bacilli found in the sputum.

RESULTS OF TREATMENT. From the history of the case it was inferred that this was one of acute pneumonic phthisis, the destruction of lung tissue and the presence of tubercle bacilli proving its tuberculous character. Recovery was rapid and complete. Cough and expectoration rapidly diminished, temperature, pulse and respiration became normal, he gained twenty-seven pounds in weight, and at the time of his discharge no evidences of disease existed, except a slight prolongation of the expiratory sounds over the cicatrized cavity. He has now been employed on an oil lease during the past six months, exposed to all the changes of climate without any special care of himself, and at the present time is perfectly well and strong. This case is especially interesting because of the rapid progress and extent of the disease as well as the completeness of the recovery. Five different physicians examined the patient and can testify to the result.

Case No. 26 Late second stage. Duration of illness seven months. Under treatment two months. Apparently cured. Age 26. German-American. Unmarried. Traveling salesman. Family history good. Has suffered from chronic catarrh of the stomach during the last three years. Seven months ago caught a severe cold, followed by a distressing cough and profuse expectoration. Has fever, chilliness, night sweats and loss of appetite. Has lost twenty-five pounds in weight, and health has declined rapidly. Has had five pulmonary haemorrhages. Treated in Cleveland three months by the Salisbury method without improvement. Drooping of right shoulder. Chest wall flattened, respiratory movement diminished, vocal fremitus increased, prolonged expiration; whispered pectoriloquy in apex. Tubercle bacilli abundant in sputum. Upper third of right lung consolidated and softening already begun. Apex of left lung infiltrated.

RESULTS OF TREATMENT. Weight has increased ten pounds. No fever or night sweats. Stomach much improved by washing. Spirometry 270 cubic inches. Expansion 4 inches. Physical condition good. Expiratory murmur slightly prolonged; and a few mucous rales remain in right apex. No symptoms of consolidation. Has been working every day in a hardware store during the past two months, and remains well.

Case No. 27 Middle third stage. Duration of illness three years. Under treatment four months. Greatly improved. Age 31. German-American. Married. Traveling salesman. Family history good. Typhoid pneumonia three years ago followed by cough and copious expectoration, heavy and purulent. Has lost twenty pounds in weight during his illness. Cough so troublesome at night as to prevent sleep, unable to lie down. Was obliged to sit up for ninety-four consecutive days at one period of his sickness. Chills, fever, night sweats, digestive disorders, chronic catarrh of the stomach, and vomiting of food. Shortness of breath on exertion. Copious haemorrhages. Has spent the last two years at prominent health resorts, namely, the Adirondack Mountains, Ashville, Aiken and Colorado. The effect of climate retarded the progress of the disease but did not check it. When admitted his temperature was 100, pulse 100 to 120. Respiration 25 to 30. Spirometry 80 cubic inches. Chest expansion two inches. Weight 108. Sputum contained tubercle bacilli. Expansion diminished on both sides, but more marked on the left. Some depression above and below clavicle. Increased vocal fremitus over lower half of left lung. Marked dullness over entire half of left lung posteriorly.

Prolonged expiration, bronchial breathing, broncophony, mucous and crepitant rales extensive throughout lung. In the lower lobe could be detected deeply seated rales and amphoric or cavernous breathing with gurgling, whispered pectoriloquy etc. A diagnosis of chronic pneumonia with pulmonary tuberculosis had been made. There was extensive consolidation of the left lung with a deep seated cavity in its lower portion. The apex of the right lung was also infiltrated.

RESULTS OF TREATMENT. Patient has greatly improved. Present weight 122 pounds. Spirometry 150 cubic inches. Correspondingly increased chest expansion. Cough and expectoration greatly diminished. The sputum is now mucous and frothy in character. Can lie in any position without bringing on paroxysms of coughing. General appearance good. Strength increased, can exercise without fatigue. Shortness of breath much less. Pulse and temperature normal. No tubercle bacilli in sputum. Dullness remains over lower half of left lung. Cavity dry and contracting. Rales have almost disappeared. Consolidation much less. Patient having tried many varieties of climate without marked benefit, says that this system of treatment is the only thing which has seemed to hit his case. He has been advised to remain in the Institution somewhat longer in order that the consolidation may still further diminish. At present engaged as gymnasium instructor to the other patients. Patient referred to us by Dr. Laban Hazeltine, Jamestown, N. Y.

Case No. 28 Middle third stage. Duration of illness two years. Under treatment five months. Much improved. Sent by Dr. C. C. McDowell, Baltimore, Md. Age 22. American. Unmarried. Traveling salesman. Phthisis in the family. In September, 1890. had a sore throat and numerous small haemorrhages. Six months afterwards troublesome cough and profuse expectoration with several copious pulmonary haemorrhages. States that he had in all about seventy-five haemorrhages, some of them very large. Cough and expectoration so troublesome as to interfere with sleep and recumbent position. Had much fever, chills, exhausting night sweats, great physical weakness, disordered digestion, shortness of breath, palpitation of the heart, and all the symptoms of rapid breaking down of lung tissue. Had lost sixteen pounds in weight. Tubercle bacilli abundant in sputum. Physical examination revealed great diminution in the respiratory movement of the left side, marked depression of chest wall in its upper third anteriorly. Drooping of the left shoulder. Increased vocal fremitus. Flatness over the upper half, and dullness of the lower half. Crepitant, gurgling and mucous rales, bronchial and cavernous respiration, broncophony, whispered pectoriloquy, cracked-pot, pleuritic friction, exaggerated heart's action, with displacement of its apex beat, and mitral murmur. This was evidently a case of pneumonic phthisis with almost complete consolidation of the upper half of the left lung which was undergoing rapid softening, and already contained a very large cavity filled with fluid. The rest of the lung was infiltrated throughout its whole extent. The entire lung was bound down by extensive pleuritic adhesions. There also existed mitral regurgitation with dilatation of the ventricles. On account of the extensive destruction of the lung tissue, the profound anaemia and weakness of the heart muscle, the patient was unable to take any active exercise without great exhaustion. He could walk not more than half a block, could not climb stairs, and spent most of the time in a lounging attitude.

RESULTS OF TREATMENT. At present his temperature seldom rises above normal. Cough and expectoration have greatly diminished, night sweats have ceased, no haemorrhage since he began treatment, appetite and digestion good,

can exercise moderately without fatigue, shortness of breath or palpitation of the heart, climb two flights of stairs without difficulty. Has gained ten pounds in weight, and chest expansion increased. The upper part of the left lung is still consolidated, cavity dry and contracting, rales nearly disappeared, and general appearance greatly improved.

NOTE. The result thus far obtained in the treatment of this patient has surprised all who have watched his progress. No hope of a cure or arrest of the disease was entertained at the time of his admission, but it is very evident that the disease has been arrested, and from present indications it seems that the cavity will entirely cicatrize. He will be advised to remain under treatment for several weeks.

Case No. 29 Advanced third stage. Duration of illness about two years. Under treatment four weeks. Died from an acute exacerbation after exposure. Age about 33. Canadian. Married. Merchant. Several members of the family had died with phthisis, two brothers during the past summer. Patient had tried climatic treatment without benefit, and came to the Institution as a last resort. There was extensive consolidation and cavities in both lungs, and great shortness of breath because of imperfect oxygenation. Unable to climb stairs or to exercise without great fatigue. Lungs undergoing rapid softening. No apparent benefit derived from treatment. Disease continued to progress, and after being chilled while out riding, he grew rapidly worse and died quite suddenly from asphyxia, due to an acute congestion of the lung tissue not already diseased.

Case No. 30 Early third stage. Duration of illness about four years. Under treatment five months. Ultimate result can not at present be determined. Age 22. Canadian. Unmarried. Stenographer. One sister died with consumption. A slight hacking cough without expectoration began about five years ago, since which time the health has gradually declined. During the past year cough and expectoration have been very troublesome. She has suffered from chilliness, fever, night sweats, shortness of breath, palpitation of the heart, disordered digestion, a loss of 28 pounds in weight, pulmonary haemorrhage and other symptoms of impaired nutrition. Temperature averaged about 100. Pulse 110 to 120. Respiration 25 to 30. Spirometry 60. Weight 102. Chest expansion 2 inches. Respiratory movement markedly diminished on left side. Depression above and below clavicle. Emaciation well marked. Increased vocal fremitus over the upper third of left lung. Dullness from apex extending to upper border of fourth rib, and to lower angle of scapula behind on left side, and to third inter-space on right side. Bronchial, broncho-vesicular and loud cavernous respiration in the upper lobe of the left lung. Broncophony, mucous and crepitant rales throughout its upper third. Physical signs of consolidation in the apex of the right lung. Upper third of left lung consolidated and softened, with a cavity in its apex. Tubercle bacilli in the sputum.

RESULTS OF TREATMENT. Physical condition not perceptibly improved. Disease advanced slightly since admission, but now quiescent. Patient better than four weeks ago. A heart murmur was detected on entrance, due to weakness of the heart muscle and dilatation of its cavities. There is still much shortness of breath on exertion, occasional chills and fever, but no evidences of present softening and breaking down. Cavity dry. Progress has not been satisfactory.

Case No. 31 Late second stage. Duration of disease about one year. History of pulmonary haemorrhages seven years ago, but subsequently

regained his health. Under treatment seven weeks. Apparently cured. Age 35. American. Hotel clerk. Married. Family history good. Habits irregular. Has had about twelve haemorrhages during past year, sometimes very copious. Cough and expectoration very troublesome which interfered with sleep. Breathed with difficulty when lying down. Fever, night sweats, loss of appetite, loss in weight ten pounds and shortness of breath on exertion. Much pain in the chest. Rapidly growing worse. Respiratory movement diminished on right side. Increased vocal fremitus, prolonged expiration, bronchial breathing. Marked dullness, crepitant and mucous rales throughout its upper third. Consolidation and the beginning of softening of the apex of the right lung, but no evidences of a cavity. Sent by Dr. G. H. Witter, Wellsville, N. Y.

RESULTS OF TREATMENT. Condition much improved. Gained seven pounds in weight. Pain, shortness of breath, and night sweats have disappeared. Very little cough and expectoration. Sleeps well and appetite good. Feels well and strong. Discharged October 25th, 1892. No evidences of disease in left lung. Slightly prolonged expiration, and diminished pulmonary resonance in the apex of right lung. No rales. His physician writes that his condition has continued to improve. Has not had a return of his haemorrhages since he began treatment.

Case No. 32 Middle third stage. Duration of disease about eighteen months. Under treatment four months. Disease apparently arrested. Age 47. American. Unmarried. Milliner. Sister and brother died from consumption. For nearly two years has had a troublesome cough with expectoration. Since she had an attack of influenza about nine months ago has been much worse. Has lost several pounds in weight, feels weak, shortness of breath on exertion, night sweats, appetite and digestion poor, and constant pain in left side of chest. Physical examination reveals well marked emaciation, depression of chest on right side, less marked over the left side. Respiratory movement greatly diminished on both sides from extensive pleuritic adhesions. Increased vocal fremitus, marked dullness, prolonged expiration. Broncho-vesicular breathing, cavernous respiration, gurgling, mucous and crepitant rales throughout the upper half of right lung. Physical signs of consolidation in the apex of the left lung. The condition is one of chronic fibroid phthisis with a medium sized cavity in the apex of the right lung, and probable dissemination of tubercular deposits in both lungs undergoing softening. Pleuritic adhesions are extensive. The larynx congested and the vocal cords thickened. Temperature 100. Pulse 100. Respiration 35 to 40. Spirometry 45. Chest expansion two inches. Weight 84 pounds. Tubercle bacilli in sputum.

RESULTS OF TREATMENT. Cough and expectoration greatly diminished. Shortness of breath much less, no night sweats, appetite and digestion good. Has gained about six pounds in weight. There still remains the physical signs of a cavity which is dry and contracting. No rales or indications of softening. Condition is much improved. Spirometry increased to 65, but expansion limited on account of extensive pleuritic adhesions. Patient says she feels well. Still remains under treatment.

Case No. 33 Advanced stage of fibroid phthisis. Duration of disease about five years. Has been traveling throughout the west during the past three years seeking benefit from a change of climate. Treated four months in Harper Hospital in Detroit by Drs. Shurley and Gibbes without more than temporary benefit. Age about 24. American. Office clerk. Unmarried. Has had several pulmonary haemorrhages. Physical examination revealed extensive consolidation and destruction in both lungs. Patient was

Greatly emaciated, and confined to his bed the greater part of the time during his stay in the Institution. No encouragement of cure or permanent benefit was given to himself or his friends. After eight weeks treatment without benefit, he was returned to his home, and lived only about two weeks. This case with several others already reported should never have been received in the Institution, since no promise of improvement could be made, and they had already reached the condition of absolute hopelessness.

Case No. 34 Middle third stage. Duration of disease about five years. Duration of treatment eighteen weeks. Much improved. Age 33. German-American. Married. Clerk. One sister dead of consumption. While working in a barber shop in the basement five years ago, his health began to decline. He had a cough with slight expectoration which has continued more or less to the present. Two years ago he had an attack of La Grippe, since which time his lungs have been much worse. He suffered for some time from fistula-in-ano, which was operated upon but not entirely cured, and there still continues a slight discharge. He has lost about ten pounds in weight. Has chilliness, a high fever every afternoon, night sweats, a troublesome cough and copious expectoration of a heavy purulent character, containing abundance of tubercle bacilli. His physical condition still remains good, his vitality not having been as yet seriously impaired. On examination there is revealed drooping of the right shoulder, depression above and below clavicle, with considerable flattening of the chest wall, and respiratory movement markedly diminished on the right side. Marked increased vocal resonance and vocal fremitus in the apex. Dullness extending from apex to fourth rib anteriorly and to lower angle of scapula behind. Prolonged expiration, broncho-vesicular, bronchial and cavernous respiration in upper third of right lung. In the left lung are found the same physical signs but less marked. There are abundant mucous and crepitant rales scattered throughout both lungs. Diagnosis of chronic disseminated pulmonary tuberculosis. Consolidation of upper half of right lung and the apex of the left. There exists a medium sized cavity in the right apex and a smaller one in the left. Extensive infiltration throughout both lungs, which are undergoing rapid softening and breaking down.

RESULTS OF TREATMENT. Cough and expectoration greatly diminished. Temperature is very seldom above the normal, pulse and respiration much diminished in frequency. Expansion of the chest increased, spirometry increased 25 cubic inches. Shortness of breath much less than when he entered. Appetite and digestion good, sleeps well, can exercise actively without fatigue and is desirous of returning home to resume his business. Has gained eight pounds in weight. On physical examination the physical signs of a cavity are found in the right apex and the middle lobe of the right lung is still infiltrated. The cavity in the apex of the left lung has cicatrized, and there is still some harsh respiration which indicated some infiltration still remaining. The cavity in the apex of the right lung is dry, and its size diminishing. No rales can be detected in either lung. The disease has been arrested apparently, and the patient's condition is certainly improving. Tubercle bacilli have diminished in numbers. Patient still under treatment.

Case No. 35 Middle third stage. Duration of illness two years. Under treatment fifteen weeks. Physical signs improved. Progress of disease arrested. Age 20. American. Married. Telegrapher before marriage. One sister died of phthisis about eighteen months ago. Other family history good. Possibly infected from the sister. Symptoms began with a cough with slight expectoration, fever and some distress in breathing, which continued until

April 1891, at which time being examined by a physician, there was found extensive consolidation of the apex of the left lung which was undergoing softening, and a distinct cavity already formed. The disease progressed uninterruptedly while the patient was under medical treatment, until finally the other lung became seriously involved. At the time of her admission, Oct., 5th, 1892, the following conditions were noted. Distressing cough with copious expectoration, purulent in character, sleep disturbed on account of cough and inability to lie down. She had lost 23 pounds in weight, and menstruation had ceased. Temperature 102. Pulse 130. Respiration about 30. There existed the symptoms and physical signs of extensive disseminated pulmonary tuberculous in both lungs, which were undergoing rapid softening and breaking down. There was a large cavity in the upper lobe of the left lung, and a smaller one in the apex of the right, over which could be distinctly heard cavernous respiration. Cracked-pot bruit on both sides. Consolidation was extensive on both sides. There were gurgling, mucous and crepitant rales in both apices. The patient's health was rapidly declining, and her condition was such that no promises could be made as to an arrest of her disease or that she would ever improve under treatment. Tubercle bacilli were abundant in sputum.

RESULTS OF TREATMENT. When admitted the patient stated that she had taken about four gallons of whiskey monthly during past eighteen months. This was immediately withdrawn and has never been administered since. Cough and expectoration greatly diminished, the sputum being mucous and frothy in character. She can sleep lying on either side and with her head low, which was impossible when admitted. She is able to climb two flights of stairs without stopping to rest, and can exercise moderately without fatigue. Appetite and digestion good, but weight remains about the same as when she entered. Infiltration and consolidation have notably diminished in both lungs. Both cavities are dry and contracting. Only a few moist rales are found in the left lung. There still remains irregular rises of temperature, probably from septic absorption. The physical condition has been much improved, the disease apparently arrested, and the life of the patient prolonged. She still remains under treatment.

Case No. 36 Late second stage or early third. Duration of illness eighteen months. Under treatment fifteen weeks. Disease apparently arrested. Referred by Dr. S. G. Dorr, of Buffalo, N. Y. Age 19. German. Married. Seamstress. Illness began with a severe attack of pleuro-pneumonia. She was confined to her bed about four months, and in the meantime was aspirated on the left side, and a large quantity of purulent fluid removed from the pleural cavity. The side had continued to discharge irregularly up to the time of her admission. During the course of her illness she had cough and expectoration, much fever, lost about thirty pounds in weight, and became so weak that she could scarcely walk. Was unable to work at any time. At the time of her admission an examination revealed the following conditions. The respiratory movements greatly diminished on the left side. Wound discharging purulent material. Increased vocal fremitus over lower half of left lung. Percussion dullness extending from apex to lower border of lung posteriorly and over the lower lobe of lung anteriorly. Bronchial, bronche-vesicular respiration, broncophony, mucous and crepitant rales extensive in lower lobe of left lung. Prolonged expiration in upper lobe posteriorly. Tubercle bacilli in sputum. Weight 116. Spirometry 80. Temperature 99 to 100. Respiration 28 to 30. Pulse 110 to 120. There was extensive infiltration of the entire left lung with consolidation of lower lobe, and commencing softening.

RESULTS OF TREATMENT. Physical condition greatly improved. Disease arrested and apparently cured. Cough and expectoration nearly absent and appetite good. Strength greatly increased, so that she is able to work in the wards of the Institution. Has gained $12\frac{1}{2}$ pounds in weight. Spirometry increased 30 cubic inches. Chest expansion 3 inches. Discharge from side ceased two months ago. There is still left some consolidation in the lower half of the left lung. Rales have entirely disappeared. Still continues under treatment.

Case No. 37 Early third stage. Duration of illness about one year and a half. Under treatment fourteen weeks. Disease arrested and patient apparently cured. Age 24. German-American. Unmarried. Machinist. Father died of stone cutter's consumption, other family history good. Illness began with cough and some expectoration, and subsequently several haemorrhages from the lungs. His health continued to decline, and symptoms grew worse. At the time of his admission he had lost about twenty pounds in weight. Was weak, was troubled from shortness of breath, and his appetite was very poor. Irregular rise in temperature. Examination revealed in the right lung, bronchial, broncho-vesicular respiration, mucous and crepitant rales, pleuritic friction, dullness, increased vocal fremitus and broncophony in the apex. The physical signs indicated consolidation of the upper third of the right lung which is already undergoing softening.

RESULTS OF TREATMENT. Cough and expectoration very slight. Physical condition much improved. Shortness of breath not troublesome. Weight has increased ten pounds. Spirometry has increased 60 cubic inches. Chest expansion greatly improved. Patient's condition is so well that he will soon be discharged.

Case No. 38 Advanced third stage. Duration of illness about two years. Under treatment three weeks. Returned home and died soon afterwards. Age about 35. American. Married. Had a cough for a long time, and every winter was confined in bed with what was supposed to be inflammation of the lungs. After an attack of influenza one year ago, her condition has grown rapidly worse. Upon examination at the time of her admission, she had all the symptoms of hectic, temperature from 100 to 102, night sweats, great weakness and emaciation. Constant cough and profuse expectoration, shortness of breath, almost complete aphonia from tubercular ulceration of the larynx, and inability to take solid food because of the great soreness in the pharynx. Physical signs revealed the presence of a large cavity in one lung with extensive consolidation, and a smaller cavity in the apex of the other. There was gurgling, mucous and crepitant rales in the upper portion of both lungs. Pleuritic adhesions were extensive and interfered greatly with the expansion of the chest. A diagnosis of chronic disseminated pulmonary tuberculosis with extensive destruction of lung tissue was made.

RESULTS OF TREATMENT. A very unfavorable prognosis was made, and the patient returned to her home unimproved. Patient referred by Dr. H. L. Atwood, Collins Center, N. Y.

Case No. 39 Advanced third stage. Duration of disease two years. Under treatment ten weeks. Condition unimproved. Referred by Dr. C. F. Howard, Buffalo, N. Y. Age 38. American. Unmarried. Journalist. Family history good. About two years ago patient had la grippe followed by pneumonia. During the following summer there was some cough and expectoration, but his general health was not much impaired. In January 1892, he caught a severe cold, since which time there has been constant cough with

profuse expectoration, severe pains in the chest, copious night sweats, loss of appetite, inability to sleep and gradual wasting. He has occasional chills and fever. On examination the following conditions were noted: Pulse 100. Temperature 102. Respiration 26. Weight 108 pounds, a loss of 26 pounds. Spirometry 130. There was well marked emaciation, drooping of the right shoulder, right chest wall considerably flattened, and respiratory movement markedly diminished. Vocal fremitus increased, upon right side from apex to fifth rib anteriorly and to lower angle of scapula posteriorly. Friction fremitus. Marked dullness corresponding to the region of increased fremitus. On right side in upper lobe of lung there is prolonged expiration, bronchial breathing, broncophony, whispered pectoriloquy, gurgling, mucous and crepitant rales, cavernous and amphoro-cavernous breathing. In the apex of the left lung there is prolonged expiration with some crepitant and mucous rales.

Diagnosis. Pneumonic phthisis, advanced third stage. Right lung consolidated from apex to fifth inter-costal space. Very large cavity in its upper third. Apex of left lung infiltrated and undergoing consolidation. Rapid softening and breaking down. Prognosis was very unfavorable. Fatal termination predicted within three months.

RESULTS OF TREATMENT. Patient has continued to decline, and has remained in bed most of the time since admission. Nearly the whole of the right lung has been destroyed, or becoming consolidated. Upper third of left lung now undergoing softening and contains a small cavity. Disease not advancing at present. Condition slightly improved during the past week. Tubercle bacilli in sputum.

Case No. 40 Early third stage. Illness began five years ago. Under treatment two months. Condition improved. Age 23. Irish-American. Married. Family history good. In 1888 patient had a pulmonary haemorrhage which was followed by a cough. From that until the present she has had about seven haemorrhages and more or less constant with expectoration, night sweats, chills, fever, and a gradual loss in weight. At the time of admission her pulse was 120. Temperature 100. Respiration 25 to 30. Spirometry 65. Chest expansion 2 inches. Weight 100 pounds. The sputum contained tubercle bacilli. There was consolidation of the upper third of the right lung, and a medium sized cavity in its apex. The left apex was infiltrated, and beginning to undergo softening. There was gurgling, mucous and crepitant rales, bronchial and cavernous respiration, and signs of present softening and breaking down. Patient has suffered from fistula-in-ano during the past two years.

RESULTS OF TREATMENT Physical condition improved. Weight increased six pounds. Spirometry 90 cubic inches. There still remains some cough and expectoration with irregular rise in temperature. The cavity in the right apex is dry, and there are no moist rales to be heard. Infiltration and consolidation diminishing in both lungs. Patient referred by Dr. S. G. Dorf, Buffalo, N. Y. The fistula mentioned above has been operated upon and is nearly well.

Case No. 41 Late second stage. Duration of illness about two years. Under treatment two months. At present improving. Referred by Dr. A. A. Hubbell, 212 Franklin St., Buffalo, N. Y. Age 34. American. Widow. Husband died from phthisis about two and a half years ago. Family history good. A hacking cough began about two years ago, and her health gradually declined, having lost ten pounds in weight. At the time of her admission she had more or less cough and expectoration, some fever, occasional night sweats, and chronic indigestion. Poor appetite and constipation. Pulse

101. Respiration 26. Temperature normal. Spirometry 142, and chest expansion $2\frac{1}{2}$ inches. Examination revealed the following condition: Right side; drooping of the right shoulder, diminished respiratory movement, increased vocal fremitus, marked broncophony, broncho-vesicular and bronchial respiration, mucous and crepitant rales, dullness over the upper third anteriorly, and to the lower angle of scapula posteriorly. There was also prolonged expiration and bronchial breathing in the apex of the left lung. Tubercle bacilli were present in the sputum. Diagnosis of pulmonary tuberculosis, latter part of second stage, and the beginning of softening. Quite extensive consolidation in the upper third of the right lung, while the apex of the left was infiltrated, and beginning to undergo consolidation. It was thought that a small cavity would form in the process of resolution.

RESULTS OF TREATMENT. During the first two weeks after admission the patient apparently improved. Cough and expectoration diminished, and she gained several pounds in weight. Subsequently she grew worse, had chills and high fever, and began to lose in weight. Her condition remained stationary during the next three weeks, after which she began to improve and at present is doing well. There still remains considerable consolidation of the upper third of the right lung, and infiltration of the apex of the left. A small portion of lung tissue is probably undergoing softening, although there are no moist rales to be heard. Prognosis: probable arrest of the disease, and eventually a complete restoration to health.

Case No. 42 Late second stage. Duration of illness about six months. Under treatment two months. Condition greatly improved. Referred by Dr. W. J. Cronyn, Dunkirk, N. Y. Age 24. English. Single. Traveling salesman. In July last he caught a severe cold which was followed by cough and expectoration, which has continued with increasing severity to the time of his admission. Had pulmonary haemorrhage, night sweats, and chills with high fever. Has been losing flesh rapidly. Has much shortness of breath, cough very troublesome and at present expectoration very profuse. Sputum muco-purulent and bloody. One sister died of consumption. Tubercle bacilli found in sputum. Pulse 105. Temperature 101 to 102. Respiration 30. Chest expansion 2 inches. Spirometry 65. Examination: drooping of right shoulder, depression above and below right clavicle, diminished expansion, increased vocal fremitus, dullness from apex to fourth rib, and to lower angle of scapula, prolonged expiration, bronchial and broncho-vesicular respiration, whispered pectoriloquy in the upper third of right lung. In the apex of the left lung, respiration is broncho-vesicular in character. Present weight 117 pounds, a loss of 35 pounds. Diagnosis, acute pulmonary tuberculosis. Consolidation of the upper third of the right lung with the beginning of softening. Left lung infiltrated in the apex.

RESULTS OF TREATMENT. Patient has greatly improved. Cough and expectoration greatly diminished, and the character of the sputum changed to frothy and mucous. Night sweats have disappeared, and there is very little shortness of breath. Has increased five pounds in weight, and strength has correspondingly increased. There still remains some consolidation in the apex of the right lung, but all rales have entirely disappeared, and the respiration is broncho-vesicular in character. Left apex is but slightly infiltrated. At present there is no regularity of fever, and no chills.

Case No. 43 Late second stage. Duration of illness one year. Under treatment seven weeks. Disease arrested and condition greatly improved. Referred by Dr. S. G. Dorr, Buffalo, N. Y. Age 19. Canadian.

Unmarried. Office clerk. Family history good. About one year ago health began to decline, he lost flesh and strength and had a hacking cough. He was advised to go into the country, where he spent two months upon a farm, and his condition somewhat improved. Soon after returning home he caught a severe cold which was followed by a bad cough with copious expectoration. In December last he had a slight pulmonary haemorrhage. Has been troubled with hoarseness about two months. On admission his pulse was 76. Temperature 101. Respiration 28. Chest expansion 3 inches. Spirometry 110. Weight 123. Diminished expansion on right side. Increased vocal fremitus, prolonged expiration, bronchial, and bronche-vesicular respiration, increased vocal resonance, sibilant, mucous and crepitant rales, and marked dullness extending from the apex to the fourth rib anteriorly, and to the lower angle of the scapula behind. In the apex of the left lung respiration was broncho-vesicular. Diagnosis: acute pulmonary tuberculosis, second stage. Extensive infiltration of the upper third of the right lung, and the apex of the left. Apex of right lung consolidated.

RESULTS OF TREATMENT. Cough and expectoration almost disappeared. Hoarseness disappeared. Physical condition greatly improved. Weight 136, a gain of 13 pounds. Spirometry 260. Chest expansion $3\frac{1}{2}$ inches. Physical signs improved. Broncho-vesicular respiration in the right apex. Dullness disappearing. Left apex nearly normal. No rales. Still under treatment.

Case No. 44 Middle third stage. Duration of illness about four months. (Probably longer). Under treatment six weeks. Physical signs and general condition rapidly improving. Patient is the daughter of Dr. J. W. Dambach, Buffalo, who with his family physician, Dr. Thos. Lothrop, of Buffalo, sent her to this Institution for treatment. Age 22. Married. German-American. Family history good. Her present illness began some time last summer, when she had chilly sensations, fever, a hacking cough, a gradual loss in weight, loss of appetite, disturbance of digestion, sleeplessness, profuse night sweats, and nervous troubles. When admitted there was very copious expectoration of a thick, muco-purulent character, shortness of breath and the ordinary hectic symptoms. Pulse 105. Temperature 101. Respiration 24. Chest expansion $1\frac{1}{2}$ inches. Spirometry 85, and weight 98 a loss of 14 pounds. There was drooping of the left shoulder, diminished expansion on the left side. Depression above and below left clavicle with some flatness of chest wall. Increased vocal fremitus, friction fremitus and percussion dullness from the apex to the lower border of the fifth rib anteriorly, and to the lower angle of the scapula on left side. Pulmonary resonance diminished in the lower half of the lung. Well marked cracked-pot opposite the second rib anteriorly. Slight dullness over right apex. Extensive gurgling, bronchial and cavernous respiration, bronchophony, whispered pectoriloquy in the upper half of the left lung in front and posteriorly. In apex of right lung prolonged expiration, bronchophony and bronche-vesicular respiration. Abundant tubercle bacilli in sputum. Diagnosis: Acute pulmonary tuberculosis. Consolidation of left lung from apex to upper border of fifth rib with extensive softening and a large cavity in its apex. Apex of right lung infiltrated and undergoing consolidation.

RESULTS OF TREATMENT. Cough and expectoration greatly diminished. Sputum becoming mucous and frothy in character. Temperature, pulse and respiration markedly diminished. Strength increasing. Night sweats have disappeared. Shortness of breath much less. Cavity dry. Rales have nearly disappeared. Infiltration and consolidation diminishing. Weight 104. Spirometry 125. Appetite and digestion good.

Case No. 45 Second stage. Duration of illness uncertain. Health has been declining for the past five years. Under treatment one month. Condition improved. Sent by Dr. J. W. Hamilton, North Clarendon, Pa. Age 22. Unmarried. American. Elocutionist. Paternal grandmother, father and two paternal aunts died of consumption. Has had a cough and expectoration during the last year. Much pain and tenderness upon the left side in the scapular region. Shortness of breath. Occasional chills, fever and night sweats. Considerable hoarseness, and soreness of throat. Pulse 100. Temperature normal, but rising irregularly. Respiration 30. Chest expansion 1 inch. Spirometry 35. Forcible expansion of the lungs being very difficult, and causing pain in the side and coughing. Weight $94\frac{1}{2}$ pounds, a loss of 6 pounds. There is drooping of the right shoulder, marked depression of the chest wall on the right side, above and below the clavicle, with diminished expansion on the same side. Vocal fremitus increased upper third anteriorly and posteriorly. Dullness over right apex, and slight dullness extending to the fourth rib, also over the lower third of the of the right lung. Some dullness over lower third of left lung. On right side corresponding with dullness are prolonged expiration, broncho-vesicular and bronchial breathing, broncophony, whispered pectoriloquy, small mucous and crepitant rales. Pleuritic friction over upper part of right lung, and base of left. Larynx hyperaemic. Vocal cords slightly thickened. Diagnosis: General infiltration and consolidation in the upper part of the right lung. Left lung infiltrated at the base. Pleuritic adhesions extensive on both sides.

RESULTS OF TREATMENT. General condition improved. Pain, shortness of breath and laryngeal complication much diminished. Very little cough and no expectoration. Night sweats disappeared. Consolidation diminished, but some infiltration still remains in both lungs. Weight $100\frac{1}{2}$, a gain of 6 pounds. Breathes much easier. Has been advised to remain under treatment two months longer.

Case No. 46 Early third stage. Duration of illness one year. Under treatment one month. Result can not at present be determined. Apparently gaining. Referred by Dr. A. A. Skinner, Framingham, Mass. Age 34. American. Widow. Father, mother, brother and two sisters died of consumption. A hacking cough began in September, 1891, and in the following December she had several pulmonary haemorrhages, and in March, 1892, she had several haemorrhages. Cough and expectoration continued to grow worse, there were irregular attacks of chilliness, fever, some night sweats, a gradual loss in weight and almost complete anorexia. Pulse 110. Temperature $99\frac{1}{2}$. Respiration 26. Chest expansion $1\frac{1}{2}$ inches. Spirometry 110. Weight 124. Sputum muco-purulent and moderate in amount. The right shoulder lower, the respiratory movement diminished on right side, sub-clavicular depression, increased vocal fremitus from apex to fourth rib and lower angle of scapula. Dullness upper third anteriorly and posteriorly, bronchial breathing, broncophony, whispered pectoriloquy, cavernous respiration, mucous and crepitant rales heard throughout upper third of right lung corresponding to area of dullness. Prolonged expiration and bronchial breathing in apex of left lung.

RESULTS OF TREATMENT. Cough and expectoration lessened. Has had some chills and irregular rise in temperature since admission. Condition has perceptibly improved during the past week.

Case No. 47 Late third stage. Duration of illness two years. Under treatment four weeks. Died. Age 21. American. Married. Tubercular family history, mother, and other near relatives having died of phthisis. Has been in a reduced condition of health four years, although for the first two years the symptoms were those only of chronic gastric catarrh. About two years ago a dry hacking cough began, which gradually increased in frequency and severity. Expectoration at first scanty and mucous in character, became more abundant and muco-purulent. There was frequent chilliness, followed by fever, progressing emaciation, anorexia, aggravating of former gastric disturbances, copious night sweats, etc. All of her symptoms took on a more acute form after her accouchment in the late spring of 1892. In the summer of the same year, 1892, in the hope of benefit from climatic change, she was taken to the Adirondack Mountains, where she was examined by Dr. Trudeau, who advised her husband to return with her to her home immediately. When visited by Dr. McDowell in October, 1892, she was already in extremis. Tubercular infiltration existed throughout both lungs, and softening everywhere. The whole upper portion of the left lung was occupied by a large cavity and another was forming in the right apex. There was a marked increase in the area of hepatic dullness, with corresponding tenderness over that region. Diagnosis: Acute phthisis, (Phthisis fulminans), engrafted on an old tubercular condition. The object of Dr. McDowell's visit was to determine whether the patient could be got into a sufficiently improved condition of health and strength to warrant her transportation to Lakewood for treatment. A temporary improvement did take place, the breaking down process was seemingly checked, portions of the infiltrated lung substance was clearing up, the cavity became dryer and rales were very much less abundant. The tenderness over the hepatic region, however, increased, and the area of dullness extended, indicating the probability of the existence of an abscess. This condition culminated when the patient had been under observation about four weeks, when the abscess broke and discharged through the air passages. She died of exhaustion within twenty-four hours after this event.

RESPECTFULLY SUBMITTED,

Albert E. Parsons M.D.

MEDICAL DIRECTOR.



STERLINGWORTH SANITARIUM,
LAKWOOD, ON CHAUTAUQUA, N. Y.
JANUARY 1ST, 1893.

THE OPINIONS OF INVESTIGATORS.

Buffalo, N. Y. Jan. 25 1893.

It is with a sense of grave responsibility that I comply with the request for my opinion upon the McDowell treatment of pulmonary tuberculosis. This is especially so when I am aware that I was probably one of the first physicians to whom the subject and details of treatment were presented by Dr. McDowell after he had satisfied himself regarding its merits, and upon said opinion together with that of other investigators experiments were made and continued at Sterlingworth Inn.

When the question of curability of pulmonary tuberculosis was first presented to me by Dr. McDowell, I very naturally gave the matter but little in any way of serious thought, but when the proposed methods of treatment were explained I could readily see the rationale of it and wondered why it had not been applied before, especially when so many bright minds have been for so many years looking for a cure or even relief from this destructive disease.

From personal observations I believe that a large percentage of cases of tuberculosis are now curable by the McDowell method.

I can but hold this opinion when I have seen several cases of the disease, that had been proven beyond the possibility of a doubt, rapidly improve and have, to all appearances, recovered, and now months later call themselves well.

As to the permanency of the cure time alone can tell, but that life has been greatly prolonged and in comfort is certain.

I also believe that those gentlemen who are conducting this work at Lakewood, are entitled to every consideration and encouragement from the medical profession for their earnest and conscientious work especially when the door is open to any physician who will come and see for himself.

Very Respectfully,

C. M. DANIELS, M. D.

In pursuance of a note to-day received asking me to give a short general statement of my knowledge of some cases of tuberculosis of the lungs under treatment at the Sterlingworth Sanitarium and my opinion as to the result of the McDowell treatment of phthisis as carried out in those cases, I cheerfully comply. It is only justice to you and other gentlemen of your Institution who are making efforts to lead out on some new and better method for the cure of consumption than that adopted by the profession generally.

In June '92 I was asked by Mr. Frisbee to be one of several physicians to examine six or eight patients at the Sterlingworth Inn. Said patients were understood to be consumptives and were there as test cases for treatment. The other physicians were Drs. Daniels of Buffalo, Palmer of Lakewood, McDowell of Jersey City, and Persons of Buffalo. The diagnosis of cases 1 to 7 was substantially as set forth in your Clinical Report of Jan. 1st, '93 which I have just read. I saw cases 8, 9, 10, 11, 17, 18, 19, and 22 shortly after date of admission and on several occasions thereafter. Case 47 I examined and treated for six weeks before admission and I corroborate your report of their condition and progress in nearly all of the essential particulars. The other patients referred to in your report I did not see or examine and therefore am unable to state anything bearing on their cases. Nos. 1 and 10 were not fair test cases. They should not in justice to the treatment be considered as even test cases at all, as the lungs and general system were so badly diseased that God Almighty could not cure them. From what I observed I am satisfied that there is much merit in the treatment and believe it a stride in advance of old methods in curing certain forms of phthisis and prolonging life in nearly all cases.

Fraternally Yours,

WM. J. CRÖNN, M. D.

DUNKIRK, N. Y., Jan. 23, 1893.

In the month of June, 1892, my attention was called by Dr. Persons to a series of experiments in the treatment of Tuberculosis which were being conducted at Lakewood, N. Y., by Dr. W. J. McDowell, of Jersey City.

Having been in active practice for a period of seventeen years with an extensive experience in the treatment of pulmonary diseases, I was skeptical as regarded any new method of treatment for the cure of Tuberculosis. The cases under examination were, many of them, in the last stage of the disease, with well formed cavities, and having all the symptoms of advanced phthisis. Cases of a similar character in my own experience had gone steadily downward until death closed the scene. My visits were frequent, and the cases were subjected to the most careful scrutiny. Much to my surprise in the majority of instances I could observe a marked change for the better in the physical signs together with an improvement in their general health.

This was a revelation, and the treatment which was fully made known to me at once appeared so rational and scientific that it seemed surprising that the principles which govern it had not long before been applied. I have had an opportunity to study every case cited by Dr. Persons, together with those being treated at the present time. Nearly all who are under examination show marked improvement in their local as well as general condition. That the change of environment brought about by the system of treatment inhibits the development and eventually destroys the bacillus tuberculosis there can be no doubt. Space will not permit a complete resume of the treatment, and as Dr. McDowell contemplates (after the experimental stage is passed) giving the therapeutics in a future article, I feel satisfied, in the interests of the profession and humanity, to append my appreciation of a treatment which, in my opinion, is the most thoroughly scientific that has ever been brought before the medical profession.

J. E. WALKER, M. D.

In reply to a request for a short statement from me as regards my opinion of the treatment for consumption originated by W. J. McDowell I would say I was present at the examination of several patients who were going to take treatment at Sterlingworth Sanitarium; that after careful examination all were found to be suffering from Tuberculosis; that I carefully watched the condition of the patients from time to time; that they soon began to show signs of marked improvement all along the line, and some of them after a comparatively short time were in such condition they returned home with no physical signs to denote that they had ever suffered from tuberculosis. I have not time or space to go into a discussion of each individual case, but the improvement was general, and such as I never expected to have seen accomplished by any form of treatment, and it is but fair to state, that skeptic as I was I now believe you have a treatment that will do more for people suffering from consumption, than any other in the world.

I have examined the report of the Medical Director; have personally examined nearly all the cases, and can frankly state that it is in no way exaggerated.

Respectfully Yours,

M. R. PALMER, M. D.

JANUARY 21, 1893.

