

Kellogg (J. H.)

LIBRARY
SURGEON GENERAL'S OFFICE

OCT.-10-1898

617.

New Form of Posterior Colporrhaphy.

BY J. H. KELLOGG, M. D.,
of Battle Creek, Mich.

The necessity for some relief from the distressing inconveniences attending complete procidentia and extreme cases of prolapse of the vaginal walls, has led to the origination of a great variety of operations for the purpose of diminishing the size of the vagina, a procedure commonly known as colporrhaphy. As each new method has been brought forward by its originator, it has been advocated as obviating the defects of methods previously employed. But, one by one, the various methods thus far introduced have proved wanting. The difficulty experienced with all methods alike has been that, however much the vaginal canal might be narrowed by the operation, the wedge-shaped uterus, steadily acting in a downward direction, has in time succeeded in reproducing the original condition. The one exception to this history of failure has been the median colporrhaphy of Lefort. But this procedure, admirable as it is in the cases to which it is adapted, is evidently justifiable only in the cases of women who have passed the menopause, since the strong median raphe produced by the operation necessarily presents an insurmountable barrier to parturition. There are also cases in which this operation might be considered objectionable upon other grounds. After making thorough trial of the various approved forms of colporrhaphy for the relief of subinvolution, cystocele, and procidentia, some five or six years ago I adopted a method of operation which, so far as I know, is novel, and which it is the purpose of this paper to describe.

This operation is especially adapted to the posterior wall of the vagina. The operation consists in the removal of a longitudinal strip of mucous membrane from the posterior

vaginal walls, the form of which is indicated in the accompanying cuts. The peculiarity of this part of the operation consists in the bifurcation of the denuded surface at its inner extremity, the cornua being made to converge and extend upwards on either side of the cervix so as to include about two-thirds of the circumference of the vaginal canal. The purpose of this form of denudation is to create, by uniting the edges of the wound, a pouch to receive the cervix uteri, the advantages of which will be presently explained. The surfaces of the wound are united in such a manner as to produce, not simply a superficial line of union, but in addition to this, an artificial thickening of the posterior vaginal wall subjacent to the superficial line of union, for the purpose of strengthening the relaxed and weakened structures. The following is a brief description of the operation:—

The operation consists of four steps—

(1) *Mapping out the area to be denuded.*—The patient being placed upon her back in the lithotomy position, the vaginal orifice is enlarged by means of retractors so as to bring the cervix uteri into view, and enable the operator to determine the amount of narrowing required. I mark out the area to be denuded by means of traction sutures ten or twelve inches in length, which are introduced thus: Seizing the mucous membrane in the meridian line about one inch in front of the cervix A (this suture is not shown in the cut),

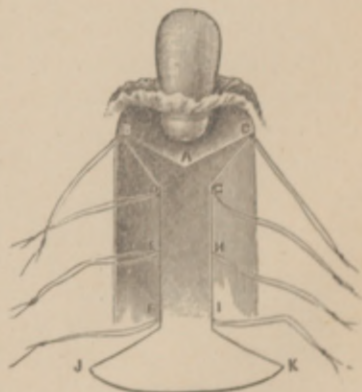


FIG. 1.

a needle armed with a piece of suture silk about two feet in length is passed through the fold of membrane held by the forceps, and the two ends tied. The hold of these seizing forceps being now released, the mucous membrane is seized at another point to the right or left, one-third of the

circumference of the vagina. A traction suture is introduced as before, and another upon the opposite side in like manner, B and C, Fig. 1. Other traction sutures are introduced at points marked D, E, F, G, H, and I. Finally the external points J and K are fixed, and indicated by a slight incision, or a snip with the point of the scissors.

(2) *Denudation.*—Starting at K, remove a strip of mucous membrane along line of union between the skin and the mucous membrane reaching to J. A similar strip is removed along the line K I, and another along the line J F. The space included between the points K I and J F may now be rapidly denuded by dissecting off narrow strips from right to left. Now drawing down the traction sutures attached to the points I and H, a fold of membrane is raised up along the crest of which a strip of membrane may be dissected up, reaching from I to H. In a similar manner dissect up a strip on the opposite side. Now denude the surface up to the points E H in the same manner as before.

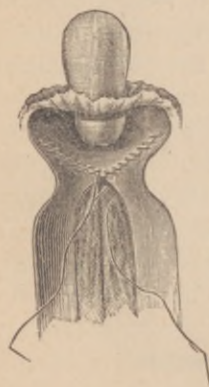

FIG. 2.

Then make taut the traction sutures H and G so as to raise a fold, and proceed as before. In like manner the sutures G C, D B, A C, and A B are successively drawn down, and the spaces inclosed between the points G C A and D B A are denuded. Hæmorrhage during the process of denudation is usually controlled by a stream of hot water sterilized by corrosive sublimate in proportion of one to four thousand, which is kept constantly flowing. Any troublesome bleeding points are secured by means of small snap forceps, which are allowed to remain in position until the edges are brought together in closing the wound. Ligatures are seldom required.

(3) *Introducing the sutures.*—We are now ready for the introduction of the sutures, Fig. 2, one of the most important parts of the operation. Two lines of sutures are introduced in the vaginal portion of the wound: (a) a continuous

deep suture; (b) a continuous superficial suture. Beginning at the apex of one of the cornuæ, a medium-sized catgut suture about fifteen inches in length is secured, and the sides of the denuded surface are carefully brought together by a buried suture from B to A. The needle should be slightly curved, being made to dip as deeply as possible without involving danger of wounding important structures. By this means the line B D is made to approximate closely to the line B A. By means of another suture, which should be about eighteen inches in length, the edges of the mucous membrane defined by the lines B D and B A are now united by superficial sutures. When the closure of the edges of the triangle is complete, the suture should not be cut off, but should be saved to complete the closure of the superficial portion of the remainder of the vaginal wound. The cornua A G C is now treated in like manner, only that the deep suture is left long to serve as a deep suture for uniting the sides of the vaginal wound. The cornua being closed, the portion of the wound having parallel sides is next closed in like manner. I find it advantageous to carry the two lines of sutures down together, making the deep suture superficial at intervals of an inch, so as to closely unite the mucous membrane with the underlying tissues. The perineal portion of the wound is closed in the usual manner, only I do not use silver wire. If the sphincter has been torn, I employ a form of suture pin having an eye near the point, (Fig. 3) which I described in a paper published in the proceedings of the American Medical Association for 1887. I have con-




FIG. 3.

tinued the use of these pins, and consider them a great advantage over wire or any other form of suture for perineal operations, at least in most cases.

(4) *The dressing.*—This is the final step in the operation, which I endeavor to make as antiseptic as possible. The vagina should be thoroughly cleansed from any remnants of

clots. Pure iodoform is applied by means of a powder-blower, afterwards a quantity of antiseptic powder, consisting of equal parts of subnitrate of bismuth, iodoform, and tannin, is thrown in. A quantity of iodoform wool or charpie is placed against the perineum. Pads of sublimated cheese-cloth are applied, and secured by proper bandage, and the patient is put to bed. The urine must be passed through a catheter.

I have performed this operation, or some modification of it, twelve times in all, and have always secured immediate union, and, with only two exceptions, without rise of temperature of more than one degree. In each of these cases the temperature reached 101° the second day after the operation, but came down to normal the next day, and remained thus.

What I suppose to be the novel and original features of this operation are: (1) the bifurcated form of the denuded surface at its inner end; and (2) the use of the buried suture for approximating the deep surfaces of the wound. The buried suture I have employed only during the last year, but the bifurcate form of denudation I adopted several years ago.

As to the results of this operation, I find that it accomplishes what it is designed to do. The cervix being caught in the pouch formed between the cornua, is held high up, so that the fundus is tilted forward. By this means the two chief causes to which failure in other forms of colporrhaphy is due are eliminated; namely, the wedge action of the uterus in dilating the vaginal canal, and the forcing outward of the vaginal wall from the weight of the pelvic organs, the last-named difficulty being obviated by the forward position of the uterus. I find, also, that the disposition to prolapse of the vaginal walls is greatly lessened by the peculiar result obtained through the use of the buried suture. As will be readily seen, the approximation of the sides of the wound by the buried suture has the effect to produce a thick fold of tissue in the recto-vaginal septum. This fold projects into the rectal space, and forms a thick and strong pillar of tissue, forked at its upper extremity. In this

fork the cervix uteri rests, and is held backward, thus tilting the fundus forward. I can hardly see what more could be desired in an operation of this sort.

The value of this operation in cases requiring it can hardly be overestimated. In the cases in which it is the most essential, the condition of the vagina is usually such that pessaries, with the exception of those having an external support, are of no avail, unless, indeed, we except the inflated ball-pessary, which gives only temporary relief at the expense of ultimately creating a condition still more deplorable. Indeed, the patients upon whom I have performed this operation have, almost without exception, been those who had abandoned pessaries of every description after having tried everything in this line that their medical advisers could suggest, and their uniform testimony is that their condition was in the end aggravated by pessaries, instead of being helped.

I do not wish to be understood as claiming that every case of procidentia, rectocele, or subinvolution of the vagina, can be radically and permanently cured by this operation alone, but I consider this operation as a fundamental procedure for the proper treatment of these cases. Cases of retroversion and procidentia require Alexander's operation. Cases of extreme anteversion connected with protrusion of the vaginal walls, may be relieved by the same means. In the treatment of sixty cases of Alexander's operation, I frequently found this procedure of exceedingly great service as supplementary to the operation for shortening the round ligaments, and consider it a necessary procedure to insure success in this operation in cases where there is great laxity of the vaginal walls.

J. H. Kellogg ^{Md} (Battle Creek, Mich.)
New Form of Posterior Colporrhaphy.
6 pp. pap. 3 figs. no date,

