

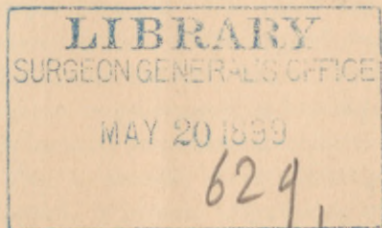
JACK (F.L.)

SOME OF THE INDICATIONS
FOR OPENING
THE MEMBRANA TYMPANI.

By FREDERICK L. JACK, M.D.

Aural Surgeon to the Massachusetts Charitable Eye & Ear Infirmary.

A ten minute paper, read at the Annual Meeting of the Massachusetts
Medical Society, June 8, 1897.



SOME OF THE INDICATIONS FOR OPENING THE MEMBRANA TYMPANI.

THE operation of opening the drum membrane for the evacuation of fluid is often neglected. The demand for this procedure becomes imperative, not only in most cases of acute middle ear inflammation, but also for the relief of fluid collected in the middle ear without acutely inflammatory movement. It is to the practicability and technique of the operation in these conditions that I would call attention.

Indications for Operation.—There are probably very few practitioners at the present time who do not recognize the importance of an early paracentesis in cases of acute middle ear inflammation accompanied with severe pain, marked injection, and bulging of the drum membrane. By the operation several desirable ends are at once attained. In the first place, the loss of blood, together with the evacuation of collected fluid, relieves the pressure, and thereby lessens, if not stops, the pain. The rapid healing of cut surfaces, as compared to that of the ragged tear generally produced by spontaneous rupture, has a decided bearing upon the subsequent improvement in hearing. I believe also that an early incision prevents the chances of mastoid complication. The ear trouble in very young children is frequently overlooked, a chance observation of aural discharge first attracting the attention. Children usually offer little in the way of objective symptoms; they seldom place

the hand over the affected ear, or in any way direct attention to the seat of trouble, whereas the general reflex nervous disorders, caused by the auditory disturbance, cover a wide range of symptoms, from slight twitching to a condition practically of opisthotonos, and to marked retraction of the legs, like that seen in acute abdominal affections.

The fact that more pronounced nervous symptoms result from middle ear inflammation in young children than in adults is chiefly due to anatomical conditions. In the attic, or upper wall of the tympanic cavity, is found a suture (*sutura petrosa-squamosa*), the connective tissue covering of which has an intimate relation with the *dura mater*. This suture in adults is closed by bone, often very thin bone, which retards or prevents the extension of the middle ear trouble to the *dura mater* or brain. An examination of the ears in infants and young children will often make clear the diagnosis, and rapid disappearance of alarming nervous symptoms will follow an early free opening of the bulging and inflamed *membrana tympani*.

There is another condition in which an opening in the drum membrane is of great service, and one the importance of which is less frequently recognized than that we have just briefly considered. I refer to the collection of fluid, either serous or mucous, in the tympanic cavity, following an acute catarrhal inflammation of the nose and throat. The symptoms naturally arising include impairment of hearing, a feeling of pressure or fullness, autophonia, tinnitus aurium, and possibly vertigo. The onset is often very sudden, and frequently follows too vigorous attempt at clearing the nose by blowing. The drum membrane upon inspection is found depressed from closure of the Eustachian tube, but there is seldom any considerable injection of blood vessels. The color of the drum varies with the relative thickness of the membrane and the nature of the fluid, serous exudation producing a straw color, mucous a dark

grey. Often the level of the fluid is indicated by a dark line. In many cases, however, due to pathological changes in the membrana tympani previous to the attack, it is impossible to see the fluid. We then rely somewhat on the history and upon hearing râles by means of the autoscope after inflation of the middle ear.

I am fully aware that many of these cases improve under other treatment, but I am equally certain that many cases of progressive catarrhal deafness are made permanently worse by neglecting to free the middle ear of its fluid contents. I make this statement advisedly, and with considerable experience in the treatment of these cases, both in the usual way, and by incision through the drum membrane. I have yet to meet a case in which complete evacuation of the fluid through an opening in the drum proved other than most satisfactory. On the contrary, it is not an uncommon experience for cases with undoubted history of fluid in the middle ear to present themselves for treatment after the usual means have been employed, with membranes collapsed held more or less firmly in place by adhesive bands. The operation is not difficult, provided the field is properly illuminated; it is only slightly uncomfortable, and the opening usually heals in twenty-four hours.

Technique of Operation.—The auditory canal and drum are first rendered aseptic by instillations of a one to five thousand corrosive sublimate solution; after drying with absorbent cotton a few drops of a 4% cocaine solution are applied to the drum by means of the cotton holder. The point of election is in the posterior lower quadrant. A very small incision is quickly made by a quick thrust of a sharp triangular knife, the fluid being forced out by inflation. The ease and rapidity of evacuation depend upon the nature of the fluid, thick mucus often requiring the use of small forceps, after presenting at the opening; serous fluid, on the other hand, escapes into the auditory canal,

and is removed by means of absorbent cotton. Several inflations of the middle ear, by means of the catheter or Politzer bag, are usually necessary to completely evacuate the middle ear. A small plug of cotton is placed in the meatus for twenty-four hours, then removed, and subsequent treatment is directed to the naso-pharynx and Eustachian tube. The relief afforded by paracentesis is immediate, and, with appropriate treatment, the danger of refilling slight.

Early paracentesis, under the two conditions I have indicated, will often avert alarming symptoms, and prevent serious results, not only as regards the hearing but even the life of the patient.

The suggestions offered in this brief communication are based not simply upon theoretical considerations but upon practical experience, and I am convinced that the importance of the subject has not been and cannot be over-estimated.

