

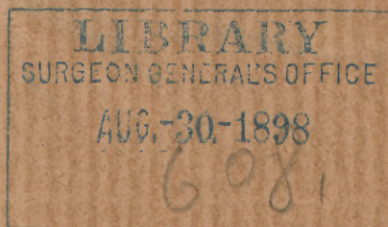
Baer (B. F.)

Primary Cholecystenterostomy by means  
of the Murphy Anastomosis Button,  
with a report of two successful  
cases, from one of which was  
obtained more than five hun-  
dred gall-stones.

---

By B. F. BAER, M.D.

Professor of Gynecology in the Philadelphia Polyclinic.





PRIMARY CHOLECYSTENTEROSTOMY BY MEANS OF THE  
MURPHY ANASTOMOSIS BUTTON, WITH A REPORT  
OF TWO SUCCESSFUL CASES, FROM ONE OF  
WHICH WAS OBTAINED MORE THAN  
FIVE HUNDRED GALL-STONES.<sup>1</sup>

BY B. F. BAER, M.D.,

Professor of Gynecology in the Philadelphia Polyclinic.

It is not necessary here, or at the present time, to plead the justification or urge the importance of surgical interference for the relief of the great and prolonged suffering, and frequently fatal termination, which results from obstruction in the biliary ducts; but taking it for granted, as proven from the literature of the subject and your personal knowledge, that medicine fails utterly to relieve in many instances, I will proceed at once to record my own experience with the latest and most successful operation which has yet been devised in gall-bladder surgery.<sup>2</sup>

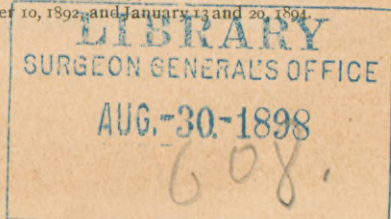
Primary cholecystenterostomy with the Murphy button has now had a fair trial in the hands of its author and of several other surgeons. The uniform success which has thus far resulted places this method far in advance of the older operation of cholecystostomy; first, because, even after cholecystostomy has been successfully performed, it is often necessary (in about one-third of the cases) to make a secondary cholecystenterostomy on account of the failure of the resultant biliary fistula to close, and second, because, in either event, by the latter operation the patient's condition is much improved, for the gall-bladder has now two permanent outlets instead of one; and as this new-made duct is of much greater calibre than the natural one any calculus that may form in the future can readily escape.

The technique of this operation is wellnigh perfect, since it is based not only upon the principle which has proven the most successful in abdominal and pelvic surgery,—viz., clean, complete, and rapid operation with immediate closure of the peritoneal cavity, but more especially because it permits of the direct discharge of the biliary secretion into the intestinal tract.

The result obtained in the cases thus far recorded has practically demonstrated that the statement of the author of this ingenious device was not too strong when he said that "this operation would produce the same revolution and favorable change in the surgery of the gall-bladder that the intra-abdominal treatment of the pedicle did in the treatment of tumors of the uterus and its appendages."

<sup>1</sup> Read by title before the Pennsylvania State Medical Society, May, 1894.

<sup>2</sup> Dr. J. B. Murphy, *New York Medical Record*, December 10, 1892, and January 13 and 20, 1894.



The first to attempt to overcome the difficulty arising from obstruction in the natural bile-tract, by cholecystenterostomy, was von Winiwarter, who, in 1881, succeeded in establishing an artificial fistula between the gall-bladder and colon after six attempts on the same patient, covering a period of sixteen months. Great credit is due Winiwarter and the patient for their remarkable courage and persistence. This operation was secondary to cholecystostomy, in which the external biliary fistula had failed to close.

In 1883, Dr. J. M. Gaston, of Atlanta, Ga., in a series of experiments upon dogs, tried to establish a fistula between the gall-bladder and duodenum, through pressure atrophy, by means of elastic ligatures surrounded by a row of serous sutures to protect the peritoneum. Although these experiments failed, Dr. Gaston is entitled to much credit for his work, as it gave an impetus to others for further efforts in the same direction. But so great were the difficulties encountered that it was nearly seven years after the publication of Winiwarter's case before another attempt was made to perform this operation on man. In 1887, Monastyrski, and, a month or two later, Kappeler, performed the primary operation by suture, the latter with success. They were followed by others, so that, according to Murphy, up to December, 1893, twenty-three primary cholecystenterostomies had been performed by different operators and different methods of suturing, but with a mortality of 35 per cent. The technical difficulties in all of these operations by suture were extreme.

In 1892, Dr. Murphy succeeded after a number of experiments in perfecting an instrument which he has named the "anastomosis button," and by which he hoped to overcome the difficulties which had hitherto been encountered in making an artificial attachment and duct between the fundus of the gall-bladder and the intestine. That he has succeeded even beyond his fondest hopes the result has shown, for by this ingenious device the new junction is accomplished by a single operation, and the mortality has been reduced from an average of at least 25 per cent. to an absolutely *nil* mortality. There have been up to this time, so far as I have been able to learn, including the two cases which I here record, nineteen operations by this method. All of these cases recovered—100 per cent! These operations were performed by nine different operators, and in all of the cases the result has been a complete restoration to health with no recurrence of symptoms.

When it is also considered that even after recovery from cholecystostomy the patient is often left with a permanent biliary fistula, which sometimes ultimately results in death from exhaustion, or compels a submission to a secondary cholecystenterostomy under far more unfavorable circumstances, the benefit obtained from the primary operation by this method appears marvellous.

It would not be just, however, to draw this comparison without calling attention to the fact that much of the earlier gall-bladder surgery was done under more unfavorable auspices than were these operations by the Murphy button. Surgery in this field was new, and, like the pioneer in all work, the operator met with the old, neglected cases which submitted to operation as a last resort. Further, the technique of abdominal surgery had not yet

been brought to the perfection which prevails at the present time. Here, as in abdominal surgery in general, the early operation, while the patient and tumor are both in good condition, gives promise of the greatest success.

*Symptoms and Diagnosis.*—The most constant and prominent symptom of biliary obstruction is paroxysmal pain in the right hypochondriac and epigastric regions. The pain is usually sharp, excruciating, and radiating to either shoulder, to the umbilical region, and sometimes over the entire abdomen; nausea and vomiting are often present. The paroxysm is sometimes followed by or associated with jaundice of more or less pronounced type. This indicates that the obstruction involves the common duct, and, if due to calculus, that the latter has probably passed from the cystic or hepatic into the common duct. When jaundice is marked, the stools are clay-colored. Partial obstruction may exist, however, without the paroxysm of pain or jaundice; the symptoms then may be simply gastro-intestinal disturbance associated with headache—biliary headache.

Physical examination is usually of value, showing enlargement of the gall-bladder and sometimes of the liver. Physical signs may, however, be entirely absent, or, if present, very difficult to make out on account of thick abdominal walls, or rigidity of abdominal muscles from fear of pain from pressure. If the abdominal wall is thin and the gall-bladder enlarged, as in one of my cases, the tumor of the gall-bladder is easily made out; but if the wall is thick, and the gall-bladder small, as in the other case, the physical signs may be simply tenderness upon pressure immediately over the gall-bladder. I have found this sign of value taken in conjunction with the rational signs.

When tumor of the gall-bladder is present, it is usually pyriform, with the small attached end or neck corresponding to the normal position of the gall-bladder, the enlarged body extending downward. It may be very mobile from elongation of the neck, so as to give rise to difficulty in differential diagnosis from movable or floating kidney, or tumor of pancreas or bowel, and, if very large, from ovarian tumor. But if its shape, peculiar position, history of case, symptoms, and the attachment of the tumor are carefully observed, diagnosis should in most cases be easily determined.

*Indications for Operation.*—This operation is especially indicated in all cases of more or less pronounced and frequently recurring jaundice or biliary colic resulting from partial or complete obstruction in the biliary ducts, if the obstruction be due to cholelithiasis or other benign disease. By other benign disease is meant a permanent narrowing of the bile-tracts from inflammatory causes within the gall-bladder or ducts (catarrhal), or from inflammatory conditions (peritonitis), or new growths, resulting in pressure from without. Of course, it is to be understood that medicinal remedies have been given a proper trial and have failed to give more than temporary relief. The operation should not be performed if a diagnosis of malignant disease is made, either before or after exploratory incision. Absence of enlargement of the gall-bladder does not contraindicate operation, but it vastly increases the manipulative difficulties and renders the procedure far from simple, especially if, in addition, the abdominal wall is thick.

CASE I.—Mrs. R., aged 36; five children and three miscarriages; last pregnancy, miscarriage, three years ago. Since the birth of the last child, six years ago, she has complained of periodical gastro-intestinal disturbance associated with the most severe headache. The attacks would usually continue for three or four days, during which time she would be utterly prostrated; they were at first invariably attended with jaundice, but later the jaundice was less marked. For many years she had been aware of the presence of a small tumor in the right umbilical region. This had been pronounced floating kidney. The tumor was at first about the size of a hen's egg. During the "bilious attacks" it would become larger and excessively tender; at these times there would be constant epigastric pain, at times associated with nausea and vomiting; the attacks would usually end with diarrhea, consisting largely of mucous evacuations. It is notable that there was at no time present in the case severe hepatic colic. The patient had been almost constantly under treatment during these years. In the fall of 1893 she consulted Dr. E. L. Vansant for a throat affection, who, on examination into her general condition, learned of the presence of the tumor. Dr. E. P. Davis then saw the patient in consultation with Dr. Vansant, and on November 24, 1893, through the kindness of these gentlemen, I was requested to take charge of the case.

The patient presented an appearance of slight cholemia with dryness of the skin and general emaciation. Physical examination revealed a tumor about the size of a goose-egg and somewhat pyriform, occupying the right umbilical region. The tumor mass was quite mobile all over the right side of the abdomen, as far down as the brim of the pelvis, but it seemed to be more at home in the hepatic region, where it was anchored. I concurred with the opinion that the tumor was a greatly enlarged gall-bladder, and that it probably contained a large number of stones. Operative measures were advised and decided upon.

Operation, February 11, 1894. An incision was made two inches to the right of the median line, beginning directly over the normal position of the gall-bladder and extending downward three inches. This exposed the enlarged gall-bladder, which was now drawn through the incision and examined. It was quite purple in color from venous congestion, but otherwise its tissues appeared to be in a healthy condition. It was very heavy and tense from the impacted stones. The cystic duct was quite elongated and distended, being also packed with calculi. The calibre of the duct was too much narrowed to admit of the passage of the stones, for the common duct seemed to be empty. A knuckle of intestine below the duodenum was next brought into the incision. Sterilized gauze was then arranged under the gall-bladder and intestine to protect the peritoneal cavity. A needle, armed with a fine silk ligature, was now inserted in the bowel, opposite the mesentery, and a stitch taken through its wall. This was repeated twice, the stitches being about one-third of an inch apart. The needle was next inserted at a right angle and a similar stitch taken; then two more stitches of like character were taken in a reverse direction parallel to the first. This formed a running thread. An incision was now made in the intestine between the par-

allel sutures, care being taken not to cut the thread in the cross suture. The button was then passed within the bowel and the ligature tied around the central cylinder. The gall-bladder was next prepared in a similar manner by the insertion of a running thread on its under side, near the fundus. Incision was now made through the wall of the gall-bladder and about a dozen of the stones were removed for the purpose of making room for the button, which was then slipped in and the suture tied around the projecting cylinder. The cylinders were then adjusted, the one within the other, and the buttons were pressed together, making a beautiful, clean, and firm coaptation. The mass was then carefully returned to the abdominal cavity and the incision closed.

The patient made a very smooth recovery, the after-treatment being about the same as that following an abdominal section for ovarian or uterine tumor. The bowels were moved on the second day, and after that every day. The temperature did not rise much above the normal. On the morning of the eighth day there was considerable intestinal pain preceding a large bowel movement which contained the gall-stones and the button. The stones were collected and counted, to the number of 527, when the nurse became tired and ceased counting. But there were not many more. The button was in good condition except that it was darkened in color. It held within the grasp of the spring cups the portion of intestine and gall-bladder which had been separated by the pressure. There was very little odor, showing that the separation had resulted from pressure atrophy simply, and not from sloughing or gangrene. Great care was observed with regard to the diet and the movement of the bowels for a number of days following the discharge of the button, but the patient made such steady progress that she was soon on full diet. The sutures were removed from the abdominal incision on the ninth day, and the patient sat up on the sixteenth day. The subsequent history of the case has been most satisfactory.

CASE II.—In November, 1893, Mr. J. H. E., a citizen of a neighboring State, was sent to this city to consult me. When I saw him at his hotel he was suffering great pain in the hepatic region, and appeared to be in the midst of an attack of biliary colic. Repeated doses of morphia, hypodermically administered, were necessary before relief was obtained. The following history was then elicited. He was aged 47 years, short of stature, was strong and muscular, and weighed 215 pounds. He had always enjoyed robust health until a few years ago, when he began to suffer from periodical headaches. These continued to grow more severe and more frequent, and one year ago began to be associated with slight pain in the hepatic region. The pain in the hepatic region at first disappeared with the decline of the headaches, but within a few months after the first attack there was more or less continuous pain in that region, with at times periods of exacerbation of great severity, so that relief could only be obtained through repeated doses of morphia. The pain was radiating in character, extending towards the epigastrium, umbilicus, and entire right side of abdomen; also throughout the chest and towards the right shoulder. The attacks were attended with slight jaundice only, and the stools

were not clay-colored. On inquiry into the family history it was learned that the mother of the patient had died at seventy from "liver disease," after long years of suffering similar to that which was now affecting the son. Obstruction in the biliary ducts was at once suspected, but corroborating physical signs were unavailable, except marked tenderness directly over the region of the gall-bladder. The patient was importunate for relief, even by surgical means, if that were deemed necessary; but as the gall-bladder did not appear to be enlarged and the subject was a rather unpromising one for surgical manipulation, because of thick abdominal walls and small gall-bladder, and further, because medical remedies had not been given a fair trial, I requested the association of eminent medical council in the case. Accordingly, Dr. S. Solis-Cohen was requested to take at least temporary charge of the patient. Dr. Cohen corroborated the diagnosis of gall-stone obstructing the cystic duct, and expressed the belief that nothing short of surgical means would effect a cure. However, it was determined that a course of medication should be pursued under his direction. This was continued during the next few months, but without benefit. On the contrary, the attacks continued to grow more severe and the patient was evidently on the decline, having lost during this time thirty-five pounds in weight. But I was sorry, when I was called upon to operate, that he had not been further reduced in flesh, for the abdominal wall was still very thick and the gall-bladder apparently not enlarged.

Operation, March 31, 1894. Assisted by Drs. Theo. A. Erck, M. S. Erdman, and William H. Wells. Dr. Cohen was present. An incision, begun immediately over the normal location of the gall-bladder and extending downward three inches through an abdominal wall which was found to be even thicker than was anticipated—fully four inches—exposed the edge of the liver with a little bit of a gall-bladder just peeping from under its edge. I was greatly disappointed at the small size of the gall-bladder, for I realized that it would be a difficult matter to make the attachment with the button at the bottom of this deep wound through the thick and rigid abdominal walls, for it would be impossible to bring the bladder to the surface; and further examination showed that it was necessary at least to open the gall-bladder, as two stones were found blocking the entrance to the cystic duct. To make matters worse, if possible, the omentum and mesentery were also loaded with fat, so that the intestines were hidden entirely out of sight. I increased the incision to four inches and tried to find and bring up a knuckle of duodenum, but failed after considerable manipulation to even bring into view any portion of the small intestine. I then decided to try to make the attachment to the colon at its nearest point to the liver—namely, at the beginning of the transverse colon. The running suture was placed, the incision made, and the smallest sized button adjusted within the intestine. If this step was difficult, the next, that of adjusting the button in the small gall-bladder, was stupendous. After adjusting the running thread, the gall-bladder incision showed that the difficulties would be even greater than anticipated, for its mucous coat was greatly hypertrophied, rendering the cavity almost too small to re-



ceive the button. But it was finally forced in and the ligature tied around its projecting cylinder. Now came the most difficult task of all, the clasping of the two buttons together. If you will recall that it is necessary to grasp the two buttons so as to get force enough to press them together; that there was no free gall-bladder to grasp; that I was making the manipulation with already worn-out fingers, and among slippery tissues at the bottom of the thick abdominal walls, with the diaphragm rising and falling violently because the patient was taking ether badly; and that just when I thought I was about to succeed in effecting the junction the button slipped out of the gall-bladder, you will be able to imagine my mental state. The outlook was so extremely unfavorable that I almost despaired of success. I next considered the feasibility of closing the intestinal incision and endeavoring to stitch the gall-bladder to the abdominal wall and draining externally; but this was equally impracticable, for I had not sufficient gall-bladder wall to stitch. I then concluded to make another attempt. This time I had torn and bruised edges to work with, but I again inserted the button and drew the ragged edges of the gall-bladder around the cylinder, and then made a final endeavor to clasp the two cylinders; ultimately I was rewarded by hearing the click of the spring upon the grooves within! Never did an exhausted and defeated army hear the click of the sabres of the hoped-for reinforcement with more joy than I heard the embrace of the opposite springs of those buttons as they pressed the intestinal wall against that of the gall-bladder and held the one in close contact with the other! And, thanks to the beautiful mechanism of the Murphy button, the adjustment was complete. The incision was then closed and the patient returned to bed, not more exhausted from the prolonged manipulation and rather rough handling of the gall-bladder than I was from the mental and physical strain in the doing of it.

The after operative history of this case was by no means as smooth as that of the first one. There were considerable pain and elevation of temperature during the following sixteen days, at the end of which time the button and the two gall-stones were passed. After this the progress towards recovery was gradual and certain, the patient returning to his home four weeks after the operation.

The later result has more than justified the undertaking of the operation in even this unpromising case, for not only has the patient been saved from a slow, torturing death, like that of his unfortunate mother, but he has been restored to perfect health. The pain and headaches have been absent since the recovery.

These two cases illustrate the extremes of simplicity and difficulty in the performance of this major operation, which latter, under the most favorable circumstances, it should always be considered. There is one point of practical importance I wish especially to emphasize, namely, that the post-operative history of the second case has been equally satisfactory with that of the first, showing that, at least, in this instance, the junction with the colon instead of the duodenum was not material. This fact is significant, because in another case presenting the same manipulative obstacles I would not spend the time which was lost in the endeavor to

bring up a portion of the small intestine, but would at once proceed to make the attachment to the colon, especially if the common duct were patulous.<sup>1</sup>

<sup>1</sup> Nearly two years have now elapsed since the performance of the operations just described. This fact renders the late publication of the paper of far more value because of the opportunity which it affords of recording the condition of the patients a long time after operation. Both cases have remained in perfect health; there has been no return whatever of the old symptoms, nor have there been any new ones which might be ascribed to the formation of the new biliary duct. Case I has recently passed safely through an accouchement at full term, and states that the pregnancy and delivery were the easiest she ever had. She has been restored from an emaciated, sallow-skinned invalidism to robust, enduring health; most of all, she rejoices in the absence of the headaches.

Case II has likewise been free from the headaches as well as from the other symptoms.



