





NLM 00059936 5

NATIONAL LIBRARY OF MEDICINE
Washington



Founded 1836

U. S. Department of Health, Education, and Welfare
Public Health Service

MEDICAL DEPARTMENT, UNITED STATES ARMY

SURGERY IN WORLD WAR II

ORTHOPEDIC SURGERY

in the

MEDITERRANEAN THEATER

MEDICAL DEPARTMENT

UNITED STATES ARMY

IN WORLD WAR II

MEDICAL DEPARTMENT, UNITED STATES ARMY

SURGERY IN WORLD WAR II

ORTHOPEDIC SURGERY
in the
MEDITERRANEAN THEATER
OF OPERATIONS

Editor in Chief

Colonel JOHN BOYD COATES, Jr., MC

Editor for Orthopedic Surgery

MATHER CLEVELAND, M. D.

Associate Editor

ELIZABETH M. MCFETRIDGE, M. A.

OFFICE OF THE SURGEON GENERAL

DEPARTMENT OF THE ARMY

WASHINGTON, D. C., 1957

UH

215

A2

8 59md

Pt. 1, v. 6

1957

c. 7,

SURGERY IN WORLD WAR II

Prepared under the direction of

MAJOR GENERAL S. B. HAYS

The Surgeon General, United States Army

Historical Unit, Army Medical Service

Colonel JOHN BOYD COATES, Jr., MC, *Director*
Major I. H. AHLFELD, MSC, *Executive Officer*
Captain J. K. ARIMA, MSC, *Special Projects Officer*
DONALD O. WAGNER, Ph. D., *Chief, Historians Branch*
WILLA B. DIAL, *Chief, Editorial Branch*
JOSEPHINE P. KYLE, *Chief, Archives and Research Branch*
HAZEL G. HINE, *Chief, Administrative Branch*

Advisory Editorial Board

MICHAEL E. DEBAKEY, M. D., *Chairman*
FRANK B. BERRY, M. D. JOHN B. FLICK, M. D.
BRIAN BLADES, M. D. FRANK GLENN, M. D.
J. BARRETT BROWN, M. D. M. ELLIOTT RANDOLPH, M. D.
STERLING BUNNELL, M. D. ISIDOR S. RAVDIN, M. D.
NORTON CANFIELD, M. D. ALFRED R. SHANDS, Jr., M. D.
B. NOLAND CARTER, M. D. HOWARD E. SNYDER, M. D.
EDWARD D. CHURCHILL, M. D. R. GLEN SPURLING, M. D.
MATHER CLEVELAND, M. D. BARNES WOODHALL, M. D.
DANIEL C. ELKIN, M. D. ROBERT M. ZOLLINGER, M. D.

Colonel JOSEPH R. SHAEFFER, MC (ex officio)
Colonel JOHN BOYD COATES, Jr., MC (ex officio)

38053

ORTHOPEDIC SURGERY
in the
MEDITERRANEAN THEATER
OF OPERATIONS

by

OSCAR P. HAMPTON, Jr., M. D., F. A. C. S., Colonel, MC, USAR

*Assistant Professor of Clinical Orthopedic Surgery
Washington University School of Medicine, St. Louis, Mo.*

Foreword

Orthopedic surgery in the Mediterranean (originally the North African) Theater of Operations developed by a process of evolution. One would almost be justified in saying that the surgery which was first performed was pioneering in character. Certainly, one is justified in saying that the early endeavors culminated in superb treatment of combat-incurred injuries of the extremities. The Mediterranean theater thus served as a testing ground for the principles and techniques which were applied with such success in the later campaigns in this theater and by which these injuries were treated in the European Theater of Operations in 1944 and 1945.

When United States Army troops invaded North Africa in the fall of 1942, almost no medical officers with previous experience of combat-incurred injuries of the bones and joints were on active duty in the theater, and no official, definitive policies had been established for the management of these wounds. It was inevitable, therefore, that these combat-incurred injuries should be managed by the principles and techniques then employed in peacetime practice and that they should be managed, also, by individual variations of these principles and techniques.

A brief experience showed that the methods employed, however satisfactory they might have been in the circumstances of peacetime practice, were not satisfactory in time of war for a variety of reasons; namely, (1) the logistic situation in North Africa; (2) the timelag, which was frequently quite prolonged; and (3) the nature of most combat-incurred wounds, which were devastating to a degree entirely unknown in peacetime.

The new policies of management, which were based on the staged treatment of battle-incurred wounds, were first applied to soft-tissue wounds. By the end of 1943, a year after the beginning of combat in this theater, the practice was well established of managing this type of wound by initial and reparative surgery overseas, with reconstructive procedures reserved for Zone of Interior hospitals. By the spring of 1944, it had become accepted practice to use the same methods in the management of compound (open) fractures. Before the war ended, they were also applied to wounds of the joints.

The most important consideration in the management of compound fractures and wounds of the joints was that of sound surgery. The sulfa drugs were useful until penicillin became available. Penicillin proved extremely valuable in the prevention and control of invasive infection. Both chemotherapy and antibiotic therapy, however, were always regarded as adjunct measures. They were never considered as substitutes for indicated surgical procedures.

Dr. Hampton's comprehensive coverage of orthopedic surgery in the Mediterranean theater during World War II is the result of careful planning. Through the foresight of Col. Edward D. Churchill, MC, chief consultant in surgery to the theater surgeon, surveys of special types of combat-incurred injuries and other lesions of the bones and joints were planned and carried out while the war was still in progress. The analyses of these surveys and the conclusions drawn from them add materially to the value of this record.

It is fortunate that the subject of wartime orthopedic surgery is so thoroughly covered in this volume. The errors made early in the war in the management of combat-incurred injuries of the bones and joints are frankly recorded, as they should be, to prevent the making of the same errors in the event of another war. The validity of the principles of management which were established in the Mediterranean theater was proved in actual combat. They are still valid. These are the principles which must govern the management of mass casualties should total war ensue in the future. Details of management may change. Principles of management are permanent.

The story that is told in this volume is a record of hard experience. It is a story that should be generally known. For this reason, I hope that this book will find its way into the libraries of medical schools and that the principles which it sets forth will be incorporated in the curricula of these schools. The medical students and young physicians who are our future medical officers will find the history of orthopedic surgery in the Mediterranean theater a helpful introduction to the management of combat-incurred injuries of the bones and joints.

S. B. HAYS,
Major General, United States Army,
The Surgeon General.

Preface

In World War II, as in all previous wars, wounds of the extremities, a great number of which involved the bones and joints, constituted the bulk of the surgical load. In the Mediterranean (previously the North African) Theater of Operations, of 111,125 wounded or injured in action it is estimated that 79,000, more than 71 percent of the total number, sustained wounds of the extremities. A significant proportion of these required orthopedic management. Incidentally, the number of wounds of the extremities in this theater approximately equaled the total number of wounded or injured in action (79,526) in the entire Korean conflict.

These figures are not surprising. In the Mediterranean theater, United States Army ground forces experienced the longest period of continuous ground combat which they had known since the War Between the States. With only very brief interludes, in the early and late summer of 1943, they were in constant contact with the enemy from 8 November 1942 until 2 May 1945. They fought from the shores of Casablanca across North Africa to Bizerte. After a short respite, they conquered Sicily. After another interlude, they invaded Italy and fought up to the Swiss border.

The medical history of the Mediterranean theater parallels the tactical history. The steady flow of battle casualties through forward and fixed hospitals from November 1942 until May 1945 provided a concentrated experience in military surgery, unusual opportunities for the observation of results, and, on indications, changes in both concepts and methods. These changes are described in detail in the chapters of this volume. In brief, the management of compound skeletal injuries in the early days of this experience was based upon the concepts of plasma for shock, sulfonamide drugs for the prevention of infection, and the closed plaster method for the management of fractures and wounds. As the result of continuing observation of the results obtained in the theater, each of these concepts was discarded.

Long before the fall of Rome on 5 June 1944, the prevailing concepts were that the most important preventive measure against wound infection was adequate debridement at initial wound surgery; that whole blood was crucial in the management of wounded men; that penicillin, used systemically, was an important measure in impending or established infection; and that wounds left open at initial surgery need not heal by granulation but, instead, that it was surgically feasible to perform delayed closure of clinically clean wounds over fractures, following which good results could be anticipated.

The delayed primary closure of soft-tissue wounds by suture, including wounds associated with compound fractures, was not, of course, an entirely new concept. It had been practiced to some extent in World War I. In that

war, however, the criterion of low bacterial count on repeated cultures of the wound before delayed closure was undertaken not only made the method impractical for general use but also, because of the repeated dressings necessary, was an invitation to secondary infection. In World War II, closure was predicated upon only a clean clinical appearance of the wound several days after the initial surgery. The method was, therefore, more widely applicable.

The lessons of World War I had, in large measure, to be learned again in World War II. Lives and limbs will be saved, and countless extended periods of morbidity will be avoided, if the lessons derived from the Mediterranean-theater experience with musculoskeletal injuries as set forth in this volume are put into practice without delay in any future war.

OSCAR P. HAMPTON, Jr., M. D.

Acknowledgments

This reasonably complete and comprehensive record of the experience in orthopedic surgery in the Mediterranean Theater of Operations reflects the efforts of a number of medical officers who served in that theater during World War II. They include—

Brig. Gen. (later Maj. Gen.) Albert W. Kenner, Brig. Gen. Frederick A. Blesse, and Maj. Gen. Morrison C. Stayer, who at various times served as theater surgeon and who had the overall responsibilities for the medical activities of the theater; and Col. (later Maj. Gen.) Joseph I. Martin, MC, Surgeon, Fifth U. S. Army.

Col. Edward D. Churchill, MC, Chief Consultant in Surgery, Office of the Surgeon, Mediterranean Theater of Operations, who guided the transition which took place in the theater in the management of wounds of the soft tissues and then in the management of wounds involving the bones and joints, and which provided the pattern for the subsequent management of these injuries in all overseas theaters.

Col. Frank B. Berry, MC, Chief, Surgical Service, 9th Evacuation Hospital, and later Consultant in Surgery, Office of the Surgeon, Seventh U. S. Army, whose observations on, and advice concerning, the problems of serious wounds of the extremities was invaluable.

Col. Howard E. Snyder, MC, Consultant in Surgery, Office of the Surgeon, Fifth U. S. Army, who effectively taught the principles of good initial surgery in all the hospitals of that army.

Maj. Champ Lyons, MC, Consultant in Wound Infection, Chemotherapy, and Penicillin Therapy, Office of the Surgeon, Mediterranean Theater of Operations, who did so much to emphasize that penicillin therapy was merely an adjunct to good wound surgery and should be used to obtain better surgical results.

Appreciation is also expressed to the late Brig. Gen. Fred W. Rankin, Chief Consultant in Surgery, Office of the Surgeon General, and his assistants, Col. B. Noland Carter, MC, and Col. Michael E. DeBakey, MC. They were all most helpful in the followup survey on the results of delayed internal fixation of compound battle fractures in the Mediterranean theater and on other problems of management of casualties with wounds of the bones and joints which were carried out in Zone of Interior hospitals.

Acknowledgment is also made to the various surgeons and orthopedic surgeons in the Mediterranean theater who made the special surveys upon which several of the chapters in this volume are based.

Finally, acknowledgment is made to the chiefs of orthopedic surgery in the general and station hospitals in the communications zone in the theater and

to the general and orthopedic surgeons in the forward hospitals, all of whom aided so materially in the development of the program of initial and reparative surgery for compound battle fractures which was in effect at the end of the war.

A very substantial and indispensable contribution to this volume, in a field widely separated from that covered by the author and by the medical officers on whose work he has drawn for the content of the book, has been made by Melvin J. Hadden, HMC, USN, who, under the direction of Mr. Herman Van Cott, chief, Medical Illustration Service, Armed Forces Institute of Pathology, prepared the very excellent layouts for the illustrations and supervised artwork and preparation of illustrations for printing.

Appreciation is expressed to The C. V. Mosby Company for their cooperation in providing printing media for several illustrations appearing in this volume which also appeared in the book "Wounds of the Extremities in Military Surgery" by Oscar P. Hampton, Jr., M. D.

Prologue

The principle that underlies all surgical management of battle fractures and wounds of major joints was relearned in the field in North Africa and Italy. When Serjeant-Chirurgion Richard Wiseman who attended Charles II in his wanderings on the continent of Europe in the 17th century wrote on the "Cure of Gun-shot Wounds," he turned to a Latin version of Hippocrates. *Omne quod contusum, necesse est ut putrescat, & in pus vertatur*, it was written. "What is contused must necessarily putrefie, and be turned into matter." This is the ancient principle that surgeons reared under the aseptic mantle spread by Lister must come to know when they are called upon to deal with the soiled and torn flesh of gunshot wounds.

"But," said the young surgeon, "I cannot take responsibility for opening a knee joint in a tent with a dirt floor!" "Why not," is the reply, "when the joint already contains devitalized cartilage and mud from a foxhole?"

A distorted version of Trueta's teaching which omitted his emphasis on the careful excision of dead tissue was a false starting point, but facts disclosed by experience soon replaced unsound ideas. Skeletal pins fixed in plaster do not withstand transport. Packing the wound with vaseline gauze causes necrosis and macerated flesh. Splinting for transport is a different art from splinting for the maintenance of reduction. Unpadded plasters abrade the skin. An evil smell and gas bubbles do not necessarily spell clostridial myositis. These and many more detailed lessons emerged as the product of grim experience and came rapidly to the surgeons of the Mediterranean theater. They are set forth in this volume dealing with gunshot wounds of the extremities.

EDWARD D. CHURCHILL, M. D.

Contents

	<i>Page</i>
FOREWORD-----	VII
PREFACE-----	IX
ACKNOWLEDGMENTS-----	XI
PROLOGUE-----	XIII

Chapter

I Introduction-----	1
II Administrative Considerations-----	3
Evolution of the Consultant System-----	3
Visits to Medical Installations-----	7
Assignment of Personnel-----	12
Facilities-----	14
Hospital Administration-----	25
Graphic Records-----	27
Accumulation of Data-----	28
III Splinting in the Combat Zone-----	29
Classification of Military Splinting-----	29
Emergency Splinting-----	31
Transportation Splinting-----	39
IV The Management of Compound Battle Fractures-----	53
Part I. The Evolution of the Program of Staged Management	
Concepts and Practices Before World War II-----	53
United States Experiences With the Closed Plaster Method-----	55
Development of the Program of Reparative Surgery-----	58
Application of the Reparative-Surgery Program to Compound Fractures-----	61
Part II. The Initial Surgery of Compound Fractures	
Surgical Timing-----	64
First Aid-----	66
Preparation for Initial Wound Surgery-----	67
Appraisal of the Wound-----	71
General Principles and Practices-----	72
Technical Considerations-----	74
Management of Bone Fragments-----	78
Fracture Management-----	80
Postoperative Regimen-----	80
Evacuation-----	80
Part III. The Reparative Surgery of Compound Fractures	
Preoperative Preparation-----	82
Technical Considerations-----	83
Postoperative Management-----	103
Results-----	103

<i>Chapter</i>	<i>Page</i>
V Regional Compound Fractures.....	115
Part I. Compound Fractures of the Humerus, Radius, and Ulna	
General Considerations.....	115
Problems of Management.....	115
General Principles of Management.....	116
Compound Fractures of the Humerus.....	121
Compound Fractures of the Radius and Ulna.....	133
Conclusions.....	137
Part II. Compound Fractures of the Femur	
General Considerations.....	137
Survey of Results, Spring, 1944.....	139
Source Material.....	140
The Program of Reparative Surgery.....	141
Technical Considerations.....	142
Appraisal of Results.....	157
Conclusions.....	159
Part III. Compound Fractures of the Tibia and Fibula	
The Reparative-Surgery Program.....	160
Analysis of Cases, 1944-45.....	161
Wound Management.....	162
Fracture Management.....	164
Evaluation of Results.....	173
Part IV. Compound Fractures of the Foot	
Wound Management.....	181
Fracture Management.....	182
Postoperative Management.....	183
VI Delayed Internal Fixation of Compound Battle Fractures—A Followup Study in the Zone of Interior.....	185
Technical Considerations.....	187
Survey of Results.....	188
Conclusions of the Survey.....	197
Analysis of Unfavorable Results.....	200
VII External Skeletal Fixation of Fractures in the Communications Zone.....	203
Analysis of Cases.....	203
VIII Wounds of Joints.....	211
Historical Note.....	211
General Considerations.....	213
Wounds of the Knee Joint.....	215
Wounds of the Hip Joint.....	237
Wounds of the Smaller Joints.....	243
IX Amputations.....	245
Indications.....	246
Technical Considerations.....	247
Analysis of Cases.....	260
X Noncombat Orthopedic Lesions.....	271
General Principles of Management.....	272
The Management of Painful Backs and Feet.....	274
Surveys of Management of Noncombat Orthopedic Lesions.....	276
Internal Derangements of the Knee.....	277

<i>Chapter</i>	<i>Page</i>
X Noncombat Orthopedic Lesions—Continued	
Joint Mice (Osteochondritis Dissecans).....	286
Recurrent Dislocations of the Shoulder.....	287
Fractures of the Carpal Scaphoid Bone.....	290
XI Disposition of Patients From Orthopedic Services of General Hospitals.....	295
General Principles of Disposition.....	295
A Sample Hospital Experience.....	297
APPENDIX.....	299
INDEX.....	345

Tables

<i>Number</i>		
1	Timing of splinting of compound battle fractures in relation to objectives and facilities.....	30
2	Relationship of shock and blood loss in 67 battle casualties.....	69
3	Blood replacement before and during initial surgery in 100 compound fractures.....	70
4	Results in relation to procedure and wound healing in 147 compound fractures of humerus.....	131
5	Results in relation to technique and status of fracture in 147 compound fractures of humerus.....	131
6	Results in relation to technique, wound healing, and status of fracture in 147 compound fractures of humerus.....	132
7	Location of Kirschner wire for skeletal traction in 613 compound fractures of femur.....	149
8	Methods of fracture management in 1,063 compound fractures of femoral shaft.....	157
9	Techniques of internal fixation in 284 fractures of femoral shaft.....	157
10	Appraisal of wound healing in 825 compound fractures of femoral shaft.....	158
11	Fracture management in 622 compound fractures of tibia and tibia and fibula.....	167
12	Fracture management in relation to level of tibial injury in 621 compound fractures of tibia and tibia and fibula.....	167
13	Severity of injury in relation to location of fracture in 132 compound fractures of tibia and 80 of tibia and fibula.....	178
14	Results in relation to severity of injury and technique of wound management in 132 compound fractures of tibia and 80 of tibia and fibula.....	179
15	Results in relation to severity of injury and technique of fracture management in 132 compound fractures of tibia and 80 of tibia and fibula.....	180
16	Combined results of wound and fracture management in relation to severity of injury in 132 compound fractures of tibia and 80 of tibia and fibula.....	180
17	Results of internal fixation on obligate indications in 135 compound fractures.....	193
18	Results of internal fixation on elective indications in 165 compound fractures.....	193
19	Results of internal fixation in relation to indications in 67 compound fractures of humerus.....	193
20	Results of internal fixation in relation to indications in 31 compound fractures of radius and ulna.....	194
21	Results of internal fixation in relation to indications in 146 compound fractures of femur.....	194
22	Results of internal fixation in relation to indications in 88 compound fractures of tibia and fibula.....	194

<i>Number</i>		<i>Page</i>
23	Composite results of internal fixation in relation to technique and location of fracture in 332 compound fractures of long bones.....	195
24	Results of internal fixation in 29 compound fractures with established wound infection.....	196
25	Essential data on 14 fractures treated by external skeletal fixation.....	205
26	Essential data on 27 fractures treated by external skeletal fixation.....	205
27	Essential data on 25 fractures treated by external skeletal fixation.....	206
28	Sites of amputation in 1,379 separate operations on United States Army troops.....	263
29	Sites of amputation in 1,389 separate operations on German prisoners of war.....	264
30	Agents of wounding and causes of amputation in 1,271 United States Army troops.....	265
31	Agents of wounding and causes of amputation in 1,332 German prisoners of war.....	266
32	Complicating injuries in 1,000 United States Army amputees.....	266
33	Indications for amputation in 1,344 operations following wounds or injuries in United States Army troops.....	267
34	Indications for 843 primary and 243 secondary amputations in United States Army troops.....	267
35	Indications for 962 primary and 427 secondary amputations in German prisoners of war.....	268
36	Combinations of levels in 85 multiple amputations in United States Army casualties.....	269

Illustrations

<i>Figure</i>		
1	First aid in field.....	15
2	Scenes at first-aid stations.....	16
3	Scenes at collecting station.....	18
4	Arrival of casualty at admission tent of clearing station.....	19
5	Ambulance transportation of wounded.....	20
6	Scenes in field hospital.....	21
7	Scenes in evacuation hospital.....	22
8	Evacuation hospital.....	23
9	General hospital.....	24
10	Improvised battlefield splinting for fracture of femur.....	33
11	Emergency splinting for fractures of forearm and about elbow and wrist.....	35
12	Emergency splinting for fracture of humerus.....	36
13	Emergency splinting for fractures of lower third of leg and ankle.....	37
14	Emergency splinting for injuries of thigh, knee joint, and leg.....	38
15	Improvised techniques of splinting after initial wound surgery.....	42
16	Modification of elephant-tusk splint for fractures about shoulder joint and elbow.....	44
17	Plaster Velpeau bandage for injuries of shoulder joint, arm, or elbow.....	45
18	Shoulder spica for injuries about shoulder joint and of arm.....	46
19	Transportation splinting of compound fracture of femur with hip spica.....	48
20	Modified Tobruk splint.....	50
21	Transportation splinting for fractures of lower extremities.....	52
22	Staged surgery of wound of calf.....	60
23	Staged surgery of wound of right arm.....	61
24	Reparative surgery of wound of left axilla and shoulder.....	62
25	Initial wound surgery of soft-part wound.....	75
26	Staged surgery of wound of thigh.....	76

<i>Figure</i>	<i>Page</i>
27 Initial surgery of wound of thigh.....	77
28 Appearance of wound at completion of initial surgery.....	78
29 Correct excisional surgery in infected compound comminuted fractures of left tibia and right femur.....	85
30 Management of compound comminuted fractures of femur and patella by delayed internal fixation.....	88
31 Reparative management of wound of thigh with associated compound fracture of femur.....	90
32 Management of compound comminuted fractures of right tibia and fibula by delayed internal fixation.....	92
33 Staged management of compound comminuted fracture of femur.....	94
34 Management of compound comminuted fracture of femur by delayed internal fixation.....	95
35 Staged surgery of bilateral compound fractures of shaft of femur.....	96
36 Management of compound fractures of tibia and fibula by internal fixation.....	104
37 Comminuted compound fracture of right humerus with radial-nerve paralysis....	106
38 Compound comminuted fracture of right humerus with loss of bone.....	108
39 Staged management of associated humeral-radial fractures and nerve injury by shortening of bone.....	111
40 Reparative management of fracture of tibia.....	112
41 Management of compound comminuted fracture of femur by balanced-suspension skeletal traction.....	113
42 Management of compound fracture of right tibia by staged surgery and modified closed plaster technique.....	114
43 Management by delayed internal fixation of compound comminuted fracture of humerus, with loss of bone and laceration of median and ulnar nerves.....	118
44 Management by delayed internal fixation of compound comminuted fracture of humerus with segmental loss of bone and laceration of radial nerve.....	120
45 Splinting for paralysis of radial nerve.....	121
46 Comminuted fracture dislocation of right shoulder, comminuted fractures of humerus and both bones of forearm, with injuries of median and radial nerves.....	124
47 Hanging cast for fracture of humerus.....	126
48 Shoulder spica cast for fracture about shoulder joint.....	127
49 Unsuccessful management of compound comminuted fracture of right radius and ulna.....	135
50 Management of compound comminuted fracture of radius and ulna by delayed internal fixation.....	136
51 Suspension traction in 90-90-90 position for compound fracture of femur.....	143
52 Management of compound oblique fracture of femur by delayed internal fixation.....	144
53 Internal fixation of displaced fracture of medial femoral condyle.....	147
54 Two-wire skeletal traction for battle fracture of femur.....	150
55 Balanced-suspension skeletal traction by half-ring leg splint and Pierson attachment.....	151
56 Navy traction for fracture of femur.....	152
57 Modlin modification of Navy traction for fracture of femur.....	153
58 Linch modification of Navy traction for fracture of femur.....	154
59 Skeletal traction by 90-90-90 suspension method for fracture of femur.....	155
60 Anteroposterior and lateral roentgenograms showing fracture of tibia with loss of bone.....	166
61 Skeletal traction in fractures of both bones of leg.....	168
62 Roentgenologic results of skeletal traction in cast.....	169

<i>Figure</i>	<i>Page</i>
63 Management of compound comminuted fractures of tibia and fibula by delayed internal fixation.....	171
64 Management of compound comminuted fractures of tibia and fibula by delayed internal fixation.....	172
65 Management of compound comminuted fractures of tibia and fibula.....	174
66 Management of comminuted fracture of tibia and fibula, by plating of fibula...	176
67 Management of fractures of fibula and tibia, with loss of bone, by plating of fibula...	177
68 Management of compound comminuted fracture of radius, with loss of bone and median-nerve palsy, by external skeletal fixation.....	208
69 Management of segmental compound comminuted fractures of tibia and fibula by external skeletal traction.....	209
70 Staged management of wound of left knee joint.....	218
71 Staged management of penetrating wound of knee joint with comminuted fracture of femur.....	220
72 Management of early suppurative arthritis of knee joint.....	222
73 Management of early suppurative arthritis of knee joint.....	224
74 Management of suppurative arthritis of knee joint.....	226
75 Management of suppurative arthritis of knee joint.....	228
76 Management of suppurative arthritis of knee joint.....	230
77 Management of suppurative arthritis of knee joint.....	232
78 Management of suppurative arthritis of hip joint.....	238
79 Management of suppurative arthritis of hip joint.....	239
80 Management of suppurative arthritis of hip joint.....	240
81 Destructive injury of entire left leg.....	246
82 Bilateral traumatic amputations of legs.....	247
83 Bilateral injuries of lower extremities.....	248
84 Traumatic amputation of right leg, multiple penetrating wounds of left leg.....	250
85 Amputation stump of left forearm.....	251
86 Technique of open circular amputation.....	252
87 Application of skin traction after amputation of leg.....	253
88 Plaster cast with elastic traction.....	254
89 Traumatic amputation of right leg, compound fracture of bones of left leg.....	255
90 Open circular amputation through middle third of forearm.....	256
91 Healed stumps after amputation by open circular technique.....	257
92 Closure of amputation stumps.....	258
93 Closure of amputation stump.....	259
94 Closure of amputation stump.....	260
95 Amputation by open flap technique, with closure of flaps at reparative surgery...	261
96 Amputation through leg near site of election, with preservation of posterior viable flap of skin.....	262

CHAPTER I

Introduction

The combat experience in the Mediterranean area lasted from November 1942 until May 1945. During this period of approximately 30 months, battle casualties were treated by the officers of the United States Army Medical Corps in the various echelons of the theater. Casualties were often heavy, and they continued to be received, in smaller numbers, even during the infrequent periods when combat activity was diminished.

During the period from January 1942 to June 1944, admissions to United States Army hospitals in England were limited to casualties from the Army Air Forces and a few British casualties received from the Mediterranean theater. Ground forces were engaged in combat in the European theater, and battle casualties were heavy only between D-day, 6 June 1944, and V-E Day, 8 May 1945.

The medical officers in the Mediterranean theater thus had a much longer experience in the treatment of battle casualties than the medical officers in the European theater and had correspondingly greater opportunities to gather data for the evaluation of their techniques of treatment.

The Mediterranean theater, with a relatively small number of troops and relatively few hospitals, was extremely fortunate in having assigned to it a considerable number of affiliated general hospitals. Many able young orthopedic surgeons were on the staffs of these hospitals. Col. Edward D. Churchill, MC, consultant in surgery to the theater surgeon, stimulated and encouraged his junior officers to record and analyze their surgical experiences. Lt. Col. (later Col.) Oscar P. Hampton, Jr., MC, consultant in orthopedic surgery for the theater, was indefatigable in spreading throughout the hospitals of the theater the principles upon which the surgery of wounds of the bones and joints is based.

During the war and immediately thereafter, Colonel Hampton, with the assistance of many of his colleagues, collected invaluable data on military orthopedic surgery. The studies which were the result of these investigations and which are presented in this volume form an unusually complete and comprehensive analysis of orthopedic surgery in an overseas theater.

MATHER CLEVELAND, M. D.,
Formerly Colonel, MC, AUS,
Editor for Orthopedic Surgery.

CHAPTER II

Administrative Considerations

During the approximately 2,500-mile advance by United States Army troops from Casablanca in North Africa, where landings were made in November 1942, to Como on the Swiss border of Italy, which was reached early in May 1945, a continuous flow of casualties were treated in United States Army hospitals. This was the largest continuous combat experience for United States troops since the War of the Rebellion.

Many of these casualties had suffered bone and joint injuries. All of them were treated under conditions without parallel in any previous war. They were treated initially by concepts and methods prevailing in civilian practice, many of which were soon found wanting in the circumstances of military surgery. Similarly, some of the techniques which had been employed by surgeons of Allied armies already in the field and which were adopted by United States Army surgeons were also found wanting. Increasing experience and repeated critical evaluation of results frequently led to the modification of concepts originally accepted and methods originally used and sometimes led to their replacement by entirely new measures. Modification and replacement of the techniques originally used were, however, a matter of evolution; they were not accomplished by directives.

The regimen for the management of bone and joint injuries which was in effect at the end of the war was based upon a program of staged management which was applicable to all wounds and which had evolved from continuing experience. Neither of its component parts, initial surgery and reparative surgery, was new, nor was the combination of the two components new. Such a program had been recommended by some surgeons and employed in some cases in World War I. It was not until the spring of 1944, however, that the scope and timing of the program were fully developed in World War II and that it was universally applied. This program was applicable to most wounds of the soft tissues and was of major importance in the management of bone and joint injuries, the end results of which depended, as much as upon any other single factor, upon the initial management and later reparative management of the compounding soft-tissue wound.

EVOLUTION OF THE CONSULTANT SYSTEM

Officers and enlisted men of the Army Medical Department assigned or attached to combat elements furnished the only medical support for the North African landings 8 November 1942, but mobile and fixed hospitals, staffed with

their intrinsic professional personnel, were established soon afterward. It was not until March 1943, however, that the consultant system began to function in the theater, with the arrival of Col. Edward D. Churchill, MC, consultant in surgery to the theater surgeon. There was a lapse of another 6 months before, on the recommendation of Colonel Churchill, a consultant in orthopedic surgery was appointed.

By the time the consultant in this specialty was appointed, it had become apparent that orthopedic surgery was sufficiently important in its own right in this active theater of operations to require more direct attention than a consultant in surgery could spare for it from his other duties. This was because (1) a large proportion of all combat-incurred injuries involve the bones and joints and (2) a large proportion of these wounds present major problems of management.

The landing at Salerno on the Italian mainland by the Fifth U. S. Army in September 1943 had resulted in a considerable increase in all casualties and in a corresponding increase in the number of bone and joint injuries. At the same time, certain personnel problems became apparent. Shortly after the landings in Italy, 11 general hospitals and several large station hospitals designated to operate in Bizerte, Oran, and Naples, arrived from the Zone of Interior. Previous experience had already revealed the need for supervision of the management of casualties with bone and joint injuries. In particular, it had showed that orthopedic surgeons without previous military experience, however wide their experience in civilian orthopedic practice might have been, required orientation in the principles and techniques of military surgery.

Maj. (later Col.) Oscar P. Hampton, Jr., MC, chief, orthopedic section, 21st General Hospital, was therefore placed on duty in the Office of the Surgeon, North African Theater of Operations, as acting consultant in orthopedic surgery. His mission was (1) to visit the newly arrived general hospitals; (2) to appraise the professional qualifications of their orthopedic staffs; (3) to acquaint their staffs with previous experiences in the theater in the management of combat-incurred bone and joint injuries; and (4) to record observations which might lead to improvement in the management of these injuries. When this mission was concluded, in December 1943, Major Hampton was dispatched to the Fifth Army, then fighting near Cassino, to communicate to forward surgeons the observations he had made in the base area, with particular reference to the quality of initial wound surgery and transportation splinting. Throughout the war, the exchange of experiences between hospitals of forward and rear areas was to prove one of the most profitable functions performed by all consultants.

After February 1944, when the position of consultant in orthopedic surgery to the theater surgeon was made permanent, Lieutenant Colonel Hampton continued to function in that capacity under the consultant in surgery until the consultant staff of the theater was deactivated in September 1945.

Neither the II Corps, which operated in Africa, Sicily, and Italy, nor the Seventh U. S. Army, which operated in Sicily, Italy, and southern France,

ever had an officer assigned as consultant in orthopedic surgery. When Capt. (later Maj.) Floyd H. Jergesen, MC, of the 2d Auxiliary Surgical Group, was placed on temporary duty in the office of the surgeon, Fifth U. S. Army, late in 1943, to make a special study of gas gangrene with Maj. (later Lt. Col.) F. A. Simeone, MC, he was also appointed acting consultant in orthopedic surgery to the Fifth Army and served in this capacity until after the Cassino-Rome campaign in May and June 1944. Thereafter, as in the Seventh Army, the surgical consultant to the Fifth Army supervised the management of bone and joint injuries.

In retrospect, delay in the appointment of a consultant in orthopedic surgery for the Mediterranean theater appears to have been wise. At the time of the North African landings, as has already been pointed out, few if any of the medical officers in the United States Army had had any experience with battle-incurred bone and joint injuries. Furthermore, none of the orthopedic surgeons who participated in the landings had served as observers with the Allied armies before the entrance of the United States into the war. Sound policymaking was obviously impossible until some experience in military injuries had been achieved. During the first months of combat, therefore, the surgeons in charge of the orthopedic sections in the various fixed hospitals worked out their special problems, observed the results of different methods of management, and in many instances recorded the data upon which sound future recommendations could be based. When a consultant in orthopedic surgery was finally appointed, comprehensive plans for the management of combat-incurred injuries were being evolved, and the experience in the theater, as far as it had gone, could be transmitted in an organized fashion to newly arrived personnel.

Whether the decision not to appoint consultants in orthopedic surgery to the armies was equally wise is more open to question. A basis for the decision was that even serious wounds of the extremities were usually, from the standpoint of initial wound surgery, second-priority cases, and that orthopedic surgeons were usually assigned to the evacuation hospitals in which the forward surgery of bone and joint wounds was chiefly performed. The policy of assigning orthopedic surgeons to evacuation hospitals may have been wasteful of trained personnel, as will be pointed out shortly (p. 13). The appointment of a consultant in orthopedic surgery to each army would have eliminated the need for a trained orthopedic surgeon in each evacuation hospital and would have meant a considerable saving in specialized personnel, who were always in short supply. There would have been other advantages in the appointment of an orthopedic surgeon to each of the armies. Such a consultant, moving continuously from hospital to hospital, could have done much, in his supervisory role, to improve the initial surgery of wounds of the extremities. He could also have played an important role in the education of medical officers who had had no previous experience in military surgery and who, in many instances, had had no previous experience in bone and joint injuries.

Functions of the Consultant

Both as acting consultant in orthopedic surgery and in his permanent capacity, the consultant in orthopedic surgery routinely advised the theater surgeon, through the consultant in surgery, on a variety of matters, such as the following: (1) The personnel assignments to orthopedic-surgery sections, including not only those of trained orthopedic surgeons but those of other surgeons and other medical officers who had to assume the management of bone and joint injuries; (2) the organization and functioning of orthopedic sections; (3) the quality of the management of bone and joint injuries; (4) changes in concepts and techniques of orthopedic surgery, both as the consultant in orthopedic surgery personally observed these changes and as they were reported to him in his official capacity; (5) the results being obtained; and (6) future planning.

Some of the consultant's time was necessarily spent at headquarters in administrative work, but most of his time was spent in the field. With the approval of army surgeons, frequent visits were made to hospitals in the combat zone, particularly during offensives, when the flow of casualties was heavy. Methods of management were observed, and suggestions for improvement were made to the consultant in surgery for each field army. These suggestions chiefly concerned the principles of debridement and the application of transportation splinting as a preliminary to the further treatment of casualties in the communications zone.

One of the chief problems in forward areas was the training of surgeons who had to care for casualties with bone and joint injuries but who had had no previous experience to qualify them for this duty. As a continuing effort, this was the responsibility of the chiefs of surgery in the various hospitals, but it was also a major responsibility of the consultants in surgery for the theater and the armies, and of the theater consultant in orthopedic surgery.

The consultant in orthopedic surgery utilized his time chiefly in the hospitals of the communications zone, where fractures and other conditions of the bones and joints could be segregated and where more definitive management of these injuries was accomplished. This was in contrast to the situation in the hospitals of the army area, where bone and joint injuries were, for the most part, a part of the general surgical problem. The major portion of the consultant's time was spent in hospitals close to the rear boundary of the army. These were the installations in which casualties were received from forward hospitals at the time when precise definitive surgery was necessary and could be most effectively carried out.

The general plan was to visit each fixed hospital for several days at a time, actually living with the orthopedic staff, observing their work in the operating room, following them on ward rounds, discussing general and special problems in both formal and informal sessions, suggesting and implementing such changes in policies and practices as special circumstances might require, and rendering whatever other aid was requested. These were tours of inspection, it is true,

but the major emphasis was upon their instructional aspects. The most practical way to achieve this objective was to study, with the medical officers assigned to the orthopedic section, the cases under treatment at the time of the visit.

These studies were comprehensive. They included the history of wounding, details of previous treatment, roentgenologic examinations, progress to date, plans for future care, anticipated disposition, and possibilities for later reconstructive surgery. It was always emphasized that, while the management of orthopedic problems was necessarily conducted by inclusive rules in time of war, the objective in each case was individual—to obtain the best result that could be obtained for the particular patient under consideration.

Improved techniques observed in one hospital were communicated to other hospitals as the consultant visited them in their turn. When new regiments were in process of introduction, when the volume of work was excessive, or when specific clinical observations had to be made for future planning, the consultant in orthopedic surgery frequently remained in one hospital for a week or more, integrating himself, for all practical purposes, into the hospital staff for this period of time, in order to accomplish results more quickly.

Although in all of these tours some attention was given to elective surgery, its performance was generally discouraged (p. 271). Emphasis was placed upon the necessity, in all military surgery, for the prompt return of the soldier to duty and upon the lack of justification for the use of hospital-bed space by any man whose future combat usefulness could not be assured.

Special educational efforts had to be undertaken when such radical changes were in the making as (1) the application of reparative surgery to compound fractures, in the spring of 1944 (p. 58); and (2) the extension of the program to wounds of the hip joint some months later (p. 242).

VISITS TO MEDICAL INSTALLATIONS

The activities of the consultant in orthopedic surgery in the Mediterranean theater can best be illustrated by his (summarized) reports to the theater surgeon of two typical visits of instruction, one in September and the other in October and November 1944.

September 1944

This tour, which began 8 September and ended 26 September 1944, covered the following hospitals:

Army hospitals.—Army hospitals visited included the 8th, 38th, and 94th Evacuation Hospitals and platoons of the 33d Field Hospital. The matters examined, which were later discussed with Lt. Col. (later Col.) Howard E. Snyder, MC, consultant in surgery, Fifth U. S. Army, were as follows:

1. Amputations were discussed in the light of Circular Letter No. 46, 29 August 1944, Office of the Surgeon, North African Theater of Operations,

United States Army.¹ Emphasis was placed upon the importance of good skin traction and the use of the elastic cord which had become available for this purpose.

2. The results of the methods then in use for handling wounds of the knee joints were reported. Emphasis was placed upon the importance of good immobilization in the forward area by the use of single hip spica casts, or, at least, Tobruk splints. Emphasis was also placed upon the instillation of penicillin after the joint had been closed at operation and upon aspiration, with reinstallation of penicillin, through a window in the cast 24 to 48 hours after operation.

3. It was recommended that injured hands be immobilized in the position of function and that a good occlusive dressing be applied. It was also recommended that a trial be given to the so-called boxing-glove type of plaster cast over mechanic's waste and sheet cotton. This method was then being tested in a number of hospitals, and its more extensive use was suggested.

4. It was pointed out that immobilization and the use of an occlusive dressing in wounds of the soft parts treated in forward areas were essential for successful reparative surgery in rear hospitals.

64th General Hospital.—This hospital, which was visited 11–15 September, was the only general hospital at Leghorn, Italy. It was very busy with battle casualties. Some few were admitted for initial wound surgery. Others were received from evacuation hospitals. Many patients were admitted from station hospitals with large outpatient clinics. The casualties included both United States and British naval personnel. Although relatively few seriously wounded men were being admitted at this time, the treatment of many of the injuries was very time consuming. Arrangements for handling fresh battle casualties were excellent, and the work was well integrated with the reparative phase of the hospital work.

Surgery on fracture cases was observed in the operating room, and ward rounds were made. In general, reparative surgery was satisfactory. There had been some modifications in the program, the evaluation of which could be made only at a later date. A few fractures had been managed by internal fixation. Results in the few wounds which had been closed at initial wound surgery were not considered satisfactory, and staged procedures were advised.

The sections of Circular Letter No. 46 which applied to orthopedic surgery were discussed.

It was noted at this hospital that several soldiers of the 92d Infantry Division had received tetanus antitoxin instead of tetanus toxoid. A wound adjacent to the knee had been sutured in the battalion aid station with the foreign body still in situ. These and related observations were reported to Colonel Snyder.

Hospitals in the Rome area.—The 33d General Hospital was not receiving patients at the time of this visit, and all remaining patients were already pre-

¹ See appendix, pp. 326–331.

pared for transfer to other hospitals. The more serious fracture cases were examined on the wards. Under the stress of closing the hospital, a number of patients with fractures of the femur had been boarded for the Zone of Interior. Their transportability seemed doubtful, and it was suggested that notes be made on their records to warn the next receiving hospital that further definitive care might be needed before evacuation.

The reparative-surgery program had been carried out well in this hospital, with strong (perhaps excessive) emphasis on internal fixation.

The 12th General Hospital had an excellent program of reparative surgery in accordance with theater recommendations. The orthopedic section had an extremely conservative attitude toward the internal fixation of compound fractures.

The 12th General Hospital made a number of suggestions, including the following:

1. That dry fine-mesh gauze be substituted for vaseline gauze in all echelons.

2. That hand injuries observed in forward areas be put up with mechanic's waste between the fingers as well as over the entire hand in the application of pressure dressings. There was skepticism about the value of the boxing-glove plaster cast, but it was regarded as worthy of a trial.

3. That simple interrupted sutures be used for delayed primary closures, instead of vertical mattress sutures.

The 6th General Hospital was visited for only half a day, and the number of cases observed was necessarily limited. The reparative-surgery program was in full use, with satisfactory results. At a meeting of the surgical staff, Circular Letter No. 46 was freely discussed. Objection was raised to the "no deviation" clause under amputations, and a case was described in which each dressing produced hemorrhage until a skin graft was applied; then healing was prompt. The staff concurred in the principles laid down in this circular but felt that occasional exceptions should be permitted. It was suggested that, if and when good surgical judgment seemed to call for a deviation from the stated policies, the deviation should be permitted but full explanatory notes should be added to the record.

In the light of the 60-day holding policy, the section on duration of traction for fractures of the femur was also questioned. It was agreed that Circular Letter No. 46 gave the hospital staff authority to maintain traction as long as a patient's condition required it.

At the 73d Station Hospital, a planeload of battle casualties had been received from France the night before. Many of the injuries were serious, including fractures of the femur and wounds of the knee joint. Arrangements had been made to transfer the most seriously wounded patients to a general hospital. Several fractures of the femur were in traction on the wards. It was suggested that in the future, if such patients were transportable, they be sent to a general hospital as soon as possible after admission. Some excellent results were seen in this station hospital, but a tendency was noted to hold, as

possible category B (limited duty) dispositions, patients who would almost certainly require category C dispositions. The whole question of dispositions was discussed with the chief of the surgical section.

It was noted in all the general hospitals visited that many patients who had received penicillin in the evacuation hospitals were being received without the proper notification ("On Penicillin") in the appropriate place on the jacket of the Medical Field Record, as prescribed in Circular Letter No. 36, 1 July 1944, Office of the Surgeon, North African Theater of Operations, United States Army.² This omission was reported to Colonel Snyder.

October–November 1944

These visits of inspection, which began 15 October and ended 19 November, covered the Continental Advance and Delta Base Sections.

Continental Advance Base Section.—The 46th General Hospital was visited 16–24 October and again 17 November. The surgical service, on the first visit, was heavily loaded with both United States and French battle casualties. French casualties were reaching the hospital without initial wound surgery. Efforts to perform initial surgery on the French casualties and reparative surgery on both French and United States casualties had taxed the surgeons to the limit, and reparative surgery had been possible to only a limited degree. Formal and informal conferences were held with the surgical service, laboratory service, and commanding officer, and the North African Theater of Operations, United States Army plan of reparative surgery, which consisted of surgery, blood replacement, and penicillin therapy, was described in detail. The reception of the plan was enthusiastic. At the request of the orthopedic surgeons, a number of patients were operated on to demonstrate the principles of the program. Many case histories were obtained, and serial photographs were arranged for. On the return visit to this hospital, 17 November, the new program was found to be functioning adequately.

The 36th General Hospital was visited 25–28 October, 30 October–1 November, and 16 November. At the time of the first visit, the surgical service was functioning with incomplete physical facilities, and the orthopedic section was particularly handicapped. Improvement was noted on the return visits, which were made at the request of the recently installed chief of the orthopedic service, for consultation on a number of cases of various types. This officer was doing an excellent job.

The 21st General Hospital was visited 29 October. The surgical service was not yet ready for admissions, but the facilities planned for the orthopedic section were the best yet seen in the theater. The orthopedic staff, as the result of an extensive experience, was already competent in reparative surgery.

The 180th Station Hospital was visited 1 November. At a staff meeting, the entire program of reparative surgery was presented and was followed by a prolonged question-and-answer session.

² See appendix, pp. 321–326.

The 35th Station Hospital was visited 2 November, when the weather prevented travel to the Delta Base Section, as planned. Reparative surgery was discussed at length with the chiefs of surgery and orthopedic surgery. The hospital was busy with minor battle casualties and had received some severely wounded patients from two plane crashes and a number of roadside accidents. Many patients were seen on the wards in consultation. The professional work was good.

Delta Base Section.—The 43d General Hospital was visited 3–6 November, 10–11 November, and 13–15 November. The surgical service was overloaded with United States Army casualties and German prisoners of war. Reparative surgery was in progress on the wounds of the soft parts. The chief of the orthopedic section was then hospitalized; later, he had to be evacuated to the United States, and a new chief of section was subsequently appointed by the hospital commander. Formal and informal conferences were held, and many patients were seen in consultation. Some were operated on, by request, to demonstrate the principles of the reparative-surgery program. Considerable progress was being made on orthopedic work in this hospital.

The 3d General Hospital was visited 7 November. Orthopedic surgery was being conducted along the same principles as had been previously employed at this hospital. Some cases were well handled, but the management of others did not measure up to the theater standards. This situation was reported to the Delta Base surgeon.

The 78th Station Hospital was visited 8 November. This hospital had received casualties from the Airborne Task Force, the most severely wounded of whom had received initial surgery at the 514th Clearing Company. Ward rounds were made and problems discussed. Transfers to general hospitals were being made correctly.

The 70th Station Hospital was visited 12 November. Surgery on the usual good station-hospital level was being performed.

The 80th Station Hospital was visited 12 November. The chief of surgery appeared to be doing an excellent job. All phases of reparative surgery were discussed with him. Several special problems, among them fractured femurs, were observed and discussed on the wards.

The 514th Clearing Company was visited 9 November. This station now had roentgenologic facilities, and its equipment was considered satisfactory. Two surgical teams, one from the 36th General Hospital and one from the 43d General Hospital, were attached to this Company. Operations had numbered 32 in September, 58 in October, and 16 to date in November. The work did not justify the attachment of two surgical teams, and the Delta Base Section surgeon was so informed. He planned to return the team from the 36th General Hospital to its proper station. The teams were advised to split all plaster casts (unsplit casts having been observed at the 78th Station Hospital) and to utilize elastic cord, a supply of which was on hand, for skin traction on amputation stumps.

Additional activities.—The consultant in surgery, Seventh U. S. Army, was informed of the observations made in rear hospitals on the surgery performed in forward hospitals. Case reports were furnished to him, and ward rounds were made with him at the 36th and 46th General Hospitals. At his request, information was supplied to the surgeon, Sixth Army Group, concerning the observations which had been made on casualties being evacuated by train and air from Army holding stations to Continental Advance and Delta Base Sections, and from Continental Advance to Delta Base Section.

ASSIGNMENT OF PERSONNEL

When the landings were made in North Africa, in the fall of 1942, the exact role to be played by qualified orthopedic surgeons in an overseas theater was still to be determined. This was chiefly because the exact surgical missions of the various echelons of medical care in the staged management of the wounded had not yet been clearly defined.

Only a few of the evacuation hospitals which arrived early in North Africa had orthopedic surgeons on their staffs, though many had general surgeons experienced in the management of fractures. The initial experiences led to the decision that each such hospital should have an orthopedic surgeon on the staff. This was not because it was expected that all wounds of the extremities would affect bones and joints or because it was considered essential that an orthopedic surgeon should perform all initial surgery in bone and joint injuries, which was an obvious impossibility. The chief reason for the decision was that a qualified orthopedic surgeon should be available in each evacuation hospital for consultation on such special problems as wounds of the joints, complicated fractures of the femur, injuries which might require amputation, and similar serious problems. It was felt that the orthopedic surgeon, with his specialized knowledge and wider experience in plaster techniques, would be extremely useful to the general surgeons who would necessarily perform most of the initial surgery in evacuation hospitals. It was also intended, of course, that, as time permitted, the orthopedic surgeon should himself handle injuries of extreme severity, such as compound comminuted fractures of the femur and penetrating wounds of the knee and hip joint.

Another reason orthopedic surgeons were assigned to forward hospitals had to do with the management and disposition of soldiers with non-battle-connected complaints, such as internal derangements of the knee, painful backs, and foot disabilities. Manpower, especially combat manpower, was always in short supply, and it was essential that as many of these soldiers as possible should be returned to duty as promptly as possible, without the loss of time and effort which would be expended in their transfer to general hospitals. On the other hand, it was equally important that men who really needed treatment and who could not be promptly returned to duty should be evacuated to

hospitals in the rear without delay. These decisions were often delicate and could best be made against a background of orthopedic training and experience.

For these reasons, many of the younger, well-trained and capable orthopedic surgeons, who had had previous experience in civilian traumatic surgery, were transferred to evacuation hospitals as soon as they arrived in the theater on the staffs of general hospitals. This proved to be a wise plan as long as policies concerning the management of bone and joint injuries were still in a state of flux. The anticipated effectiveness of these trained orthopedic surgeons was fully realized, and they made important contributions to the increasing efficiency of initial wound surgery. They themselves, however, were seldom content with these assignments, and requests for transfers to general hospitals were frequent, on the ground that as trained orthopedic surgeons they would be more useful in the performance of reparative surgery and definitive reduction of fractures than they were in evacuation hospitals, where initial surgery was limited to debridement, gross alinement of fractures, and transportation splinting.

Although the weight of these arguments was fully realized, the policy of assigning orthopedic surgeons to evacuation hospitals continued the same in the Mediterranean theater throughout the war. In retrospect, this inflexibility does not seem to have been altogether wise. As policies of surgical management in forward areas became standardized and as surgeons in these areas became experienced in the management of wounds of the extremities, the original need for orthopedic surgeons in evacuation hospitals became much less pressing. At this time, in view of the shortage of trained orthopedic personnel in rear hospitals and the demands of the regimen of reparative surgery for trained men, it would probably have been wiser to utilize in general hospitals many of the surgeons assigned to evacuation hospitals. The assignment of a consultant in orthopedic surgery to each army (p. 5) would further have reduced the need for experienced orthopedic surgeons in hospitals in the army areas.

Orthopedic surgeons who were heads of orthopedic teams were occasionally attached to field hospitals in the division area in Sicily and in the early days of the fighting in Italy, but this practice was a misuse of qualified personnel and was soon discontinued. Injuries of the bones and joints were seldom, in themselves, of sufficient urgency to require treatment in field hospitals, and the few which were could be cared for by the well-trained general surgeons attached to these installations. Orthopedic surgeons, on the other hand, were seldom equipped to treat the serious wounds of the chest and abdomen which constituted the chief work in a field hospital, and they could not, therefore, handle a proportionate share of casualties with these injuries or of casualties with multiple injuries involving the chest and abdomen as well as the extremities. For these reasons, orthopedic teams were used only in evacuation hospitals after early 1944.

FACILITIES

In World War II, before a casualty with a bone and joint injury reached a general hospital in the communications zone, he had passed, successively, through a battalion aid station, a collecting station, a clearing station, and an evacuation or field hospital. The care he received in the division area was limited to emergency measures designed to supplement the first aid he had received on the battlefield and to make him transportable to the evacuation hospital. Classification as to transportability was a major responsibility of the clearing station. No special orthopedic equipment other than splints was therefore usually required in these echelons of medical care (figs. 1, 2, 3, 4, and 5).

Soldiers with wounds of the extremities, as already noted, were usually second-priority casualties. They were therefore not transferred to the field hospital adjacent to the clearing station unless shock, the presence of a tourniquet, a traumatic amputation, an abdominal wound, a severe chest wound, or an impaired airway required immediate attention.

Definitive initial surgery in the evacuation or field hospital was directed toward the management of the soft-tissue injury, not the bone injury, except for gross alinement of fractures and immobilization for transportation. Plaster of paris and auxiliary supplies and splints were therefore the only special equipment required for bone and joint injuries in the evacuation hospital (figs. 6, 7, and 8). A fracture table was essential equipment, and the portable fracture table provided by Medical Supply (Item No. 7099300) proved entirely satisfactory.

Materials for internal fixation of fractures, overhead fracture frames, and material for the management of fractures in balanced-suspension skeletal traction were authorized items of supply in evacuation hospitals. They were all superfluous items at this level. They are used in the definitive management of fractures, which is the mission of hospitals in the communications zone, though not of installations in the army area.

In the general hospital in the communications zone (fig. 9), where fractures were reduced and other definitive care provided, desirable special facilities included, at a minimum—

1. An operating room, at least 20 by 25 feet, to accommodate two operating tables and a large table for sterile supplies. It was also desirable to have an adjoining room in which patients could be anesthetized and in which the transportation casts applied in the evacuation hospital could be removed.

2. A ward of 75 to 100 beds, to be used as a femur (traction) ward. It was essential that this ward be equipped for the taking of roentgenograms with portable apparatus and desirable that it be near the X-ray department.

3. Other wards of 75 to 100 beds. When it was practical, it was best to admit patients to these wards according to the nature of their injuries, but anatomic subdivision was not always possible because of multiplicity of wounds and the variations in the bed status. The principle of segregation of special



AFIP CA-4340-D

FIGURE 1.—First aid in field, Fifth U. S. Army, Italy, December 1943.

injuries, however, was sound and preferably was adhered to as circumstances permitted.

4. A plaster room, about 20 by 30 feet, equipped with three plaster tables; a fully equipped table for dressings; and storage cabinets for splints, accessory materials, and sterile supplies. This plaster room was preferably located adjacent to the principal orthopedic ward. It was used for the changing of plaster casts as well as for minor surgical procedures, usually without anesthesia.

Essential items of supply in a general hospital included an adequate number of overhead fracture frames, Army half-ring leg splints, and materials for balanced-suspension skeletal traction and for internal fixation of fractures, as well as materials for the application of plaster-of-paris casts.

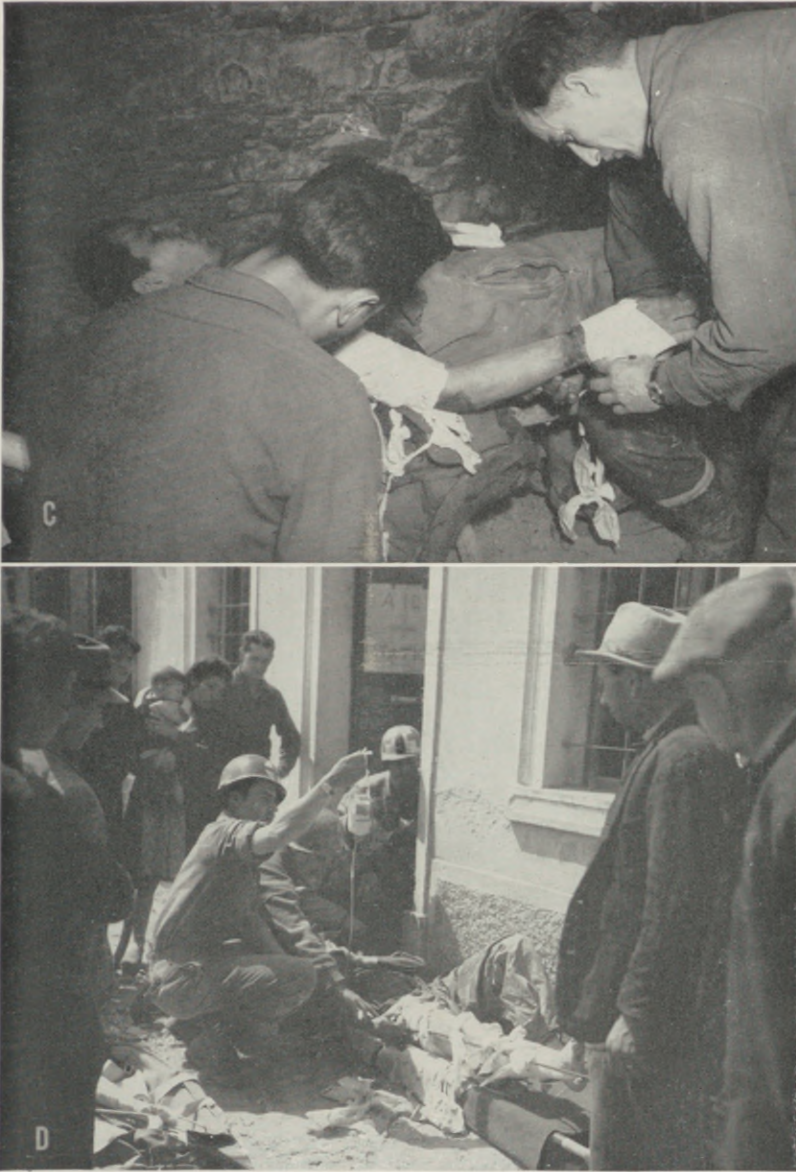
5. Facilities for the examination of ambulatory patients from other wards and of outpatients. The plaster room could be used for this purpose, if necessary, but this was less desirable than provision for a special consultation and examining room.

Braceshops.—Although tables of organization included a qualified brace-maker in the personnel of all numbered general hospitals, tables of equipment provided little equipment for braceshops when these hospitals first came into the North African theater. It soon became evident, however, that there was a definite need for a few braces, special splints, belts, and similar items in an overseas theater which functioned on a 90- to 120-day holding policy.



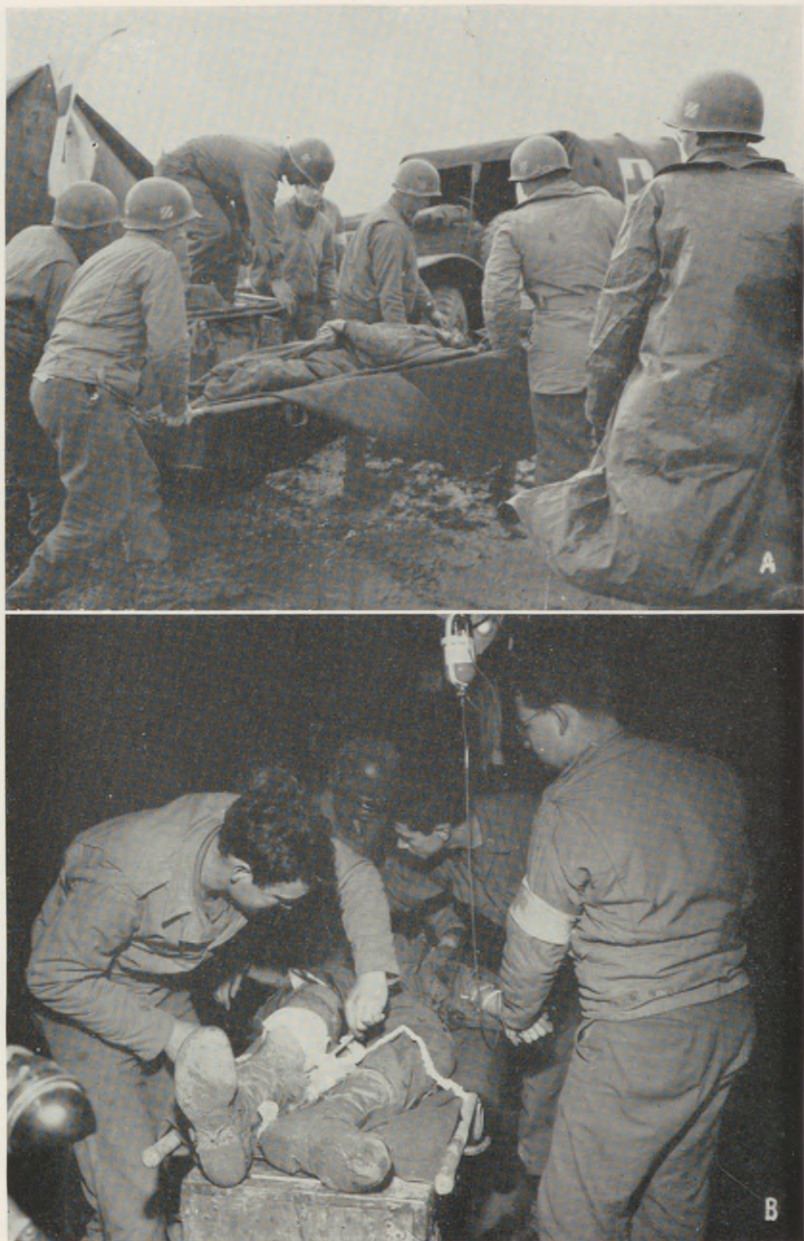U. S. Army photos

FIGURE 2.—Scenes at battalion aid stations in World War II. A. Litter bearers bringing casualty into Fifth U.S. Army battalion aid station in Italy. B. Infantrymen at Fifth U.S. Army battalion aid station in Italy waiting for evacuation. They had been dug out of a wrecked building which had collapsed after being hit by a shell.



U. S. Army photos

FIGURE 2—Continued. C. Administration of first aid to infantryman in Fifth U.S. Army battalion aid station in Italy. This man, like the casualties in B, had been dug out of a wrecked building which had collapsed after being hit by a shell. D. Administration of plasma to wounded German prisoner outside of Fifth U.S. Army battalion aid station in Italy, April 1945.



U. S. Army photos

FIGURE 3.—Scenes at collecting station on Anzio beachhead, March 1944. A. Infantryman, wounded by enemy artillery, being carried into a collecting station after transportation to the station in the back of a jeep. B. Wounded infantryman being given plasma at medical collecting company.



U. S. Army photo

FIGURE 4.—Casualty being taken into admission tent of clearing station, Fifth U.S. Army, Italy, November 1943.

The first braceshop to function in North Africa was set up at the 21st General Hospital, late in 1942, soon after the hospital was established at Bou Hanifia, the site of a former spa, some 65 miles south of Oran. Many of the tools were secured from the well-equipped machine shop that had been part of the former bathhouse and hotel facilities. Other tools, as well as supplies of steel, leather, and salvaged canvas, were obtained from the engineering and quartermaster departments in the base section.

As this shop was the only equipped braceshop functioning at this time in the Mediterranean Base Section, requisitions were forwarded to it, through the office of the base surgeon, from other hospitals in the area. Eventually, the volume of requisitions became so large that this shop was formally designated as braceshop for the entire base section. This proved an efficient and economical plan. As might have been expected, the orthopedic staff at the 21st General Hospital made the fullest use of the braceshop, but orthopedic surgeons in other hospitals in the base section were also assured of the braces and belts which they needed without the expenditure of a large overhead in their own hospitals. There was no waste of personnel. Requisitions from other hospitals in addition to his own kept the bracemaker at the 21st General Hospital busy at all times and justified the maintenance of a fully equipped and staffed shop. The requisition and provision of material were also simplified and expedited by the operation of a single shop rather than multiple shops.

When the 21st General Hospital was moved from North Africa to Italy, the braceshop at the 46th General Hospital served the hospitals in the medical center at Oran by the same general plan. The bracemaker in charge had had



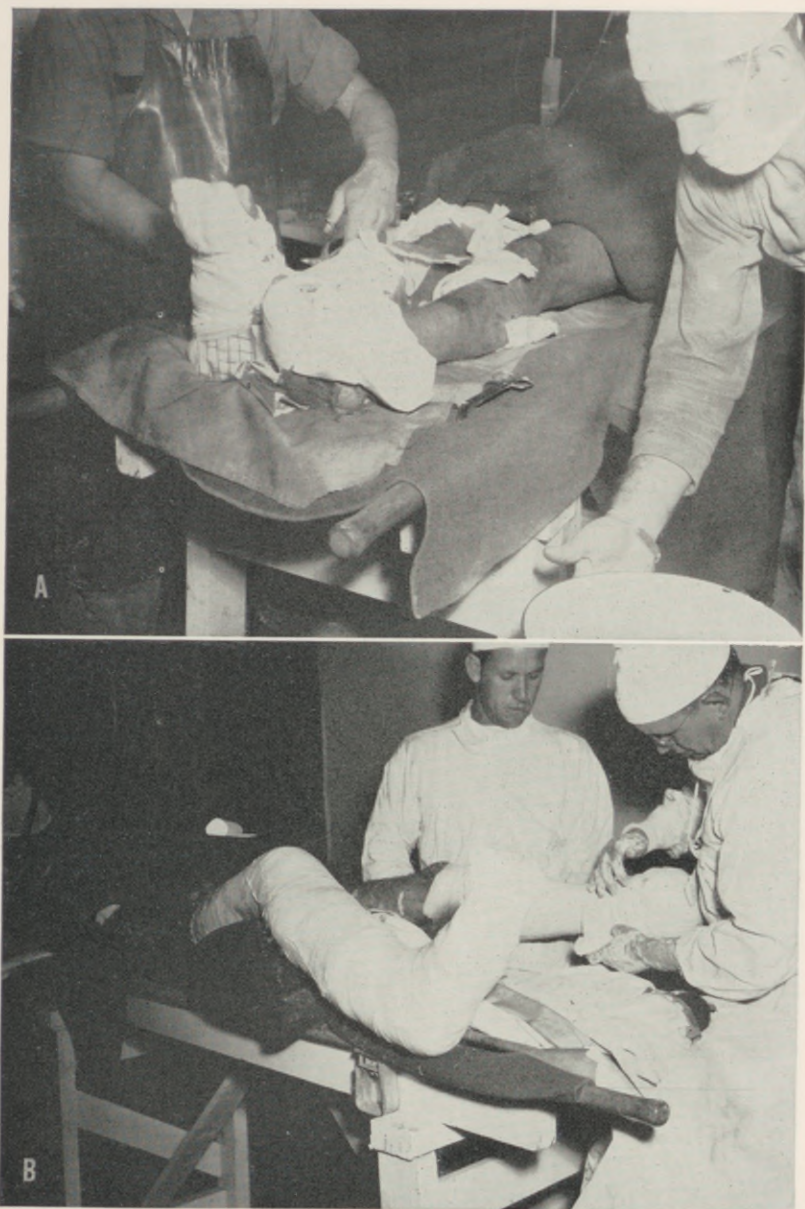
U. S. Army photo

FIGURE 5.—Ambulance transportation of wounded, Fifth U.S. Army, Italy, April 1945.

an extensive experience in civilian life, and bracemakers from other hospitals in the area at times worked under his direction. In Italy, the braceshop at the 21st General Hospital served the 3 general and 2 station hospitals in the medical center at Bagnoli, just outside of Naples, as well as the orthopedic section of its own hospital.

A shop planned for the 24th General Hospital and intended to serve the medical center at Bizerte did not become operational, as this hospital and the other hospitals the braceshop was intended to supply moved to Italy shortly after the equipment for the shop had been issued. Hospitals not served by area braceshops continued to operate their own small shops, to meet their special needs. In these isolated hospitals, the bracemakers usually served as orthopedic technicians, with bracemaking an incidental assignment.

The output of the theater braceshops consisted chiefly of canvas belts for support of the back, metal braces for personnel returning to limited duty, and individual splints and appliances. Standard splints were repaired and altered, and shoes were also altered. Since patients with fractures which would not permit return to duty within the period of the theater holding policy were evacuated to the Zone of Interior while they were still in plaster, there were few calls for the type of brace which would be needed during reconstructive surgery and rehabilitation.



U. S. Army photos

FIGURE 6.—Scenes in 33d Field Hospital, Fifth U.S. Army, Italy, September 1944. A. Removal, in operating room, of bandages placed on patient by medical aidmen in field. B. Dressing of wounds of distal portion of foot following initial surgery and application of a cast for fractures of the bones of the leg.



U. S. Army photos

FIGURE 7.—Scenes in 8th Evacuation Hospital, Fifth U.S. Army, Italy, January 1944. A. Wounded soldiers lying in receiving room of hospital. B. Winterized wards of hospital. Winterizing was accomplished by building up wooden sides inside the side walls of the ward tent to the height of the canvas and placing wooden frames, with doors, at the ends of the tent. Wooden floors were also provided. C. Operation of initial surgery for wounds of the extremity in progress.



AFIP CA-4340-A; U. S. Army photos

FIGURE 8.—A. 94th Evacuation Hospital, Fifth U.S. Army, Italy, December 1943. B. Operation by orthopedic team from 2d Auxiliary Surgical Group at 94th Evacuation Hospital, Fifth U.S. Army, Italy, December 1943. Cast is being applied after initial surgery for compound fracture of the left femur, caused by shell fragment. Note use of portable fracture table.



U. S. Army photos

FIGURE 9.—24th General Hospital, Florence, Italy. A. Exterior view of headquarters and surgical buildings. B. Operating room. C. Large surgical ward, serving especially for patients in traction.

HOSPITAL ADMINISTRATION

Assignment of cases.—When the North African Theater of Operations was established, the assignment of responsibility for compound fractures was somewhat confused. Some chiefs of surgery felt that, as in World War I, these injuries should be the responsibility of general as well as orthopedic surgeons and should be treated in general surgical as well as orthopedic sections. In several hospitals, the chiefs of surgical sections elected to assign casualties with bone and joint injuries alternately to general surgical and orthopedic sections.

These policies proved unwise and unsound. The general surgeon and the orthopedic surgeon frequently had wise counsel and skilled assistance to offer each other in the management of combat wounds, but only a brief experience was necessary to demonstrate that the best results were obtained when bone and joint injuries were managed exclusively in orthopedic wards. Almost without exception, this was the policy in effect in all general hospitals in the theater by the spring of 1944.

Segregation of bone and joint injuries, as already noted, was neither necessary nor practical in evacuation hospitals, where initial surgery was limited to management of the compounding wound. In properly operated fixed hospitals, however, it was found best for orthopedic sections to receive all casualties with fractures and joint injuries except, for obvious reasons, those with associated fractures of the ribs, skull, and maxillofacial bones. Fractures of the bones of the hand were also exceptions to this policy in hospitals in which general surgeons experienced in the management of hand injuries were attached to the staff. Otherwise, these injuries were managed on orthopedic wards.

Patients with concurrent wounds which relegated fractures to a place of secondary importance were admitted to the general surgical or other appropriate wards, but personnel from the orthopedic section assumed responsibility for the bone and joint injuries. Failure to provide permissible treatment of the fracture would have resulted in needless deformity and might even have caused a spreading, life-endangering infection.

Orthopedic surgeons also had the responsibility for all acute, recurrent, and chronic conditions affecting the function of the bones and joints of the extremities and of the back and shoulders.

Consultations were answered on request from the remainder of the surgical service and from other services in the hospital. Examinations were carried out on the ward or in the outpatient department, according to the status of the patient.

Caseload.—The proportion of the hospital census represented by the orthopedic caseload varied according to the total hospital census, which might be unusually high because of medical conditions or for other reasons. As a rule, during an active campaign, the orthopedic section accounted for about 25 percent of the hospital population and for about 35 to 40 percent of the

surgical census. After the campaign ended, these proportions usually increased because of the long periods of hospitalization required by casualties with fractures.

To take care of this load ideally in a 1,000- or 2,000-bed general hospital, the following personnel was necessary:

1. A chief of the orthopedic section, who was responsible to and worked under the administrative control of the chief of the surgical service. Technically, a classification of B-3153 was desirable, though, when their training, initiative, and industry warranted it, these assignments were often given to officers with classification of C-3153. Many of these officers rapidly attained the higher rating, particularly if they had had some previous civilian experience in acute trauma of the extremities. Many of them did outstanding orthopedic surgery in North Africa, Sicily, and Italy.

If the chief of the orthopedic service were to perform his duties competently, he had to exercise his supervisory and executive functions to the fullest extent. They were not so exercised when he dissipated his time and effort by assuming the duties of a ward officer on any special ward. It was essential, instead, that he keep his time free for ward rounds, supervision of junior officers, emergency consultations, observation of seriously ill soldiers, and operating-room duties. At times, he had to spend the entire day in the operating room. The best section chiefs were those who utilized their time in this fashion.

2. A senior ward officer, to serve in a twofold capacity, as assistant chief of the orthopedic section and as ward officer on the traction ward. As the reparative program for compound fractures developed (p. 53), it became extremely important to have on each service an experienced orthopedic surgeon, or a general surgeon with special experience in traumatic surgery, who was qualified to make quick decisions when the pressure of work was too heavy for the chief of the section to make them all. These decisions frequently had to be made in the operating room.

The assistant chief of section was usually either a C-3153 or a C-3150 (general surgeon), though officers with D classifications, who were interested in traumatic surgery, frequently advanced, sometimes rapidly, to the higher rating. In the Mediterranean theater, it proved perfectly satisfactory for general surgeons to assume the management of fractures and joint injuries, provided that they functioned as members of the orthopedic staff, under the supervision of the chief of the orthopedic section. It was, however, neither desirable nor practical for a general surgeon to have the responsibility of fracture management if at the same time he had the responsibility for abdominal and chest injuries and for other unrelated injuries.

3. Junior ward officers. These officers had classifications of D-3153 or D-3150, but, as in other categories, it was possible for officers with general-duty classifications to advance to specialty categories if they were interested in traumatic surgery. Each junior ward officer usually carried a patient load of 75

to 100 patients, the number varying with the size of the hospital and the number of admissions after a campaign.

When convalescent sections were set up in general hospitals, it was found to be highly desirable for each ward officer to continue to supervise his own patients as they were transferred to these sections. This duty increased the officer's caseload, but, as convalescent casualties required only a minimum of care, the burden seldom proved excessive, and the continuity of care thus secured was well worth the extra effort.

4. **Technicians.** A qualified, industrious group of enlisted technicians was indispensable for the smooth functioning of an orthopedic section. Their training in plaster and splinting techniques was the responsibility of the chief of the orthopedic section in each hospital. An orthopedic section caring for 400 to 500 patients required at least 5 technicians and also required the services of a bracemaker (p. 15). Properly taught technicians readily mastered all the principles and details of plaster, splinting, and skeletal-traction techniques. With experience and under minimal supervision, they could apply plaster casts, including spicas; erect Balkan frames (see fig. 9C); arrange pulleys for skeletal traction; and perform numerous similar duties, thus leaving medical officers free for strictly medical tasks. Technicians also made plaster bandages, if stock supplies were not available.

It was the usual practice for the best qualified man in the group to serve as the chief technician. Among his other duties were the storage, maintenance, and supply of splints, accessories, and plaster.

Outpatient dispensaries.—After a short experience with the operation of outpatient dispensaries in general hospitals, it became clear that these dispensaries should be kept to an absolute minimum and should be chiefly used for seeing ambulatory patients in consultation and for periodic observation of convalescing patients. Any other plan handicapped the smooth functioning of the orthopedic section because it required the withdrawal from it of much-needed personnel. Outpatient clinics attached to station hospitals were better prepared to take care of the type of work ordinarily seen in a civilian orthopedic clinic, and it was particularly desirable and convenient for them to exercise this function in base sections.

GRAPHIC RECORDS

Early in 1944, the Army Pictorial Service provided, informally, photographers to assist the consultant in orthopedic surgery in recording methods of splinting and other orthopedic procedures and in securing illustrations of the results of wound and fracture management. These illustrations proved very useful for instructional and demonstration purposes.

Later, the 3d and 6th Medical Composite Detachments, Museum and Medical Arts Service, supplied both photographers and artists as the need arose. Photographs and drawings were thus accumulated to show variations

in traction and splinting methods, serial wound management, the technique of special operations, and various other items. In many instances, it was possible to make complete case studies from the first observation of the casualty in a forward hospital, before initial surgery, to the end results of management in base hospitals, before disposition. Motion pictures were also made, some of them in color.

ACCUMULATION OF DATA

Throughout the period of active fighting, as well as after the war ended, several different plans were followed to accumulate data on casualties with bone and joint injuries. The following methods were used:

1. Throughout the period of active fighting, efforts were made to stimulate the interest of the various chiefs of orthopedic sections in accumulating factual information on small groups of cases according to their special interests.

2. In relatively quiescent periods, arrangements were made through the theater surgeon for several chiefs of orthopedic sections in general hospitals to travel about the theater to visit other general hospitals and to gather data on subjects of special interest to them and to the theater consultant in orthopedic surgery. These trips also served to acquaint the surgeons making the surveys with techniques and methods employed in other hospitals.

3. After the war ended, arrangements were made through the theater surgeon to have additional surveys made by other orthopedic surgeons, who visited most of the hospitals and studied their records on special orthopedic problems.

4. Still other medical officers were placed on temporary duty in the Office of the Surgeon, to study disposition-board proceedings and other records available in that office, in an effort to gather as much data as was possible on several special orthopedic problems and on the results of the treatment employed for them.

The data thus collected furnish some of the supporting information in various chapters of this history.

CHAPTER III

Splinting in the Combat Zone

CLASSIFICATION OF MILITARY SPLINTING

The exigencies of military surgery in World War II required, as already noted, that all care of battle casualties be rendered in phases, in installations located, equipped, and staffed for various specific missions. The splinting of bone and joint injuries was similarly timed. It was necessarily interrupted for each phase of surgical management. It was carried out with material and facilities that varied according to the mission of the installation at which the care was rendered. It was provided again, with a new objective, after each phase of treatment had been completed.

By a process of evolution, splinting in overseas military surgery in World War II (table 1) was eventually classified as follows:

1. Emergency or first-aid splinting, which was provided within the divisional area of the combat zone as an integral part of resuscitation and to render the casualty transportable to a hospital equipped for surgery.

2. Splinting after initial wound surgery, which was provided in an evacuation hospital or, as indicated, in a field hospital. It was not intended to obtain or maintain reduction of fractures. Its objective was to facilitate transfer of the wounded soldier to a fixed hospital in the communications zone.

3. Splinting after reparative surgery, which was applied in a fixed hospital in the communications zone. It was sometimes designed to achieve reduction of fractures. It was always designed to maintain reduction and to provide prolonged immobilization. As a matter of convenience, it will be discussed under the headings of the management of regional and special injuries.

4. With an occasional exception, such as fractures of the femur and of the hand, splinting for transportation to the Zone of Interior did not represent a special type. The casts applied after reparative surgery were sometimes changed before the casualty was returned to the United States, for reasons of cleanliness or because the casts had become too loose to be effective. As a rule, however, the definitive splinting applied for the fracture in the fixed hospital served until the cast was removed in the hospital in the Zone of Interior in which treatment would be continued.

TABLE 1.—Classification of splinting of compound battle fractures by phase of management, in relation to timing, objectives, and facilities

Phase of management	Time after wounding	Anticipated duration	Medical installation	Surgical personnel	Methods	Materials, facilities
Emergency, transportation to a forward hospital.	0-12 hours...	4-24 hours...	Battlefield, battalion aid station.	Medical aidmen.....	Improved, standard.....	Improved, half- and full-ring splints, basswood, wire ladder splints, slings.
Initial surgery, transportation to a fixed hospital.	8-36 hours...	1-10 days...	Battalion aid, collecting, clearing stations. Field, evacuation hospitals.	General-duty medical officers. General, orthopedic surgeons.	Inspection, adjustment, replacement. Plaster casts, skin traction (amputation), metal splint (occasional).	X-ray facilities, plaster, standard splints.
Reparative surgery, maintenance fracture reduction.	5-10 days...	21-120 days...	General, special station hospitals.	General, orthopedic surgeons, physiotherapists.	Skeletal traction, plaster casts, internal and external fixation, metal splints, walking irons, simple braces.	X-ray facilities, plaster, standard splints, Kirschner wires, Steinmann pins, Balkan frames, bone plates, screws, external-fixation apparatus, braceshops. Do.
Transportation to Zone of Interior. ¹ En route to Zone of Interior.	21-120 days... ...do.....	7-28 days... 10-14 days...	do..... Hospital ship..... Plane..... Army general hospitals, special centers.	do..... General-duty officers. Nurse..... Orthopedic surgeons, physical and occupational therapists.	Plaster casts, simple metal splints. Changes of cast? ² None.....	Plaster. None. Complete, brace and prosthetic shops.
Reconstructive rehabilitative.

¹ After partial or complete bony union.² Only if necessary.

EMERGENCY SPLINTING

Historical Note

In World War I,¹ splints and other appliances used by the United States Army Medical Corps were not standardized until late in 1917. A board appointed by General Headquarters, American Expeditionary Forces, to investigate and report upon the advisability of standardization suggested that a manual of splinting be prepared for the use of medical officers. The manuscript was approved by the commanding general, American Expeditionary Forces, 9 September 1917, and 6 weeks later the Manual of Splints and Appliances for Use of the Medical Department of the United States Army was delivered to supply depots in France. The printing of the manual, as well as the manufacture and procurement of the recommended splints and other appliances, was then the responsibility of the American Red Cross.

A second board of officers was appointed in October 1918 to revise the manual on splinting and to examine the necessity for changes in the splints and other appliances in use. Although the board completed its work in only a few days, the second edition of the manual was not ready for distribution until 1 February 1919, more than 2 months after the end of World War I.

No significant changes seem to have been made in the methods prescribed in this manual until 11 September 1940, during the prewar mobilization of the United States Army. This was 15 months before the entry of this country into World War II. The manual issued at this time (Medical Field Manual, FM 8-50, Splints, Appliances, and Bandages) served as the textbook for the training of officers and enlisted men of the Army Medical Department during the period of mobilization and for the first 2 years of United States participation in World War II.

The methods described in this manual were based on the use of the splints standardized in the Army Tables of Equipment (then called the Basic Equipment List) before the beginning of mobilization. These methods were naturally modified in the light of experience in overseas theaters, but no formal revision of the manual was issued until 15 January 1944.

Splinting is mentioned only incidentally, and with almost no details, in Orthopedic Subjects,² one of the Military Surgical Manuals prepared by the Committee on Surgery of the Division of Medical Sciences of the National Research Council, which appeared in 1942.

Improvised splinting was not mentioned in the manuals prepared in World War I. It seems to have been included for the first time in the second (1931) edition of the Military Medical Manual. It was only briefly discussed

¹ The Medical Department of the United States Army in the World War. Washington: Government Printing Office, 1927, vol. XI, pt. 1, pp. 549-590.

² Orthopedic Subjects. Prepared and edited by the Committee on Orthopedic Surgery of the Committee on Surgery of the Division of Medical Sciences of the National Research Council. Military Surgical Manuals. Philadelphia & London: W. B. Saunders Co., 1942.

in this edition and was mentioned with similar brevity in each of the subsequent editions of this manual, including the sixth, which was issued in 1944.

The Medical Field Manual (FM 8-50) issued in 1940, also contains no mention of improvised splinting. The 1944 revision, entitled "Bandaging and Splinting," contains no direct text references to improvisations, but illustrations show the use of sticks as splints for the forearm and the use of a coat and a shirttail as slings. Soldiers Handbook (FM 21-100), issued 23 July 1941, contained a brief but excellent paragraph on the subject. First Aid for Soldiers (FM 21-11), issued 7 April 1943, contained a detailed description and many excellent illustrations of improvised methods of splinting. Long before this date, however, intensive and thorough instruction in improvised methods had been given to Medical Department enlisted men of the Regular Army, both before and during the period of mobilization and after the entry of the United States into the war.

Equipment

Standard United States Army equipment for emergency battlefield splinting in World War II included hinged half-ring leg splints; hinged full-ring arm splints; wire ladder and basswood splints; and triangular, roller, and Carlisle compressed bandages.

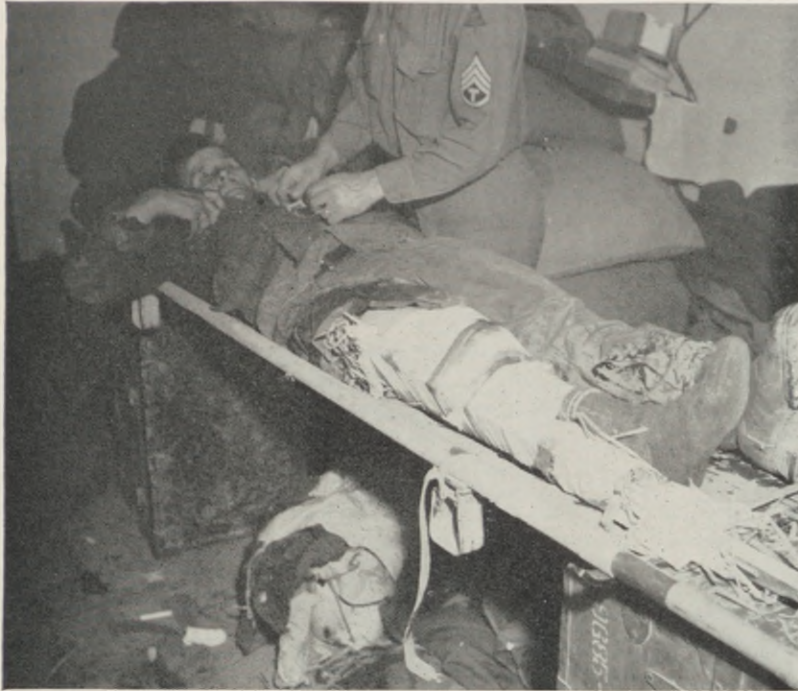This equipment, while it was generally efficient, was extremely cumbersome. Throughout the war, the desire was repeatedly expressed, and the need was clearly evident, for a light, readily adjustable, easily transportable, universally applicable splint which medical aidmen could use on the battlefield. At the end of the war, this need had not yet been satisfied.

General Considerations

The emergency splinting of a fractured extremity had as a chief objective the preparation of the wounded man for his transportation, with minimum discomfort, from the battlefield to a hospital in which he would receive surgical care. It was also an important part of first-aid management. It minimized or prevented shock in bone and joint injuries. It reduced the need for narcotics. It was thus an essential step in the resuscitation which had to be accomplished before surgery could be undertaken.

Reduction of the fracture was not an objective of emergency splinting. The purpose of emergency splinting was to prevent additional damage to the soft parts by fragments of bone and to keep the patient as comfortable as possible while he was on his way to the evacuation hospital. The criteria of its success were therefore comfort and relief from pain during transportation.

Medical aidmen, during their training, were always instructed that it was desirable, when possible, to "splint 'em where they lie" and to use standard methods of splinting. As a practical matter, neither of these instructions was always possible of accomplishment. For a variety of reasons, it was sometimes more expeditious to bring the wounded man to the battalion aid station on a



AFIP 45-55a

FIGURE 10.—Improvised battlefield splinting for fracture of femur. A board is secured to the trunk by the wounded man's own belt and to the injured right lower extremity by several turns of bandage.

litter. The chief of these reasons was that delay on the battlefield might have resulted in additional hazards to the casualty as well as risk to the aidmen themselves. In the battalion aid station, the environment was safer; better equipment was available; and the splinting, which could be applied deliberately, was frequently more precise and more accurate than splinting applied nearer the front. None of these reasons, however, was an indication for failure to splint the wounded man on the battlefield whenever that was possible.

Improvised splinting, as already mentioned, was taught along with standard methods during the period of training. The ingenuity of the United States Army medical aidman, when he found himself in circumstances of stress, often went beyond his formal teaching. A fractured lower extremity (fig. 10), for instance, was bandaged to a rifle, to a handy board, or to a limb from a nearby tree. A fractured upper extremity was held against the chest by the field jacket after the upturned shirttail had been fashioned into a sling. These and other improvisations proved extremely satisfactory, and, when they were adequate, they, like more conventional splinting, were left undisturbed as the casualty was evacuated through the successive echelons of the division medical battalion.

If for any reason either improvised or conventional splinting did not seem adequate, it was adjusted or replaced at the battalion aid station. All splints were carefully inspected at each subsequent installation and were adjusted as necessary, but they were not removed or replaced except for good reason. Even if it was necessary to remove the dressing and inspect the wound, it was seldom necessary to remove the splinting to accomplish this purpose.

Regional Emergency Splinting

Upper extremity.—Well-padded coaptation basswood or wire ladder splints furnished satisfactory emergency splinting in injuries of the bones and joints of the forearm and hand (fig. 11). It was promptly learned that a sling composed of a triangular or roller bandage must be added to keep the patient comfortable (fig. 11C).


Difficulties frequently developed when the hinged full-ring arm splint was used under battlefield conditions for fractures of the humerus. This splint proved undesirable in almost every respect. Many of the wounded soldiers complained of constant discomfort when they were put up in it with traction applied by means of a hitch placed about the wrist and fastened to the end of the splint. The full elbow extension produced by traction predisposed to angulation of the fragments, and the angulation, in turn, introduced risk of damage to the brachial artery and the main nerve trunks. Still another dangerous possibility from pressure of the ring was injury, which might be irreparable, to the axillary contents.

For these various reasons, the hinged full-ring arm splint was employed less and less during the course of the Tunisian campaign, but it was still occasionally used in the theater, in spite of instructions to the contrary, until December 1944, because new units coming from the United States had been taught to apply it.

Eventually, this splint was completely replaced for fractures of the arm and shoulder joint by two other methods which were simple to apply and which provided maximum relief of pain and discomfort. Both held the elbow in about 90° flexion.

1. In the first of these methods, a Carlisle pad was placed in the axilla and a triangular bandage was applied as a sling to hold the elbow at, or almost at, a right angle. A second triangular bandage was used to bind the arm, in this position, against the chest, and was reinforced by a few turns of a roller bandage. During the latter part of World War II, this simple method came to be considered the method of choice for emergency splinting of fractures of the humerus and for fractures about the shoulder.

2. The second method of emergency splinting (fig. 12) required the use of a padded wire ladder splint extending from the tip of the shoulder down the posterior aspect of the arm and forearm to the hand. The arm was held at the side, with the elbow almost at a right angle; then the splinted arm and forearm were bandaged against the chest by a roller or triangular bandage.



AFIP FC-44-3, C-44-66, C-44-657

FIGURE 11.—Emergency splinting applied for fractures of forearm and about elbow and wrist. A. Basswood coaptation splints used for fractures of forearm and wrist. Wire ladder splint used for fractures of forearm and about elbow. Note free use of Carlisle pads, loop of roller bandage for sling, and reenforcing turns of bandage which are added if shock or concurrent injuries make it desirable that soldier travel as litter case. B. Basswood splint (applied in battalion aid station) for compound fracture of forearm. C. Sling added to complete emergency splinting in compound fracture of forearm. D. Wire ladder splint and sling applied in clearing station for fracture of forearm by small-arms fire.

Lower extremity.—Either single or double wire ladder splints, well padded, were used for fractures of the foot and ankle (fig. 13). Often a single splint was sufficient; it was passed down the back of the leg, around the heel, and up the plantar surface of the foot. If false motion or instability at the site of the fracture was present with a single splint, a second was passed down one side of the leg, around the plantar surface of the heel, and up the other side of the leg. The foot was splinted at right angles to the leg, and roller bandages were used to hold the splint or splints in position.

The half-ring leg splint proved, on the whole, quite satisfactory for fractures of the leg, knee joint, thigh, and hip joint (fig. 14). Three triangular bandages served as slings for the fractured portion of the extremity and two others for the intact portion. The foot was held almost at a right angle by a foot support, and the distal end of the splint was elevated by another foot

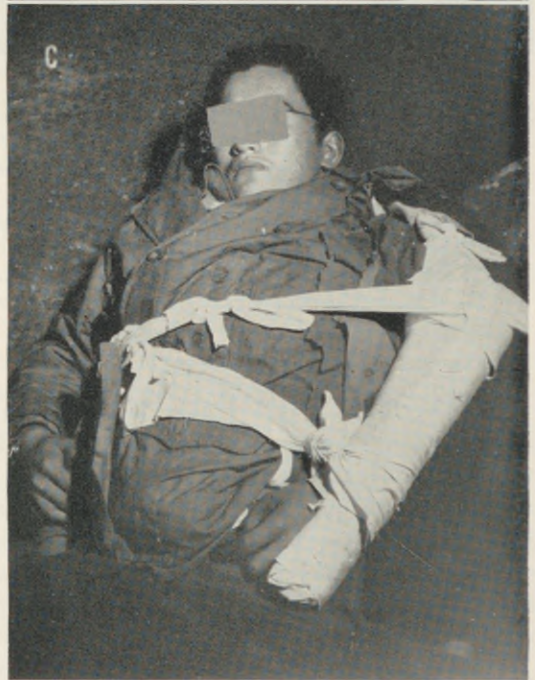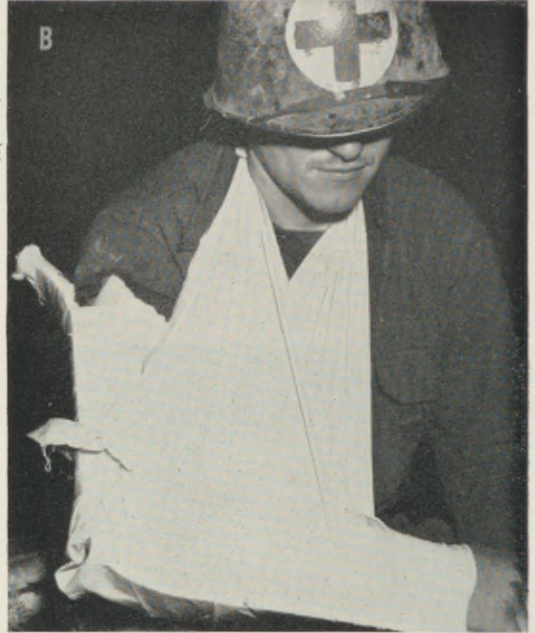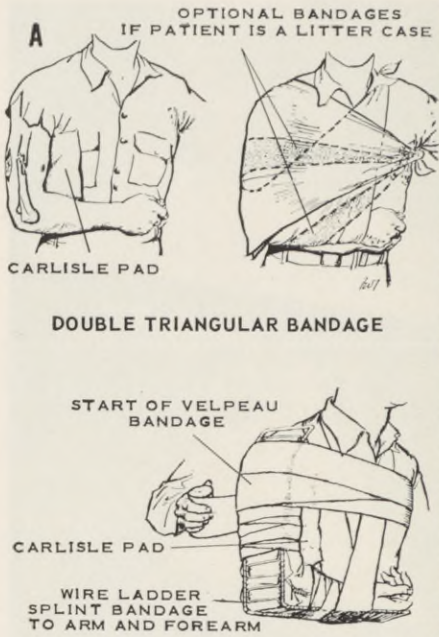


FIGURE 12.—Methods of emergency splinting, either of which is satisfactory, for fracture of humerus. Fractures in this location cause considerable pain, and effective splinting is essential for the patient's comfort during evacuation to a hospital. A. Technique of application of double triangular bandage and wire ladder splint reinforced by Velpeau bandage. B. Emergency splinting with wire ladder splint and sling for battle-incurred compound fracture of humerus. C. Wire ladder splint applied for emergency splinting of compound fracture about elbow. Note reinforcing bandages about body.

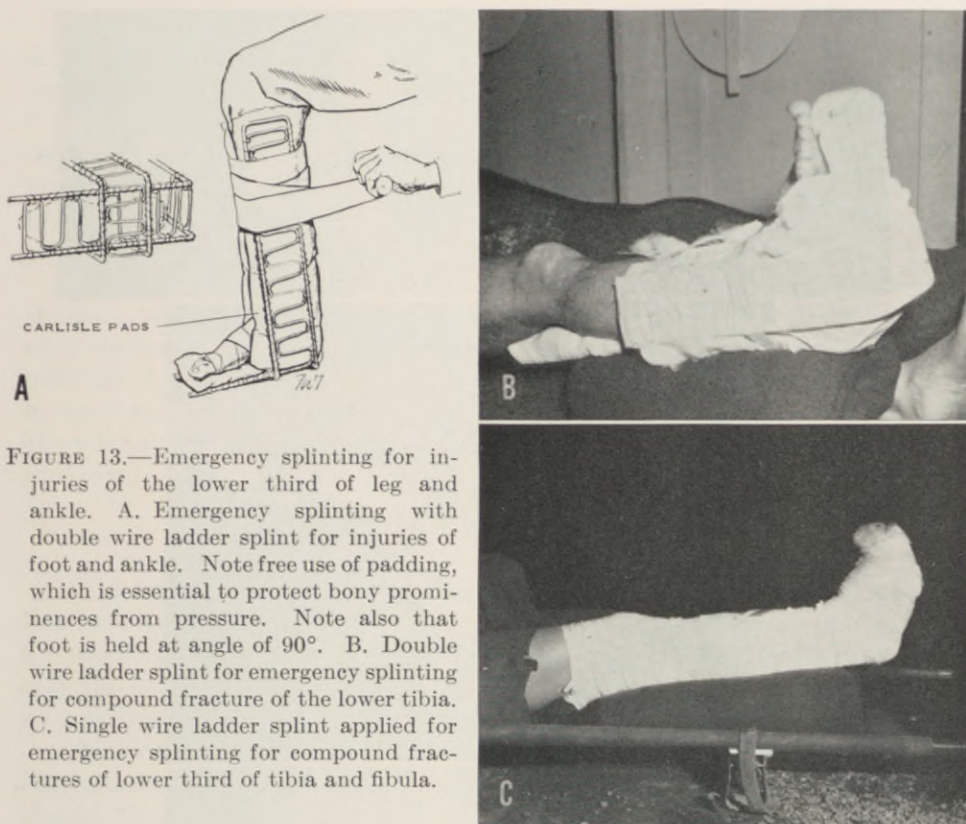


FIGURE 13.—Emergency splinting for injuries of the lower third of leg and ankle. A. Emergency splinting with double wire ladder splint for injuries of foot and ankle. Note free use of padding, which is essential to protect bony prominences from pressure. Note also that foot is held at angle of 90° . B. Double wire ladder splint for emergency splinting for compound fracture of the lower tibia. C. Single wire ladder splint applied for emergency splinting for compound fractures of lower third of tibia and fibula.

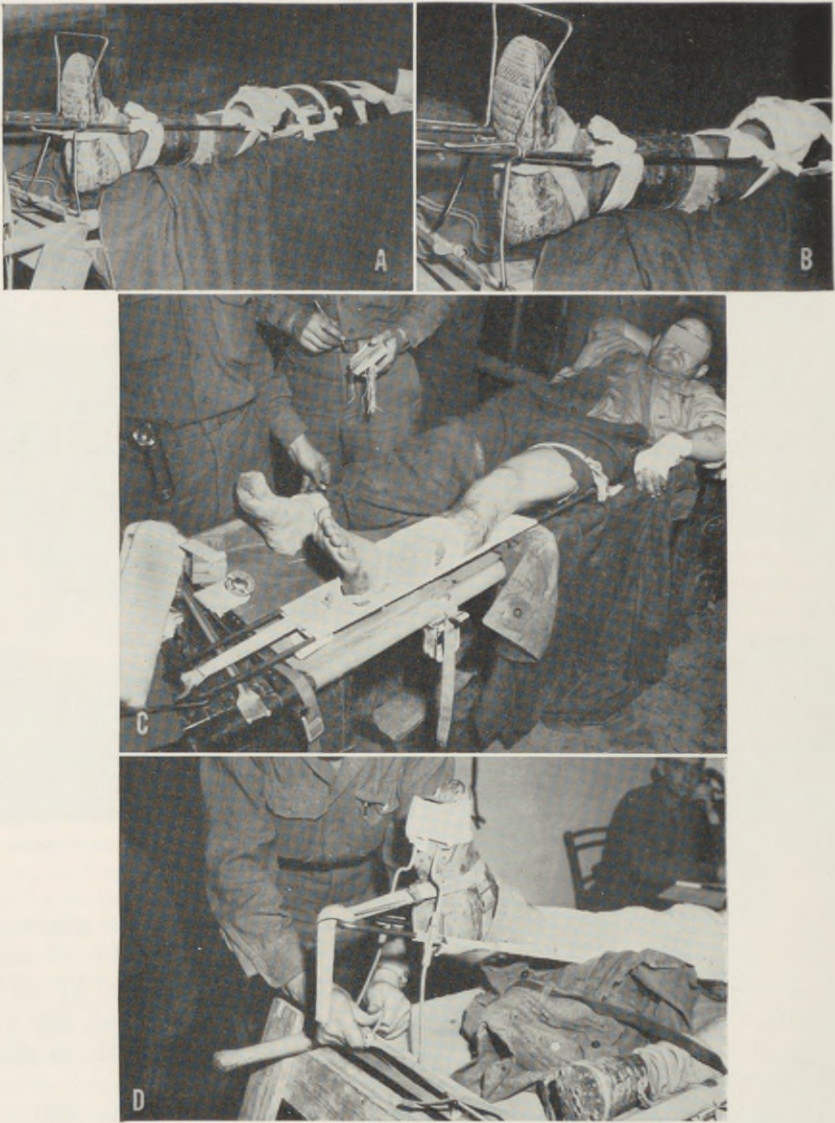
AFIP FC-44-4, C-44-652, Fd-44-10

support, this one being turned downward. Late in the war, a single gadget slipped over the end of the splint took the place of both supports. A standard webbing strap was placed about the heel and ankle and fastened to the end of the splint, thus providing moderate fixed traction. The strap was applied with the shoe on, but the shoelaces were then loosened or cut, to allow for possible swelling of the ankle and foot.

A casualty was not comfortable during evacuation in the half-ring leg splint unless the distal end of the splint was elevated and made secure. This was accomplished by fixing the lower half of the foot support used to maintain elevation of the distal end of the splint in the bar by which the splint was attached to the stretcher. The bar was standard equipment.

A number of other precautions were necessary when the half-ring leg splint was used:

1. Deflexion or unfolding of the hinged half ring, with sagging of the upper end of the splint, was likely to result in a painful drag on the thigh. This could be almost entirely prevented if care was taken to see that the half ring was folded completely into the 90° position when the splint was applied.



AFIP Ca-45-736, Ca-45-738, Fd-45-55

FIGURE 14.—Emergency splinting with Army half-ring leg splint for injuries of thigh, knee joint, and leg. A and B. Fixation of splint by litter bar. This accessory proved a valuable adjunct for comfortable emergency splinting. C. Application of Army half-ring splint with traction, at collecting station, for compound fracture of middle third of tibia. Basswood coaptation splints had been used for emergency splinting. D. Substitution, in a clearing station, of standard splinting (traction in an Army half-ring leg splint) for the improvised splinting shown in figure 10.

2. If the injury was near the hip or the knee, the splint was bent 15° to 20° at the knee before it was applied, so that those joints would be put up in some degree of flexion.

3. In fractures of the lower third of the femur, the popliteal vessels had to be protected against injury from the sharp bony fragment likely to project posteriorly. The risk of injury to the popliteal artery was decreased if the extremity was put up in slight flexion at the knee instead of in complete extension.

4. Pressure necrosis, which was a possibility underneath the strap crossing the foot, was guarded against by avoiding strong traction. Strong traction, as a matter of fact, was not required, since the objective was merely to immobilize the fracture, not reduce it. The results were therefore accomplished by moderate or even minimal traction. It was necessary to inspect the strap at each halt in the line of evacuation, to be sure that pressure had not become excessive.

TRANSPORTATION SPLINTING

The routine use of plaster of paris for transportation splinting in the evacuation hospitals of the combat zone in World War II was a major advance over the methods of splinting used in World War I, when for all practical purposes only the splints and appliances described in the manual issued in 1917 (p. 31) were provided in forward areas and plaster was seldom used.³

Medical planning for World War II contemplated the use of plaster in the forward zone, partly because United States surgeons were fully trained in plaster techniques and partly because these methods had been used with satisfaction in forward installations during the Spanish Civil War as well as in Allied forward hospitals before the entry of the United States into the war. Standard United States Army Medical Department equipment for hospitals in the combat zone therefore included ample supplies of plaster of paris and sheet wadding, in addition to standard splints. Portable fracture tables became available after the Tunisian campaign in 1942-43. Up to that time, some hospitals were supplied with Meyerding sacral rests. Those which did not have them made use of wooden blocks, tin cans, and other improvised substitutes, which were more or less satisfactory. The chief objection to these improvisations was that they were wasteful of personnel. At least one person was required to hold each lower extremity while a hip spica, for instance, was being applied.

³ It should be remembered that the First U. S. Army functioned in World War I for only about 11 weeks, from 2 September to 11 November 1918. The number of casualties during this period was large but amounted to only a small fraction of those sustained in the European theater or Mediterranean theater during World War II. There was no consultant system in World War I, except on paper, until hostilities were almost concluded. Those of us who served in World War I, I have found, cannot recall seeing any circulars or directions concerning the proper splinting for evacuation of wounded. The Army ring splint was used to evacuate patients from field hospitals to evacuation hospitals, and, in many instances, it was doubtless reapplied before they were sent to the rear from evacuation hospitals. Plaster-of-paris plints, however, were also used. I recall applying them myself, and I have checked with a fellow medical officer who served in a nearby evacuation hospital and who spent his entire time applying plaster-of-paris splints to immobilize fractures for evacuation. [Editor's note.]

General Considerations

The objective of transportation splinting in a forward hospital was to maintain gross normal alinement of the injured extremity, to immobilize the adjacent joints in the position of function, and to accomplish these purposes without causing nerve or circulatory damage or causing pain by pressure on bony prominences.

Some of the techniques used in the hospitals of the combat zone early in the North African experience proved completely unsatisfactory and dangerous as well. Among them were skintight, unpadded plaster casts and skeletal fixation with incorporation of transfixion pins or wires in the cast (p. 55).

The ideal transportation splint proved to be a well-padded plaster-of-paris cast which held the fracture in grossly normal alinement and which immobilized the joints above and below the injury in the position of function. Once the lesson was learned, no exceptions were permitted to the rule that all circular plaster casts applied to the extremities must be split or bivalved in the operating tent of the forward hospital before the patient was taken off the operating table. There were two reasons why it was not safe to postpone this procedure: (1) There were no ward officers in the usual sense of the term in forward hospitals, and the splitting or bivalving of the cast was therefore the responsibility of the surgeon, who could not count on time to leave the operating room to split casts on the ward; and (2) theoretically, provision had to be made for a tactical situation which might demand immediate evacuation and allow no time for such details as splitting casts.

Plaster casts for transportation purposes were made relatively thick and heavy, to prevent breakage after they had been split or bivalved. Muslin bandages were wound around them snugly after they had been split, to protect their integrity and increase their stability.

After the cast had been applied, a diagram was drawn on it showing the location and general contour of the fracture (fractures), the location of the wounds of entry and exit, and the extent of the skin loss. Those who cared for the casualty in the course of his evacuation, as well as those who received him in the general hospital, thus had a readily available source of information concerning his injuries.

The application of good transportation splinting often required the help of several persons. A single assistant could not possibly support a lower extremity in which both the tibia and fibula were fractured so that the fragments were kept in satisfactory alinement, while at the same time the foot was kept in 90° dorsiflexion, in neutral version, and the knee in mild flexion. An attempt to put the lower extremity in plaster with aid from a single assistant who grasped the toes and provided both elevation and traction almost invariably resulted in immobilization with posterior bowing, with the foot in plantar flexion and inversion and the knee in complete extension. This is as pernicious a position as can be imagined for immobilizing an extremity with a fracture of the tibia and fibula. Properly, the plaster was applied for such an injury

while one assistant supported the fracture and another held the foot in correct position.

Improvised methods (fig. 15) were designed to reduce the number of helpers necessary after initial wound surgery, personnel shortages always being a problem. Thus the use of a narrow, removable support of flexible metal under the knee while the cast was applied to the lower extremity kept the joint in slight flexion and made it possible for a single assistant to support the fractures of the lower leg in reasonably good alignment and at the same time hold the foot in the position of function (fig. 15A).

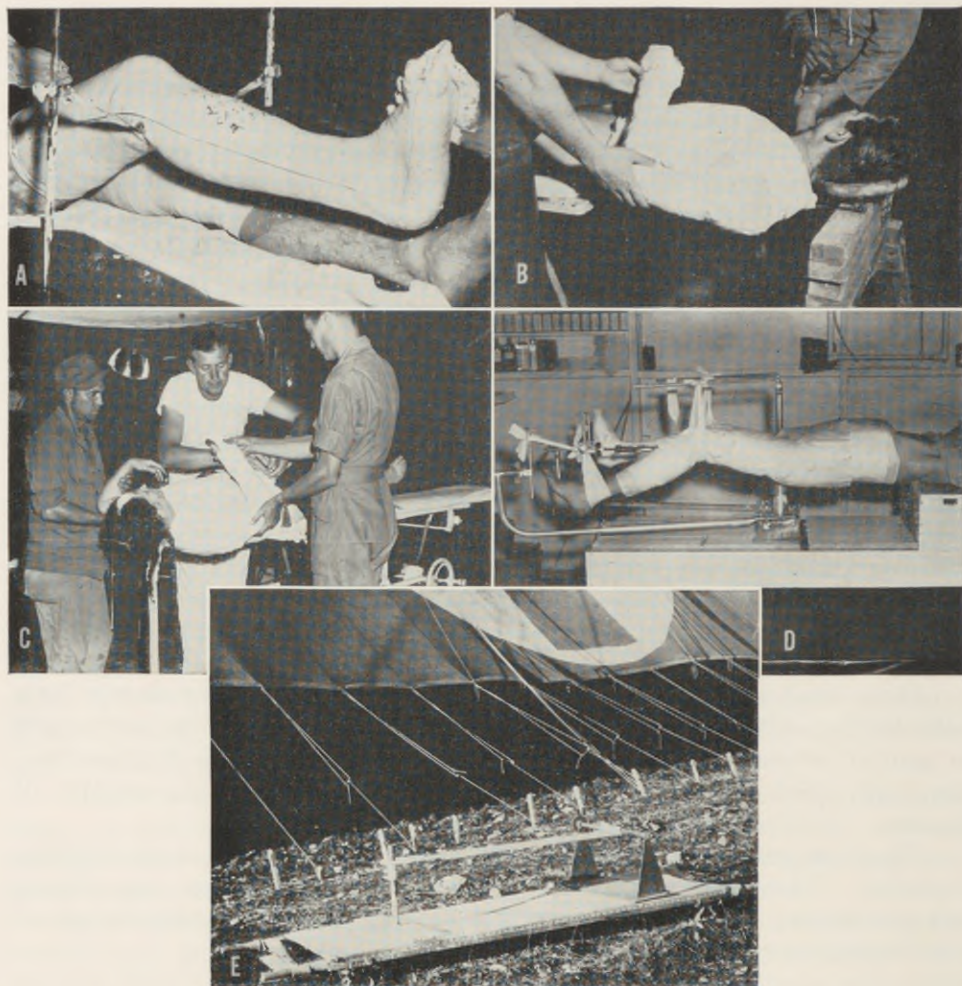
A plaster Velpeau or shoulder spica was extremely useful in transportation splinting for injuries of the upper arm and shoulder but was difficult to apply because of lack of standard equipment. The hinged full-ring arm splint, although unsatisfactory for the purposes for which it was intended (p. 34), was very useful in the application of plaster about the shoulder (fig. 15B). The end of the splint was placed on the operating table and the ring on some convenient available support, such as a sawhorse. The patient's head rested comfortably in the ring during the application of the cast. The splint was easily pulled out from beneath the cast after the plaster had hardened. A long, narrow board or a narrow strip of strong metal could also be used in this fashion (fig. 15C), but it was less convenient for the surgeon and considerably less comfortable for the patient.

If the hand was suspended from a stand used for intravenous therapy by a roller bandage tied about the thumb and fingers, long arm plaster casts could be applied for fractures of both bones of the forearm with the fragments in reasonably good position and the wrist and elbow joints in the position of function.

These are merely examples of some of the shortcuts and improvisations employed. They were highly advantageous when casualties were heavy, demands urgent, and surgical personnel in short supply. Numerous others were devised as special necessities developed.

Regional Splinting

Arm and shoulder joint.—For several years before the war, the hanging plaster cast had been popular in the United States for fractures of the humerus and injuries about the shoulder joint. It was therefore natural that it should have been rather widely used in the early stages of the North African campaign. It soon became evident, however, that while this cast might be satisfactory in civilian practice, it was not an adequate transportation splint in military circumstances. Reports from general hospitals which received casualties put up in hanging casts were always to this effect. Most patients with fractures of the humerus were necessarily transported recumbent after initial wound surgery, with the result that the traction produced by the weight of the cast in the hanging position was lost and little immobilization was maintained during transportation. Ambulance rides over rough terrain helped to increase the



AFIP C-44-652, FD-44-9, C-45-759, C-44-542, CA-44-137

FIGURE 15.—Improvisations designed to save time and economize on personnel in application of splinting in evacuation hospital after initial wound surgery. A. Application of plaster cast of lower extremity in evacuation hospital. Note narrow removable support of flexible metal which is readily improvised and is exceedingly valuable in the proper application of the cast. Note also data on cast. B. Use of hinged full-ring splint to facilitate application of plaster Velpeau or shoulder spica. C. Application of plaster Velpeau or shoulder spica is facilitated with patient lying on narrow metal strip, one end of which rests on the operating table and the other on an improvised headstand. D. Application of hip spica. The patient rests on a portable fracture table placed on top of a wooden table improvised in a fixed hospital. The same type of portable fracture table is placed on a standard folding operating table for the application of hip spica casts in forward hospitals. E. Improvised canvas sling, stretched between crossbars fixed to a litter, for application of body cast or plaster Velpeau.

loss of immobilization and added to the patient's discomfort. Because of universally adverse criticism, the hanging cast was seldom used after the first months of 1943.

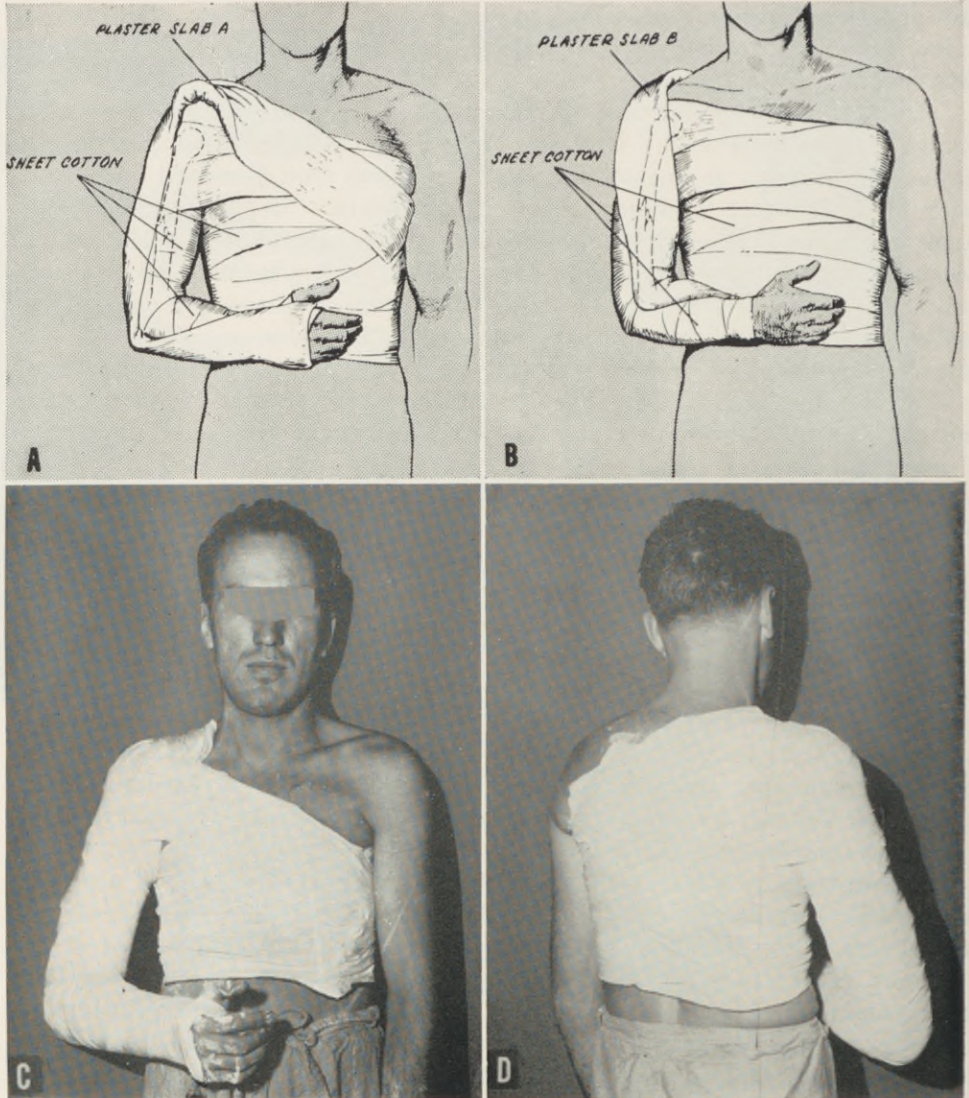
In the early North African experience, fractures of the humerus were also immobilized by the so-called U-plaster cast, which the British had used widely in the Middle East. It was not satisfactory and was soon discarded. Another, later method, which also never achieved popularity among United States Army medical officers, was the so-called elephant-tusk splint (fig. 16), which was introduced during the Italian campaign. Because it could be removed and replaced, it was theoretically useful (1) in injuries of the arm or shoulder associated with chest injuries which required thoracentesis and (2) in vascular injuries which required repeated inspection of the entire arm and forearm.

The plaster Velpeau and the shoulder spica both proved excellent transportation casts, and one or the other was always used after the fighting for Cassino and Anzio began in the winter of 1944. Both maintained the arm at or near the side and the elbow at 90°. This position permitted transportation with minimum discomfort.

The plaster Velpeau (fig. 17) was, for a number of reasons, the better of the two techniques: It provided maximum comfort. It was easy to apply and remove. It fitted within the bars of the litter, which was an important consideration in comfortable transportation. If thoracentesis was necessary for an associated chest injury, access to the chest could be provided by windows cut into the cast. If radial-nerve paralysis was present, excellent temporary support could be provided for the thumb and the proximal phalanges of the fingers by extending the plaster sufficiently to hold them in extension. When the plaster Velpeau was applied correctly, it was not necessary to split it, since it did not completely enclose the arm.

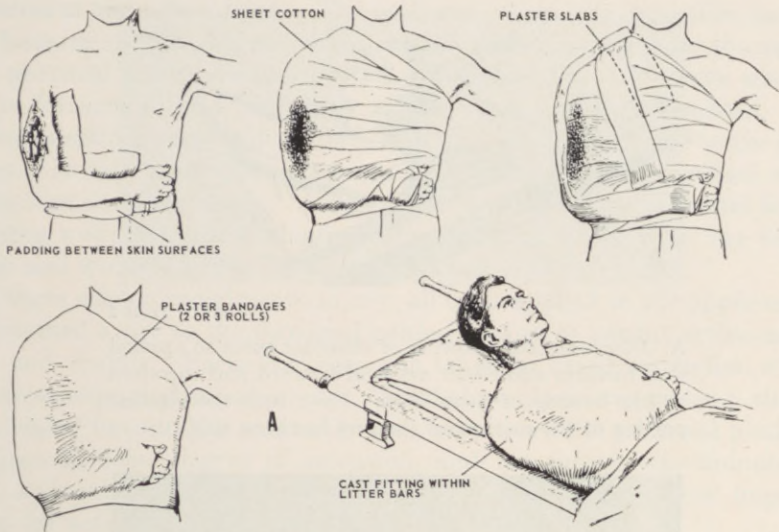
There were, it is true, some theoretical objections to the use of a plaster Velpeau for transportation splinting. The chief was that the adducted position of the arm at the side was unsuitable for fractures of the upper third of the humerus. This was not a sound argument, for two reasons. The first was that a surgeon in a forward hospital was not concerned with the definitive reduction of fractures. The second was that the comfort provided by the cast predisposed to muscular relaxation, so that it was the exception, at the general hospital, not to find the upper humeral fragment adducted and in reasonably good alignment with the distal fragment.

The shoulder spica (fig. 18) provided just as comfortable transportation as the plaster Velpeau in injuries of the arm and shoulder, but it had a number of disadvantages in a forward hospital: The spica had to be applied with special precautions, preferably with the arm in the position of internal rotation at the shoulder and with the elbow and arm held anteriorly rather than laterally. Otherwise, the cast would not fit within the bars of the litter or cot, and the elbow would project and might be traumatized during transportation. Finally, the spica required more personnel for its application, and the use of more plaster, than the Velpeau.



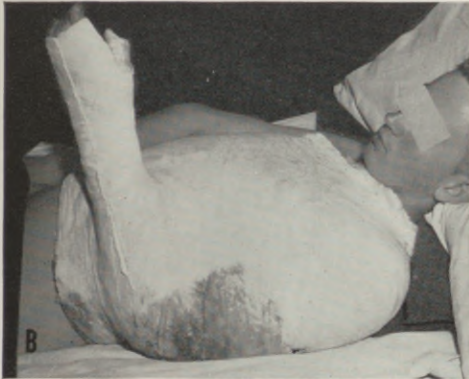AFIP FC-44-9

FIGURE 16.—Modification of elephant-tusk splint for fractures about shoulder joint and elbow. This splint has only a limited field of usefulness, but every military surgeon should be familiar with it. The shoulder and elbow are points of stress, and the cast most often breaks at these points. A and B. Technique of application of elephant-tusk splint. C and D. Anterior and posterior views of completed splint.



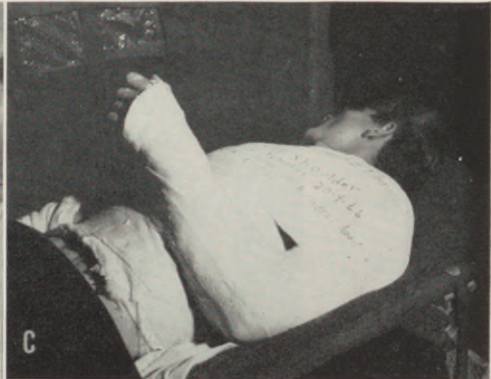AFIP FC-44-6

A. Diagrammatic showing of steps of application of plaster Velpeau. For several reasons, this cast provides excellent transportation splinting for fractures of the humerus. It can be constructed from only 2 plaster slabs and 2 or 3 rolls of plaster bandage. There are no points of stress, so breakage need not be feared. The entire hand, if desired, can be left free.



AFIP CA-44-612

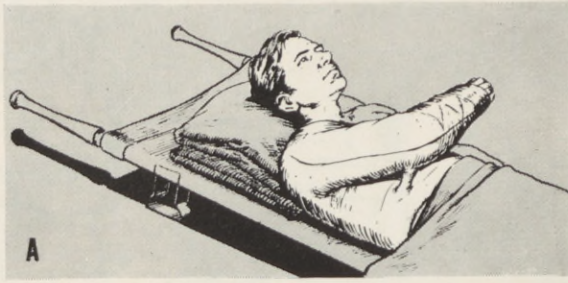B. Plaster Velpeau used as transportation splinting for compound fracture of lower third of humerus. The hand in this case projects farther forward than usual.



AFIP FD-44-924


C. Plaster Velpeau applied in evacuation hospital after initial surgery for compound fracture in region of shoulder. Note data on cast.

FIGURE 17.—Plaster Velpeau bandage for injuries of shoulder joint, arm, or elbow.



AFIP Fe-45-2

A. Diagrammatic showing of shoulder spica so applied that forearm and elbow are held forward and therefore within bounds of litter bars. Note that the circular portion of the cast about the arm has been split.



AFIP C-44-480

B. Shoulder spica applied in evacuation hospital, following initial surgery for compound fracture of humerus with injury to radial nerve. Note support temporarily provided for thumb and proximal phalanges of fingers. Note also data on cast.

FIGURE 18.—Application of shoulder spica for injuries about shoulder joint and of arm.

Forearm and elbow joint.—The preferred transportation splint for wounds of the forearm and elbow joint was a plaster cast extending from the upper arm to the proximal palmar crease. It was so applied that the elbow was held at 90°, the forearm in mid pronation, and the wrist in slight cockup. A sling provided additional immobilization and at the same time added to the patient's comfort. It was particularly important that the sling be supplied when the casualty had no other injury. Under these circumstances, he would be treated as walking wounded, and without a sling the hand would be in the dependent position and would rapidly become edematous.

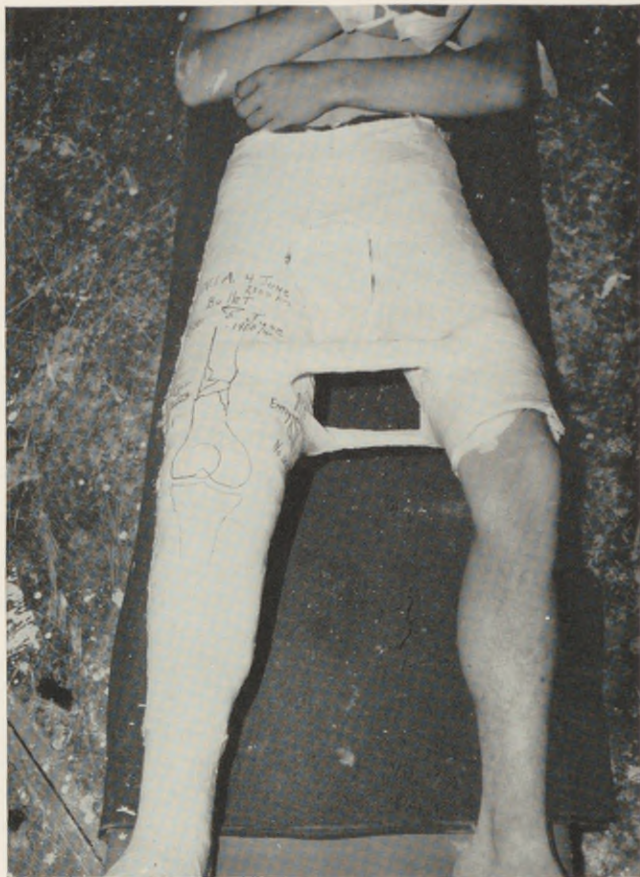If there was no radial-nerve injury, all casts applied to the upper extremity were trimmed away to the proximal palmar crease, to permit active use of the fingers and thumb. Particular care was taken to avoid restriction of motion in the metacarpophalangeal joints. If radial paralysis was present, the plaster was extended beyond the palmar crease, to support the proximal phalanges of the fingers in some degree of extension, and the thumb was immobilized in partial abduction and extension. The distal phalanges of the fingers were left free for active motion.

Thigh and hip.—Although the hinged half-ring traction splint was standard United States Army equipment, it was seldom used in transportation splinting, even during the early stages of the North African campaign.

During both phases of the Tunisian campaign, United States Army medical officers had ample opportunity to observe the British use of the Tobruk splint. This splint, so named because it first came into use during the evacuation of Tobruk, was practically always used by the British for transportation splinting of fractures of the femur, and its use was recommended in the preparatory United States Medical Department directives⁴ for the invasion of Sicily. United States Army surgeons who served in Sicily never liked the Tobruk splint for fractures of the femur. They found it difficult and time consuming to apply and did not regard the immobilization provided as satisfactory. For these reasons, the Tobruk splint was not generally accepted in the Mediterranean theater during the remainder of World War II, even after its application had been greatly simplified and it had proved highly effective for transportation splinting in injuries of the knee (p. 49) and the lower third of the femur.

In spite of the unpopularity of the Tobruk splint, every United States Army military surgeon should have been familiar with it. It was far more desirable than the hip spica when injuries of the large bowel for which colostomy had been performed were associated with fractures of the femur. It was particularly useful for fractures of the lower third of the femur and wounds of the knee joint. It was also useful when either plaster or water was in short supply or when speed of application was important.

⁴ (1) Circular Letter No. 13, Office of the Surgeon, North African Theater of Operations, 15 May 1943, subject: Memoranda on Forward Surgery. (2) Circular Letter No. 16, Office of the Surgeon, North African Theater of Operations, 9 June 1943, subject: Memoranda on Forward Surgery Especially Applicable to Amphibious Operations. (See appendix, pp. 299-303 and 304-307, respectively.)



AFIP C-44-338

FIGURE 19.—Hip spica applied in evacuation hospital for transportation splinting of compound fracture of femur. The cast has been split along the outer side. Note that knee spread is held to a minimum, so that the cast fits within the bars of the litter. Note also the data on the cast, including the highly informative diagram of the injury.

Early in the North African campaign, the single hip spica was widely used for fractures of the femur and fractures about the hip joint. Later, the double spica (fig. 19) came into general use. It was really a spica and a half, since the cast on the uninjured side was carried only to the knee. On the injured side, the cast extended from the foot to the costal margin. A plaster slab extended beyond the toes. The plaster was molded about the pelvis and was trimmed low in front, to permit the injured man to sit semierect during travel. Knee spread was held to a minimum, so that the cast would fit between the bars of the litter or cot on which the casualty was transported. Such a spica cast emerged as the recommended transportation splinting for fractures of the femur.

Certain precautions were necessary in the application of the spica. In fractures of the upper third of the femur, the hip and knee were both flexed at 35° to 40° . In fractures of the lower third, in order to guard against pressure in the popliteal space by rotation of the lower femoral fragment, the knee was flexed at 30° to 35° , which required a compensating degree of flexion of the hip. Care was taken to insure that the heel and buttock were held in the same horizontal plane when the cast was applied. Otherwise, the upper rim of the cast could produce uncomfortable pressure against the back or the abdomen when the patient was recumbent in bed or on a cot and the heel and buttock necessarily assumed the same plane.

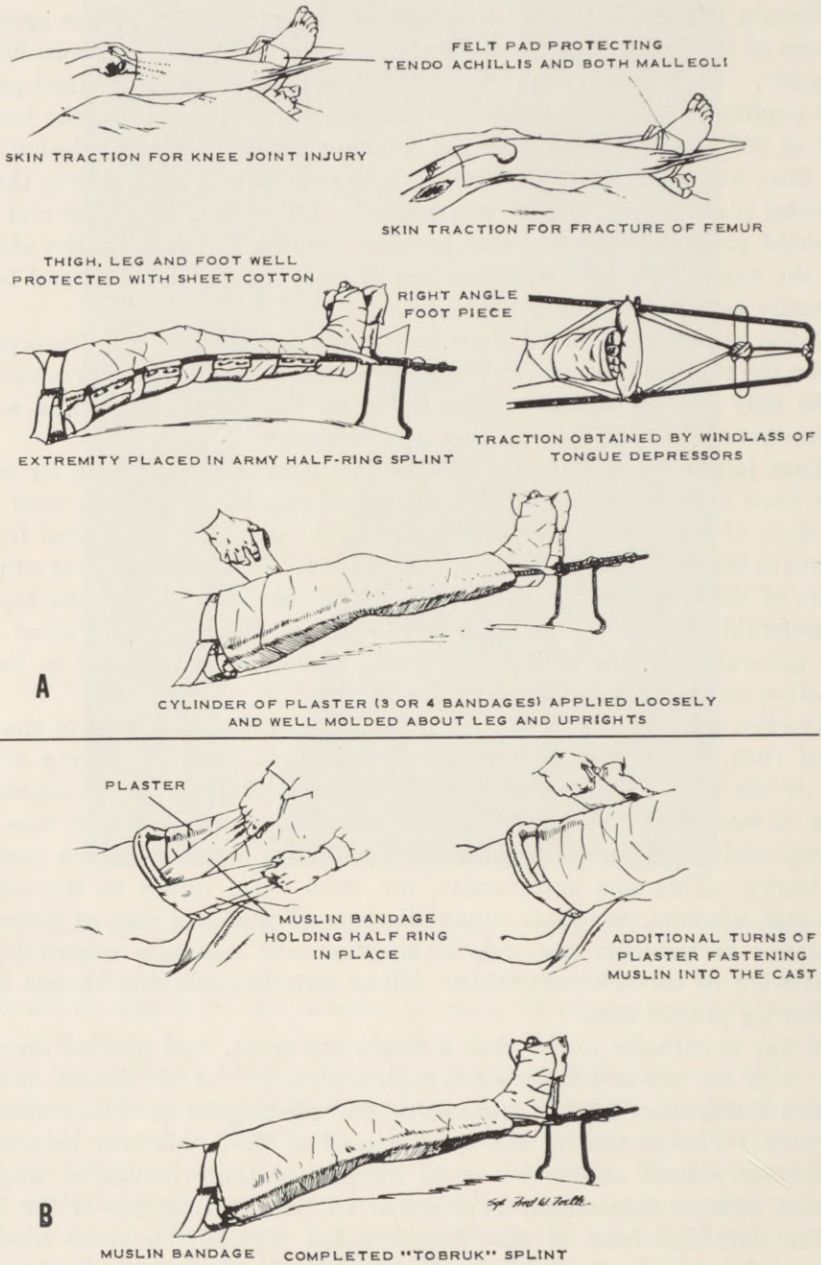
If the spica was bivalved from toes to hip, cross sticks were incorporated between the thighs both anteriorly and posteriorly. As a rule, it was necessary to split only the leg section of the spica, on the outer aspect, and a single anterior cross stick was then all that was necessary.

Knee joint.—Satisfactory methods of transportation splinting for wounds of the knee joint were slow in developing. Long leg casts were used in the early days of the North African invasion and continued to be used by most surgeons in forward areas until the spring of 1944. This technique was employed in spite of the early British experience, which had showed that the hip spica was preferable for such injuries, and in spite of reports from United States Army general hospitals to the effect that casualties transported in long leg casts often suffered a great deal of pain.

The hip spica began to be used for injuries of the knee joint in the latter part of 1943, but it was employed only sparingly until the spring of 1944. Then its use was recommended officially, as part of the effort to improve the results in wounds of the knee joint. The long leg cast, however, was easier to apply and it continued to be used frequently, especially when casualties were heavy. This was unfortunate, for, even when injury to the adjacent bones was minimal, adequate immobilization of the knee was of paramount importance in reducing the risk of infection. It was also essential if the patient were to travel comfortably. These criteria could not be met by use of a long leg plaster cast.

It was eventually found that a single hip spica, well molded about the pelvis, with the hip and knee joints each held in 15° to 20° flexion, provided the most satisfactory kind of transportation splinting for an injury about the knee joint. The portion of the spica encircling the trunk was kept narrow and did not extend above the costal margin, so that the soldier might sit semierect without discomfort, as in spicas applied for fractures of the femur.

The simplified form of the Tobruk splint (fig. 20) could be used as a substitute for the plaster hip spica for wounds about the knee joint, and its ease of application often made it a desirable substitute. Because it had proved so unsatisfactory in its original form for fractures of the femur, it never became widely popular for this purpose in Fifth U. S. Army hospitals. The simplified form of the Tobruk splint was, however, recommended for



AFIP FC-44-1

FIGURE 20.—Application of modified Tobruk splint. A. Application of adhesive tape for traction; sheet cotton and plaster. B. Stabilization of half ring by loop of muslin bandage incorporated in plaster.

wounds of the knee joint by the consultant in surgery, Seventh U. S. Army, just before the invasion of southern France.

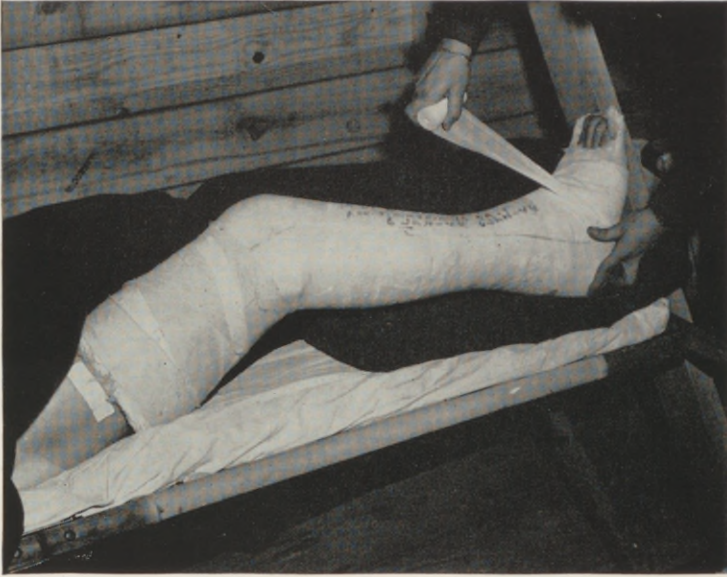In the original Tobruk splint, traction was provided by strips of adhesive plaster passed down each side of the thigh and leg. A long leg plaster cast, which included the foot, was applied over these strips, which emerged from the cast just above the malleoli. The injured extremity in the plaster cast was then placed in a Thomas splint and the traction strips were tied to the end of the splint. Traction was provided by means of a windlass. Additional turns of plaster were passed around the leg and the bars of the splint.

In the simplified Tobruk splint (fig. 20), the traction strips of adhesive were placed down each side of the extremity, as in the original technique, and the limb, heavily covered with sheet cotton, was placed in an Army half-ring splint. The traction strips were then passed around the footrest, which supported the foot at about 90° , and were tied to the end of the splint. Tongue depressors passed between the traction strips just proximal to the distal end of the splint served as windlasses to provide some traction. Several turns of plaster were next applied loosely about the limb and the splint, from just above the malleoli to the groin. They were molded about the uprights and along the posterior and anterior surfaces of the thigh and leg. The distal end of the splint was elevated by means of a second foot support, which was turned downward. A figure-of-eight plaster bandage bound the foot to the foot support. This precaution, which prevented rotation of the leg, increased the patient's comfort.

The full-ring Thomas splint would have been more satisfactory to use with the Tobruk splint than the half-ring splint, but the latter had been standardized equipment since the beginning of World War II, and the full-ring splint was not available in evacuation hospitals. Deflection of the half ring at any time after it was applied caused the upper end of the plaster to press against the thigh and produced considerable discomfort. This could be avoided by fixed traction on loops of a bandage passed through the half ring. The ends of the loops of bandage were incorporated in the plaster about the thigh and the half ring was thus stabilized in the correct position.

Surgeons of the forward hospitals of the Fifth and Seventh U.S. Armies who used the Tobruk splint by the modified technique just described were almost unanimous in stating that it can be applied more quickly and more easily than a hip spica.

Leg, ankle joint, and foot.—Fractures of bones of the leg, ankle joint, and foot were put up in molded plaster casts (fig. 21). If only the bones of the foot were broken, the cast was stopped at the knee. For injuries about the ankle and for fractures of the tibia, fibula, or both bones, it was carried to just below the groin. The foot was held at 90° , in neutral version, with the arches well molded. A plantar slab extended beyond the toes, to protect them from the pressure of blankets and from other trauma during transit. Hyperextension of



AFIP C-44-663

FIGURE 21.—Transportation splinting in fractures of lower extremities. Long leg cast applied in evacuation hospital, following initial surgery. The cast has been split down the outer side, and a muslin bandage is being applied about it to maintain its integrity. Note the excellent position of the knee and ankle joints, the plaster support for the protection of the toes, and the data inscribed on the cast.

the toes was avoided. The knee was immobilized in about 15° flexion. Failure to provide this small degree of flexion increased the difficulty of obtaining fixation of the foot at the proper angle, since complete extension of the knee increased the tension on the gastrocnemius muscle.

CHAPTER IV

The Management of Compound Battle Fractures

Part I. The Evolution of the Program of Staged Management

CONCEPTS AND PRACTICES BEFORE WORLD WAR II

Orthopedic practices in general use at the end of World War I called for the management of most compound battle fractures in splints or appliances based on the general principles of splinting. Skin traction was used for continuous traction. Only occasional fractures were put up in skeletal traction, and plaster was not generally used because freedom of joint movement was considered desirable.

In the management of compound fractures, great emphasis was placed upon the sterilization of the wound. Infection was combated by local applications of such agents as BIP (bismuth subnitrate, iodoform, and paraffin) or by the elaborate irrigation ritual of the Carrel-Dakin method. Evaluation of the results accomplished during the last months of the war, when these methods had become fairly well stabilized, showed a high incidence of infection, which was likely to run a prolonged course; a high incidence of malunion and non-union; and rates for amputations and for fatalities which exceeded reasonable expectancies.

After the war, the Carrel-Dakin method continued to be used in the management of civilian compound fractures and joint injuries, at first enthusiastically, then with increasing dissatisfaction. It was tedious and troublesome to apply, and the end results left much to be desired. Gradually, for these reasons, it fell into disuse. Meantime, a method usually credited to H. Winnett Orr was increasing in popularity. This method had been devised to meet the dual problems of an infected wound and a fractured bone. The wound was left open, to secure drainage, and the fracture was managed by skeletal fixation in a plaster cast. One objective of the method was the prevention of the trauma and reinfection which experience had shown was likely to occur with frequent dressings.

The first wartime test of the closed plaster technique (which, incidentally, was a revival of the "occlusive" method described by Ollier in 1872) came during the Spanish Civil War, when it was employed by Trueta¹ and others with

¹ Trueta, J.: Treatment of War Wounds and Fractures With Special Reference to the Closed Method as Used in the War in Spain. New York: Paul B. Hoeber, Inc.

a number of modifications. It was eventually used in some 20,000 cases. In 1,073 open fractures personally treated by Trueta, the reported results were excellent. There were only 6 deaths, and only 2 of these, both after operations for gangrene, were directly related to the compound fractures. Results were classified as poor in 91 other cases, in 4 of which amputation was necessary. As these results became generally known, the closed plaster method became increasingly popular, and, when World War II broke out in 1939, it was natural that it should be employed in the Allied armies, as well as in the German and the Russian Armies.

The steps of the closed plaster technique were described by Trueta as follows:

2. Once the patient is anesthetized, thoroughly wash the entire extremity and the wound with water, soap and a nail brush, until the whole is completely clean and the wound itself is bleeding; shave all hair. Paint the surrounding skin with a weak alcoholic solution of iodine, without touching the wound in any circumstances.

3. Excise the skin edges of the wound, remove all contused tissue and widen the wound as much as may be required. Excise carefully and unhesitatingly all nonviable muscular and cellular tissues, noting in particular the colour of the injured muscles, their contractility on stimulation with forceps, and their capacity to bleed.

4. Open up the neighbouring cellular spaces affected by the contusion and, where necessary, incise the soft tissues, following up the cellular spaces in the depths of the wound, always keeping in mind the need for adequate drainage. Remove any haematoma present.

5. Remove the majority of bone fragments that are completely denuded of periosteum or displaced, and all foreign bodies found at the site of fracture. There is no need to be concerned much about any pieces of bullet that are difficult to locate; but it is most important to excise carefully all foreign organic matter (pieces of clothing, wood, etc.). The procedures described above—namely, the removal of all foreign matter, the excision of all the tissues immediately surrounding the wound, including devitalized soft parts in the vicinity, and the opening up of cellular spaces—is known technically as debridement.

6. If the thigh, knee joint or leg is fractured, reduce the fracture by traction on an orthopaedic table or by hand. In arm fractures which require traction or abduction, apply the appropriate apparatus. Details may be found in the chapters dealing with wound of the different regions.

7. Once the fracture is reduced firmly dress the wound with sterile gauze and immediately immobilize with plaster, including the two adjoining joints if possible.

8. Give an injection of tetanus antitoxin.

Drainage and Suture

In cases in which deep cavities are present drainage must be arranged by opening up the aponeurotic planes and the intermuscular spaces; this drainage can generally be maintained by the insertion of sterile gauze, but in some cases no inconvenience results from the insertion of a rubber tube which may be buried under the plaster and retained until the first change of the cast. No complication of any kind can be attributed to drainage; on the other hand, retained discharge, the result of bad drainage, may bring about disaster.

The immediate reaction to this method of treatment was sometimes severe. The temperature might rise to 104° F., and the axillary or inguinal lymph nodes might become enlarged. These phenomena were not regarded by Trueta as indications, in themselves, for the premature removal of the cast or for cutting windows into it. The only indication for removal of the plaster

ahead of the time determined upon—from 10 days to a month after operation, depending upon circumstances—was the appearance of such symptoms and signs as edema of the distal portion of the extremity; inability to move the toes or fingers; and evidences of progressive infection, including lassitude, a progressive increase in the intensity of the pain, and a rising pulse rate. As a rule, the cast was kept in place without change for 10 to 15 days in summer and for a month in winter. The seasonal distinction was explained by the fact that the strong odor which emanated from the wound in this method of treatment was not well tolerated during the summer by the patient's associates in the ward.

UNITED STATES EXPERIENCES WITH THE CLOSED PLASTER METHOD

Since United States experiences with the closed plaster method had been reasonably good in civilian practice and since British and other European surgeons had apparently had good results with it in the first months of World War II, it was natural that United States Army medical officers should be prepared to use it in the North African invasion. The circumstances early in the invasion were not conducive to a coordinated plan of timed surgery such as was developed later. Evacuation hospitals were widely separated, and often the medical officers in them had no knowledge of what hospitals were behind them. The situation, in short, was an invitation to the one-stage management of compound fractures which was offered by the closed plaster method.

In the early experience in North Africa, the general plan of management, although it was not really official, was as follows: After debridement in a forward hospital, the wound was dressed with vaseline gauze; the fracture was reduced; and a plaster cast was applied, in which skeletal transfixion pins were sometimes incorporated. The patient was then transferred to a general hospital where, in the absence of specific indications to the contrary, the cast was left in place for 4 to 6 weeks. At the end of this time, it was assumed, wound healing would be progressing satisfactorily by granulation, and the fracture would also be well on its way toward healing.

In theory, this was not an unsound policy. In practice, it proved unworkable, and the results were poor. Patients were frequently febrile when they were received in general hospitals; often the temperature was very high. If the casts had been split or bivalved, as theater regulations required (p. 40), the plaster was often disintegrating and ineffective. If the casts had not been split, the circulation was sometimes threatened. Transfixion pins were often broken, and infection about them was frequent. Even when the fracture had been adequately reduced in the forward hospital, position was likely to be lost in transit over long distances and rough roads, and a second reduction was necessary at the general hospital. Finally, when the casts were left in situ the theoretical length of time, blister formation, excoriations of the skin, and pressure sores were frequently present when they were removed.

Because of the poor condition in which so many casualties were received in general hospitals, it was found inadvisable to allow the casts to remain in place for the specified length of time, and they were usually changed at once. Inspection was likely to reveal two reasons for the infection: (1) Devitalized tissue had not been completely excised, and (2) the wound was actually plugged by the pack of vaseline-impregnated gauze. Displacement of fractures was frequent, but, if only a week or two had elapsed since wounding, the displacement could usually be corrected by manipulation or skeletal traction. If 2 weeks or more had elapsed, in many cases this was not possible, and faulty reduction had to be accepted.

Even in the relatively small number of cases in which conditions appeared to be favorable when the casualties were received at the general hospital, surface impressions were not always correct. When the cast was finally removed, at the end of several weeks, unsuspected infectious processes were often revealed. In many cases, purulent exudate had been dammed back by the dressings which plugged the wound, and the infection had been buried beneath the closed plaster. Moreover, reduction of the fracture was often lost as the cast became loose as a result of atrophy of the musculature as well as decreased swelling.

These observations in the first months of the North African invasion made it clear that a strict application of the closed plaster regimen was not practical in the circumstances which then prevailed. Initial surgery was often inadequate, perhaps because it was, of necessity, performed by surgeons without previous experience in military surgery.

By the early spring of 1943, the closed plaster method had been modified to meet these circumstances. All casts applied after initial surgery in the forward area were removed at the fixed hospital not later than the 15th day after wounding. The surgeon who assumed charge of the patient thus had an opportunity to inspect and appraise the wound when the dressings were removed and before it was re-dressed. It was also possible to manipulate the fracture, institute traction, or carry out whatever other measures of fracture management the particular case required. Finally, the wound was covered with an occlusive dressing, and, if traction had not been instituted, a fresh plaster cast was applied.

The 15th day after wounding was arbitrarily set as the upper time limit for these manipulations. It is true that some fractures were reducible after longer time lapses but most of them were not, and additional postponement of attempts at correction would have introduced the risk of serious trauma to the soft parts, which in turn was conducive to infection.

At this period in the war, the attention of surgeons in general hospitals was chiefly concentrated on the reduction of fractures. It was believed that an open wound was necessary to permit prolonged drainage and that interference with the wound would reactivate infection. Secondary surgery, when

the cast was removed, was therefore limited to the unroofing of areas of dead tissue and the excision of presenting and protruding tags of similar tissue. The depths of the wound were seldom investigated. Slow healing of the wound by granulation, with resultant scar formation, was accepted as the best that could be expected in the circumstances.

As the months passed and experience increased, concepts of wound management and fracture management began to alter. It began to be realized, as later experience amply proved, that, if devitalized tissue was not completely excised at the first surgical attack on the injury, infection was a likely outcome. If large hematomas remained in undrained dead space, they were likely to undergo purulent decomposition. If dead tissue were allowed to remain in the wound, neither systemic nor local chemotherapy nor a combination of these methods could prevent wound infection. Once wound infection had developed, local necrosis of living tissue would follow, and a vicious circle was likely to be established.

Several clinical observations of considerable importance, as follows, were made during this period of the war:

1. Although the sulfonamides had no ability to prevent local infection, invasive infection was extremely infrequent when they were used, and infected wounds seldom manifested the cardinal signs of inflammation.

2. Systemic chemotherapy, though it could not prevent local infection, was apparently extremely effective in preventing the type of invasive infection of streptococcic origin which had been associated with so many compound fractures in World War I.

3. Unreduced fractures which required repeated manipulations or whose position in traction required repeated readjustments were peculiarly likely to become infected.

4. Infection was also likely to occur in injuries in which the fracture was exposed in the wound and dead space was difficult to obliterate. This was particularly true of fractures of such bones as the tibia, the ulna, and the tarsus, all of which lie immediately beneath the skin.

The significance of these various observations was not immediately realized. The fear of reactivating infection persisted, and wounds containing grossly devitalizing tissue continued, for the most part, to be managed in the general hospitals by a hands-off policy, in anticipation of the spontaneous sequestration of dead tissues. Delayed surgical excision was thought to be neither feasible nor safe. For the same reason, inadequate reduction of many fractures, particularly of the tibia, the fibula, and the bones of the forearm, and fractures about the joints, continued to be accepted because it was feared that infection would follow operative manipulation and reduction. As the result of these concepts and practices, the incidence of malunion and nonunion of compound fractures continued too high through most of 1943, and wound healing was prolonged and sometimes was not obtained at all.

DEVELOPMENT OF THE PROGRAM OF REPARATIVE SURGERY

The closed plaster method of management of compound fractures was for all practical purposes written off early in 1944 because, even with the modifications which had been introduced, the results were not satisfactory. Analysis of the results, furthermore, showed that improvement could be accomplished only by a fundamental change in surgical concepts. Superficial alterations of technique would not accomplish the purpose. In particular, it would be necessary to discard the concept that surgery in an infected field could not be performed because of the risk of precipitating a limb-endangering osteomyelitis if not a life-endangering generalized infection.

The changed approach to battle-incurred compound fractures and the revised concept of their management were both embodied in the reparative-surgery program which had been instituted in the Mediterranean Theater of Operations late in 1943. At this time, the delayed closure of clinically clean wounds of the soft parts began to be practiced by a number of surgeons and was enthusiastically encouraged by the consultant in surgery for the theater. Though this story is told in detail in another volume of the clinical series of this history, it must be briefly summarized here, because it provides the background for the experience in the reparative surgery of compound fractures.

It was always a general principle of military surgery in World War II that wounds should be left open following debridement. The wartime experience with primary closure of soft-tissue wounds was brief and unhappy. Wound healing by granulation, however, had not provided the answer to the problem, and, as just indicated, delayed closure of soft-tissue wounds began to be practiced late in 1943, at first occasionally, then more frequently, and with informal official encouragement.

This was not a new idea. It had been practiced to some extent in World War I, with, however, one essential difference. No matter at what time delayed primary closure was to be instituted, cultures were taken from the wound when it was exposed for dressings, and closure was not scheduled if the bacterial count was high. In effect, this meant that the wound must be dressed one or more times to obtain the material for culture. It meant, further, that each of these dressings offered fresh opportunities for infection. Finally, it meant that a considerable amount of laboratory work was prerequisite to the closure of any wound. For two reasons, therefore, the policy of delayed primary wound closure had only a limited application in World War I: (1) If bacterial counts were high, as they frequently were, the optimal time for wound closure was missed, and healing by granulation had to be accepted. (2) Multiple dressings and extensive laboratory studies were so time consuming as to be completely impractical when the flow of casualties was heavy.

In World War II, delayed primary wound closure was based upon an entirely different concept. It was preferably accomplished within 4 to 7 days

after wounding if the wound looked clinically clean and if surgical limitations (that is, loss of tissue, dead space, or excessive tension if the wound were to be sutured) did not contraindicate it. Bacterial counts were not made. The decision to close the wound or leave it open longer was based entirely on very careful inspection and clinical appraisal. If tags of devitalized tissue could be excised and hematomas and dead space could be eliminated, wound closure was not regarded as contraindicated. If skin deficits prevented closure by suture, reparative surgery was still performed if closure could be effected by rotation or advancement of flaps of skin or by the use of split-thickness skin grafts. In other words, the criteria for closure were not bacteriologic but clinical. The requirements were (1) a clean wound, either present on inspection in the general hospital or secured by some additional excisional surgery; and (2) freedom from the surgical limitations just listed.

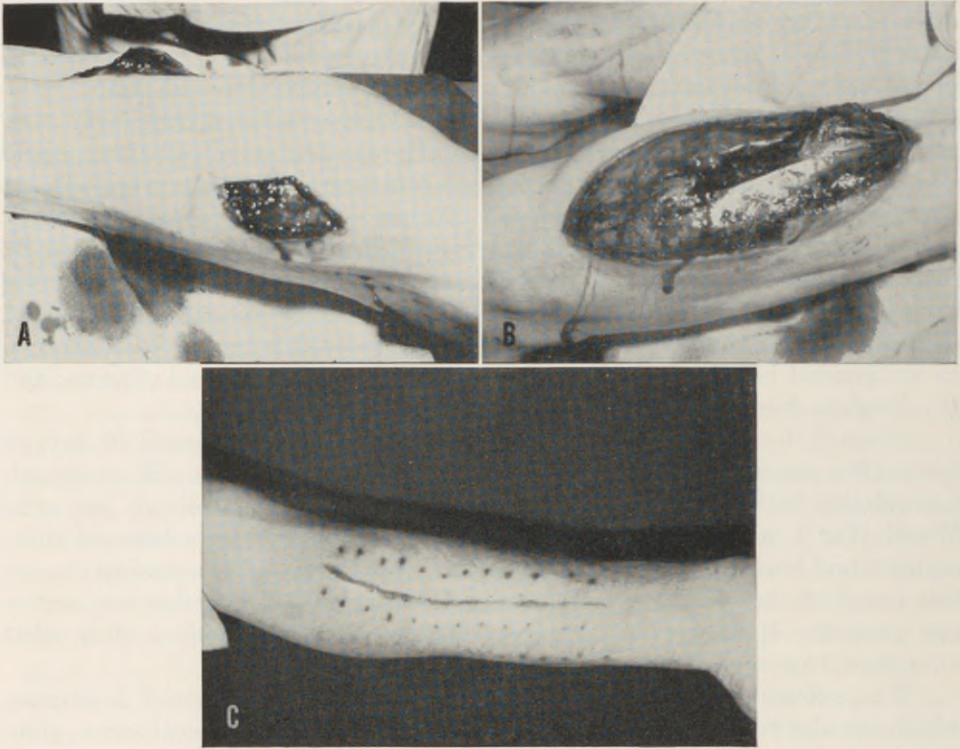Even if the casualty was not seen in the general hospital until 10 days or more after wounding, delayed closure of clean wounds was still practiced. Granulation had usually begun in such cases, and closure involved, just as in World War I, actual excision of the wound. Even after this lapse of time, cultures and bacterial counts were omitted. The decision for or against closure was based on the clinical impression that invasive wound infection was or was not present. If it was not present, closure was accomplished after what amounted to a second debridement.

The extensive bacteriologic studies carried out by Lyons and Rustigian, which are also reported in detail in another volume of this clinical series, completely confirmed the soundness of these practices. These observers were able to demonstrate that cultures taken from blood clots and from bits of devitalized tissue removed from an otherwise clean wound which healed after delayed closure with no evidence at all of infection exhibited bacterial flora entirely comparable to that found on cultures of similar material secured from wounds in which infection was established. The mere presence of these bacteria, therefore, was obviously not the cause of wound infection.

From these observations, the following concepts were derived:

1. Wound suppuration becomes established as the result of the decomposition of devitalized tissue and hematomas in dead space.
2. Pathogenic bacteria are present in all war wounds, but they are unlikely to survive if the tissue from which they secure their nutriment is eliminated at debridement.
3. If this pabulum is removed and if living tissue is protected from invasive infection by an effective antibacterial agent, then the bacterial flora of clinically clean wounds can be disregarded, infection or sepsis is not a complication to be feared, and whatever reparative surgery may be indicated can be performed on established surgical principles and will be followed by sound wound healing in the great majority of cases.

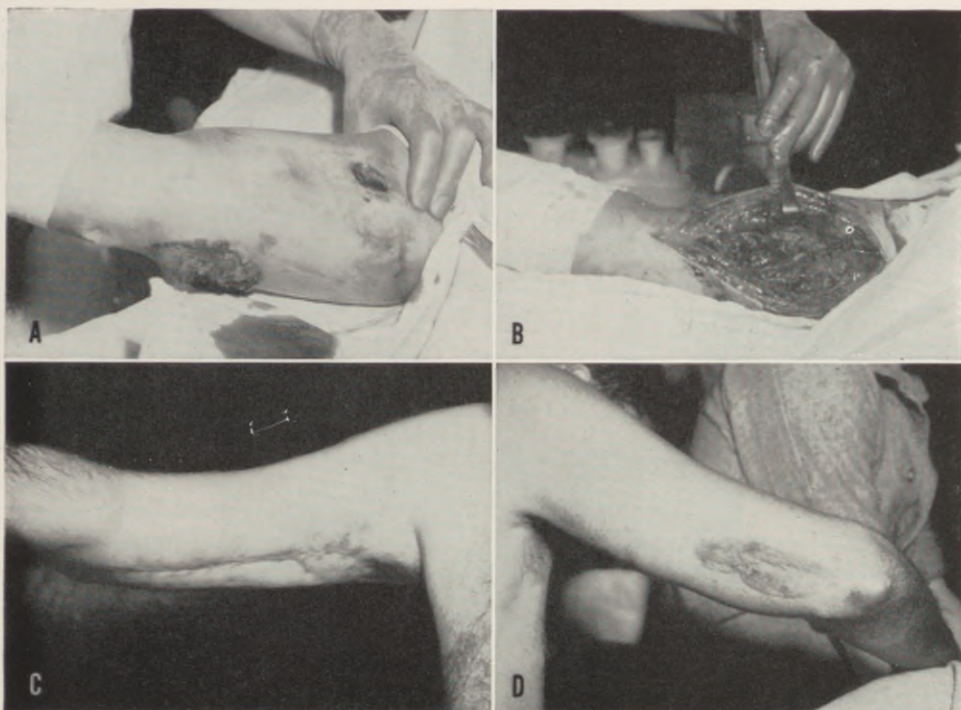
By the time of the fall of Rome, in June 1944, the consultant in surgery for the Mediterranean theater was able to report that up to that time at least



AFIP C-44-332, C-44-367

FIGURE 22.—Staged surgery of wound of soft tissue of calf. A. Appearance of wound before initial wound surgery. B. Appearance of wound at completion of initial surgery. Note exposed fascia and tendon in wound. Note also extent of resection of damaged muscle tissue. C. Wound healing after closure by suture at reparative surgery 6 days later. Split-thickness relaxing incisions have been made to avoid excessive tension on the suture line.

25,000 soft-tissue wounds had been closed by delayed primary suture on the indication of their gross appearance alone. Bacterial counts were not made in any of these injuries, partly because identification of species and tests for pathogenicity would have required weeks of arduous laboratory work and partly because preliminary qualitative or quantitative bacteriologic analysis of the flora of the wound by smear and culture would not have provided information of either diagnostic or prognostic value. In at least 95 percent of the soft-tissue wounds managed by these principles, healing occurred with no loss of life or limb and without serious complications (figs. 22, 23, and 24). The most usual explanation in the 5 percent of unsuccessful closures was failure to remove residual dead tissue in the deep recesses of the wound before the wound was sutured.



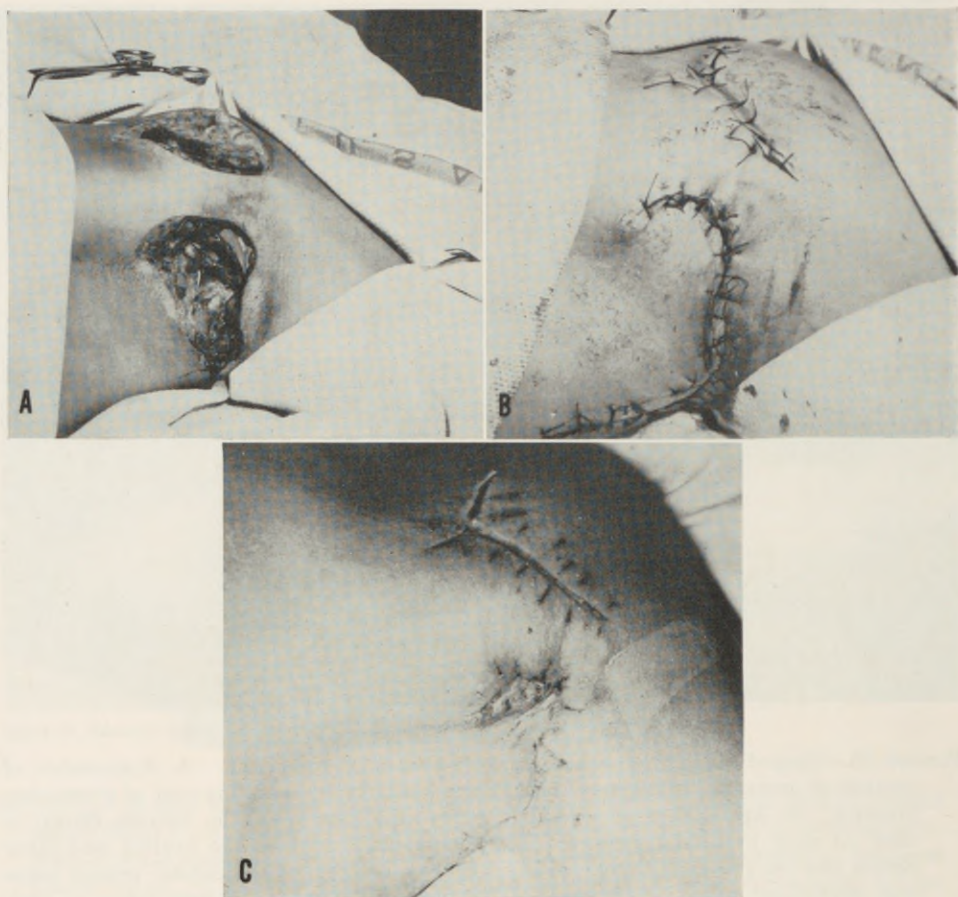
AFIP C-44-331, C-44-368

FIGURE 23.—Staged surgery of wound of soft tissues of right arm. A. Appearance of wounds of entry and exit before initial wound surgery in operating tent of evacuation hospital. B. Appearance of wound of entry (the smaller of the wounds shown in view A) after excisional surgery. Exploration disclosed that the median and ulnar nerves and the profunda brachii artery had been severed. Considerable muscle tissue was devitalized. The artery was ligated, and the damaged muscle tissue excised. The severed nerves were merely identified. C. Healed incision $3\frac{1}{2}$ weeks after delayed closure at reparative surgery. D. Healed wound of exit (shown in view A) after coverage by split-thickness skin grafts.

APPLICATION OF THE REPARATIVE-SURGERY PROGRAM TO COMPOUND FRACTURES

The writing off of the closed plaster management of compound fractures, even with its modifications, occurred, as already noted, early in 1944. By this time, the effectiveness of the reparative-surgery program for wounds of the soft parts had become fully established. It was logical to extend this program, which had proved so eminently successful, to the management of compound fractures, in which results, to date, had often left a great deal to be desired.

The program had already been applied, informally, to small groups of cases in half a dozen hospitals, with generally good results. Its expansion into a



AFIP CA-44-347

FIGURE 24.—Reparative surgery of wound of left axilla and shoulder. A. Appearance of wounds in operating room of base hospital just before reparative surgery. Note axillary artery and severed nerve trunk visible in axillary wound. B. Appearance of wounds at conclusion of reparative surgery. By extending the axillary wound with an incision along the posterior margin of the chest wall, it was possible to advance and rotate a flap of skin, after which it was possible to cover the axillary contents and close the wound without excessive tension on the suture line. C. Healed wounds 15 days after delayed closure.

theaterwide program of management in the late spring of 1944 could not have occurred under more propitious circumstances, for the following reasons:

1. The educational program in forward hospitals concerning standardized principles of excisional surgery and transportation splinting had begun to bear fruit, and debridement, as a general rule, was now being performed completely and correctly.

2. The chain of evacuation from Cassino, by ambulance and train, to

general hospitals in Naples and Caserta was relatively short. After 23 May 1944, air evacuation from the Anzio area was also functioning well.

3. The functions of forward and general hospitals in the management of compound fractures had been completely clarified. The mission of forward hospitals was the salvage of life and limb by initial wound surgery, together with the application of transportation splinting, without effort at definitive reduction. The mission of fixed hospitals in the rear was the prevention of infection or its treatment, closure of the wound, and reduction of the fracture. It was recognized, in short, that the management of compound fractures in overseas theaters was a two-stage procedure. The mission of forward hospitals did not include fracture management, and the splinting applied in them was designed primarily for transportation and not to maintain precise alinement of bones.

4. A bed status had been established in general hospitals which permitted patients to be held the length of time necessary for the employment of reparative surgery and fracture management.

5. Supplies of blood had become available in sufficient quantities to permit transfusions in more liberal amounts than had previously been possible or than had been regarded as necessary.

6. Penicillin had become available in sufficient quantities for general use.

The extension of the reparative-surgery program to the management of compound fractures was intimately related to the availability of penicillin. The original plan had been to establish an orthopedic center in the theater to test the surgical possibilities of this new agent as soon as it could be supplied in sufficient quantities for this purpose. This plan was later discarded. Instead, Maj. Oscar P. Hampton, Jr., MC, theater consultant in orthopedic surgery, and Maj. Champ Lyons, MC, who had done much of the original work with penicillin in the Zone of Interior, were constituted a team to be attached, in turn, to each of five general hospitals in the Naples area, for periods of 1 to 2 weeks, to initiate in them a program of reparative surgery under penicillin protection for compound fractures.

This project was set up with no preconceived notions. No effort was made to prove anything at all about penicillin. It was merely used as a probable safeguard while surgical eradication of an infectious process was undertaken. The first cases selected for treatment in each hospital were invariably infected compound fractures. Surgery was aggressive. It included not only the drainage of abscesses but also the excision of devitalized tissue, foreign bodies, and sequestra; freshening of wound edges; reduction of fractures, with, if necessary, stabilization by internal fixation; and closure of wounds by suture about 7 days after this operation. Liberal blood transfusions were an essential part of the program.

Within a few weeks, the soundness of these new policies had become so apparent that the program was extended to include all fractures and all joint injuries. Subsequent appraisal of results showed that when the original injury did not make prolonged drainage inevitable and reduction of fractures impos-

sible, the reparative-surgery program was found to be capable of accomplishing, in large measure, its original objectives; namely, (1) elimination of wound infection; (2) rapid wound healing, with minimal scar formation; (3) optimum reduction and stabilization of fractures; and (4) maximum functional restoration of the wounded part. These objectives were achieved by a three-point plan of management consisting of (1) adequate blood replacement, to overcome anemia, permit the prolonged anesthesia so often necessary in compound fractures, and aid in wound healing and in the defense against infection; (2) antibiotic therapy, to protect living tissue against invasive infection; (3) precise surgical therapy, designed to repair defects caused by the missile or resulting from initial wound surgery and planned, at the same time, to prevent infection or to control it if it was already present.

Blood replacement and antibiotic therapy, valuable as they were proved to be, were recognized from the beginning as merely adjunct measures. Good surgery was the keystone of the reparative-surgery program for compound fractures. Wound healing by granulation was inevitable and had to be permitted in a certain proportion of all compound fractures, but it was no longer accepted in any instance in which the program of delayed closure of wounds by suture or skin graft was applicable.

Part II. The Initial Surgery of Compound Fractures

SURGICAL TIMING

The surgery of wounds involving bones and joints was ideally rendered in three phases, initial wound surgery in the combat zone and reparative surgery in the communications zone, with reconstructive surgery, if it was necessary, a function of hospitals in the Zone of Interior. One of the most important medical developments in World War II was the perfection of surgical timing, by which hospitalization, evacuation policies, and the scheduled transportation of patients from one medical installation to another were progressively correlated with the temporal necessities of surgical management. As always in warfare, tactical circumstances and the maintenance of combat efficiency required the evacuation of the injured soldier who was not to return to duty within the theater farther and farther away from the battlefield, both to remove him from the combat zone and to leave hospital facilities near the front available for the freshly wounded, whose need for care was urgent. This military necessity required, in turn, that medical care be rendered in phases, by different surgeons, at different times and in different places. Professional and logistic considerations were problems which could be solved only in relation to each other.

The pattern of wartime surgical care is thus radically different from the pattern of civilian care. This is one of the things that makes their introduc-

tion to military surgery so difficult for medical officers, however competent they may be, who are fresh from civilian practice. It is a matter of the first importance that they learn and adhere to the prescribed routine, and it is here that the educational efforts of consultants have a particularly wide field of usefulness.

Because of their character, bone and joint injuries lent themselves particularly well to surgical timing. In them, as in other wounds of the extremities, surgical care was rendered in phases, in installations equipped and staffed to supply the special phases of care required at the time after wounding when the casualty reached them. It cannot be too strongly emphasized that it was the *timing* of each phase of management, not the location of the installation in which the surgery was performed, which was of supreme importance.

As the consultant in surgery for the Mediterranean theater, Col. Edward D. Churchill, MC, repeatedly emphasized, surgical considerations established the necessity for (1) as short a timelag as possible between wounding and initial wound surgery; (2) an optimum 4- to 7-day delay between excisional initial surgery and reparative wound revision and closure; and (3) suitable holding periods in hospitals coincident with those stages of wound management.²

The timelag between wounding and the institution of first-aid measures, although it was often lengthened by the intensity of combat, seldom exceeded a few hours. The timelag between the institution of first-aid measures and initial wound surgery for bone and joint casualties was influenced by a variety of factors, including the intensity of combat, the numbers of casualties, the distance of the evacuation hospital from the frontline, the condition of the roads, the availability of transportation, and the delay required for resuscitation. As a rule, it did not exceed 12 to 16 hours.

From the standpoint of reparative surgery, it was preferable that casualties reach a general hospital in the communications zone by the 4th day after the first operation and essential that they reach it not later than the 7th to the 10th day. Since the majority of casualties with injuries limited to the bones and joints became transportable from forward hospitals within 2 to 3 days after initial wound surgery, this requirement could usually be met without difficulty. Hospitalization for periods varying from 2 to 12 weeks, depending upon the nature and location of the fracture, was necessary after reparative surgery.

The chief thing that an inexperienced medical officer had to learn, whether or not he had had experience in orthopedic surgery in civilian practice, was that battle-incurred compound fractures are materially different from those resulting from traffic and other civilian accidents. For example—

1. Battle-incurred fractures in World War II were usually produced by high-velocity missiles or shell fragments which had, for all practical purposes, the effect of an internal explosion. The shattering effect of the energy imparted by the missile produced bone fragments which frequently themselves acted as

² Churchill, E. D.: The Surgical Management of the Wounded in the Mediterranean Theater at the Time of the Fall of Rome. *Ann. Surg.* 120:269-283, September 1944.

secondary missiles, being driven into the muscle tissue and adding greatly to the original soft-tissue damage. These fragments, like the original missiles, had a tearing, disruptive action which led to extensive damage in multiple directions, often far from the site of injury.

2. Battle-incurred compound fractures were always compounded from without in. The missiles passed through clothing which was often soaked with the mud, grime, and filth of the battlefield. They often blasted or carried fragments of the clothing and other material into the wound with them.

3. The timelag from wounding to operation, which is usually minimal in civilian injuries, while very occasionally as short as 3 to 4 hours, not infrequently was as long as 12 to 24 hours. The mere lapse of many of these periods of time implies that at operation the wounds had passed beyond the stage of simple contamination and were potentially infected.

Convalescent hospitals in either the combat or communications zone played little part in the management of casualties with bone and joint injuries. The mission of these hospitals was to receive lightly wounded men after their professional care had been completed at evacuation hospitals and to prepare them for return to combat duty after a short period of what amounted to rehabilitation. Very few soldiers with injuries of the bones and joints had injuries whose care could be completed within the holding periods permitted at evacuation or convalescent hospitals. In the great majority of instances, for that matter, care could not be completed at general hospitals in the communications zone, and evacuation to the Zone of Interior was necessary.

FIRST AID

The preliminary management of compound fractures is briefly summarized in this chapter, to make the record complete. The only measures employed on the battlefield and in the battalion aid stations and collecting and clearing stations were those necessary to check hemorrhage, prevent further damage to soft tissues, relieve pain, avert or control shock, and prevent further contamination of the wound while the wounded soldier was being evacuated from the frontline to a hospital staffed and equipped to perform initial wound surgery. These steps included—

1. The application of sterile occlusive dressings. These dressings were inspected at each of the echelons of the division medical service but were removed and replaced only for cause, which was chiefly the suspicion of fresh or recurrent hemorrhage.

2. The control of hemorrhage by compression dressings. If they were not effective and if the bleeding vessel could not be visualized and controlled by the application of a hemostat, a tourniquet was used. Casualties with bone and joint injuries became first-priority cases once a tourniquet was applied.

3. The administration of morphine, in limited doses, if the pain was too severe to be controlled by simpler measures. The routine administration of

morphine in the large doses given early in the war was later replaced by a more discriminating use of morphine, in smaller doses, and of sedatives, according to the requirements of the individual patient. Actually, a man who had suffered a compound fracture was frequently promptly relieved of pain by the correct application of emergency splinting (p. 32).

4. Plasma transfusion. Transfusions of plasma while the casualty was in one of the stations en route to an evacuation or field hospital had a single objective, to provide lifesaving resuscitation and make him transportable. Plasma was administered as necessary in the battalion aid station, the collecting station, or the clearing station. Blood was not available in these medical echelons of the Mediterranean theater during World War II. If, however, the blood pressure was found to be critically low in the clearing station, experienced medical officers, instead of holding the patient there to administer plasma, frequently transferred him to the adjacent field hospital, where whole blood was always available.

5. Emergency splinting, which was an essential step in all bony and massive soft-tissue injuries of the extremities. This subject is discussed in detail in a separate chapter (p. 31).

6. Other measures. These included the administration of a booster dose of tetanus toxoid and the institution of chemotherapy. Until near the end of the war, chemotherapy included the local use of sulfonamide powder or crystals.

PREPARATION FOR INITIAL WOUND SURGERY

The routine preoperative management of casualties with bone and joint injuries in a forward hospital consisted of the following steps:

1. A rapid examination, after the clothing had been cut away, to determine the location and extent of the injuries and to evaluate the soldier's general condition.

2. Inspection of the dressings and of the emergency splinting. If resuscitation occupied any considerable time or if operation was delayed for other reasons, the inspection was repeated at regular intervals. It was frequently necessary to reinforce the splinting or to adjust it when the patient was first examined. If the lower extremity was in a half-ring leg splint, the traction hitch was examined, to be certain that pressure on the dorsum of the foot was not excessive. Careful attention to splinting frequently eliminated the necessity for the administration of morphine or other drugs to control pain.

3. Conservation of body warmth, by the use of blankets under the patient as well as over him. Excessive covering and external heat, which would cause sweating and loss of body fluids, were avoided.

4. The prompt use of a tourniquet if there was evidence of bleeding. Patients with tourniquets already in situ were, as already noted, first-priority cases.

5. Roentgenologic examination, which was an essential part of the preoperative routine in all bone and joint injuries. Roentgenograms, which were made in the usual anteroposterior and lateral views, were planned to include not only the known area of damaged bone and retained foreign bodies but also as large a portion of the surrounding areas as possible.

6. Induced vomiting or gastric lavage, unless the stomach had already been completely emptied by vomiting or more than 12 hours had elapsed since intake of food.

7. Withholding of food and fluids by mouth. If the patient complained of thirst, he was permitted to rinse his mouth or to suck a moist sponge.

Resuscitation.—Many casualties were in moderate or severe shock and required some resuscitation as part of the preoperative preparation. The measures employed to combat shock included—

1. The use of the Trendelenburg position unless complicating chest or head wounds contraindicated it. The patient was very gradually restored to a level, recumbent position when the systolic blood pressure reached 80 mm. Hg.

2. Oxygen administration by nasal tube if cyanosis was present.

3. Blood and plasma transfusions according to the indications of the special case. The necessity was determined entirely by clinical findings (table 2). Detailed laboratory studies were impractical in the preoperative wards of an evacuation hospital, and medical officers, as their experience increased, became more and more skilled in the interpretation of clinical observations in terms of blood replacement.

In practice, the liberal use of whole blood proved the most effective single measure of resuscitation for casualties in actual or impending shock. Most men with compound fractures required some replacement of lost blood before and during operation. Often they required large quantities.

In at least half of all cases, patients with fractures of the femur required a minimum of 1,000 cc. of blood before they could be subjected to initial wound surgery. Studies in the 16th Evacuation Hospital showed that 28 of 100 casualties with fractures of the femur required between 1,500 and 2,000 cc. of blood before and during operation and that only 9 required no blood at all. Of 100 patients with compound fractures of the radius, ulna, or both bones of the forearm, in contrast, only 3 required between 1,500 and 2,000 cc. of blood, and 63 received no blood at all before and during operation. Patients with compound fractures of the humerus and of the tibia, fibula, or both bones of the leg formed an intermediate group in respect to the need for whole blood. Of the 400 patients with compound fractures of the bones included in this survey (table 3), only 110 (27.5 percent) required no blood at all before and during operation, while 48 (about 12 percent) required between 1,500 and 2,000 cc.

Blood could not be administered by any rule of thumb. The individual man's condition determined how much he needed and when he was fit for surgery. Enough had to be given to overcome the most severe symptoms and signs of shock, plus enough to prepare him for the additional strain of anesthesia and operation and to compensate for the estimated blood loss on the operating

TABLE 2.—*Relationship of degree of shock and average blood loss in 67 patients with all types of wounds*

Degree of shock	Clinical observations								Average blood loss (corrected values in round numbers, in percentage of normal)	
	Blood pressure (approximate)	Pulse quality	Skin temperature	Skin color	Skin circulation (response to pressure, blanching)	Thirst	Mental state	Blood volume	Hemoglobin	Percent
None	Normal	Normal	Normal	Normal	Normal	Normal	Clear and distressed	14	20	
Slight	Decreased 20 percent or less.	do.	Cool	Pale	Definite slowing	do.	do.	21	30	
Moderate	Decreased 20 to 40 percent.	Definite decrease in volume.	do.	do.	do.	Definite	Clear and some apathy unless stimulated.	34	46	
Severe	Decreased 40 percent to nonrecordable.	Weak to imperceptible.	Cold	Ashen to cyanotic (mottling).	Very sluggish	Severe	Apathetic to comatose; little distress except thirst.	46	55	

Source: Medical Department, United States Army, Surgery in World War II. The Physiologic Effects of Wounds. Washington: U. S. Government Printing Office, 1952, pp. 28, 56.

table. It was a very easy matter to underestimate the amount of blood lost at wounding and during transportation, as well as later at operation.

TABLE 3.—*Blood replacement before and during initial surgery in 100 consecutive compound fractures of each of the long bones*¹

Blood replacement (in cc.)	Radius, ulna, or both	Humerus	Tibia, fibula, or both	Femur	Total fractures	Percentage
2,000	1			10	11	2.8
1,500	2	5	12	18	37	9.3
1,000	17	36	35	50	138	34.4
500	17	36	38	13	104	26.0
None	63	23	15	9	110	27.5
Total cases	100	100	100	100	400	100.0

¹ These observations were made at the 16th Evacuation Hospital in the Mediterranean Theater of Operations.

In most of the casualties with bone and joint injuries, systolic blood pressures could be restored to 100 mm. Hg before operation. If this level could be attained without too much delay, that was naturally desirable. If it could not be, experience showed that operation should be undertaken only (1) after a combination of blood replacement and other measures had raised the blood pressure to 80 mm. Hg, which was a safe and satisfactory level for men of military age; (2) when the trend of the pulse rate was downward and the trend of the quality upward; and (3) when other symptoms and signs of shock were decreasing or had disappeared. It was not safe, however, to undertake operation until a sufficient quantity of blood was available to cover possible losses at operation.

Plasma transfusion was stopgap therapy and was eventually used only for that purpose; that is, to elevate the blood pressure to a level compatible with life and to maintain it at that level until transfusions of whole blood could be given and operation undertaken. The chief usefulness of plasma was in the echelons of the division medical battalion, but it was also used as indicated in evacuation and field hospitals.

Another important clinical fact which was eventually confirmed during World War II was that the wounded man did best if he was resuscitated as rapidly as possible and operated on with equal promptness. A wounded man who had been brought out of shock could readily slip back into it. The second attempt at resuscitation was always more difficult than the first and was sometimes not as effective. This was as true of patients with extensive compound fractures as of those with injuries of the chest or abdomen. The aim of resuscitative therapy was not to restore the casualty to his normal status nor to repair the organic damage caused by even a brief period of depressed blood pressure. Both of these objectives, in fact, were unattainable within a limited time and without the corrective effect of operation, which was itself a part of

the resuscitative procedure. The aim of resuscitation in an evacuation hospital was merely to make the patient fit for initial wound surgery, and his best interests were served if he was operated on as soon as that objective had been achieved.

Objectives of initial wound surgery.—The objectives of initial wound surgery (debridement), regardless of the type of injury, were threefold: (1) To save life, (2) to save limb, and (3) to prevent or eradicate infection. The attainment of these objectives was accomplished by (1) the arrest of hemorrhage; (2) the removal of foreign bodies and foreign material within the wound; (3) the excision of tissues which had been destroyed by the missile (missiles) or devitalized by the impairment or destruction of the blood supply to the part; (4) the provision of drainage, which was accomplished by nonclosure of the wound; and (5) transportation splinting. Transportation splinting is discussed in detail under a separate heading (p. 39). When these objectives had been accomplished, the result was a wound easily managed at reparative surgery.

APPRAISAL OF THE WOUND

After the wounded man with an injury or injuries of an extremity had been adequately treated for shock in the shock or preoperative tent of the evacuation hospital, he was transferred to the operating tent, accompanied by the roentgenograms which had been taken of the injured area.

Only occasionally was the soldier removed from the litter on which he had been transported and placed on an operating table. As a general rule, the litter was placed on the table or was supported by its handles on boxes or sawhorses, and itself served all the purposes of a standard operating table. This plan had a number of advantages. It conserved the time and effort of the operating-room personnel. More important, it spared the patient the move from the litter to the operating table before operation, and from the table to the litter at the end of the procedure. This was highly desirable, because casualties who had previously been in shock were likely to suffer recurrent shock if they were moved about.

Examination in the admitting tent of an evacuation hospital (p. 67) was essential to identify the wounds and determine the patient's status. A detailed examination, however, was impossible under the circumstances which prevailed in that area, and it was therefore deferred until he had reached the operating room. It was, as a matter of fact, to the advantage of a patient in shock not to disturb him for such an examination until he had been properly prepared for operation. When he was placed on the operating table, under a good light, with the emergency splinting and dressings removed, and with roentgenograms available for reference, it was possible to make a thorough examination and complete appraisal of the injuries. The routine was as follows:

1. The site of entry of the missile (missiles) was determined, and the site of exit was sought for.

2. When the sites of entry and exit had been identified, the course of the missile was determined. If a site of exit was not found, the course was postulated from the site of entry to the point at which the retained missile was demonstrated by roentgenograms. After this information had been secured, it was possible to plan the incision or incisions which would provide most convenient and most satisfactory access to the devitalized tissue and retained foreign material which had to be removed, as well as to whatever nerve or vascular injuries might be present.

3. Determination of the presence or absence of arterial pulsations distal to the wound (wounds) of an extremity was an essential part of preoperative appraisal. If pulsations could not be obtained, the major blood vessels which might be damaged had to be visualized and treated according to the indications.

4. Function of major nerve trunks also had to be investigated, though this was not always an easy matter, since damage to bone and muscle might prevent active movement of the digits of the hand or foot, even when the motor nerve supply remained intact. On the other hand, careful investigation of the status of motor function and sensory supply usually permitted the surgeon to arrive at some definite conclusion concerning the integrity of the major nerve trunks. By observation of only the motions of the thumb, for example, it was possible to decide whether or not there had been functional damage to each of the three major nerve trunks of the upper extremity. If the distal phalanx of the thumb could be extended or if the entire thumb could be abducted and extended, it could be assumed that the radial nerve was intact. Active flexion of the thumb against the side of the hand established the integrity of the ulnar nerve. When there was evidence of loss of function in the supply of a major peripheral nerve, the nerve was usually exposed during initial surgery to permit an accurate estimate of the degree of damage.

GENERAL PRINCIPLES AND PRACTICES

Initial wound surgery, whatever modifications might be necessary in individual wounds, was ideally conducted on the basis of certain principles and practices, as follows:

1. The length of the timelag from wounding to operation was of no importance in the decision whether, or when, to perform initial wound surgery. Fresh wounds were operated upon as promptly as possible. Old wounds (that is, wounds of more than 48 hours' duration) were managed in the same manner except that invasive spreading infections, with cardinal signs of inflammation such as cellulitis and lymphangitis, were best managed by antibiotics, immobilization, and the application of warm wet dressings until an optimum time for surgery could be selected. There was no hesitation, however, in draining septic hematomas, fascial-plane abscesses, and large masses of dead, autolyzing tissue when the casualty was first seen.

2. A precise knowledge of regional anatomy was essential. Indeed, the initial surgery of war wounds of the extremity amounted to a postgraduate course in surgical anatomy. The surgeon had to know the location of the nerve and blood supply of every muscle and had to respect blood vessels and nerves in his dissection. This was particularly important when there were large wounds in the region of heavy muscles, such as the gastrocnemius-soleus group in the calf and the rectus femoris in the thigh. The technique had to be both careful and precise, for irreparable damage could be done if major blood vessels and nerve trunks were damaged in the course of the operation.

3. Roentgenograms were made routinely in two views, so as to cover as broad a field as possible about the wound or wounds. They were available for use in the operating tent.

4. An adequate light and a competent assistant were basic requirements.

5. A wide field was prepared, to allow for extension of the original incision or for counterincision as might be necessary.

6. The operative procedure was carried out in an orderly manner. There was no place in initial wound surgery for haphazard, bloody, cut-and-slash techniques.

7. Adequate exposure was essential for the complete excision of devitalized tissue. Bold incision was therefore the first step at operation. As a general rule, the line of incision was placed parallel to the long axis of the limb, though on the hand, the foot, or the buttock the incision might follow the natural lines of the skin. The creation of circular skin defects had to be avoided, though excision of a small area (2 to 3 mm.) of devitalized skin on the margins of the wound might be indicated.

8. Dead and devitalized tissues had to be completely excised. This was the most important single step in preventing infection. Failure to excise devitalized muscle seeded with pathogenic bacteria led to the sepsis for which combat-incurred wounds are notorious. If tissue devitalized by the missile or produced by the surgeon in the course of operation was left in situ, wound healing would not occur until it had sloughed away. The fascial layers had to be incised as freely as the skin, since free access to devitalized muscle is necessary for thorough excisional surgery.

9. Retained foreign bodies, especially if they were of any considerable size, were best removed at initial surgery. It was important that they be identified and, if possible, removed, because the path which led to them was the track along which devitalized muscle would be found. Moreover, foreign bodies, especially high-explosive shell fragments, were likely to carry into the wound bits of clothing, shoe leather, or other foreign material, which would be removed when the fragments themselves were removed. Deep recesses containing foreign bodies might be approached by counterincisions planned anatomically over fascial planes rather than by cutting through normal muscle structure.

10. Fine hemostats were used whenever they were available, and only the smallest possible amount of tissue was ligated. Structures within the wound

were not traumatized more than was necessary by the use of tissue forceps. Sponging was done very gently.

11. Ligatures for the control of bleeding vessels were as fine as possible. They could be either absorbable or nonabsorbable, but the young surgeon found his operating time shortened when nonabsorbable sutures were used because they were bulkier and therefore easier to handle.

12. Incisions and counterincisions were left open, and no sutures were used following the excisional phase. The provision of drainage, which was inherent in this policy, was a cardinal principle of the management of such injuries. There were only two exceptions to this rule: The synovial membrane was closed in wounds of the joints (p. 216), and flaps of skin were tacked loosely in wounds of the hand to cover cartilaginous surfaces and tendons which would otherwise be left exposed.

13. The unsutured wound was carefully dressed with fine-mesh gauze so that all raw surfaces were covered. The purpose of the dressing was merely to hold the raw surfaces of the wound apart and permit drainage from its depths. The portion of the dressing placed in the depths of the wound always had to be placed loosely. Otherwise, as the wound and the area about it began to swell, the dressing would become dangerously tight.

TECHNICAL CONSIDERATIONS

The wide variation in the location of battle injuries of the extremities and in the extent of the damage to the deeper structures required variations in the surgical procedure which made it impossible to outline the step-by-step technique for initial surgery which could be outlined for an appendectomy, for instance, or the repair of an inguinal hernia. The principles and policies just listed served as a guide to what had to be done. Certain technical considerations, however, were applicable to all types of wounds (fig. 25).

Incision.—The location of the wound usually, though not always, determined the location of the surgical incision. Wherever it was located, care was taken to make it of adequate length. It was always better to make it too long rather than too short; the unnecessary length did no harm, since an incision heals from side to side, not from end to end. It was also desirable that the surgeon, at the initial operation, plan the skin incision so as to expose the devitalized deeper structures.

Instead of an incision through the wound, a standard longitudinal incision was frequently used, so placed as to open into muscle planes and offer a better access to devitalized muscle tissue. It was never wise to extend an incision proximally and distally from the center of a wound which ran in the opposite direction, or from the center of a circular wound. These practices created a crucial type of incision, which handicapped the closure of the operative incision at reparative surgery and might even prevent closure entirely, particularly at the point at which the wound of entry was crossed by the surgical incision. If an incision had to be extended proximally and distally from the wound pro-

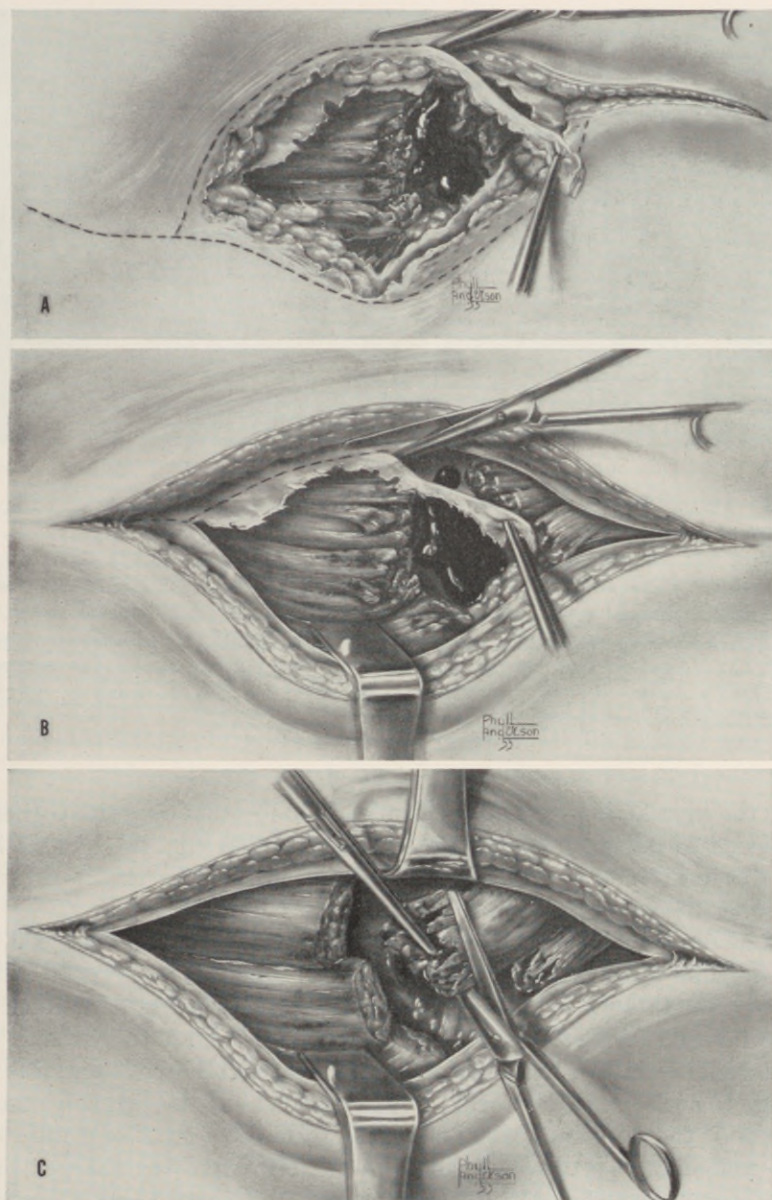
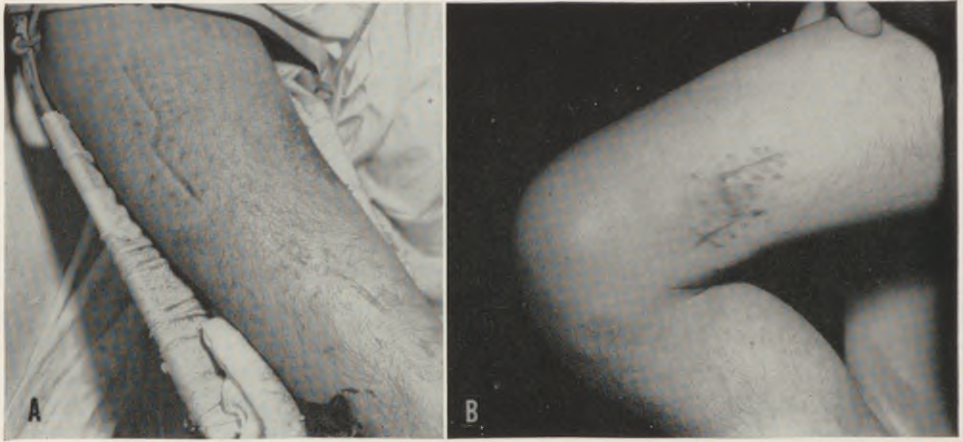


FIGURE 25.—Technique of initial wound surgery of soft-part wound. A. Incision of skin, in long axis of extremity and excision of the traumatized skin border. B. Exposure of depths of wound, excision of devitalized fascia. Damaged muscle in depths of wound is visualized. C. Saucerized wound. Debridement is almost completed. The last of the devitalized muscle is being cut away with scissors.



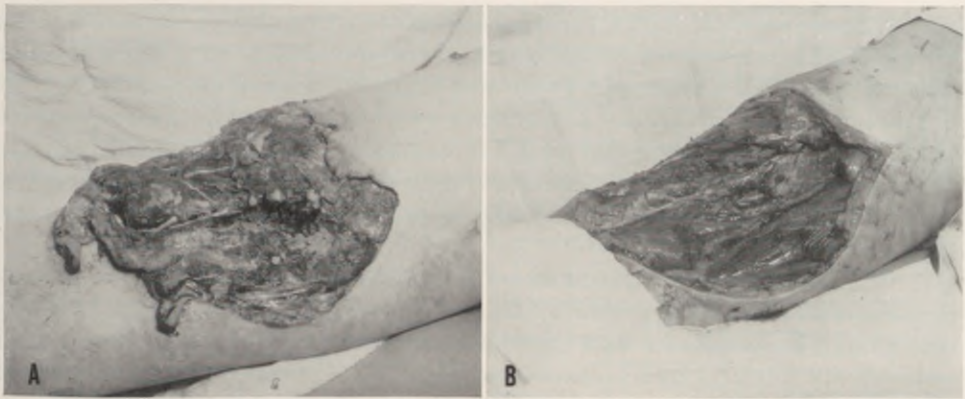
AFIP FA-45-50, FA-45-47

FIGURE 26.—Staged surgery of wound of thigh. A. Anterior wound of thigh compounding fracture of femoral shaft. Appearance 3 weeks after reparative surgery. B. Lateral wound of soft parts 4 weeks after reparative surgery. Note that in these wounds the proximal and distal incisions extending from the transverse wounds of entry were correctly made at initial wound surgery. Z-plasty incisions, which can be closed without difficulty, were thus obtained, rather than cruciate incisions, difficult to close, which would have resulted had the surgical incisions been made across the center of the transverse wounds. (These wounds were debrided by Maj. Howard B. Shorbe, MC, 2d Auxiliary Surgical Group.)

duced by the missile, it was best to begin each limb at an opposite corner of the wound, so as to leave, in effect, a Z-shaped incision (fig. 26). This kind of incision was particularly desirable in areas in which the skin was normally tight, as over the anterior surface of the leg.

Skin devitalized by the entrance of the missile had to be excised, but as little as possible was removed and no normal skin was sacrificed. The skin incision was made with a knife, and surgical perfectionists demanded that a knife also be used for the excision of the skin edges about the wound. Experience showed, however, that, when this practice was followed, there was usually a tendency to excise more skin than was necessary. If the surgeon's technique was such that the excision could be limited to removal of 2 to 3 mm. of skin, then the scalpel was preferable, since its cutting edge was sharper than the cutting edges of scissors. On the other hand, the advantages of excision by scalpel were more theoretic than real, and trimming of the skin edges of a wound with scissors was easier and generally more rapid.

Excisional surgery.—Once the skin incision had been made and the wound laid fully open, there was no objection to the careful use of a pair of sharp scissors for excision of devitalized fascia and muscle. Strong encircling fascia, such as the fascia lata, was opened widely, and all grossly traumatized areas were excised.



AFIP CA-44-135

FIGURE 27.—Initial surgery of large, ragged wound of anterior surface of right thigh. A. Appearance of wound before initial surgery. B. Wound after adequate excision of devitalized tissue.

The decision as to just what muscle tissue should be excised was decidedly less simple, because devitalization was not so easily determined. A time-honored criterion of death of muscle is its failure to contract when it is pinched with thumb forceps, and this test was frequently used. Muscle which contracted when pinched was unquestionably viable, but the reverse was not true; failure of contraction did not necessarily mean that the muscle was dead and should be excised. Muscle which bled freely when it was cut, even if it did not contract when it was pinched, was probably still viable.

If bleeding did not occur, then the muscle was definitely not viable and the excision had to be carried back until muscle which bled on section was reached. On the other hand, even though there was some bleeding when damaged muscle was cut, it was always best to carry out excisional surgery if the tissue appeared macerated or the muscle bundles were separated (fig. 27). In other words, while it was essential that excisional surgery be thorough, it was the responsibility of the military surgeon to be certain that the incision he undertook was justified and that he was not extending it beyond indicated limits.

The wound, as has been repeatedly emphasized, was left open when initial wound surgery was concluded. A saucerized type of wound was generally desirable, though there were exceptions, particularly when the original injury was of the through-and-through variety. Large dead spaces, in which serum and wound exudate could collect, were eliminated by counterincisions and dependent drainage. Rubber-tissue drains were not used after initial wound surgery except when they were essential to insure dependent drainage of residual dead space.

Dressing of the wound.—The raw surfaces of the wound were covered with fine-mesh gauze. After the program of reparative surgery was in effect

at the fixed hospitals in the theater, dry gauze was regarded as best for this purpose, since drainage of wound exudate was provided by capillary attraction when it was used. When the gauze was removed, several days after the first operation, a clean, relatively dry surface was usually found. Petrolatum-impregnated gauze could also be used, but capillary attraction was not provided through its meshes and when it was removed the surface of the wound was likely to have a slimy and less healthy appearance than when dry gauze was used.

Whether dry or petrolatum-impregnated gauze was used, the wound was dressed in the following manner: Single strips of gauze were arranged side by side around the perimeter with the ends of the strips in the depths of the wound, until all raw surfaces had been covered (fig. 28). It was not the intention to




FIGURE 28.—Appearance of wound after strips of dry or petrolatum-impregnated fine-mesh gauze had been loosely introduced into depths at completion of initial surgery.

pack the wound. The purpose of the dressing was merely to hold the raw surfaces apart and provide drainage from the depths of the wound. Inexperienced military surgeons, partly because of their inexperience and partly because of a desire to reduce the oozing of blood from the raw surfaces, were inclined to pack the wound tightly. When this was done, there was no provision for the swelling which normally follows an operative procedure, and the tightly packed dressings became even more undesirably tight.

After the fine-mesh gauze strips had been placed in the wound, they were covered with standard gauze dressings.

MANAGEMENT OF BONE FRAGMENTS

It was impossible to avoid moving bony fragments about during the debridement of compound fractures, and it was easy, unless great care was taken, to tear them away from attached soft tissue. All manipulations of fragments

therefore had to be very gentle. Sponging had to be done carefully in the region of the fractures, for jagged fragments could become entangled in the meshes of the gauze and could be avulsed from their remaining attachments, especially when the sponge was removed from the wound.

To the end of the war, there was no universal agreement in the Mediterranean theater as to the management of bone fragments. A few surgeons believed that all fragments should be allowed to remain in situ or should be replaced after they had been removed and cleansed, on the ground that segmental bone defects would thus be avoided and the chances of union increased. The background of this policy was the concept that these fragments were, in effect, bone grafts, which could be expected to participate in the process of healing.

The majority of surgeons took the opposite point of view. They willingly admitted that the removal of bone fragments introduced the risk of segmental defects and that segmental defects, in turn, militated against the union of fractures. In their opinion, however, these fragments should be removed because, since they were totally devoid of soft-tissue attachments and were therefore without blood supply, they were, in effect, devitalized tissue, which might serve as a nidus of infection and prevent healing of both the injured bone and the compounding wound.

The whole disagreement was, to a certain extent, academic. Surgeons of both schools of thought naturally left in situ all fragments with any sort of soft-tissue attachments, regardless of their size, since it could be assumed that some degree of vascularization would persist through these connections. Fragments totally devoid of soft-tissue attachments were usually small (three-fourths inch in diameter or less), and their removal seldom created defects of sufficient size to prevent good contact between major bone fragments.

The policy therefore evolved of removing all small fragments of bone totally devoid of soft tissue and of leaving in situ those with even the smallest amount of attachment to the soft parts. If a large fragment was totally detached and its removal would create a segmental bony defect, the chance of leaving it in place was usually taken, even though it had no soft-tissue attachment. Fragments of bone totally devoid of soft tissue were, as a rule, small fragments of cortical bone, which made up only a relatively minor portion of the bony circumference at the level of the fracture.

The policy of removing totally separated fragments of bone from the wound had a sound basis. It was repeatedly observed in general hospitals in the earlier months of the war that when compounding wounds, without soft-tissue deficits, failed to heal within a few weeks, exploration of the depths of the wound was likely to reveal totally loose fragments of bone which were acting as sequestra. For this reason, delayed healing and nonhealing were particularly frequent in compound fractures of the tibia, in which fragments of cortex were often indriven into the medullary canal and remained in that location until they were removed surgically.

FRACTURE MANAGEMENT

The management of compound fractures at initial wound surgery was limited to the correction of gross malposition. Splinting was applied only for transportation purposes (p. 39). Definitive reduction was postponed until the reparative stage of surgery, which was carried out in the fixed hospital. There were the following sound reasons for this policy:

1. Initial wound surgery was usually performed in an operating tent in a forward hospital, often with the wounded man lying on the same litter on which he had been brought into the hospital (p. 71). Neither environment nor circumstances were conducive to the accurate reduction of fractures.

2. Roentgenologic controls, which are essential for accurate fracture reduction, were not feasible in evacuation hospitals.

3. Even if precise fracture reduction could have been obtained under these unfavorable circumstances, reduction would likely have been lost during application of the plaster cast.

4. Even if precise reduction could have been maintained during the application of the cast, displacement of the fragments would have been almost inevitable after the cast had been split or bivalved, as was required in forward areas, to guard against circulatory impairment during transportation.

5. The early experience in the North African theater had shown that the use of internal fixation and of skeletal fixation in casts as primary procedures in forward hospitals was attended with a high incidence of infection and extremely unsatisfactory end results.

6. The limited personnel in forward hospitals did not warrant the expenditure of time and effort which would have been required to reduce compound fractures properly. The delays thus entailed, in fact, might have put other wounded men awaiting surgery in jeopardy of life as well as of limb.

POSTOPERATIVE REGIMEN

The postoperative regimen after initial wound surgery consisted of standard measures, with additional blood replacement as necessary. Casualties with compound fractures of the femur and other serious injuries often required additional transfusions. The fingers or toes were inspected at regular, frequent intervals, to evaluate the circulatory status of the injured part, so that bandages and casts could be loosened if any vascular impairment became evident. Repeated inspection was also necessary to detect early signs of gas-bacillus infection, which readily developed in limbs which were the site of compound fractures associated with vascular damage. Finally, repeated inspections were necessary to detect early evidence of continuing or recurrent hemorrhage.

EVACUATION

The soldier with a compound fracture was held in the evacuation hospital after initial wound surgery only long enough for him to recover from the

immediate effects of operation and for the surgeon who had operated on him to be certain that he could be transported safely to the rear. A casualty with an injury of a bone or joint generally became transportable within 24 to 48 hours. His transportability was determined not only by his actual status but also by certain external considerations, such as the tactical situation, the mode of transportation available, the distance to be traversed, and the number of casualties to be moved. If there was any doubt at all about the soldier's status, it was usually the policy to keep him in the forward hospital a day or two longer, particularly if it seemed that the transportation time might be unduly prolonged by delays at airfields or other holding points or for other reasons.

Part III. The Reparative Surgery of Compound Fractures

Under the concept of reparative surgery as it developed in the Mediterranean theater, surgery of some kind was indicated on every casualty with a compound fracture as soon after his arrival at a fixed hospital as he could be properly prepared for the operation. The procedure, depending upon the necessities of the special case, was excisional, reparative, or both. This concept represented an entirely new development of World War II.

Four to seven days after wounding was regarded as the optimum time for the reparative stage of wound surgery, and particularly for the closure of a compounding wound, though a maximum of 10 days was still within permissible limits. Operation within these time limits was a perfectly practical objective. It gave time for the transfer of the patient from an evacuation to a fixed hospital; for the proper evaluation of his status after he had arrived; and for preoperative preparation, including roentgenologic examination and blood replacement. In a series of 188 compound fractures treated during a push period at the 23d General Hospital during the breakout from the Anzio beachhead, the average time between wounding and reparative surgery was 8.3 days. This was a usual, not an exceptional, accomplishment.

From the physiologic standpoint, the time lapse of 4 to 7 days between initial and reparative surgery allowed for the sequestration of bits of residual devitalized tissue which had been overlooked or which could not be excised at initial wound surgery. By the end of this interval, it was possible to make a decision concerning the viability of questionably devitalized tissue which had been deliberately left in situ at the first operation. It was not too long a time to permit further debridement, if it should be indicated, before infection could become established. Purulent exudate formed by the decomposition of dead tissue would not yet have had time to exert a locally necrotizing action, and heavy granulation tissue would not yet have formed and fixed in position the deep and superficial soft parts. Finally, this interval was within the golden period for the management of fractures. It was too soon for them to have become fixed by callus formation, and they were still amenable to closed or open manipulation.

PREOPERATIVE PREPARATION

Roentgenologic examination.—New roentgenograms were made as soon as the casualty was admitted to the general hospital. The films made in the evacuation hospital were supposed to travel with the patient, but this rule was not always observed. Even when they were available, however, they were used only for comparison, as they had been made before initial wound surgery, during and after which conditions were likely to have changed. More recent roentgenograms permitted an accurate appraisal of the position of bony fragments, the precise loss of bone, and the location of any retained foreign bodies.

Blood replacement.—Secondary anemia, often of a considerable degree, was present in a large number of the casualties with bone and joint injuries when they were received at fixed hospitals. This was in spite of the generally adequate use of blood in the forward hospital. A series of 138 fractures of the long bones treated at the 23d General Hospital well illustrates this point. Thirty-three patients (24 percent) had hematocrit values under 30. Eighty others (58 percent) had values between 31 and 40, and only 25 (18 percent) had values of 40 or higher, the desirable level for the reparative operation. Only 2 of the 38 patients with fractures of the femur fell into the 40 or higher group. In another series of 166 fractures of the long bones observed at the 21st General Hospital, the proportions were substantially the same: 37 casualties (22 percent) had hematocrit readings under 30, and only 31 (19 percent) fell into the group with readings regarded as safe for operation without further preparation.

Since operation with low hematocrit levels would have introduced a completely preventable risk, the correction of secondary anemia was the first step in preoperative preparation. Transfusions were given, as a rule, until the desired level of 40 or better was reached. The copper sulfate falling-drop technique proved a simple and satisfactory method of determining this value as well as the total serum-protein value.

Preoperative requirements were roughly calculated as 500 cc. of whole blood for each 3 to 4 points of deficit on the hematocrit reading or for each 0.9-gm. percent deficit in hemoglobin. Except when hemorrhage created an emergency, which was not often in a fixed hospital, the total volume of blood administered in a 24-hour period did not exceed 1,000 cc.

Additional blood was also given as indicated while the reparative operation was in progress as well as during the postoperative period. The principles of administration were the same, regardless of the location of the injury. On the other hand, the necessity for blood replacement was usually far greater in certain fractures, especially fractures of the femur (p. 68), than in others.

No absolute proof can be adduced to show that such intensive blood replacement was necessary for good results. There is, however, a good deal of indirect proof. More liberal transfusions became the practice at about the

same time that penicillin became available and the program of reparative surgery in compound fractures came into general use. Results in these injuries were greatly improved after this threefold plan of management was instituted, though it is naturally impossible to assign credit for the improvement to any single phase of the program. The risk of prolonged anesthesia and of a long and taxing operation was naturally far less in a patient whose anemia had been corrected. It was also the general impression that casualties who had received liberal blood transfusions were much less likely to suffer from chronic wound infections and much more likely to show prompt healing of wounds than those in whom this measure had been omitted. The postoperative course was also always much smoother in patients who had received ample transfusion therapy.

Antibiotic therapy.—Before the spring of 1944, when penicillin became generally available, it was the policy to continue in the fixed hospital the sulfa drug which had been given in the forward hospital. The same policy was followed with penicillin. The surgeons in the general and station hospitals had had the benefit of the teachings of Maj. Champ Lyons, MC, in the proper use of penicillin after it had become available for use in battle casualties. As a result, this agent was always used as an adjuvant to surgery in an effort to provide a wider margin of safety for the aggressive surgical measures of reparative surgery.

Penicillin therapy initiated in a forward hospital was continued in the general hospital in all wounds involving the bones and joints. It was also used after operation until wound healing was well on the way to completion. This was usually 5 to 10 days after the reparative operation. If drainage from the wound persisted, penicillin was usually given for a longer period.

TECHNICAL CONSIDERATIONS

Reparative surgery could not be undertaken unless holding policies were such that the casualty could be kept at bed rest in the same hospital until healing of the wound was complete. When the injury was a compound fracture, this requirement also implied healing of the fracture to a stage at which transportation could safely be permitted. The early experience in the theater had shown that the transfer of the wounded from one hospital to another while sutures were still in place after delayed wound closure and while the wound was still unhealed, was always hazardous and could be attended with serious complications.

All reparative surgery was performed under general anesthesia, in an operating room set up for any type of surgery which might be indicated. This meant that instruments and equipment were available for skeletal traction and internal fixation, as well as for the repair of soft-tissue defects by suture or by graft.

The plaster cast and dressing applied after initial wound surgery were not removed until the patient was on the operating table and fully anesthetized.

This practice was an important feature of the reparative stage of military wound surgery for several reasons, as follows:

1. A fundamental concept of the staged management of combat-incurred injuries was that every wound required some additional surgery, either further debridement or closure of the wound by suture or skin graft, after initial surgery. Reduction of the fracture was also necessary, since fracture management was not a function of forward hospitals (p. 80).

2. Since these procedures had to be carried out in the operating room, under anesthesia, there was no reason to subject the patient to painful dressings on the ward or to the risk of hemorrhage.

3. The risk of secondary contamination on the ward was avoided by the practice of removing in the operating room the cast and dressings applied after initial surgery in a forward hospital.

4. This practice conserved the time and effort of medical and ward personnel.

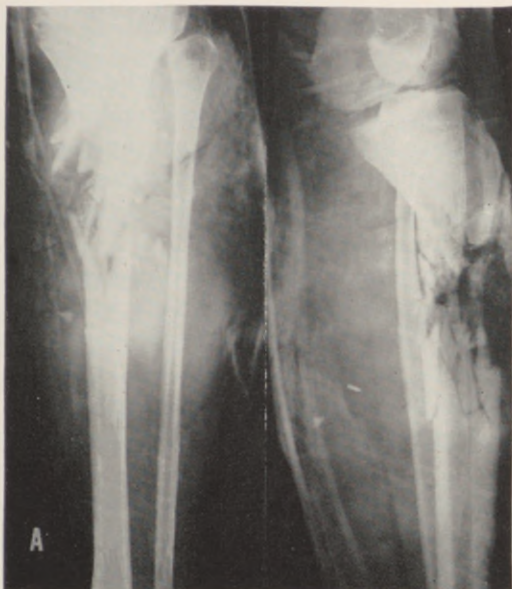Because of the varieties of injuries encountered, it was not possible to recommend a step-by-step technique for the reparative surgery of compound fractures. The operation, however, always followed a definite plan.

Appraisal and Revision of the Wound

Wound revision was conceived of as an extremely careful completion of excisional surgery, to remove tissue that might lead to suppuration. The entire wound, including the fracture site, was exposed by gentle retraction and explored to verify the adequacy of initial surgery. Incisions were enlarged, if necessary, to facilitate exposure. Any remaining foreign material, accessible foreign bodies, totally detached fragments of bone, or devitalized soft tissue was removed. Old blood clot was cleaned out. Means of obliterating or draining dead space were considered.

In the clinically clean case, wound revision consisted, at the most, of the excision of remaining tags of devitalized tissue. In compound fractures, however, further excisional surgery was not infrequently indicated. This was particularly true of large, deep wounds, such as wounds of the thigh associated with a compound fracture of the femur.

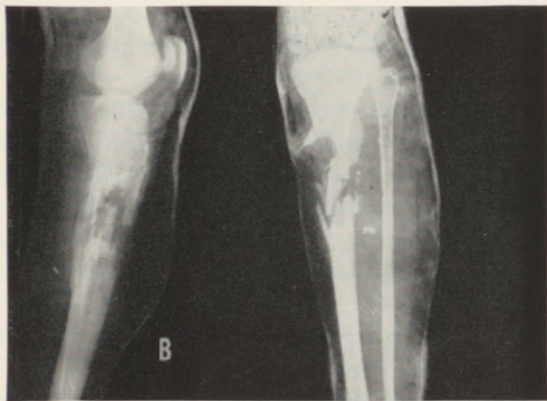Reduction to a minimum of residual devitalized tissue was the keystone of the staged plan of management of battle-incurred compound fractures. Failure to explore the depths of the wound and to follow up the exploration with the necessary excisional surgery was repeatedly shown to account for many of the failures to obtain wound healing when the program of delayed primary wound closure was being tested in the Mediterranean theater late in 1943 and early in 1944. Adequate excisional surgery usually resulted in the prompt subsidence of infection (fig. 29). To perform the kind of surgery necessary, the formerly accepted concept—that operation in an infected field would not only fail in its objectives but might be followed by serious consequences—had to be discarded.



AFIP C-44-243

A. Roentgenograms of left leg made when patient was received in fixed hospital 5 days after wounding; initial wound surgery had been performed 2½ hours after wounding.

B. Roentgenograms made 5 days after the reparative operation. Although further sequestration seemed probable at this time, it did not occur; when the cast was changed 4 weeks later, the wound was clean, drainage had ceased, and there was clinical evidence of bony stability. If this fracture site had been explored when the patient was received in the general hospital, and if the totally detached bone fragments which were acting as devitalized tissue had then been removed, osteomyelitis of the tibia might have been prevented.



AFIP C-44-243

FIGURE 29.—Control of infection in compound comminuted fracture of upper half of left tibia and upper third of right femur by correct excisional surgery. In this case, when the cast on the left leg was changed for the second time in the fixed hospital 18 days after wounding, purulent, foul-smelling drainage suggested an incipient osteomyelitis. Twelve days later, the wound was explored, and several dead, totally detached, in-driven fragments of bone were removed.

Fracture Management

Thorough visualization of the depths of the wound to determine its clinical status permitted full view of the fracture site. Reduction could therefore, for all practical purposes, be conducted, at least in part, as an open operation. Direct inspection was supplemented by study of the roentgenograms taken just before operation. It was thus possible to decide, with all the evidence at hand, the best means of obtaining and maintaining reduction.

The method of fracture management depended upon the circumstances of the special injury. Whenever possible, the ends of the fragments were adjusted under direct vision, after they had been freed from intervening soft parts. Twisted and rotated fragments were aligned. In most cases, the decision was to accomplish reduction either by manipulation and plaster immobilization or by skeletal traction. Internal fixation was employed only under special circumstances.

Internal fixation.—Internal fixation, per se, was by no means an objective of the reparative-surgery program. It was usually neither advisable nor possible because of severe comminution. The program permitted its use, however, with the limitations to be outlined below, when it was indicated to maintain fracture reduction. Fixation was obtained by plating, multiple screws, or wire sutures.

Rigid stabilization of the fracture in reduction by a plate or by multiple screws offered certain advantages: (1) Anatomic apposition and alignment were secured, in anticipation of faster bony union with no deformity; (2) dead space was obliterated and the traumatizing manipulations just mentioned were avoided (fig. 30); (3) handling of the extremity for necessary subsequent wound care was facilitated (fig. 31); (4) early joint motion and muscle exercise, in anticipation of a more rapid return to function, could be permitted; and (5) the management of concurrent injuries which precluded traction and required repeated trips to the operating room was facilitated.

The use of internal fixation was, however, limited by three factors other than comminution. These were (1) the desire to minimize intrawound trauma caused by the operative procedure, which could produce additional devitalized tissue; (2) interference with the covering of all exposed bone cortex with vascular soft parts (fig. 32); and (3) the desire to avoid the periosteal stripping which may be necessary to permit the application of a bone plate and which carries the danger of massive sequestration (fig. 33). Periosteal stripping, which deprives the outer cortex of bone of its nourishment, is an important consideration in surgery in a field known to be contaminated and potentially infected, and this consideration therefore always had to be recognized in the reparative surgery of compound fractures. Practically, if the wound was regarded as clean and if the other factors were favorable, especially the availability of vascular soft parts for covering bone, as in the arm or thigh, there was less hesitancy in stripping sufficient periosteum to permit the required surgery.

If, on the other hand, the wound was regarded as dirty or doubtful, stripping was restricted or avoided.

When the factors that might restrict its use were not unfavorable and the contour of the fracture permitted, rigid internal fixation was frequently employed in order to gain the advantages of a well-reduced and stabilized fracture. Fixation through the compounding wound was at times practical but had the disadvantages of retraumatizing tissue. It also had the disadvantage of placing the metal on bone usually devoid of periosteum, as well as at the bottom of dead space created by excision of devitalized muscle. For plating, therefore, a separate standard approach to the fracture was advisable, to permit covering of the bone and metal by periosteum and vascular soft parts (fig. 34).

In actual practice, when internal fixation was indicated, multiple-screw fixation (by 2 or more screws) was frequently used (figs. 35, 36, and 31). Many fractures by their obliquity lent themselves to this technique. Little or no additional periosteal stripping was required to permit placement of the screws, and intrawound trauma was not excessive. If the fracture, because of comminution, did not permit rigid fixation, one or more wire sutures were sometimes used to hold major fragments in approximation. These could usually be placed without additional periosteal stripping, a factor of particular importance in a wound with recognized established infection. In comminuted fractures with segmental bone loss, wire sutures permitted approximation of the major fragments.

Bony union is a prime consideration in any fracture, and contact of the fragments greatly enhances the chances of union. The shortening of an extremity to overcome segmental loss and obtain contact of fragments by internal fixation of some kind was therefore often a justifiable and indicated procedure that was permissible under reparative fracture surgery (figs. 37 and 38). A nerve-trunk or a muscle-group deficit associated with a fracture at times was the indication for the deliberate removal of attached bone fragments and shortening of the extremity. In this way, continuity of all the severed major structures was achieved, with the objective of maximum functional restoration of the extremity instead of merely a good fracture result as demonstrated by roentgenograms (fig. 39).

There were a number of special types of fractures in which internal fixation was frequently employed at the first operation of reparative surgery, to achieve special objectives. Among them were (1) fractures about joints, such as fractures of the condyles of the femur or the humerus, to permit anatomic replacement of articular surfaces; (2) fractures of long bones deep in muscle tissue, such as fractures of the femoral shaft and upper radius, in which circumstances favored early reattachment of soft parts to the bone; (3) fractures which experience had shown were difficult to hold in reduction by other means, such as fractures of the olecranon and fractures associated with massive loss of soft tissue (fig. 38); and (4) fractures with segmental loss of bone, to achieve contact of the fragments and prevent nonunion (fig. 32).

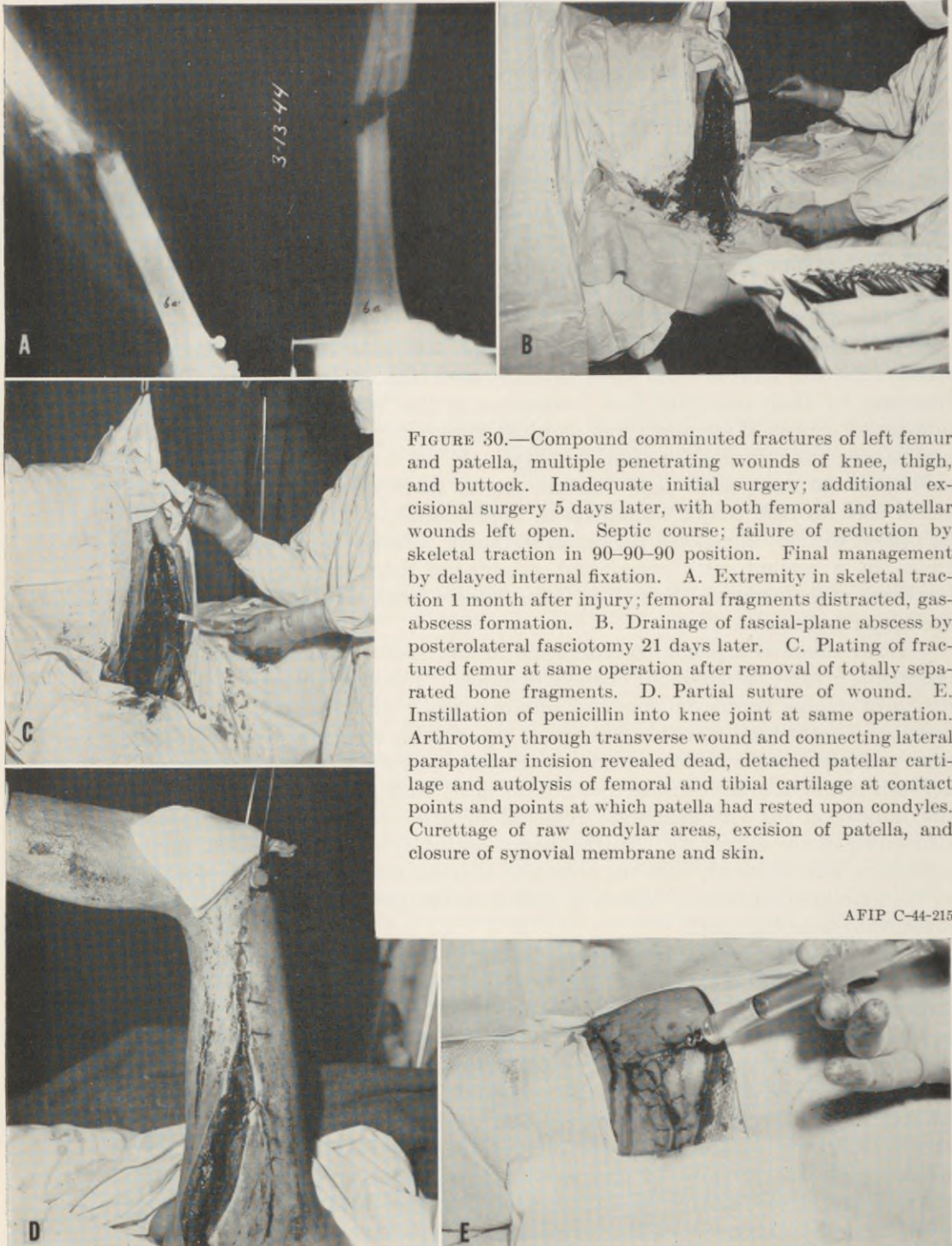
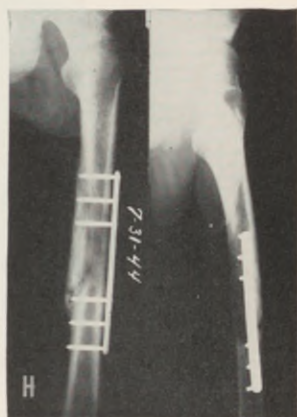


FIGURE 30.—Compound comminuted fractures of left femur and patella, multiple penetrating wounds of knee, thigh, and buttock. Inadequate initial surgery; additional excisional surgery 5 days later, with both femoral and patellar wounds left open. Septic course; failure of reduction by skeletal traction in 90-90-90 position. Final management by delayed internal fixation. A. Extremity in skeletal traction 1 month after injury; femoral fragments distracted, gas-abscess formation. B. Drainage of fascial-plane abscess by posterolateral fasciotomy 21 days later. C. Plating of fractured femur at same operation after removal of totally separated bone fragments. D. Partial suture of wound. E. Instillation of penicillin into knee joint at same operation. Arthrotomy through transverse wound and connecting lateral parapatellar incision revealed dead, detached patellar cartilage and autolysis of femoral and tibial cartilage at contact points and points at which patella had rested upon condyles. Curettage of raw condylar areas, excision of patella, and closure of synovial membrane and skin.

AFIP C-44-215

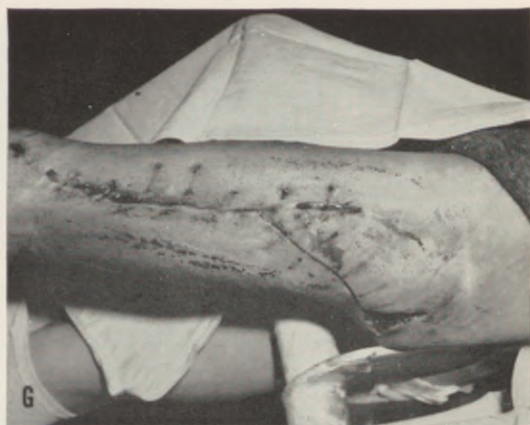
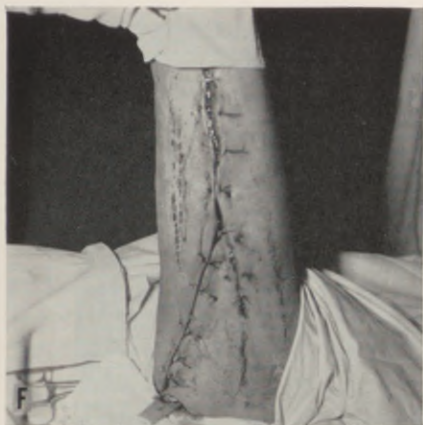
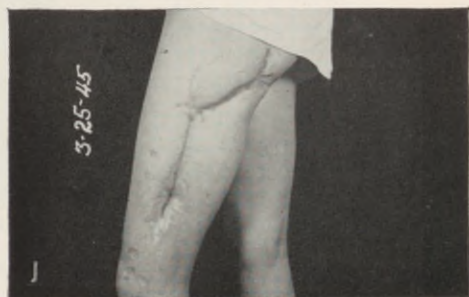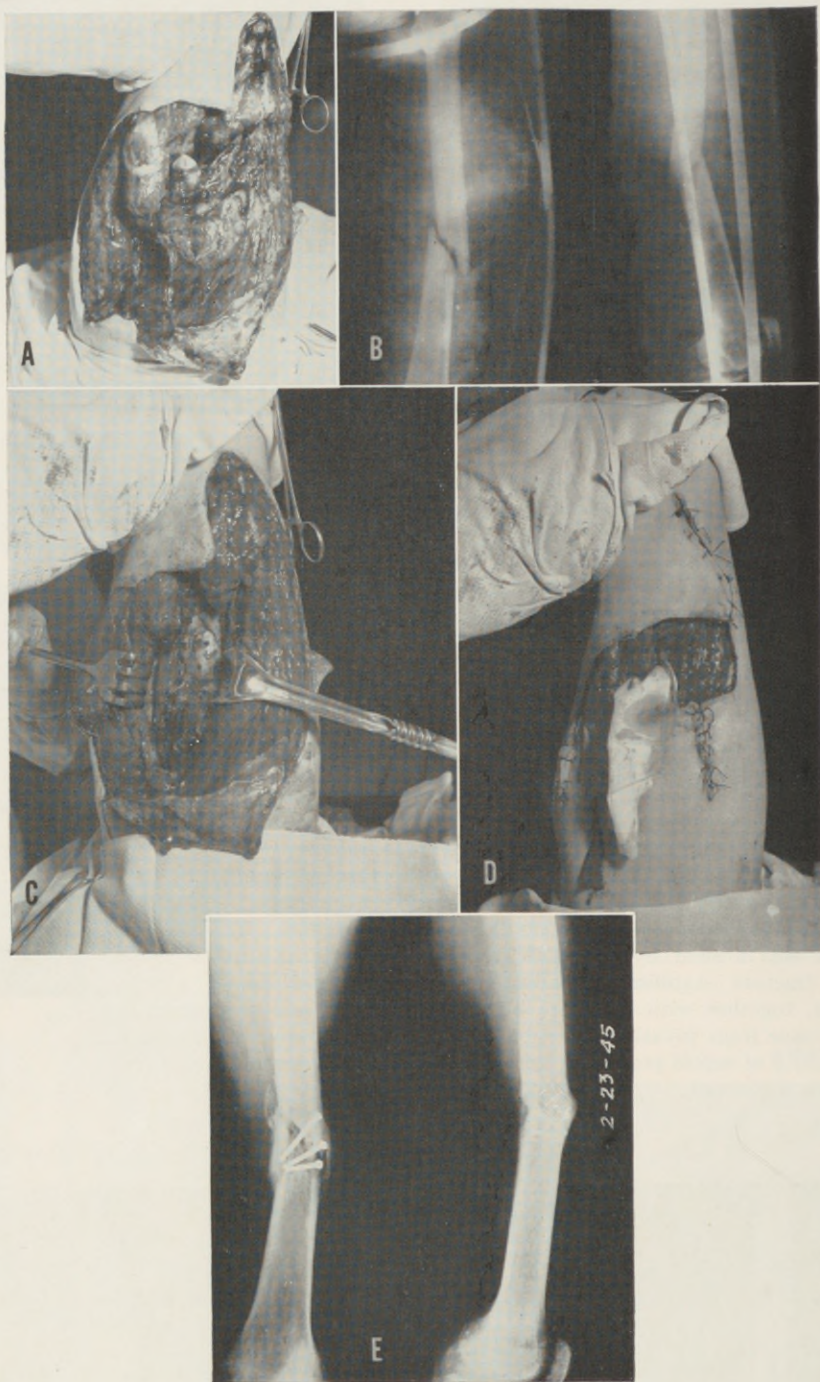
FIGURE 30—Continued. F. Staged closure of compounding wound of femur over small drain, 6 days after operation shown in views B, C, and D. G. Appearance of wound 13 days after reparative surgery and 7 days after staged closure shown in view F. Healing has been obtained, except for small granulating areas in old compounding wound and at proximal end of drainage incision. H. Roentgenograms made 5 months after wounding. It was thought that a small area of sequestrum formation might be present at this time. I. Roentgenograms showing solid bony union and excellent anatomic alinement of femoral fracture, 13 months after wounding. The metal was later removed because of some absorption about one of the screws. Granulation tissue present under plante was curetted. J. Healed wounds of knee and thigh, 13 months after wounding.



This patient, 4 weeks after wounding, presented septic knee joint, grossly septic wound of thigh, unreduced fracture of femur, and gas abscess which could have been mistaken for gas gangrene. He could logically have been considered a candidate for amputation. This gloomy outlook was altered by complete excisional surgery, closure of dead space, fracture stabilization, adequate drainage, and staged wound closures, together with adequate blood replacement and protection of living tissue from invasive infection by systemic therapy. End result was control of septic process in knee and thigh and union of fracture in anatomic alinement.

AFIP C-44-215, C-44-247; U. S. Army photos





AFIP Fd-44-17

FIGURE 31. (See opposite page for legends.)

Internal fixation was preferably avoided when the disadvantages exceeded advantages, as in fractures of the tibia, in which periosteal stripping was hazardous because overlying skin is not a sufficiently vascularized soft part and in which the presence of metal may interfere with even skin closure.

When the indications and advantages were not clear cut, it was thought best to perform wound closure and attempt reduction of the fracture by manipulation or traction. If the attempt was unsuccessful, a planned open reduction and internal fixation could be carried out later, perhaps after healing of the compounding wound. The important point was that if poor anatomic results could be prevented by surgical measures performed on sound principles, results of this kind were no longer accepted for fear of lighting up infection.

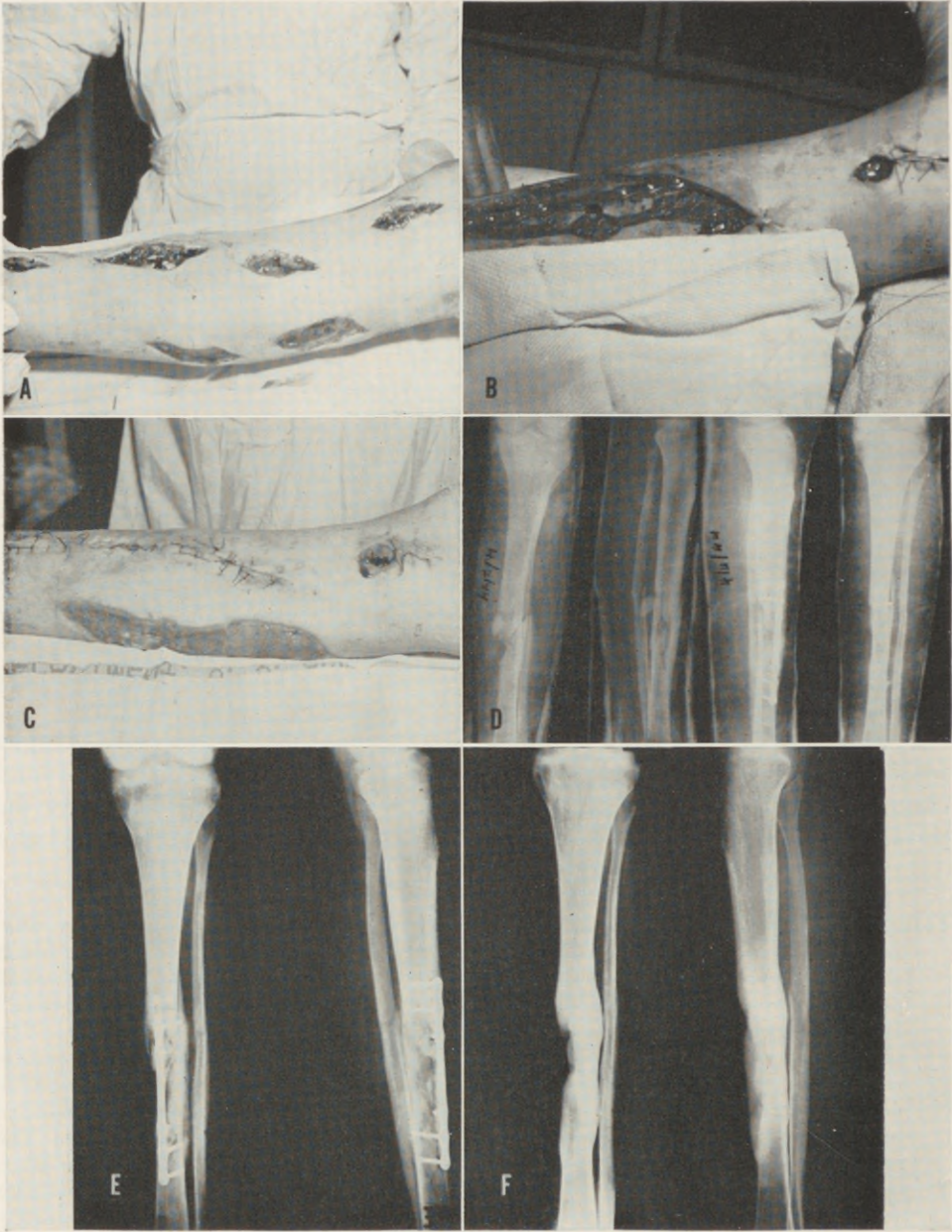
Wound Closure and Drainage

The hazards of an open wound in a compound fracture are the sequestration and sloughing of exposed bone cortex, tendon, and fascia; reinfection at dressings; and slow wound healing by granulation. The advantage of an open wound is continuing drainage from the depths of the wound until healing by granulation has sealed off the fracture site. The gaping wound forms a natural channel for drainage. When the wound is not dependent, however, and infection intervenes, there may be pocketing, puddling, or pooling of purulent exudate in the fracture site or adjacent fascial planes with continuing local necrosis of the collagenous tissues.

In reparative surgery of compound fractures, the hazards of an open wound were recognized, and an attempt was made to overcome them by wound closure. The need was also recognized for providing a means of egress for the possible breakdown of any residual devitalized tissue not yet separated and of a

FIGURE 31.—Reparative management of massive wound of left thigh with associated compound fracture of femur. A. Massive wound of thigh compounding fracture of femur shown at reparative surgery, 6 days after wounding, with the extremity in the 90-90-90 position. Note the distal end of the proximal bony fragment projecting in the wound. B. Anteroposterior and lateral views of fracture before reparative surgery. The patient was transported in a Tobruk splint. C. Exposure of fracture site by gentle retraction, after which the fracture was stabilized by multiple-screw fixation with minimal periosteal stripping. D. Partial closure of wound, with drainage established by dry fine-mesh gauze inserted into residual dead space about fracture site. The remaining defect probably represents the skin loss at wounding. Ten days later, coverage was successfully effected with a split-thickness skin graft. E. Anteroposterior and lateral roentgenograms made in Zone of Interior hospital 3 months after reparative surgery. The fracture is uniting in excellent position and almost in anatomic alignment.

Internal fixation by multiple screws was selected in preference to other methods in this injury because the huge compounding wound of the thigh would probably have decreased the effectiveness of skeletal traction. Staged operative procedures were necessary to obtain complete wound healing. The contour of the fracture permitted satisfactory stabilization with screws without additional periosteal stripping. (This patient was managed by Maj. Charles M. Henry, MC, 36th General Hospital.)



AFIP C-44-263, C-44-302, (England GH)RC-80, (England GH)RC-84

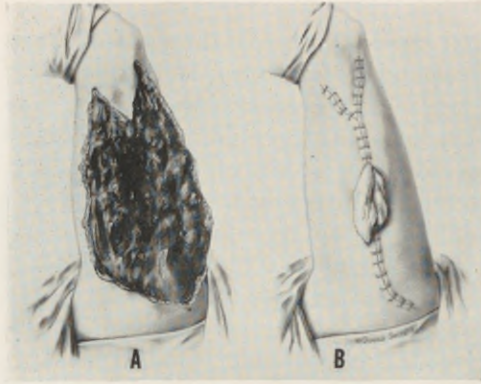
FIGURE 32. (See opposite page for legends.)

contaminated hematoma in unobliterated dead space. In the light of these facts, the complete closure of wounds compounding fractures was justified only when the pabulum for wound infection was nil. A deep abscess about a fracture site underneath a sutured or healed epithelial bridge could produce nothing but irreparable damage. An increased margin of safety was obtained, therefore, by providing drainage, dependent if possible, by utilizing wounds or counter-incisions as indicated. Drains were carefully inserted, so as not to cause tissue necrosis, and were removed between the 3d and 10th day, depending upon the indications, before rigid sinus formation had occurred.

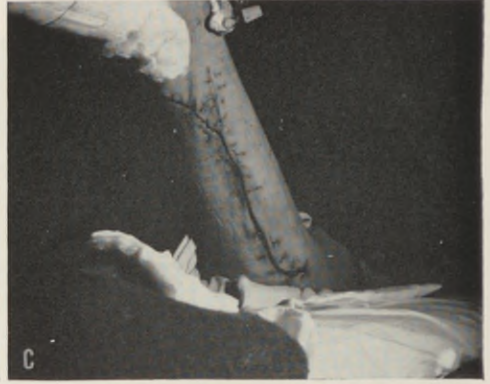The problem of closure of the compounding wound was approached with the major objective of covering exposed bone cortex, tendon, and fascia with healthy soft parts, and with the minor objective of reducing skin defects to a size compatible with adequate drainage. Closure was accomplished, whenever possible, by simple, loosely tied, interrupted sutures. Sliding or rotation of flaps often permitted closure of the wound (fig. 36). It was recognized that soft parts must adhere to the bony cortex to permit revascularization, whereby the dying bone could be absorbed and replaced by new living bone (fig. 40). Otherwise, sequestration was inevitable. Wound closure, therefore, was

FIGURE 32.—Management of compound comminuted fracture of middle third of right tibia and fibula, with multiple penetrating wounds of left leg, by delayed internal fixation. A. Wounded left leg prepared for reparative surgery in fixed hospital 5 days after wounding and initial wound surgery. Note the multiple wounds. B. Stabilization of fracture of tibia through incision connecting anterior wounds. After an unsuccessful attempt to fix the fracture by multiple screws, the periosteum was stripped over a long middle fragment, and stabilization was accomplished by the anteromedial application of a long plate to strut the comminuted fragments. C. Closure of surgical wound. Note that two posteromedial wounds have been connected to form a relaxing incision, to permit closure of the surgical wound and also to provide for drainage. D. Roentgenograms made in fixed hospital before and after reparative surgery. Note hairline reduction of tibia in postoperative films. E. Roentgenograms made in Zone of Interior hospital 3 months after wounding. Stabilization of the fracture had been accomplished, but the plate, with some cortical bone, was still exposed, although there was no evidence of infection. A week later the plate, screws, and four sequestra were removed; firm union of the fracture was found at operation. F. Roentgenograms made 11 months after wounding, showing solid union of fracture.

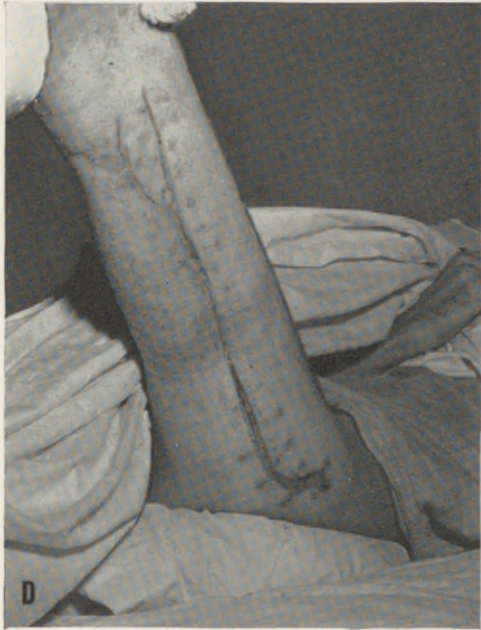In retrospect, this fracture of the tibia might have been adequately stabilized by plating the fibula or might have been managed by skeletal traction in a cast. Either of these methods would have avoided periosteal stripping and the application of metal at a point at which it was likely to interfere with the healing of soft parts over bone. The anteromedial surface of the tibia is not a good location for plating if there is any question of wound healing, though in this case the location of the wounds determined the location of the incision and of the site on which the metal had to be placed.



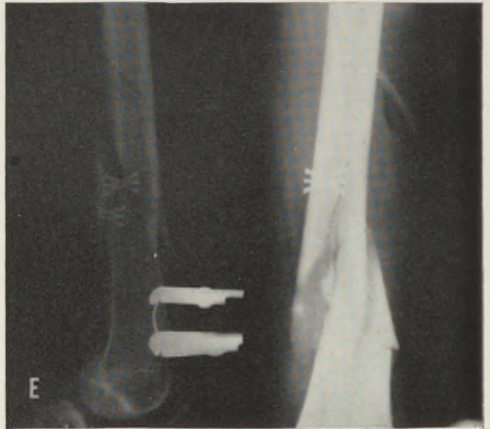
A. Drawing of compounding wound at this time. B. Closure of wound with drainage of residual dead space by dry fine-mesh gauze.



C. Appearance of wound 9 days later. Healing is now practically complete. AFIP Fd-44-18

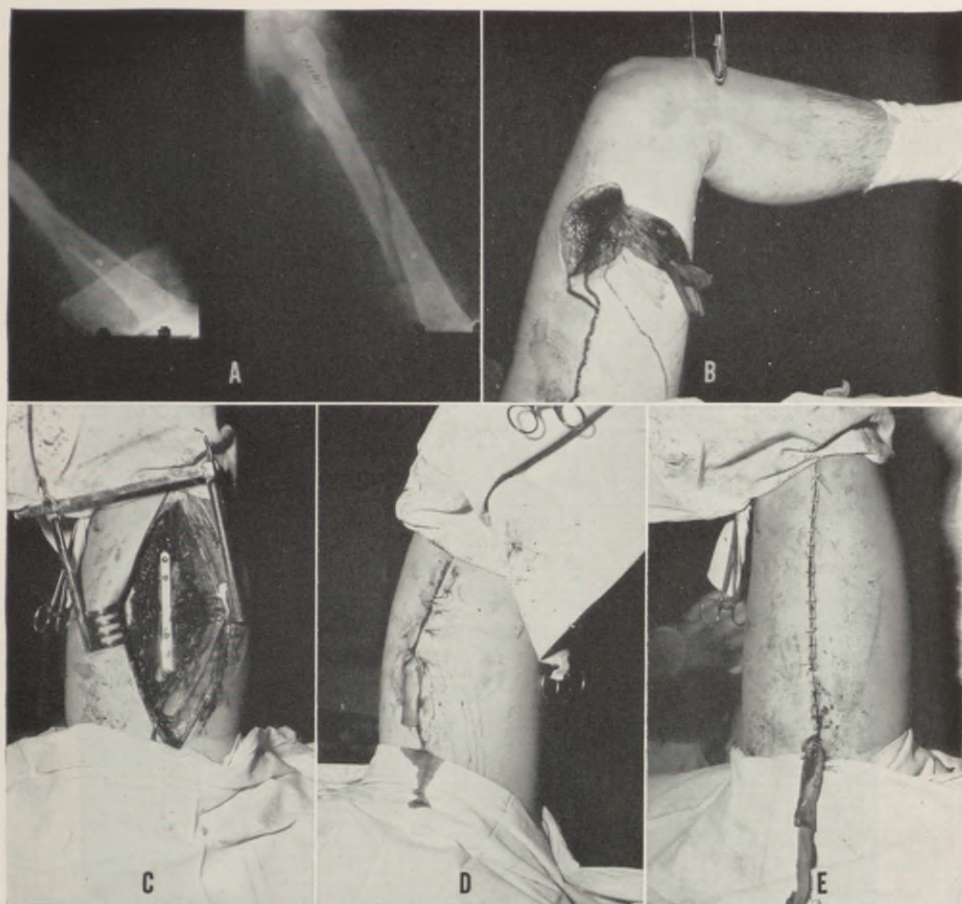


D. Firmly healed wound 1 month after reparative surgery. AFIP Fd-44-18



E. Reduction of fracture by two-wire skeletal traction. Wire lifting distal femoral fragment is visualized, but wire inserted in tibial tubercle for longitudinal traction is not seen. The fracture united in good apposition, length, and alignment. (This patient was managed by Lt. Col. Roderick E. Begg, MC, and Capt. John E. Manning, MC, 46th General Hospital.) AFIP Fd-44-18

FIGURE 33.—Staged management of compound comminuted fracture of left femur, reparative phase. In this case, because of the tactical situation, initial surgery for a very large posterior wound compounding the fracture had to be delayed until 60 hours after wounding. In spite of the long timelag, excisional surgery at the initial operation was thorough, and the wound was quite clean when it was observed in the operating room at the general hospital 9 days later.

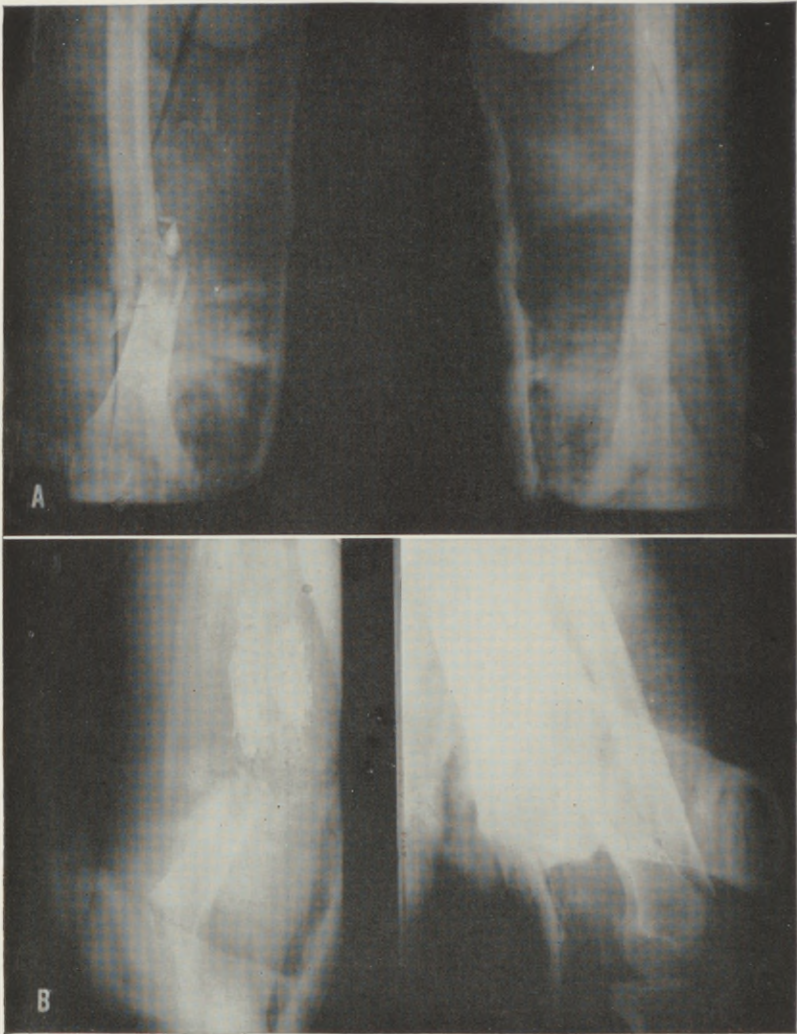


AFIP C-44-210

FIGURE 34.—Management of compound comminuted fracture of middle third of left femur by delayed internal fixation. A. Anteroposterior and lateral roentgenograms of left femur before reparative surgery. B. Anteromedial wound exposed in operating room. The extremity is in the 90-90-90 operating position. C. Stabilization of fracture in reduction through posterolateral incision by bone plate. An additional screw was inserted through the compounding medial wound with drainage. D. Closure of surgical incision with drainage. E. Closure of compounding medial wound with drainage.

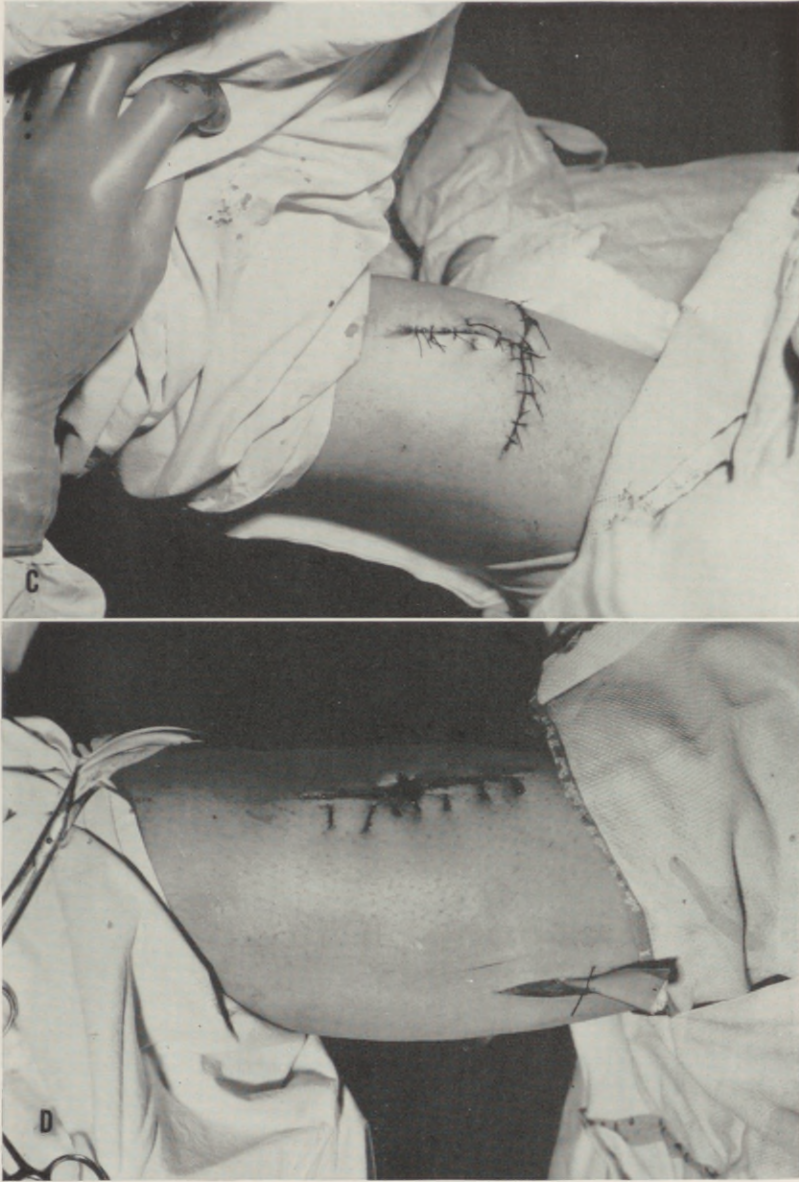
After operation, the extremity was placed in skeletal traction in a Thomas splint with Pierson attachment. Active and passive knee motion and quadriceps exercises were instituted promptly. When the patient reached the Zone of Interior 8 weeks after wounding, the wounds were well healed, the fracture had united in anatomic alignment, and a full range of knee motion was possible. He was returned to duty in a motor pool in a general hospital 12 months after wounding.

The approach to the fractured femur via a standard anatomic plane permitted the bone which was exposed by surgery to be covered by healthy soft parts and also permitted dependent drainage. The fracture was reduced anatomicly and was stabilized, so that the extremity could be handled as necessary for care of the soft-tissue wounds. Management of the fracture by skeletal traction would probably have provided adequate reduction, but joint exercises would have been delayed and hospitalization would have been prolonged overseas.



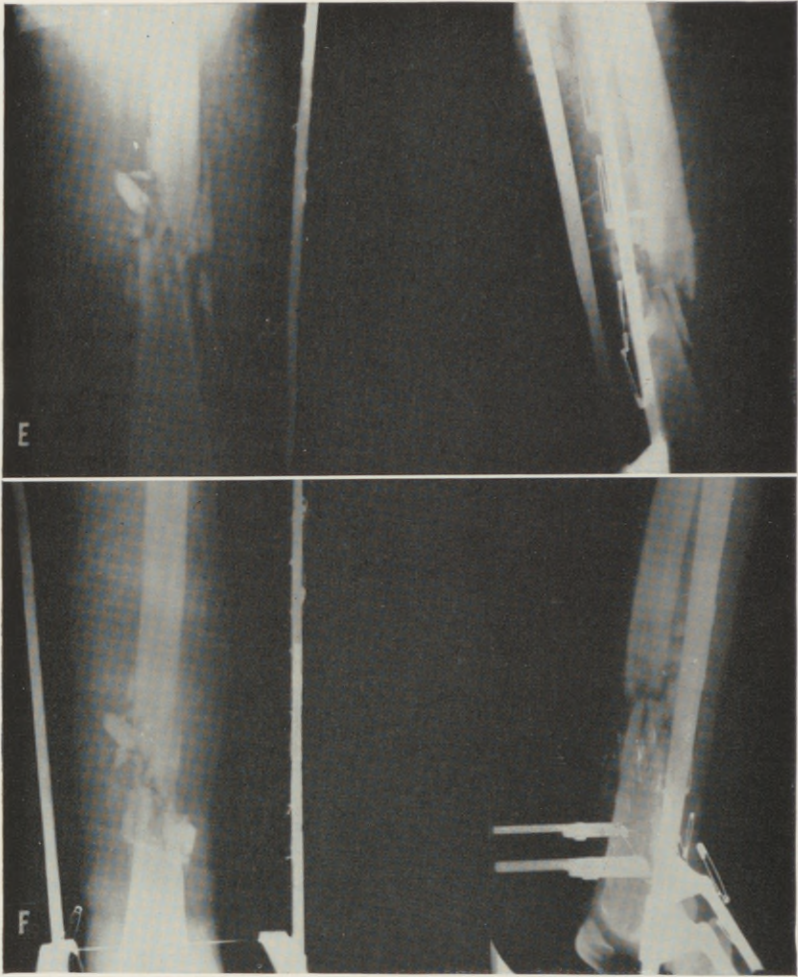AFIP C-44-287

FIGURE 35.—Staged surgery of bilateral compound battle fractures of shaft of femur, reparative phase. This soldier received 1,500 cc. of whole blood in a forward hospital before and during initial wound surgery, 1,500 cc. in the general hospital before the reparative operation, 500 cc. during the operation, and 500 cc. after operation. In spite of these massive transfusions, the highest hematocrit reading after blood replacement was 41. A. Anteroposterior views of each femur in the general hospital, with double hip spica used for transportation splinting still in situ. B. Lateral views.



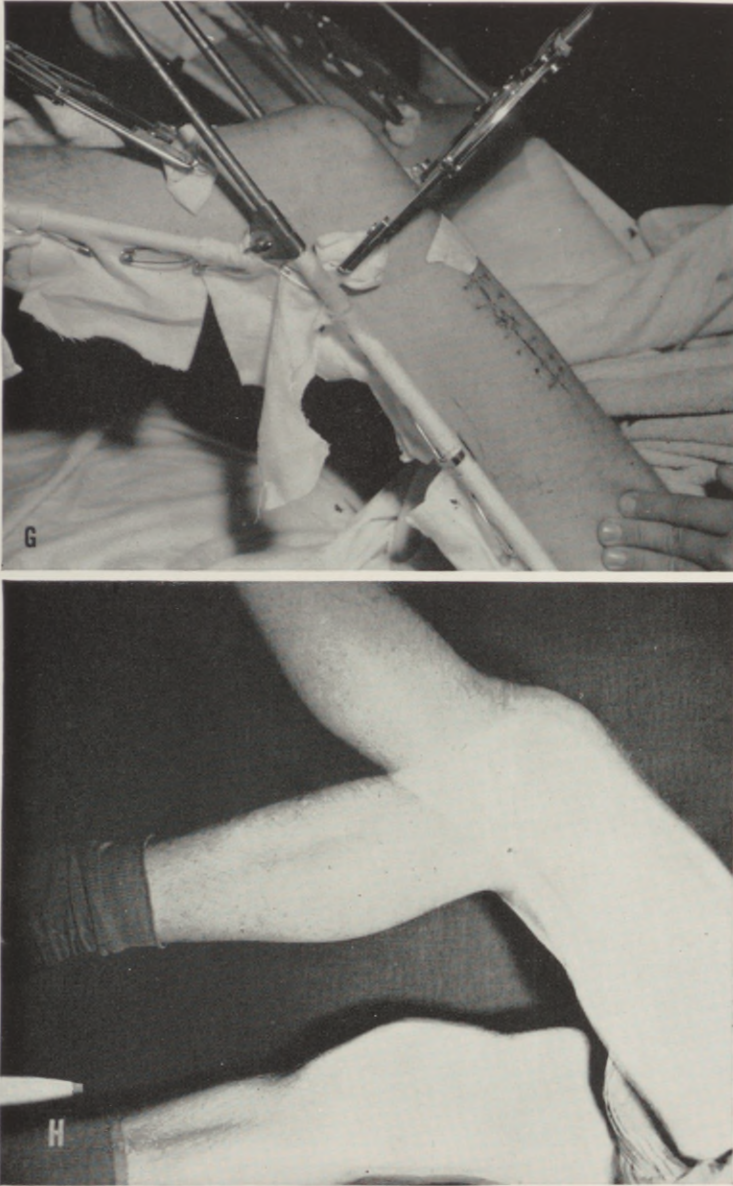AFIP C-44-287

FIGURE 35—Continued. C. Medial stellate compounding wound of left thigh after suture. D. Lateral compounding wound of left thigh after suture. Drainage was maintained for several days through the posterolateral fascial plane.



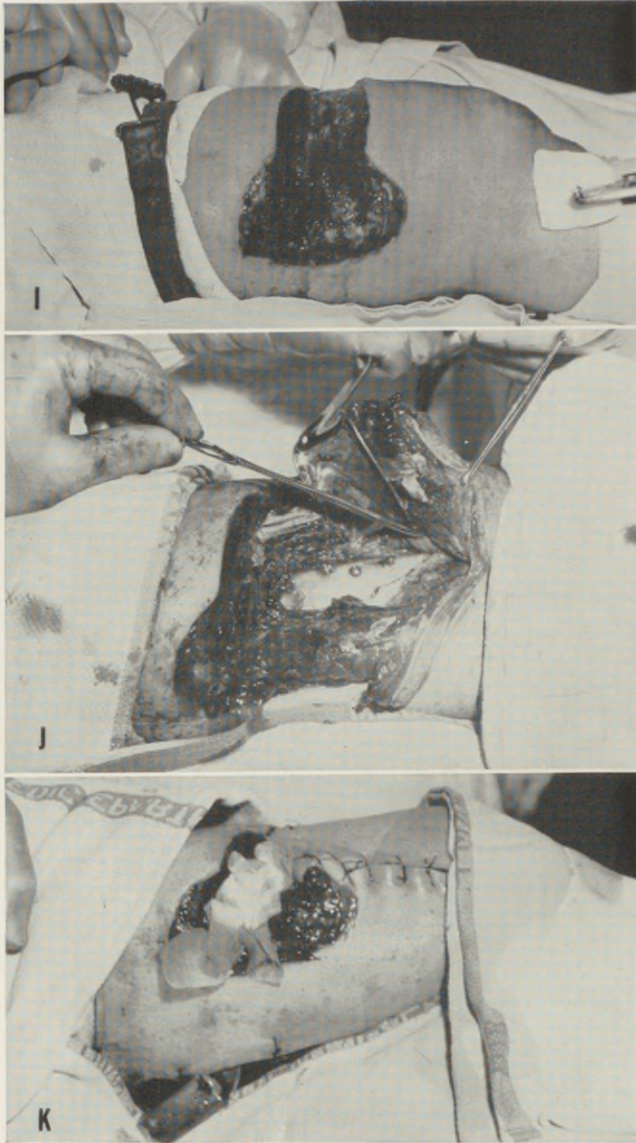
AFIP C-44-287

FIGURE 35—Continued. E. Anteroposterior and lateral views of left femur showing inadequate reduction with tibial pin for traction in Army half-ring leg splint. F. Same as view E, after addition of femoral wire for lift of distal fragment (two-wire traction). The distal fragment is now in excellent apposition and alignment.



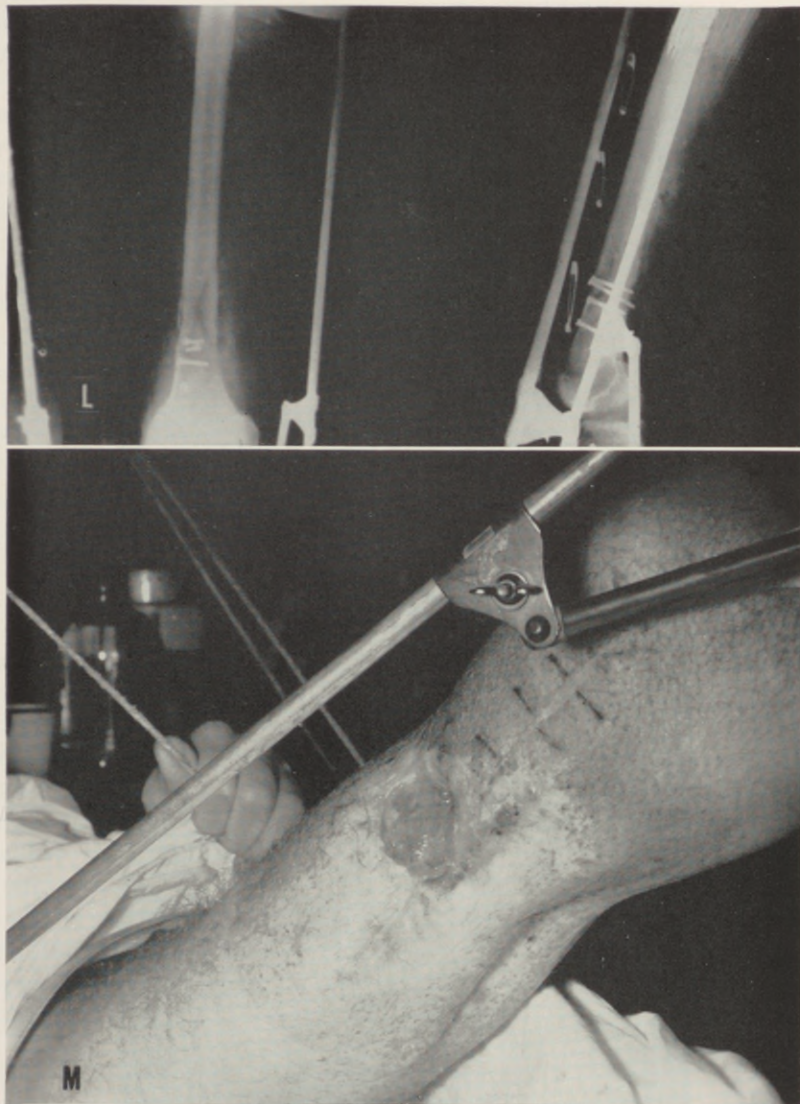
AFIP C-44-315, C-44-287

FIGURE 35—Continued. G. Two-wire skeletal traction applied to left lower extremity. Note sound healing of compounding wound 3 weeks after reparative surgery. H. Active motion of left knee (65° to 70°) 6 months after wounding. At this time, the fracture of the femoral shaft is firmly united, and all compounding wounds are well healed.



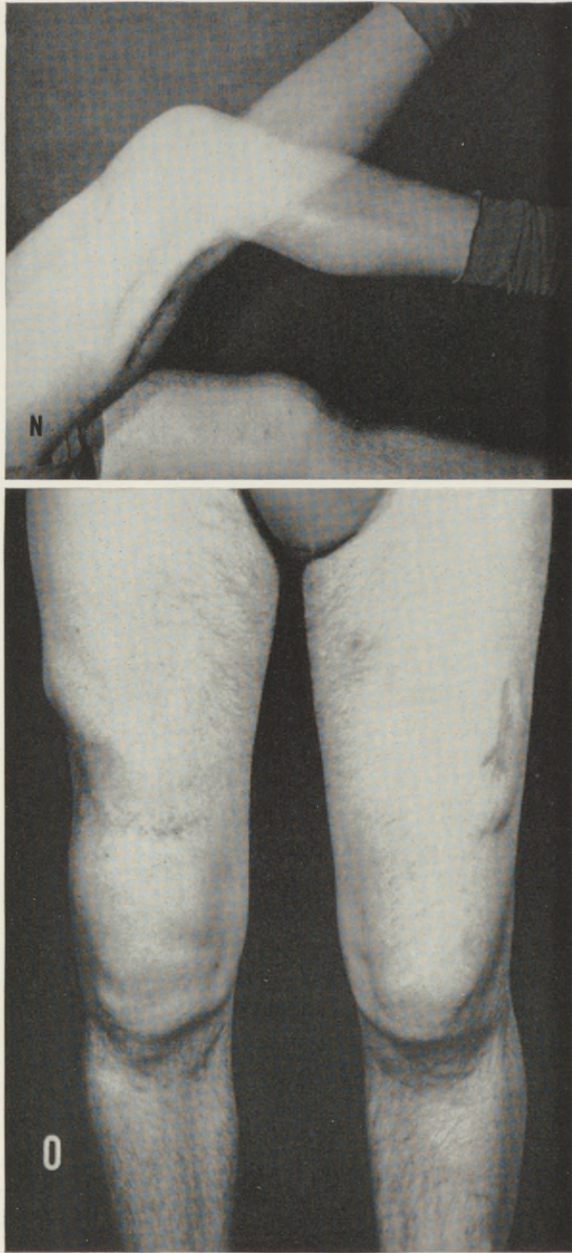AFIP C-44-287

FIGURE 35—Continued. I. Rather severe compounding wound of fracture of right femur. Patient is on operating table, ready for reparative surgery. Note loss of muscle tissue and skin. Note also tourniquet about limb, to reduce further blood loss. J. Exposure of fracture of right femur through incision extending distally from wound. The fracture was easily reduced and firmly fixed internally with multiple screws. K. Partial wound closure, loose packing of remaining defect with dry fine-mesh gauze. Note establishment of dependent drainage through posterolateral fascial plane. Wound healing by granulation had to be accepted in this instance because of the size of the soft-tissue defect.



AFIP CA-44-474, C-44-287

FIGURE 35—Continued. L. Postoperative anteroposterior and lateral roentgenograms showing excellent reduction of fracture of right femoral shaft. The internal fixation was protected by balanced-suspension skeletal traction. M. Appearance of right thigh 8 weeks after reparative operation. All wounds are healed, but the granulating area is not yet scarified. There is no sinus to bone.



AFIP C-44-287

FIGURE 35—Continued. N. Range of active motion in right knee 6 months after reparative surgery. The fracture is soundly united, and all wounds are well healed. O. Anterior view of thighs and upper legs, showing healed wounds, 6 months after reparative surgery. (This patient was managed by Capt. John J. Modlin, MC, 21st General Hospital.)

designed to obviate the hazards of exposed bone cortex, the salvage of which was probably the most important attainment of reparative surgery of compound fractures (figs. 41, 36, 37, and 40).

In actual practice, some compounding wounds were closed with drains of rubber tissue or dry, fine-mesh gauze, which emerged through the most dependent portion of the wound or through a counterincision (figs. 35, 37, and 38). In others, surgical limitations, such as dead space which could not be obliterated or loss of soft tissue, precluded closure of the wound by suture. In these instances, partial closure, so as to protect denuded bone cortex, was often possible (fig. 42). In still other instances, usually following extensive wound revision for dirty wounds, the entire wound was left unsutured in order to provide the advantages of drainage through an open wound (figs. 30 and 34). In such cases, closure of the wound was usually carried out a few days later, if the wound was clinically clean.

If closure could not be undertaken because of loss of tissue, the wound was loosely packed with dry, fine-mesh gauze in the expectation that healing would occur from the depths by granulation (figs. 42, 31, and 35).

POSTOPERATIVE MANAGEMENT

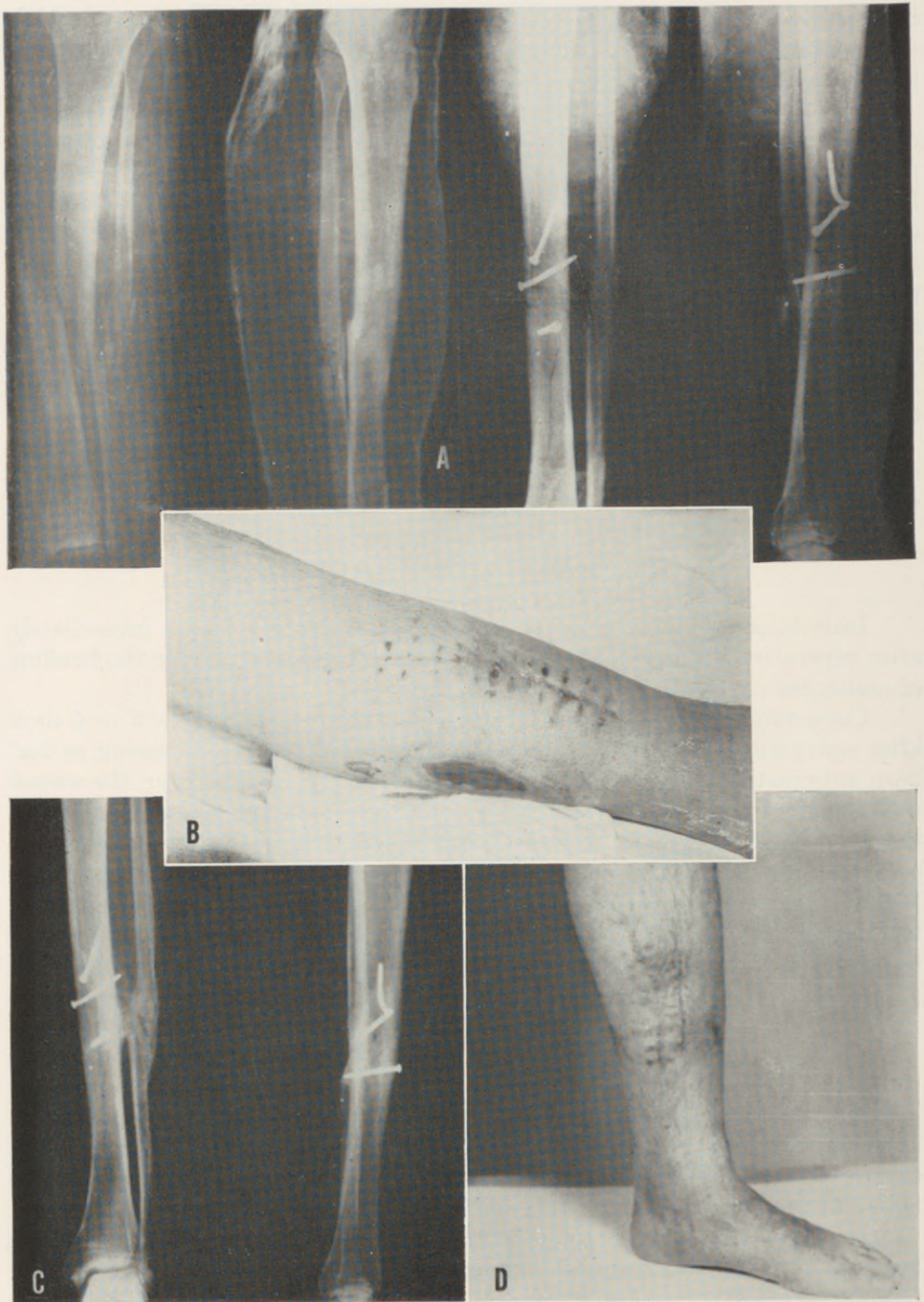Immobilization of the compound fracture was instituted immediately after reparative surgery. Special techniques are discussed under the heading of management of regional fractures (p. 115).

Compounding wounds closed by suture were dressed within 2 to 4 days after operation, to make certain that wound healing was progressing as had been anticipated. When the extremity had been put up in plaster, the wound was reached through a window cut into the cast; care had to be taken, when the window was replaced, to avoid so-called window edema, which could be prevented by using the same amount of padding as had been used originally. Ideally, inspections and dressings were carried out under a strict aseptic technique, including the use of masks to cover the nose and mouth, to reduce the chances of droplet infection. Practically, this ideal was seldom achieved.

RESULTS

The delayed primary closure of combat-incurred wounds was carried out infrequently and in only a limited number of cases in World War I (p. 58). Under the principles of reparative surgery, the program of staged wound closure was established in World War II as a logical and surgically sound policy in wounds of the soft parts and in compound fractures.

It is true that wounds limited to the soft parts are naturally inclined to heal, but they healed faster and with less scarring under the program of reparative surgery. With this method, multiple dressings of open wounds, which were often extremely painful, were eliminated. The chances of secondary infection of granulating wounds were reduced. Scar formation was minimized.



AFIP CA-44-520

FIGURE 36. (See opposite page for legends.)


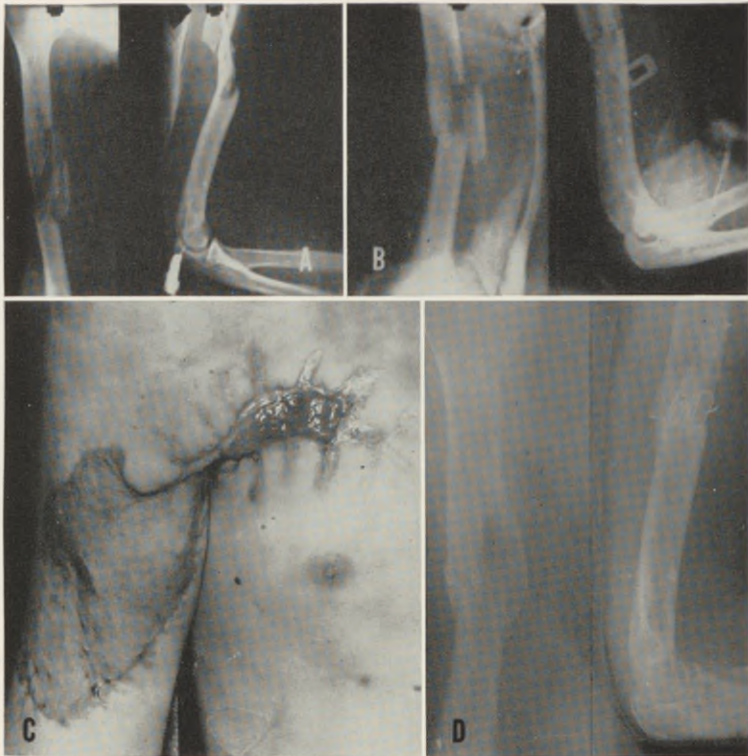


FIGURE 36.—Compound fractures of left tibia and fibula managed by internal fixation of tibia by multiple screws. A. Anteroposterior and lateral views of fractures before and after fixation of tibia, which has been stabilized in reduction by multiple screws through anteromedial wound. Note that the contour of the fracture permits stabilization by this method. In addition, the screws could be placed without significant periosteal stripping, and soft parts were available to cover all exposed bone and metal. The fractures were compounded by anteromedial and posterolateral wounds. B. Healed anteromedial wound. Closure without tension was effected by a posteromedial relaxing incision. The supplementary incision might have been split grafted at the same operation, though this was not done. Drainage was established through the smaller posterolateral wound. Healing by granulation occurred in this wound and in the relaxing incision. C. Anteroposterior and lateral views of fractures 6 months after internal fixation of tibia, showing healing of fracture in anatomic alignment. Note that only 2 of the 3 screws have been effective in stabilization. D. Solidly healed anteromedial wounds 8 months after reparative surgery. Note the shorter, more anterior scar on the leg, resulting from the incision made in a Zone of Interior hospital to remove the screws, because of some tenderness over the head of one of them, before the patient was returned to duty. (This patient was managed by Maj. Joe M. Parker, MC, 21st General Hospital.)



AFIP CA-44-519

FIGURE 37.—Severely comminuted compound fracture in middle third of right humerus associated with extensive loss of muscle and skin over anterior surface of arm and clinical signs of radial-nerve paralysis. Staged management. This patient was admitted to a general hospital 6 days after initial surgery, during the formative phase of the reparative-surgery program. The arm was placed in balanced skeletal traction, and the large wound was dressed in anticipation of healing by granulation. Eight days later, the wound was draining profusely, and adequate reduction of the fracture had not been achieved. The wound was then revised under anesthesia, and all residual devitalized muscle tissue was excised. The radial nerve, damage to which had been suspected, was found intact. Several totally separated fragments of bone were removed, and the segmental defect thus created was overcome by approximating major fragments with a wire suture through the cortex of each fragment. Available muscle tissue and fascia were sutured to cover exposed bone, and a shoulder spica cast was applied. Three weeks later, the granulating defect on the arm was successfully covered with a split-thickness graft. A. Anteroposterior and lateral views showing inadequate reduction of fracture in skeletal traction. B. Apposition of major fragments achieved by wire-suture fixation after removal of totally loose comminuted fragments. C. Healed soft-tissue wound after application of split-thickness graft through window in cast. Access could not be obtained to the wound over the anterior chest wall near the axillary fold, and it was still unhealed when the shoulder spica was removed 10 weeks after reparative surgery. Additional surgery was required in the Zone of Interior because of scar-tissue contraction of the anterior axillary fold. D. Anteroposterior and lateral roentgenograms made in Zone of Interior showing solid healing of compound fracture of humerus.

The incidence of permanent disability was decreased, and the period of temporary disability was shortened.

The program of reparative surgery also proved a sound surgical method in the management of clinically dirty wounds and wounds in which infection had become established. These wounds had always furnished serious difficulties in military surgery. The problem was largely solved by the application of the principles of reparative surgery. By this routine, dirty wounds and infected wounds were promptly converted into clean wounds, and staged reparative procedures could then be instituted.

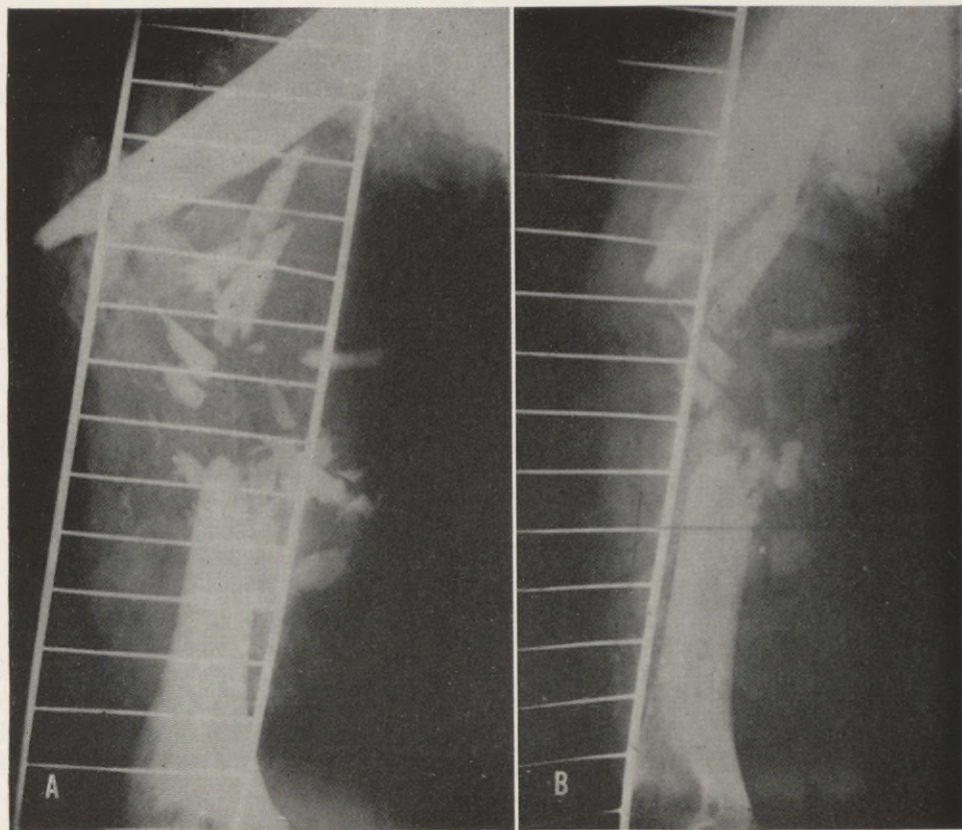
The reparative-surgery program proved as applicable to combat-incurred compound fractures as to soft-tissue wounds. When it was applied, wound infection was reduced. If infection did develop, secondary wound revision was instituted. The aggressive policy (1) of excising the pabulum upon which pathogenic bacteria could feed and (2) of instituting drainage was in sharp contrast to the former plan of waiting for the sequestration of devitalized tissue, including devitalized bone, a plan which was always attended by the further necrosis of living tissue.

The World War II experience supplies complete refutation for the former concept that surgery carried out in an infected field is inevitably followed by generalized infection. So far as is known, no deaths, amputations, or serious systemic sequelae could be attributed to the program of reparative surgery.

Reduction of fractures was greatly improved after the introduction of reparative surgery, for the reason that inadequate and unsatisfactory reduction was no longer accepted if it could be corrected by either surgical or nonsurgical measures. Segmental bone defects, in which nonunion is almost the rule if they remain uncorrected, were also seldom accepted. Internal fixation was chosen on definite indications to maintain anatomic position and permit early joint motion and exercise. In many instances, functional results were thus greatly improved.

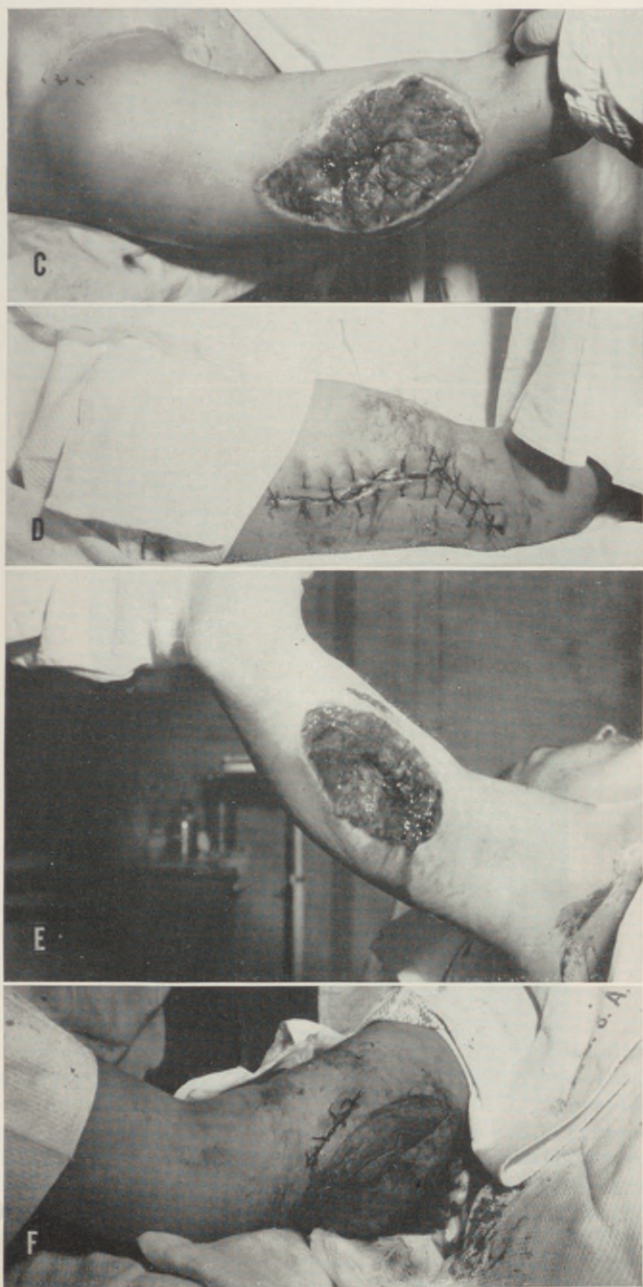The complete healing obtained in most cases following suture of the wound converted the compound fracture into a simple or closed fracture. Even if healing was not complete, the fracture site was often rapidly closed off, so that the same effect was achieved. Small skin defects either were left to heal by granulation or were covered by skin grafts. As a rule, when wound healing was not as good as had been hoped for, the unsatisfactory result could be attributed not to any defect in the surgical program but to errors in judgment as to what was surgically feasible or to errors in surgical technique.

In some cases encountered in the Mediterranean theater, the nature of the injury was such that prolonged drainage from the depths of the wound was inevitable, no matter what method of management was used. These injuries were characterized by numerous partially detached bone fragments and a great deal of associated dead space. The clinical course was usually the same. Drainage persisted until the denuded bone had been revitalized or had sequestered and could be removed surgically. Sinus formation was frequent and persistent when sequestration occurred. When the sinus led to



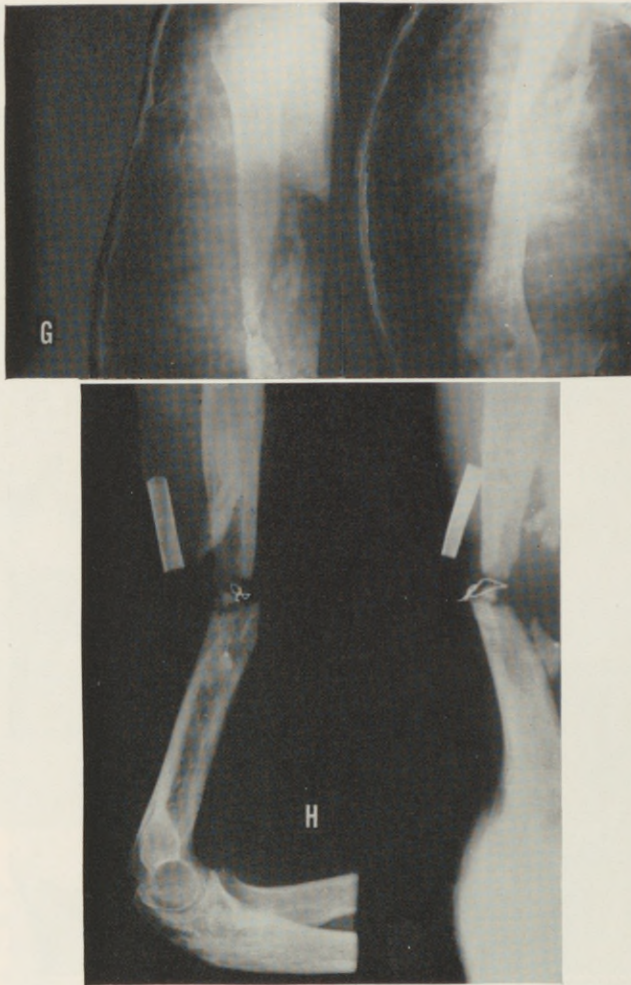
AFIP Fd-44-19

FIGURE 38.—Severe compound comminuted fracture of middle third of shaft of right humerus with loss of more than 4 cm. of bone. Management by approximation of major fragments with single wire suture and wound closure. A and B. Anteroposterior and lateral roentgenograms made on patient's admission to evacuation hospital before initial wound surgery. At this operation, the brachial artery and the median and ulnar nerves were found intact, but the radial nerve was severed.



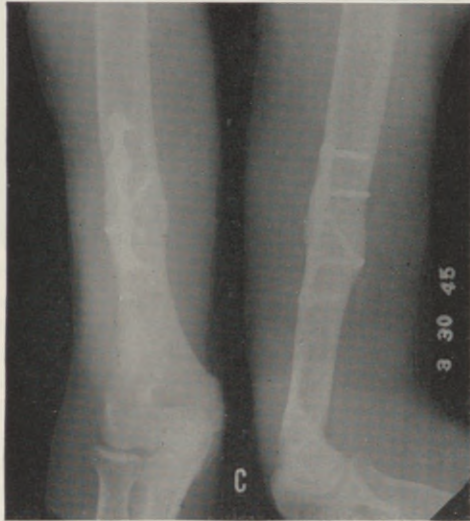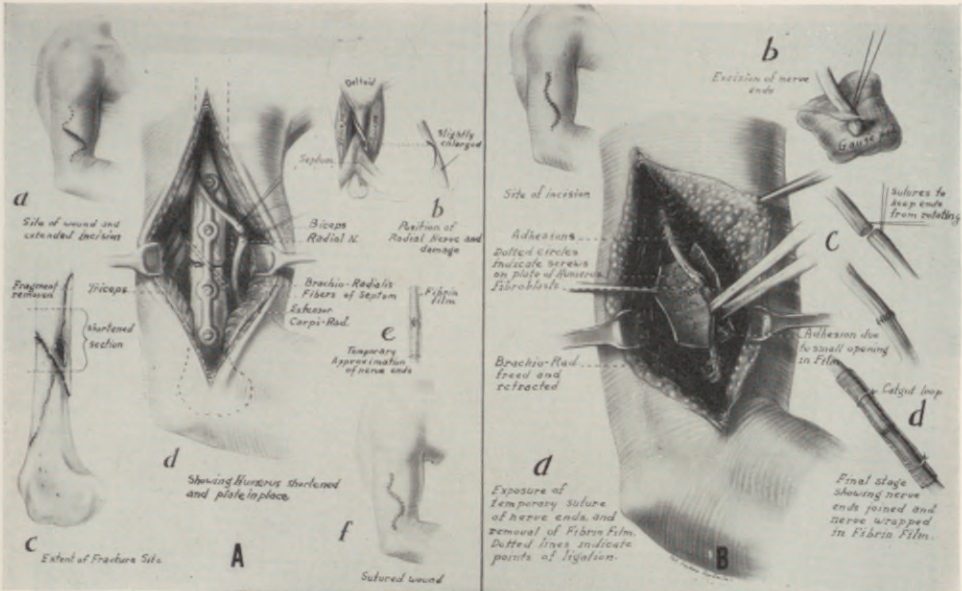
AFIP Fd-44-19

FIGURE 38—Continued. C. Lateral compounding wound seen in operating room in general hospital 9 days later. D. Closure of wound by suture, without excessive tension. E. Large and small medial wounds of same extremity ready for reparative surgery. F. Same wounds at conclusion of reparative surgery. The smaller wound has been sutured; the larger has been covered with a split-thickness skin graft.



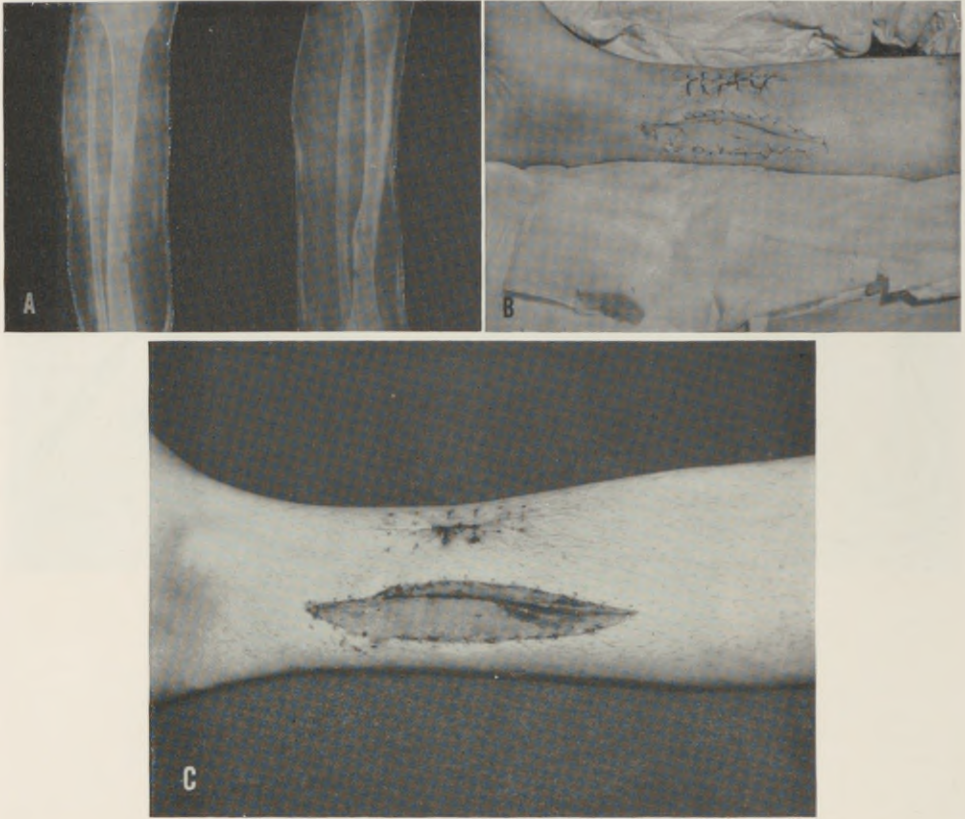
AFIP Fd-44-19, 54-3045-1

FIGURE 38—Continued. G. Anteroposterior and lateral views showing the minimal contact of major fragments obtained by wire suture. H. Same as view G, 7 months after reparative surgery, showing nonunion of fracture. A tantalum cuff encloses the repaired radial nerve. The soft-tissue wounds in this case healed promptly, and the prompt healing greatly facilitated nerve repair. The fracture was finally united after bone grafting several months later. The failure of the attempt to obtain union by use of a wire suture at reparative surgery does not in any way lessen the correctness of the effort. (This patient was managed by Maj. Charles M. Henry, MC, 36th General Hospital.)



AFIP CB-44-56, (England GH) RC-83

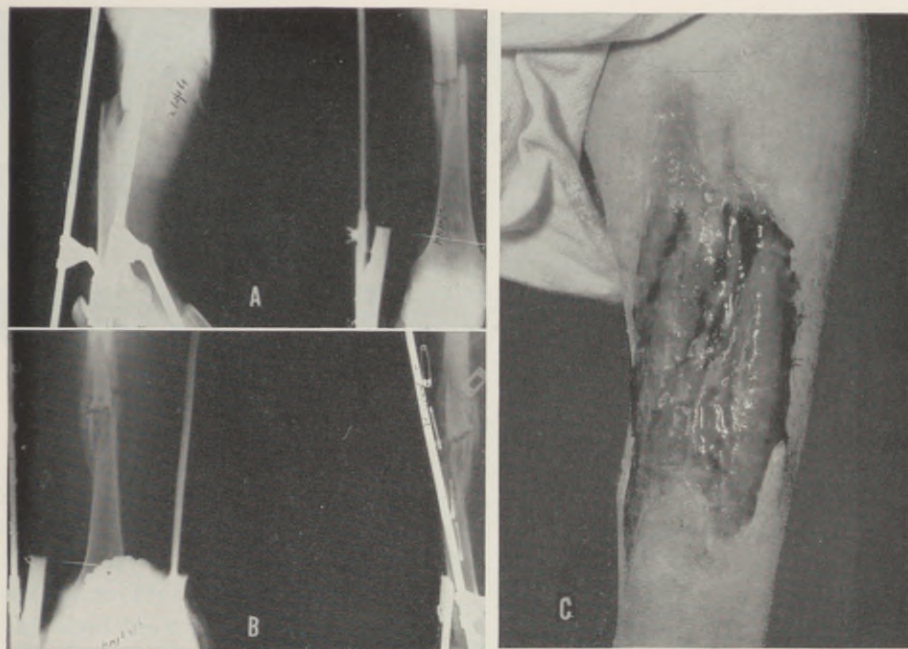
FIGURE 39.—Staged management of associated humeral-radial fracture and nerve injury. Inspection of the radial nerve at reparative surgery 10 days after wounding showed destruction of $1\frac{1}{2}$ inches of nerve tissue. The fractured humerus was shortened by excision of portions of the comminuted fragments; then the major fragments were plated. The nerve ends were united with one suture and wrapped in fibrin film. Prompt healing after closure of wound by suture; definitive nerve suture 16 days later; excellent end result. A. Steps of reparative operation 10 days after wounding. B. Steps of definitive nerve repair 16 days later. C. Anteroposterior and lateral roentgenograms showing united fracture in perfect alignment $6\frac{1}{2}$ months later. At this time, there was evidence of returning function in the radial nerve supply. Orthopedic surgery was performed by Maj. Joe M. Parker, MC, and neurosurgery by Lt. Col. Henry G. Schwartz, MC, 21st General Hospital.



AFIP C-44-216, C-44-286

FIGURE 40.—Reparative management of mildly comminuted fracture of right tibia resulting from penetration of limb by high-explosive shell fragment. A. Anteroposterior and lateral roentgenograms at general hospital 10 days after wounding. The compounding wound had been left open after debridement in a forward hospital. B. Closure of compounding wound at reparative surgery. A long posteromedial relaxing incision permitted the use of a sliding flap and thus permitted closure without tension. The defect created by the relaxing incision has been covered with a split-thickness graft. C. Healed wounds 2 weeks after reparative surgery. Note that the take on the skin graft is about 95 percent. Sound wound healing followed soon afterward. This casualty could be rehabilitated for duty in the theater of operations, which was a rather unusual result in compound fractures of the bones of the leg and one which would have been impossible except under the regimen of reparative surgery. (This patient was managed by Capt. George H. Marcy, MC, 23d General Hospital.)

sequestra that could not be prevented surgically, the outcome had to be accepted as the inevitable result of injury. In these cases, failure of wound healing was attributable to the presence of retained dead tissue and not to bacterial infection per se.

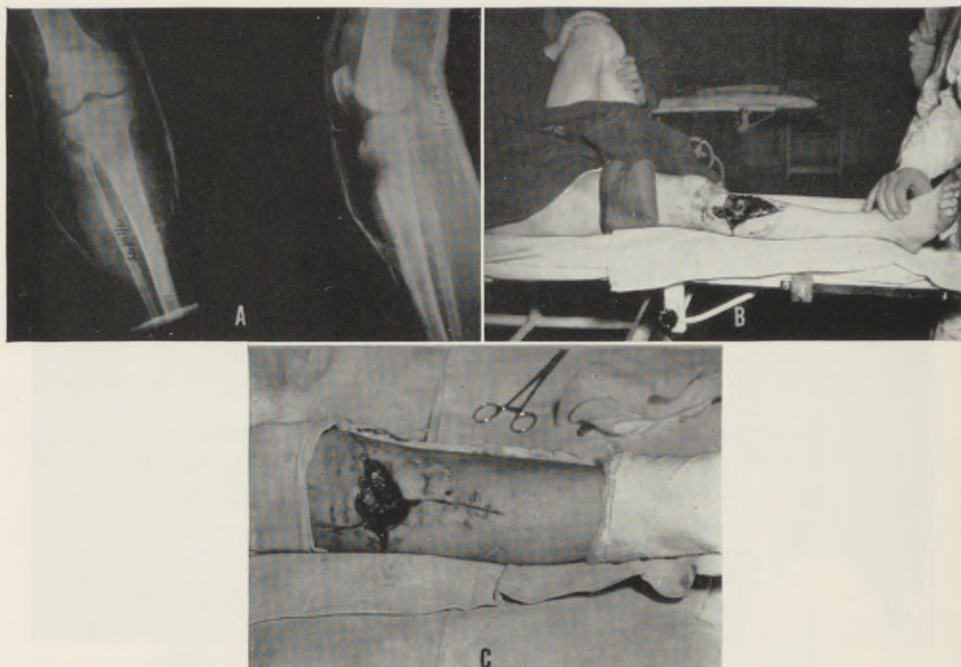


AFIP C-44-273

FIGURE 41.—Management of compound comminuted fracture of shaft of femur by balanced-suspension skeletal traction; sequestration of denuded bone not covered by soft parts. The anterolateral wound compounding the femoral fracture was extensive, and the considerable muscle loss left the femoral fragments exposed for several inches. Reduction of the fracture was carried out in a general hospital shortly after the patient was received, but reparative surgery was omitted. A. Anteroposterior and lateral roentgenograms showing fracture of femoral shaft in traction just before reduction in a general hospital. B. Anteroposterior and lateral roentgenograms showing healed fracture with massive sequestrum formation, 68 days after wounding. C. Wound of thigh 78 days after wounding. Note continued drainage and lack of healing.

The sequestra were eventually removed, and dependent drainage was established, under penicillin protection, but skin grafting was necessary before wound healing was eventually achieved. In this case, early reparative surgery, with closure of the wound over the exposed bone, might have prevented sequestration of the femoral fragments. Wound healing and fracture healing were finally achieved, after delayed reparative surgery. (The case was managed at the 21st General Hospital in January 1944, before the program of reparative surgery of compound fractures had become theaterwide.)

The program of reparative surgery proved again that in the management of combat-incurred compound fractures there is no substitute for surgery. Blood and penicillin were essential adjuvants, but the whole program was based upon the concept that the bacterial flora in an open war wound is of minor



AFIP C-44-225

FIGURE 42.—Management of compound fracture of upper third of right tibia by staged surgery and modified closed plaster technique. A. Anteroposterior and lateral roentgenograms showing defect in upper third of tibia following initial surgery. B. Large compounding wound of soft tissues, with several stellate extensions, shown in operating room in general hospital just before reparative surgery. C. Suture of extensions of wound, so as to cover all exposed cortical bone. The remaining defect was left open, and the modified closed plaster regimen was instituted. When the sutures were removed, 12 days after the reparative operation, through a large window in the cast, the stellate incisions were found well healed.

The remaining defect was loosely packed with fine-mesh gauze, and the window was replaced in the cast and secured with several turns of plaster bandage. The next dressing was set for the period at which the cast would be changed, 4 to 6 weeks after the first dressing, probably after the soldier had been transferred to the Zone of Interior. The modified closed plaster method was used in this case because loss of tissue made complete closure of the soft-tissue wound impossible. In addition, closure would have been doomed to failure because of the underlying dead space caused by the defect in the cancellous bone. It was essential, in this injury, that the exposed cortical bone be covered, and this was achieved by partial closure.

importance compared to the pathologic process itself. By the end of World War II, this concept of the management of combat-incurred wounds had been generally accepted, and the spotlight of attention had been focused where it belonged; that is, upon their surgical management.

CHAPTER V

Regional Compound Fractures

Part I. Compound Fractures of the Humerus, Radius, and Ulna¹

GENERAL CONSIDERATIONS

Compound fractures of the bones of the upper extremity were frequent, as is shown by the experience of two general hospitals which functioned in the Mediterranean theater. These bones were injured in 992 (34.1 percent) of the 2,911 compound fractures treated at the 45th General Hospital during 1944, and in 685 (37.1 percent) of the 1,844 compound fractures treated at the 21st General Hospital over the same period. When the 332 fractures of bones of the hand are excluded, composite figures for the two hospitals show that the bones of the arm and forearm were involved in 1,098 (23.1 percent) of all the compound fractures treated in them during 1944. Of these injuries, 322 were compound fractures of the humerus, and 338 were compound fractures of the radius, ulna, or both bones.

Compound fractures of the long bones of the upper extremity offered a peculiarly attractive field for the application of the principles and procedures of reparative surgery. They are therefore discussed in considerable detail. The management of injuries of the hand is not considered in this volume. These injuries are discussed in detail in the volume on hand surgery.

PROBLEMS OF MANAGEMENT

Certain special problems of management presented themselves in compound fractures of the upper extremity:

1. The major objective of the management of all wounds of the arm and forearm, including all compound fractures, was maximum restoration of the function of the hand. This function varies from the finer precision movements to grasping with strength. It was therefore essential, in addition to repair of the bony framework and skin covering, that the integrity of muscle, tendon, and nerve be restored, as nearly as possible, to its original state or that it be otherwise compensated for, and that early motion, particularly of the fingers,

¹ Data for this section were collected by Maj. Joe M. Parker, MC, and Capt. Francis R. Crouch, MC, 21st General Hospital; Capt. John W. Rovane, MC, 300th General Hospital; Maj. William R. Ferguson, MC, Capt. Robert B. Gottschalk, MC, and Capt. James H. Flynn, MC, 33d General Hospital; and Lt. Col. George A. Duncan, MC, 45th General Hospital.

be instituted, to minimize fixation of joints, muscles, and tendons. The overwhelming importance of function of the hand always had to be borne in mind, therefore, when the management of compound fractures and other injuries of the arm and forearm was determined upon.

2. A severed nerve in the arm or forearm or a severed tendon or tendons in the forearm was sometimes of greater importance than the associated compound fracture or fractures. In the staging of reparative-surgery procedures, however, the repair of nerves and tendons was postponed until the wound had healed and there had been optimal restoration of the bony framework (fig. 39). Nerves and tendons could then safely be repaired through a healed wound. These operations were functions of hospitals in the United States. The necessities of concurrent injuries therefore sometimes determined the method of fracture management and sometimes dictated the plastic procedures which might be necessary to accomplish wound healing in injuries of the upper extremity.

3. Bone loss with resulting partial or segmental defects was not infrequent, particularly in the humerus, and called for special methods of fracture management (figs. 43 and 44; also figs. 37 and 38).

4. Immobilization of the upper extremity is difficult, a circumstance which made maintenance of reduction of certain fractures, particularly those of the humerus and of both bones of the forearm, correspondingly difficult.

5. In spite of the serious problems of management presented by compound battle-incurred fractures of the upper extremity, the favorable factors on the whole outweighed the unfavorable. The richly vascularized muscular sleeve about the whole circumference of the arm and upper forearm predisposed to rapid healing of both wounds and fractures and to minimal infection. Similarly, except in the lower forearm, there is a paucity of dense fascia and tendons and therefore an absence of tissues with poor blood supply and a correspondingly limited resistance to infection. The well-developed muscular sleeve just described facilitated the coverage and revascularization of bones denuded at wounding and further denuded at surgery. Dead space was readily obliterated, and adequate drainage could be secured with equal ease. Maintenance of full bone length in this region was relatively unimportant from the standpoint of future function. Finally, bone and nerve surgery could be performed at the same operation or in stages, according to the necessities of the special case.

GENERAL PRINCIPLES OF MANAGEMENT

Unless serious associated injuries required longer stays in evacuation hospitals, soldiers with wounds of the upper extremity usually reached general hospitals within 2 to 4 days after initial wound surgery. Since blood loss was considerably less severe than in compound fractures of the femur and of the bones of the leg, little time had to be spent in elaborate preoperative preparation. Transfusions in the amount of 500 to 1,000 cc. usually restored the

hematocrit reading to the 40 regarded as optimal before reparative surgery. Most casualties therefore reached the operating room by the 7th day after wounding and seldom later than the 10th day. This meant that practically all surgery could be done within the optimum period. In a series of 147 compound fractures of the humerus, for instance, to be reported later in this chapter (p. 130), reparative surgery was done on an average of 6.5 days after wounding.

A study of peripheral-nerve function was part of the preoperative survey in wounds of the arm and forearm, but final appraisal was made in the operating room, after the cast had been removed and before anesthesia was begun. The status of nerve function could thus be determined with absolute certainty when the extremities were unhampered by supporting casts or dressings.

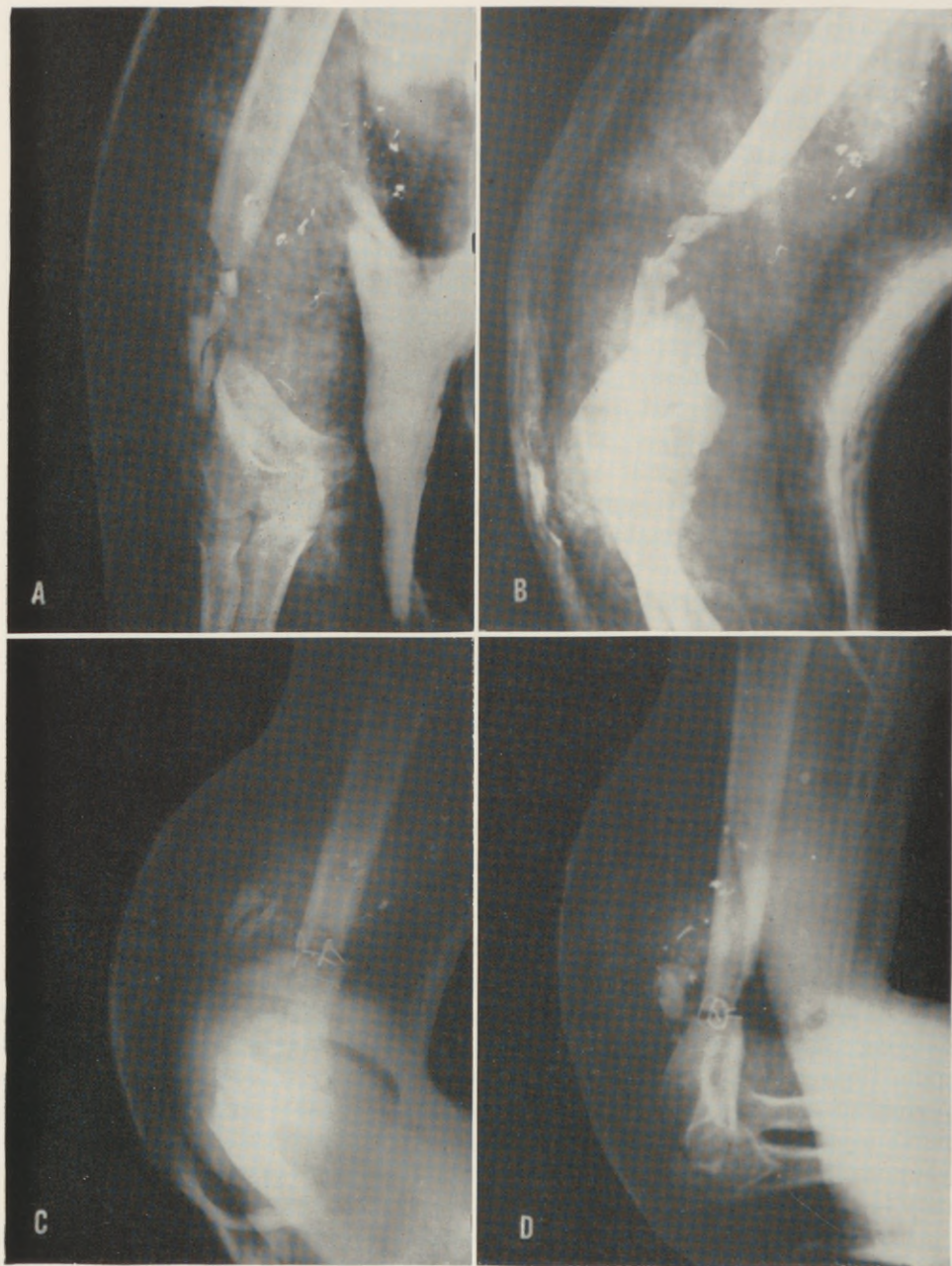Wound management.—Wound management in compound fractures of the upper extremity followed the general principles of reparative surgery. The wound was widely exposed, so that inspection to the depths was possible and the fracture could be fully visualized. Any residual devitalized tissue was excised. Small, totally separated fragments of bone were removed. The decision as to fracture management was made, and internal fixation, if it was the method selected, was carried out.

Whenever possible, the wound was closed by accurate approximation of the soft parts, to achieve obliteration of dead space, coverage of denuded bone, or protection of nerves and blood vessels from possible damage by bone fragments. Buried cotton sutures were employed in one hospital during the last 6 months of the war. Drainage was employed routinely in the first days of the reparative-surgery program. Later, it was provided only on specific indications, which existed in perhaps 70 percent of all cases.

When incomplete initial surgery had resulted in a clinically dirty wound, so that extensive additional excisional surgery was required, closure was usually postponed for several days, to be certain that the wound was clean. Whenever possible in these circumstances, the bone was covered by muscle, in an effort to effect as rapid revascularization of the bone as possible.

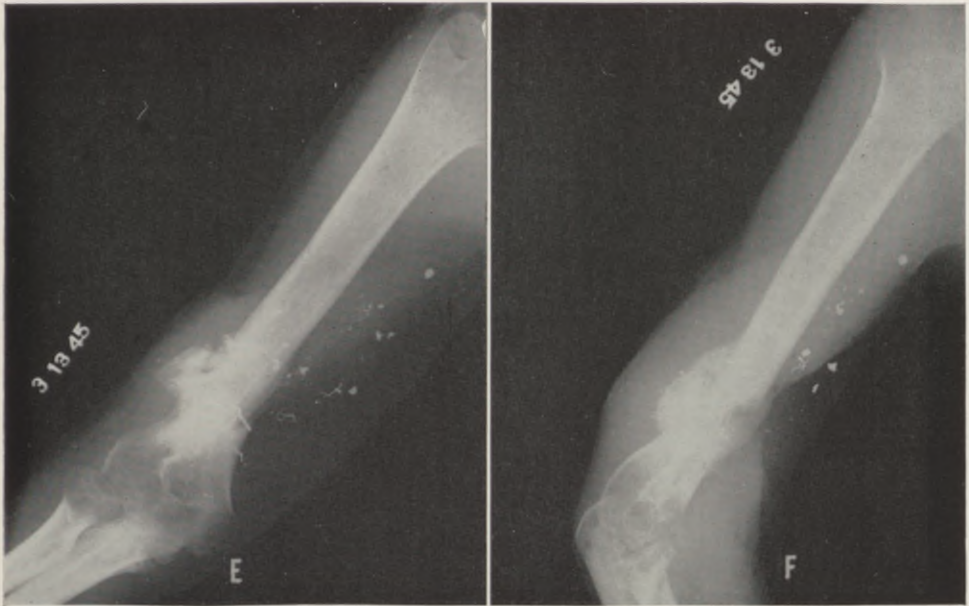
Splinting.—The general principles of splinting were applied in immobilization of the extremity after reparative surgery. All plaster casts, including hanging casts, were trimmed at the proximal palmar crease unless specific indications existed for immobilization of the fingers. Precise splinting, which permitted active motion of the fingers, was provided in associated radial-nerve injuries, so as to avoid continuing stretch of the paralyzed muscles and yet permit a full range of active motion (fig. 45). It was not considered necessary to employ special splinting for median- or ulnar-nerve palsies.

After the early healing phase in compounding wounds of the forearm and immediately after reparative surgery in wounds above the elbow, full and active finger motion was encouraged as part of routine postoperative management. If nerve, muscle, or tendon injuries prevented full and active motion of all the joints of the fingers, the fingers were moved passively many times daily, in order to prevent fixation.



AFIP (Cushing GH) P-1505-A-E, 745

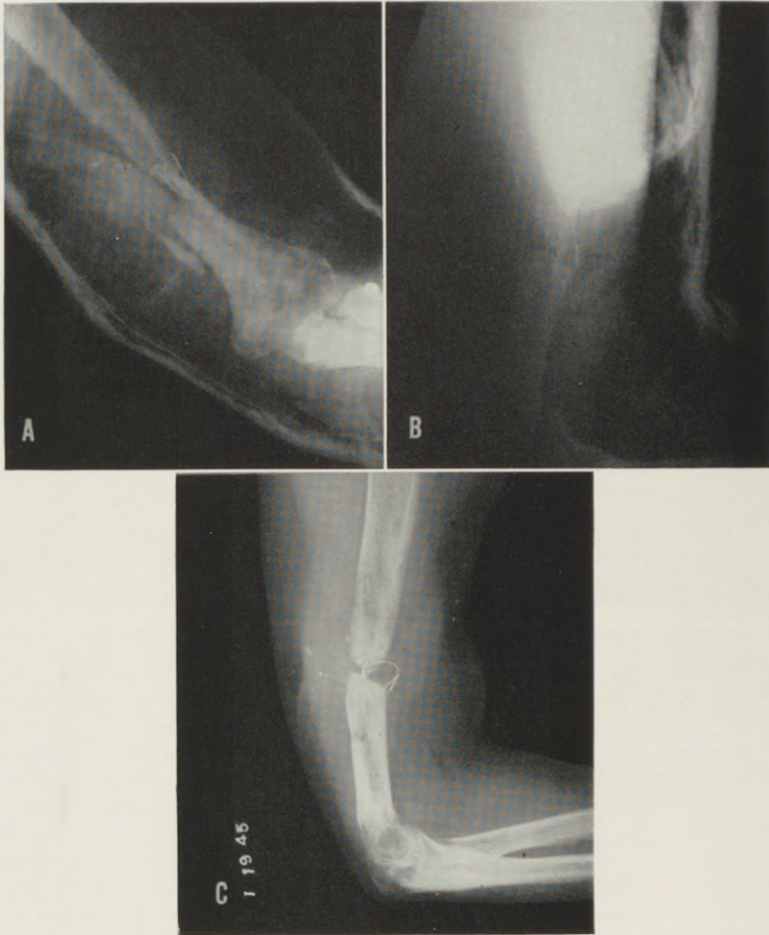
FIGURE 43. (See opposite page for legends.)



AFIP (Cushing GH) P-1505-A-E, 743

FIGURE 43.—Management by delayed internal fixation of compound comminuted fracture of shaft of right humerus, with segmental loss of bone and laceration of median and ulnar nerves. Ligation of the brachial artery and vein was necessary at initial wound surgery, at which the severed median nerve was approximated and the ends of the severed ulnar nerve were tagged with wire sutures. A. Anteroposterior roentgenogram showing compound comminuted fracture of right humerus, before reparative surgery. Note bone loss and resulting defect. Totally loose bone fragments were removed at the reparative operation. B. Lateral roentgenogram of fracture. C. Anteroposterior roentgenogram of fracture after internal fixation with 3 wire sutures, 23 days after wounding. At this operation, the end of each fragment was squared to provide a maximum surface for the bony contact achieved by the fixation procedure. The resultant shortening was about 2 inches. The wound was left open for the next 7 days, then was partially closed by suture and a skin flap was rotated so as to cover all denuded bone. D. Lateral roentgenogram showing fracture after internal fixation. This view, like the anteroposterior view C, shows the fragments in good contact with each other. E. Anteroposterior roentgenogram made in Zone of Interior hospital 3 months after wounding. The fracture united promptly, without sequestration or removal of metal, and wound healing was also satisfactory. F. Lateral roentgenogram made in Zone of Interior hospital.

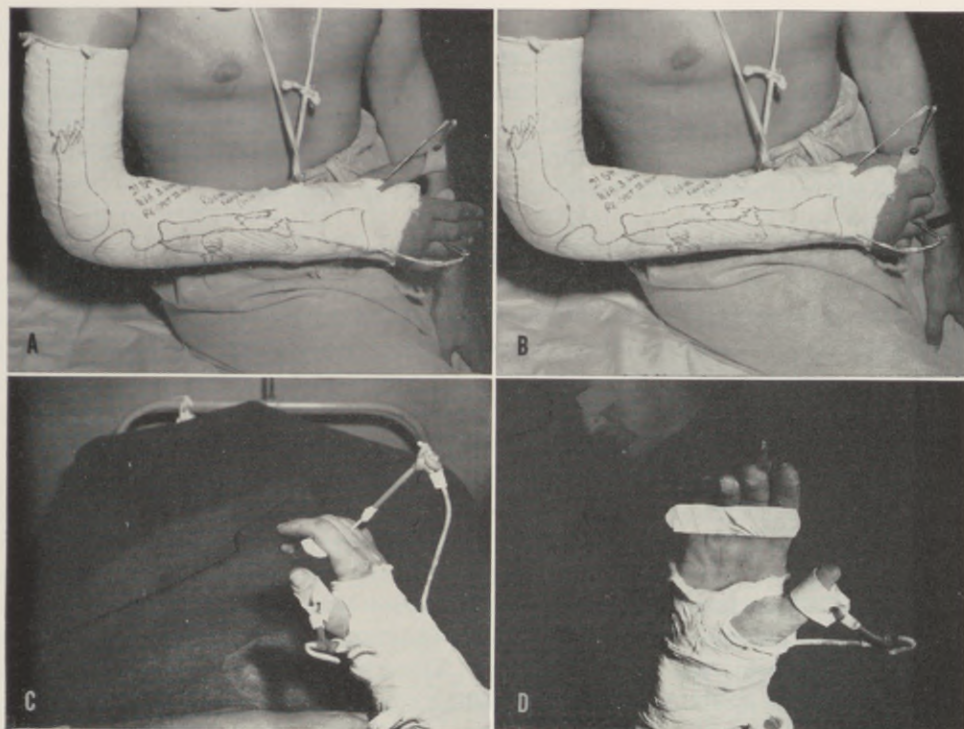
In this case, all residual devitalized tissue was excised at wound revision. Twelve days later, apposition of the fragments of bone was obtained by surgery on the bone. Eight days later, wound closure was accomplished, the open wound having provided drainage in the interval between the operations. The aggressive surgical approach prevented almost certain nonunion of the fracture, while the procedures undertaken for wound healing made it possible to undertake nerve surgery soon after the patient reached the Zone of Interior. (This case was managed by Maj. Herbert W. Harris, MC, at the 17th General Hospital.)



AFIP (Cushing GH) P-1504

FIGURE 44.—Management by delayed internal fixation of compound comminuted fracture of right humerus with segmental loss of bone and laceration of radial nerve. A. Anteroposterior roentgenogram of fracture of humerus after approximation of fragments by two wire sutures at reparative surgery. Note that contact between the fragments is only minimal. B. Lateral roentgenogram of fracture shown in view A. C. Lateral roentgenogram made in Zone of Interior hospital 8½ months after wounding, showing nonunion of fracture of humerus. The wounds healed well, but bone grafting was necessary to secure union of the fracture. Definitive suture of the radial nerve was carried out at the same operation.

Although the approximation of fragments in this case did not lead to union, the procedure employed provided a chance for union to occur and facilitated later reconstructive surgery. Without internal fixation, nonunion was inevitable because of the segmental bone loss at wounding. (The case was managed at the 21st General Hospital by Maj. Joe M. Parker, MC, and Lt. Col. Henry G. Schwartz, MC.)



AFIP C-44-363, Fd-44-14

FIGURE 45.—Splinting for paralysis of radial nerve. A. Hanging cast utilized for reduction of fracture of humerus. Note fingers relaxed, in functional position. B. Complete flexion of fingers and thumb by power of median- and ulnar-nerve supply. C and D. Closeups showing elastic supports to prevent continuing stretch of paralyzed muscles. Note discarded plasma tubing, used in preference to the elastic cord which was supplied for traction. Tubing is more effective because it stretches more readily. A piece of string tied to the plasma tubing passes between the third and fourth fingers and is attached to a portion of a tongue depressor. The cuff around the thumb is made of adhesive tape.

COMPOUND FRACTURES OF THE HUMERUS

The material on compound fractures of the humerus is based on surveys from three hospitals, as follows:

271 compound fractures of the humerus treated at the 21st General Hospital in Italy and later in the European Theater of Operations during 1944 and 1945.

221 compound fractures of the humerus analyzed from the 1944-45 disposition-board proceedings at the 300th General Hospital in the Mediterranean theater.

147 compound fractures of the humerus treated at the 33d General Hospital in 1944 and 1945, during the last 9 months of the war.

Compound fractures of the humerus are most conveniently discussed according to the location of the fracture. In the 337 cases from the 300th and 33d General Hospitals in which these data were stated, the injuries involved the shoulder joint and the proximal end of the humerus in 18 percent, the shaft from the surgical neck to the supracondylar level in 65 percent, and the distal end and elbow joint in 17 percent.

Fractures of the Proximal End of the Humerus

Several particularly important observations, with correspondingly important therapeutic implications, were made in compound fractures of the proximal end of the humerus with involvement of the shoulder joint. These observations included the following:

Dislocations of the head of the humerus were very frequently associated with compound fractures of the head and neck (fig. 46). They were overlooked at the initial operation in a large proportion of the cases encountered early in the war. In one group of 24 consecutive injuries of the proximal head of the humerus with involvement of the shoulder joint, there were 8 associated dislocations. When the frequency of the association was realized, it became common practice to obtain stereoscopic roentgenograms of all fractures about the shoulder joint before reparative surgery. The dislocation was usually anterior, and, if the head of the humerus was split longitudinally, the fracture surface was found resting on the anterior lip of the glenoid. Closed reduction was not possible in this type of case. Instead, it was necessary to restore the normal regional relationships by open operation on the fracture dislocation.

Concurrent injury to the major nerve trunks was not frequent, but the wounds were frequently so located that damage to the axillary nerve seemed highly probable. Nothing could be done about such an injury, as this nerve is too small to be attacked directly and repair was therefore out of the question. It was the general practice, in order to preserve any undamaged nerve supply for the deltoid, to employ an anterior approach to the fracture, with reflection of the deltoid, and often with utilization of a portion of the compounding wound.

If the head of the humerus was not too badly comminuted, the usual procedure was to maintain reduction by 1 or 2 screws or by wire sutures. When the comminution was so extensive that reduction was impossible, the dislocated head was excised, and the upper end of the shaft of the humerus was placed against the glenoid. If enough of the head remained intact to permit partial restoration of the cartilaginous relationship of the shoulder, with a decrease in the articular surface of the head, observations at operation showed that the remnant of the surface of the head glided well through a fair range of motion. The end results of this technique are not known.

When both the head of the humerus and the glenoid process were so completely shattered that it was impossible to reorganize any articular mechanism in the shoulder joint at reparative surgery, the wound was left open because

the extensive damage to the articular cartilage probably made prolonged drainage inevitable. The best plan of management was to immobilize the shoulder in plaster in the position of function, in the expectation that spontaneous fusion would occur.

Fractures of the Shaft of the Humerus

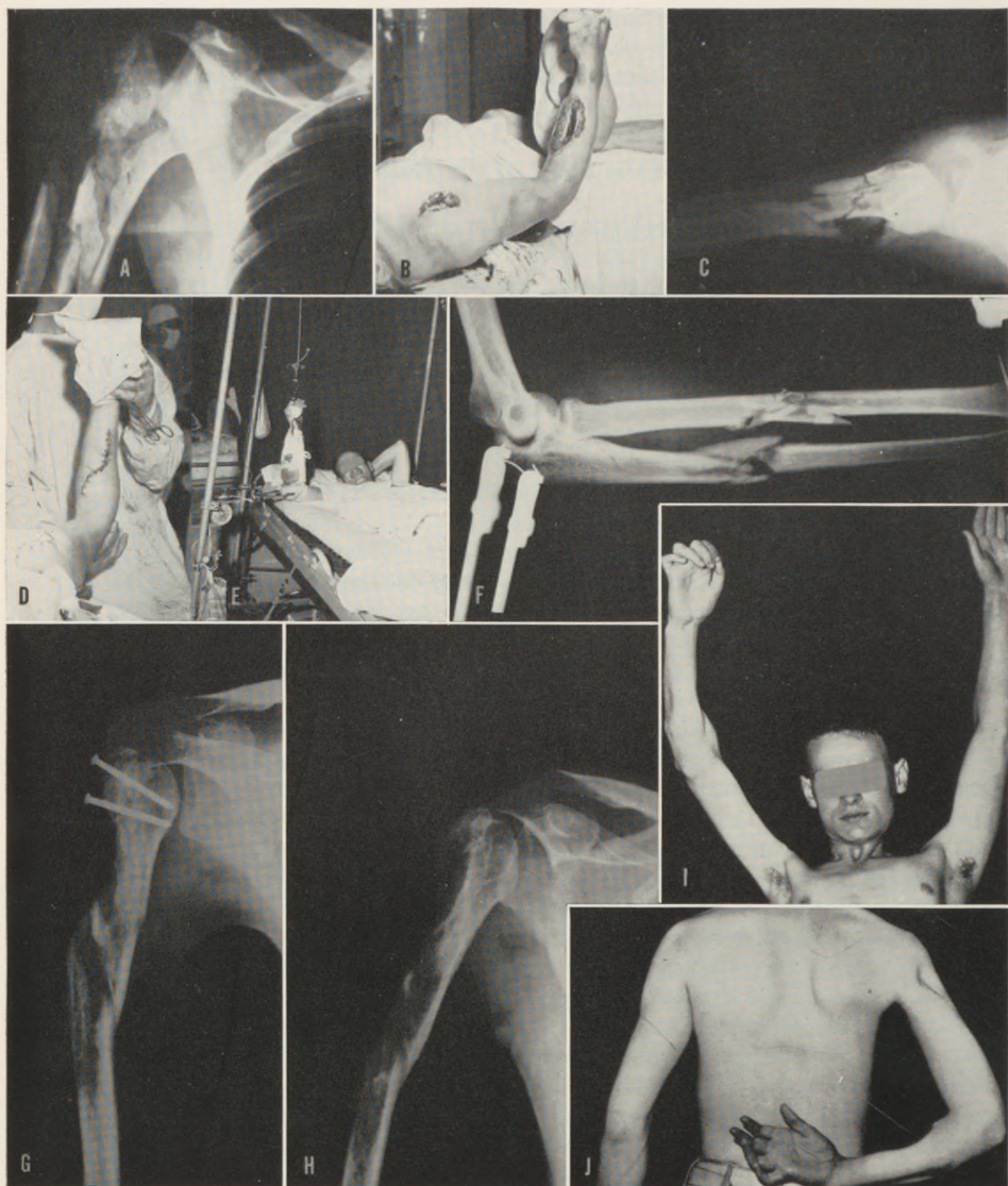Compound fractures of the shaft of the humerus included a wide variety of injuries. The compounding wounds varied considerably in size, depending upon the type and velocity of the missile and the extent of the initial debridement. Bone injuries ranged from incomplete cortical fractures to avulsions of several inches of the shaft. As a rule, the extent of bony damage paralleled the extent of soft-tissue damage.

Wounds in this area were likely to be clinically clean. It was usually possible, without undue difficulty or further trauma, (1) to explore them adequately and to remove devitalized tags of tissue, totally loose fragments of bone, and other foreign material; and (2) to appraise the extent of bone damage and determine possible nerve damage.

After the type of fracture management had been decided upon and internal fixation, if it was indicated at this time, had been carried out, the wounds were closed by the layer-suture technique. Wound closure was carried out as part of reparative surgery in about 70 percent of all fractures of the shaft of the humerus. A certain number of the remaining cases were left unsutured because the wounds were of small size. The others were closed or grafted at a staged procedure. As already noted, it was unusual to find any evidence of infection in wounds of this area of the humerus or any considerable amount of retained foreign material or necrotic tissue. When these circumstances were encountered, the usual secondary excisional surgery was performed, and closure was delayed for 5 to 7 days after operation.

Methods of fracture management in compound injuries of the shaft of the humerus depended upon whether or not bone loss had occurred.

Fractures without bone loss.—In fractures without bone loss, the hanging cast was frequently used whenever the patient could be ambulatory (fig. 47). It was replaced by the shoulder spica (fig. 48) in cases of massive soft-tissue injury or in cases in which distraction of the humeral fragments had occurred or seemed likely to occur. In addition to its advantages from the therapeutic standpoint, the hanging cast converted a bed patient into an ambulatory patient, permitting him to go to mess and to the latrine and generally to take care of himself. These were considerations of no little importance in a busy general hospital with limited manpower. Patients were comfortable in the cast and quickly learned how to lie down and rise from the bed without assistance and without discomfort. During periods of temporary recumbency soon after wounding, reduction was maintained by traction, which was provided by a weight extending from a plaster loop at the elbow over a pulley at the foot of the bed. Later, the elbow was merely supported by a pillow.



AFIP 88226, CA-44-346, 88230, 88228, 88229, 92364, 92365

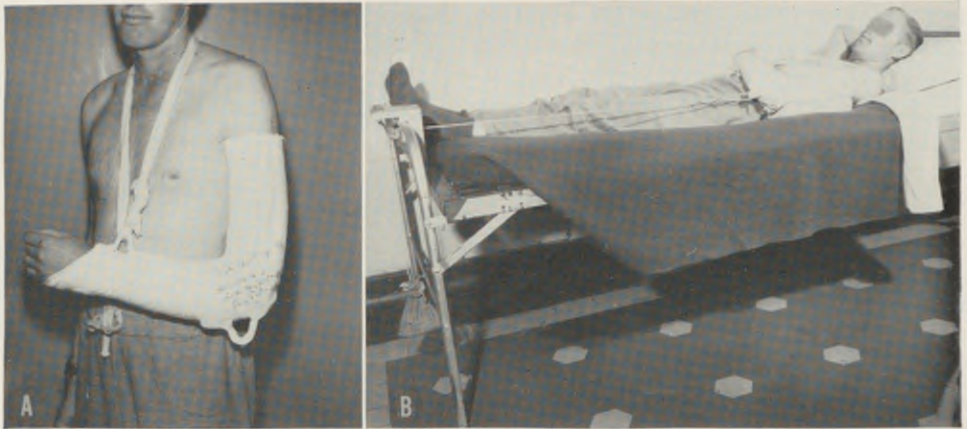
FIGURE 46. (See opposite page for legends.)

If the fracture was in the lower portion of the shaft, alinement was best maintained by placing the forearm in complete pronation, as a precaution against outward bowing at the fracture site. The cast was made lighter than in civilian practice and was never weighted, since badly comminuted battle-incurred fractures with associated soft-tissue damage were easily distracted.

In the early days of the North African campaign, the shoulder spica was frequently used for fractures of the shaft of the humerus, and some surgeons continued to use it in all cases of this kind. Those who tested the hanging cast, however, usually came to prefer it. The spica was difficult to apply satisfactorily with the patient recumbent, and, even when it was applied snugly with the patient erect, it was not at all unusual, 10 to 14 days later, to find that it had become loose and that the fragments were angulated. In a busy overseas theater, a cast which had to be replaced at frequent intervals was open to serious objection. United States experiences in civilian practice would have suggested a wider wartime use of the shoulder spica. It was widely used in the Spanish Civil War, as well as by British surgeons in the North African theater.

It was the general opinion in the Mediterranean theater that the hanging cast, in addition to being more comfortable for the patient than the shoulder spica, gave better results from the standpoint of bony alinement and main-

FIGURE 46.—Comminuted fracture dislocation of right shoulder, comminuted fracture of shaft of humerus, comminuted fractures of both bones of forearm, associated injuries of median and radial nerves. A. Anteroposterior roentgenogram in general hospital showing fracture dislocation of shoulder and comminuted fracture of shaft of humerus. B. Compounding wounds of shoulder and middle third of forearm just before reparative surgery. Note exposed tendons in wound of forearm. C. Anteroposterior roentgenogram of shoulder and upper arm after reconstruction of head of humerus and fixation by multiple screws. Extremity is in skeletal traction for comminuted fracture of shaft of humerus. D. Compounding wounds after closure at reparative surgery. Note proximal and distal extension of wound of shoulder region to permit adequate exposure. E. Skeletal traction applied for comminuted fracture of humerus, with wire through olecranon, and for comminuted fractures of bones of forearm, with wire through distal ends of both bones. F. Anteroposterior view of bones of forearm in skeletal traction. Note suture of stainless-steel wire inserted at reparative surgery to hold major fragments of radius in apposition. G. Anteroposterior roentgenogram showing united fracture of humerus in Zone of Interior $3\frac{1}{2}$ months after reparative surgery. Note that absorption of bone in the head of the humerus has left the proximal ends of the screws projecting into the soft tissues. H. Same as view G, after removal of screws. Further union of the fracture of the shaft occurred later. I. Range of overhead reach 8 months after reparative surgery. J. Range of internal motion at same time. When this photograph was made, radial-nerve function had returned, but a median-nerve paralysis was still present. Later, spontaneous recovery occurred. The extremely satisfactory result achieved in these serious injuries was made possible only by an aggressive surgical approach and the employment of a varied armamentarium of procedures at reparative surgery. (This patient was managed by Maj. Joe M. Parker, MC, at the 21st General Hospital.)



AFIP Fd-45-22

FIGURE 47.—Hanging cast used for fracture of humerus. A. Cast with patient erect. Note plaster loops for sling and for traction in recumbency. Wrist is free, but hand is supported by plaster extension. B. Patient recumbent. Traction from loop is utilized in this position. Only 4 or 5 pounds are necessary. Note folded towel supporting arm.

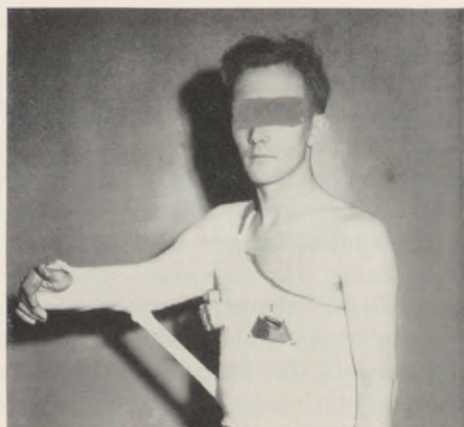tenance of the position of the fragment. Instances were recorded in which reduction was accomplished satisfactorily by the hanging cast after skeletal traction had failed. Many patients were evacuated before any opinion about union could be expressed, but results were generally good in the cases held long enough for observation.

The hanging cast was often used for transportation to the Zone of Interior. Patients with injuries of the humerus, with or without involvement of the shoulder joint, were seldom in condition to travel before the third or fourth week after wounding. By this time, the bony fragments were usually beginning to unite, and transportation in this type of cast was regarded as entirely proper.

Fractures with bone loss.—There were two important considerations in fractures of the shaft of the humerus with bone loss. The first was the amount of bone lost and the degree of shortening which would result if the bone ends were approximated without replacement of the segmental deficit. The second was the probability of sound primary healing of sutured soft parts, to facilitate bone grafting at an early date. These considerations were necessarily weighed against each other in deciding whether to accomplish repair by internal fixation, to overcome the segmental defect, or by other measures in cases of bone loss.

If shortening did not exceed 3 to 4 cm., good contact of the bone ends could usually be attained by means of 1 or 2 wire sutures (fig. 37). Sutures were used in preference to plates because they could be inserted with little or no periosteal stripping. When they were supplemented by firm external splinting, the fracture was well immobilized (figs. 38, 43, and 44). With this technique, reparative surgery of the soft tissues was accomplished without

FIGURE 48.—Well-applied shoulder spica cast for fracture involving shoulder joint. If shoulder fusion is anticipated, the degree of abduction is debatable.



A FIP Fd-45-20

difficulty. In the occasional case in which contact of the fragments had been particularly satisfactory, a hanging cast was employed. Most often, however, a shoulder spica was used.

If bone loss was so extensive that shortening in excess of 4 cm. would be required to obtain contact of fragments, it was considered preferable to accomplish healing of the compounding wound and return the patient to the Zone of Interior, with the idea that bony continuity would be restored at a later reconstructive operation. This may or may not have been a better plan than internal fixation of the fracture with wire sutures to obtain contact of the fragments.

Internal fixation was employed in only a small proportion of the fractures of the shaft of the humerus encountered in the Mediterranean theater (p. 199). When it was used, plating was usually avoided, for the obvious reason that stripping of the periosteum would have introduced fresh trauma and would have enhanced the possibility of sequestration.

In the 271 compound fractures of the humerus analyzed at the 21st General Hospital, internal fixation was used 22 times but was accomplished by plating only twice; wire sutures were used 15 times and multiple screws 5 times. In the 147 cases treated at the 33d General Hospital, internal fixation was also used 22 times and was accomplished by plating 5 times; wire sutures were used 9 times, and sutures and screws were used in combination 8 times.

Associated nerve injuries.—In all compound fractures of the shaft of the humerus, the possibility of an associated nerve injury existed and had to be taken into account in the preoperative evaluation of the patient. Radial-nerve injuries were by far the most frequent, as the following figures show:

In the 271 fractures of the humerus treated at the 21st General Hospital, there were 108 nerve injuries, including 70 injuries of the radial nerve, 30 of the ulnar nerve, and 8 of the median nerve. Injuries of the radial nerve were present in half of all fractures of the middle third of the shaft.

In the 147 fractures treated at the 33d General Hospital, there were 66 nerve injuries, including 36 injuries of the radial nerve, 20 of the ulnar nerve, and 10 of the median nerve.

Radial-nerve injuries were thus present in 25.4 percent of these two series (106 of 418 cases), ulnar-nerve injuries were present in 11.9 percent (50 cases), and median-nerve injuries were present in 4.3 percent (18 cases).

Because nerve injuries are treated in detail in the neurosurgical volume of the clinical history of World War II, only brief mention need be made of them here. The important considerations in nerve injuries were that (1) the possibility of the injury be borne in mind in the preoperative survey, as has already been emphasized, and (2) that, when clinical paralysis was present, the necessity for exposure of the nerve at operation be considered. The preoperative estimate, as a practical matter, was made on the basis of demonstrable motor and sensory deficits.

Combined nerve and bone surgery proved so successful when it was tried tentatively that during the last 9 months of the war it became common practice at reparative surgery to expose the involved trunks in all instances of peripheral-nerve palsy, to permit precise determination of the damage, unless—

1. A sufficiently detailed note on the record showed that the nerve had been visualized intact at initial surgery.

2. The location of the wound and of the fracture made it anatomically unlikely that the nerve had been injured. In such cases, a diagnosis of nerve injury was sometimes made, but returning function usually became evident in 2 to 3 weeks. This happened in seven cases, for instance, at the 21st General Hospital.

The status of the nerve was usually determined by inspection after it had been exposed, though in some cases an injection of physiologic salt solution was employed as an aid in determination of intraneural continuity. If the nerve was found severed or so severely traumatized that, although it was intact, physiologic interruption had evidently occurred, the extent of the damage was evaluated, and the possibility of approximating the nerve ends after resection of the damaged portion was determined. The technique of fracture management was often influenced by this decision.

If the divided nerve ends could apparently be brought together without tension, internal fixation, even if plating was necessary, was sometimes employed, so that staged nerve repair could be carried out as promptly as possible. Of the 22 internal-fixation operations performed at the 21st General Hospital, an associated nerve injury and the desirability of early repair were the indications in 15 (fig. 39).

If comminution precluded fixation of the fractured bone, 1 cm. or more of the length of the arm was often deliberately sacrificed by removal of loose fragments, in order to accomplish stable internal fixation and permit nerve repair to be undertaken within the optimal period of 3 weeks after wounding. If a nerve deficit existed, a section of the fractured shaft of the humerus,

sometimes up to 4 cm., was excised, so that the ends of the damaged nerve could be brought together.

Definitive nerve suture was never performed at the first operation of reparative surgery. Nerve surgery at this operation never went beyond the loose approximation of the ends of the nerve by a single suture, and even this procedure was by no means the rule. Definitive repair was undertaken at a later date, through a healed wound. What could be accomplished at the staged nerve operation, however, often depended upon what had been done about the fracture at reparative surgery.

In view of the very poor results which were being reported after nerve grafting in the Zone of Interior and the relatively or actually good results being achieved by the combined procedure described, this new and radical approach to fractures of the shaft of the humerus associated with nerve injuries was regarded as fully justified. Obviously, the close cooperation of orthopedic surgeons and neurosurgeons was essential for the best results.

The majority of the combined procedures in this series were undertaken in injuries of the radial nerve. Relatively few were undertaken for injuries of the median and ulnar nerves, which, though probably of greater importance functionally, were less frequent.

Fractures of the Distal Portion of the Humerus

In fractures of the distal portion of the humerus involving the elbow joint, the extent of the injury again determined the technique to be employed.

Fractures of the condyles, if they were not too greatly comminuted, were reduced as anatomically as possible and were often fixed internally, to facilitate early motion. This was a consideration of the utmost importance in the restoration of function.

T-fractures, with separation of the condyles, were often held in reduction by two screws or by a combination of wire sutures and screws. This area of the humerus, fortunately, usually tolerates without difficulty the manipulation and stripping of the periosteum necessary for accurate reduction of the fragments. It was occasionally necessary to shift flaps of skin in order to close the tissues over exposed bones or joints. One case was observed in which a thick flap of skin was utilized to seal the elbow joint, which was preserved with only this covering.

Markedly comminuted fractures about the elbow, with destruction of the condyles of the humerus and the upper ends of the radius and ulna, permitted little choice in fracture management. The technique employed depended upon the condition of the compounding wound. Clean wounds of the elbow with marked comminution were treated by delayed closure. At one hospital, if infection was present, resection of the elbow joint was sometimes performed. The wound was closed with drainage or was left open and closed at a later operation. The flail elbows which resulted from these operations did not seem to be satisfactory while the patients remained under observation and were

probably no more satisfactory later. The value of this procedure, therefore, was debatable except as a means of controlling severe infection and avoiding amputation.

Fractures of the lower end of the humerus were associated with more ulnar- and with fewer radial-nerve lesions than fractures of the shaft. Wounds characterized by avulsion of the medial epicondyle were so frequently accompanied by ulnar-nerve paralysis that accurate appraisal of possible nerve damage was a routine step in their management.

Results of Reparative Surgery

As in all compound fractures, the compilation of end results was impossible overseas in fractures of the humerus. The great majority of patients were transferred to the Zone of Interior before complete wound healing or complete union of the fracture had occurred. There was, however, general agreement in the theater that, in terms of wound healing and in the maintenance of satisfactory reduction of fractures until union was in progress, the reparative surgery of compound fractures of the humerus had produced excellent results. In many cases, wound healing was complete within 3 weeks of wounding, and in many others it was complete at this time except for small areas of granulation. It appeared that, if the plastic and other procedures necessary to achieve skin coverage had been correctly performed, only sequestering bone retarded wound healing.

An analysis of the 147 cases treated at the 33d General Hospital² provides support for these generalizations. They were classified as follows:

27 cases with massive soft-tissue destruction and, in most instances, severe bone comminution (group A).

69 cases with moderate soft-tissue damage and severe comminution of bone (group B).

51 cases with minimal soft-tissue damage and minimal comminution of bone (group C).

Treatment was regarded as successful in these cases if the wound was completely healed or if only small areas of healthy granulation tissue were present, so that the fracture site was well sealed off. Fracture management was regarded as successful if adequate apposition and alinement of fragments were maintained until union had occurred or until the patient was transferred to the Zone of Interior. Management was regarded as unsuccessful (1) if the fracture site was not sealed off and there was a sinus or opening wound leading to it and (2) if satisfactory reduction of the fracture was not maintained under the circumstances just described. Classification of results as unsuccessful because of a persisting sinus to bone set rather rigid qualifications for wound healing, particularly in comminuted fractures, in which many bone fragments are partially denuded at wounding and therefore are potential sequestra. The

² A total of 151 cases were treated at the 33d General Hospital, but 4 cases were omitted from the analysis, 2 in which amputation was necessary because of circulatory gangrene, and 2 others in which no followup could be secured.

data available in the series of compound fractures of the humerus analyzed from the 33d General Hospital (tables 4, 5, and 6) deserve certain brief comments.

The results were tabulated from the standpoint of wound revision as the first step of reparative surgery because they improved as time passed and revision of the wound became more complete. Early in the experience, the depths of the wound, including the fracture site, were not routinely exposed.

TABLE 4.—Results in relation to procedure and wound healing in 147 compound fractures of the humerus treated at the 33d General Hospital 1944-45

Procedure	Successful ¹				Unsuccessful ¹			
	Group A	Group B	Group C	Total	Group A	Group B	Group C	Total
Wound revision:								
Complete.....	22	51	29	102	4	2	-----	6
Incomplete.....	-----	10	18	28	1	5	1	7
Total.....	22	61	47	² 130	5	7	1	13
Technique of closure:								
Suture.....	18	59	47	124	4	6	1	11
Partial suture.....	4	1	-----	5	-----	-----	-----	-----
No closure.....	-----	2	3	5	1	1	-----	2
Total.....	22	62	50	134	5	7	1	13

¹ See text, p. 130, for code.

² The details of wound revision were unknown in 4 cases.

TABLE 5.—Results in relation to technique and status of fracture in 147 compound fractures of the humerus treated at the 33d General Hospital 1944-45

Technique	Successful ¹				Unsuccessful ¹			
	Group A	Group B	Group C	Total	Group A	Group B	Group C	Total
Hanging cast.....	6	24	11	41	-----	4	-----	4
Other plaster immobilization.....	12	23	27	62	-----	3	-----	3
Airplane splint.....	1	2	9	12	-----	-----	-----	-----
Internal fixation and plaster.....	6	11	4	21	1	-----	-----	1
External skeletal fixation.....	² 1	2	-----	3	-----	-----	-----	-----
Total.....	26	62	51	139	1	7	-----	8

¹ See text, p. 130, for code.

² While it is known that union was delayed in this case, reduction was adequate.

TABLE 6.—*Results in relation to wound healing and status of fracture in 147 compound fractures of the humerus treated at the 33d General Hospital 1944-45*

Results ¹	Group A	Group B	Group C	Total
Successful wound healing and fracture management	22	57	50	129
Successful wound healing, unsuccessful fracture management		5		5
Unsuccessful wound healing, successful fracture management	4	5	1	10
Unsuccessful wound healing and fracture management	1	2		3
Total	27	69	51	147

¹ See text, p. 130, for code.

Totally detached bone fragments and dead tissue were therefore left in situ in many cases. At this time, revision was limited to the trimming of tags of devitalized tissue along the wound edge. Later, the importance of insuring that the wound was free of all devitalized tissue before repair was undertaken became generally recognized. It then became routine to expose the depths of the wound by gentle retraction, evacuate old blood clot, and excise necrotic tissue and bone fragments totally devoid of soft-tissue attachment. Considerably better results were produced under this new policy (table 4).

In 5 of 13 wounds in which healing was classified as unsatisfactory, a typical osteomyelitis was present, of the type frequently seen in battle-incurred fractures and always characterized by heavy drainage and rather extensive sequestration. Union is known to have occurred in some of these cases in spite of these unfavorable circumstances.

Some information is available from other hospitals to supplement the material presented in these tables from the 33d General Hospital. It is known, for instance, that in 112 of the 128 compound fractures treated while the 21st General Hospital was functioning in the hospital center at Naples, the wounds were completely healed or almost completely healed when the patients were evacuated to the Zone of Interior.

In 116 cases managed at the 300th General Hospital, later information showed that, when the patients were considered ready for evacuation to the United States 90 to 120 days after wounding, complete healing had occurred in 94 cases, and in 11 others, while there were some areas of granulation, there was no opening to the fracture site. In nine cases, there were sinuses to the bone, and there were two instances of osteomyelitis, in both of which the fracture site was infected and sequestration was occurring.

Since the combined bone-nerve reparative regimen placed emphasis on early wound healing, so that nerve suture might be performed through a clean surgical approach within 3 to 4 weeks after healing, information concerning

this point is of interest. In the 116 cases for which information is available in the series from the 300th General Hospital, 30 of the wounds (26 percent) were healed within 3 weeks, and 41 others (35 percent) within a total of 4 weeks. Sixty-one percent of the wounds were thus healed within the optimal time for nerve suture. Eight other wounds were healed within 5 weeks, but no information is available for the remaining cases.

COMPOUND FRACTURES OF THE RADIUS AND ULNA

The statistical material on compound fractures of the bones of the forearm is based on the following surveys:

243 compound fractures—112 of the radius, 97 of the ulna, and 34 of both bones observed at the 21st General Hospital in Italy and later in Europe during late 1944 and 1945.

272 compound fractures—113 of the radius, 107 of the ulna, and 52 of both bones, analyzed from the 1944-45 disposition-board proceedings at the 300th General Hospital in the Mediterranean theater.

319 compound fractures—136 of the radius, 124 of the ulna, and 59 of both bones, treated at the 45th General Hospital. Both the 1944 and 1945 admissions are included in this series.

This makes a total of 834 compound fractures of the bones of the forearm—361 of the radius, 328 of the ulna, and 145 of both bones. Not all data are available in all series.

Wound management in compound fractures of the bones of the forearm followed the principles generally employed in reparative surgery. The technique varied, for anatomic reasons, according to the portion of the forearm in which the fracture was located. Although the structures of the upper half of the forearm are more tendinous than those of the upper arm, no special difficulties were usually encountered in that area. As the wrist is approached, muscle is replaced by fascia and tendon, both of which are structures with little power to resist infection, because of their poor blood supply. For these reasons, wounds in this area were sometimes necrotic and sloughing when the patients reached the general hospital. Closure could not be considered in such cases until after further excisional surgery, and delayed closure frequently required split-thickness skin grafts or sliding or advancement of skin flaps.

Fracture management.—Fractures of a single bone usually presented no problem in fracture management, for, just as in fractures of a single bone of the leg, the intact bone served as a splint for the fractured bone, and displacement was seldom significant. Procedures to achieve reduction were necessary only in fractures about the joints and in an occasional instance of narrowing of the interosseous space. In the 209 compound fractures of the radius or of the ulna observed at the 21st General Hospital, cast immobilization, with no effort at further reduction, was all that was necessary in 190. This was a typical experience.

Fractures involving the olecranon process required anatomic reduction and fixation to restore joint congruity. Wire-suture fixation was often useful.

Fractures of the head of the radius were best managed by excision of the comminuted fragments. This procedure removed a potential nidus of infection and eliminated a handicap to future function of the elbow.

Fractures of both bones of the forearm in the upper third often presented problems in the maintenance of reduction (fig. 49). When soft tissue was available for early wound healing, it was often a good plan to place a long plate on the ulna, to serve as a strut for the comminuted fragments, as well as to maintain length and alignment in the injured bones. This was not always possible, however. The subcutaneous position of the ulna often created difficulties in wound healing when only skin was available for coverage of the bone and metal. In spite of these problems, repair of soft parts of the upper forearm was usually successful if excisional surgery was complete and soft-tissue loss was not excessive.

If the contour of the fracture permitted rigid stabilization of both bones and if soft parts for adequate coverage were available, stabilization by multiple screws or plates was often useful. This procedure accomplished anatomic reduction, avoided encroachment of the bones on the interosseous space, and permitted earlier pronation and supination.

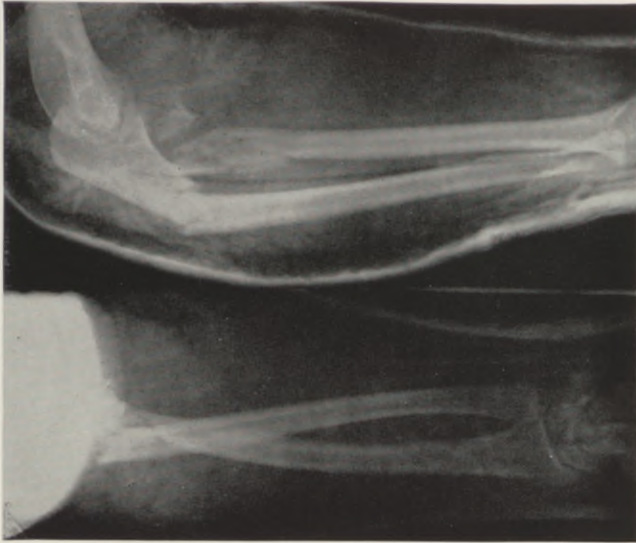
In comminuted fractures of both bones without bone loss, skeletal traction with a wire through the distal ends was occasionally used to accomplish adequate reduction.

In comminuted fractures of both bones with bone loss, internal fixation, usually by wire sutures, was used to approximate the fragments. Comminuted fragments of one bone were occasionally removed to permit approximation of the fractured ends of the other. As a rule, however, this was not advisable because of the successes attained in bridging defects with bone grafts at reconstructive surgery.

In the distal portion of the forearm, because of the relatively superficial position of the bones, internal fixation by plating was performed only on special indications (fig. 50). It was essential that sufficient soft tissue be available for closure.

Combined bone-nerve injuries.—Peripheral-nerve injury was almost as common in wounds of the forearm as in wounds of the arm. In the 243 fractures observed at the 21st General Hospital, the radial nerve was injured 28 times, the ulnar 32 times, and the median 25 times, a total incidence of more than a third. Nerve lesions in the forearm were more often incomplete than in similar lesions in the upper arm.

All 28 of the radial injuries just mentioned occurred in the upper forearm, in which combined nerve and bone operations are likely to be technically difficult if not entirely impractical. In these cases, approximation of the nerve ends was frequently of less importance because the principal deficit could be overcome later by some reconstructive procedure at the wrist, usually a tendon transplant or a fusion operation. Repair of the median and ulnar nerves was,



U. S. Army photos

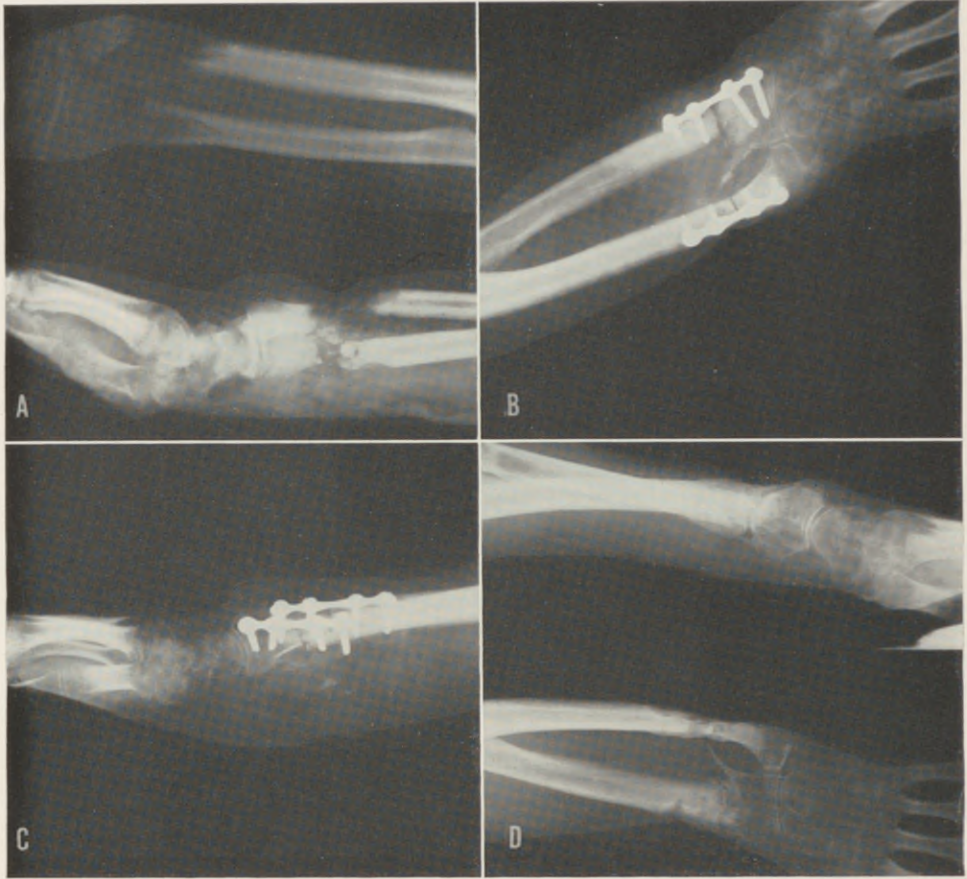
FIGURE 49.—Unsuccessful management of compound comminuted fracture of upper third of right radius (head) and ulna (just distal to coronoid process). Anteroposterior and lateral roentgenograms of fractures after incomplete manipulative reduction at reparative surgery in general hospital. Note angulation of ulna and loose fragments of radius. The fracture united in this position, and 6 months after wounding rotation was almost nil and elbow motion was limited to 10° to 15° .

In this case, the wound healed satisfactorily, but osteotomy was eventually necessary to correct the malunion of the ulnar fracture. If the loose fragments of the upper radius had been removed and the ulna plated in good alignment at reparative surgery, prompt healing could have been anticipated, for skin and soft parts were available for a satisfactory wound closure. This procedure would have permitted reasonably early elbow motion and would probably have produced an improvement in the end result.

however, a matter of paramount importance, and in this series from the 21st General Hospital the bony structure was deliberately shortened five times, and the fractures were plated to facilitate later nerve suture. None of the bone defects thus created exceeded 3 cm.

Nerve and tendon operations in the lower forearm were always performed in the Zone of Interior.

Results.—Although no statistical data were available on the results accomplished in reparative surgery of compound fractures of the forearm, it was generally acknowledged that neither the healing of compounding wounds nor the reduction of fractures was as satisfactory as corresponding results in compound fractures of the humerus. For this, there were a number of explanations, including the exposed position of fracture sites in the ulna, the abundance of poorly vascularized fascial and tendinous structures in the distal portion of the forearm, and the paucity of well-vascularized soft tissue in this area.



AFIP (O'Reilly GH) 4071-4074

FIGURE 50.—Management of compound comminuted fracture of distal third of left radius and ulna by delayed internal fixation. Reparative surgery, 11 days after wounding, consisted only of manipulative reduction of the fractures and partial wound closure. The wound healed only in part, and necrotic bone presented through an opening in it. A. Anteroposterior and lateral roentgenograms of fractures of radius and ulna 1 month after unsuccessful manipulative reduction. Note poor alinement of fractures and destruction of bone. B. Anteroposterior roentgenogram showing same fractures 3½ months after wounding and 5 weeks after they had been plated in reduction. Apposition and alinement are now good. The shortening from necrosis and bone loss was about 3 inches. C. Lateral roentgenogram taken at same time as view B. D. Anteroposterior and lateral roentgenograms 6 months after fractures had been plated. Removal of sequestra and metal was necessary to accomplish wound healing.

In this case, failure to achieve adequate reduction and wound healing after the first operation of reparative surgery indicated the necessity for additional surgery long before it was performed. In spite of the delay, however, and the infection, correct reparative surgery was eventually responsible for an excellent result. (This case was managed at the 300th General Hospital by Maj. Spencer A. Collom, Jr., MC.)

Although results in compound fractures of the forearm were not as good as those obtained in similar injuries of the upper arm, later results were known to be far superior to those obtained before the program of reparative surgery was introduced in the Mediterranean theater. It is known, for instance, that 84 of the 319 soldiers treated at the 45th General Hospital (approximately 26 percent) were returned to duty within the 90- to 120-day holding period in this theater. These are excellent results, and there is no reason to believe that they were not generally duplicated.

CONCLUSIONS

As this limited analysis has shown, the objectives of reparative surgery in compound fractures of the humerus and the bones of the forearm (minimal infection, optimal fracture reduction, early wound healing, maximal functional recovery) were apparently achieved in a large proportion of these injuries. In many of the casualties, the additional reconstructive surgery which would have been necessary under the old plan of management was not necessary under the new plan. In other cases, the reconstructive phase of surgery was expedited, and the necessity for multiple operations was decreased. The mission of overseas surgery was thus largely accomplished in battle-incurred compound fractures of the upper extremity managed in the Mediterranean Theater of Operations.

Part II. Compound Fractures of the Femur³

GENERAL CONSIDERATIONS

According to the machine records of the Mediterranean Theater of Operations as they were available for examination in July and August 1945, fractures of the femur made up 12.7 percent of the principal diagnoses of battle fractures at the time of dispositions by the various general hospitals in the theater. This is in general agreement with the experience of the 45th General Hospital in the year 1944, which can be assumed to be representative. In that year, fractures of the femur accounted for 11.3 percent of all compound fractures managed on the orthopedic section of this hospital. When only compound fractures of the extremities were considered, the incidence increased to 12.6 percent. When fractures of the bones of the hand and the foot were excluded, the incidence of compound fractures of the femur rose to 19.2 percent.

In World War II, just as in World War I, a battle-incurred compound fracture of the femur was properly regarded as one of the most serious skeletal injuries which a soldier could sustain. In World War I, there were 971 deaths

³ The statistical data in this section were collected by Capt. John J. Modlin, MC, Maj. Joe M. Parker, MC, and Capt. Russell J. Crider, MC, 21st General Hospital; Col. Francis J. Cox, MC, 24th General Hospital; Maj. William R. Ferguson, MC, 33d General Hospital; Maj. Irvin Caben, MC, 64th General Hospital; Maj. Spencer A. Collom, Jr., MC, and Maj. William M. Ewing, MC, 300th General Hospital; Maj. Benjamin E. Obletz, MC, and Maj. Joseph D. Godfrey, MC, 23d General Hospital; and Lt. Col. George A. Duncan, MC, 45th General Hospital.

(25.2 percent) in the 3,850 recorded femoral fractures.⁴ These fractures constituted 23.6 percent of all recorded battle fractures (16,339). In a study made in Fifth U. S. Army mobile hospitals in 1945, 114 of the 1,450 deaths (including deaths on arrival) (7.9 percent) were attributed to compound fractures of the lower extremity. It seems fair to assume that the great majority of these injuries were fractures of the femur. The World War II figures do not include traumatic amputations of the thigh, which may have been included in the figures for World War I.

Compound fractures of the femur furnished major problems in both forward and fixed hospitals. Considerable time and effort were required for their management; in view of their frequency, this was a very practical consideration in overseas hospitals. In forward hospitals, even when experienced surgeons were in charge, 2 hours was regarded as acceptable operating time for initial surgery, counting from the time the wounded man was placed on the operating table until the transportation spica was applied.

Large amounts of blood had usually been lost in compound fractures of the femur, and shock was correspondingly severe. Massive transfusions were necessary for resuscitation in evacuation hospitals, as well as for protection during initial wound surgery. In 100 consecutive compound fractures of the femur managed at the 16th Evacuation Hospital, 28 patients required from 1,500 to 2,000 cc. of whole blood before and during the operative procedure (p. 68).

Large quantities of blood were also required in preparation of these patients for reparative surgery at general hospitals. In 50 casualties received at the 23d General Hospital from evacuation hospitals on the Anzio beachhead, the hematocrit reading was under 30 in 38 cases. In another group of 242 casualties received at the 21st General Hospital, the great majority had to be given 2,000 cc. or more of blood before the hematocrit reached 40, the desirable preoperative minimum. Fifty-three casualties treated at the 300th General Hospital required an average amount of 1,900 cc. of blood during the preoperative and post-operative periods.

Even in civilian practice, simple fractures of the femur may be difficult to manage. Battle fractures were often severely comminuted and were complicated by one or more large compounding wounds. If infection had become established, additional problems were introduced. Erosion of a femoral artery was always a possibility in such cases, and amputation occasionally had to be considered for lifesaving reasons. Battle fractures, therefore, presented exceedingly difficult problems of management. Even seasoned ward surgeons were overtaxed and exhausted by the long hours of work required later in the care of these patients on the wards. Carelessness in any regard could result in loss of reduction or in retardation or failure of wound healing.

The wards devoted to fractures of the femur, with their forests of Balkan frames and their mazes of splints, ropes, pulleys, and weights, were, however, among the most interesting in the hospital. Fractures of the femur were of

⁴ Walker, John B.: End Results, Fractures of Long Bones. In *The Medical Department of the United States Army in the World War*. Washington: Government Printing Office, 1927, vol. XI, pt. 1, pp. 491-547.

special interest for another reason: this was the one type of fracture held long enough in a theater of operations to permit evaluation of the union of the fracture and healing of the compounding wound.

SURVEY OF RESULTS, SPRING, 1944

Balanced-suspension skeletal traction was from the beginning the standard method of management of femoral fractures in the general and station hospitals of the Mediterranean theater. In a few instances, only a plaster hip spica was used, but this was unusual.

The results obtained by these techniques during 1943 and the first months of 1944, although relatively satisfactory, were regarded as less than optimum in many instances. Adequate reduction was usually secured with skeletal traction, but it was frequently not ideal, and the alinement obtained in fractures of both the upper and lower third of the femur often left much to be desired. While healing of the compounding wounds by granulation eventually occurred in the majority of cases, the process was undesirably slow and often was attended with heavy scar formation. The incidence of deep-seated abscesses in the posterior fascial planes was not unduly high, though it increased early in 1944, during the attacks on Cassino and at the Anzio beachhead. It was generally observed that infection was most frequent when the fracture had not been reduced or well immobilized or had been distracted and when repeated manipulations had been undertaken to correct these errors. It was often difficult to maintain reduction while the necessary dressing of large compounding wounds was carried out. The location, magnitude, and condition of these wounds complicated the management of the fracture and played a part in the establishment of infection.

During April and May 1944, a survey of fractures of the femur was conducted in six general hospitals and in a station hospital which was then serving as a general hospital in the Naples area, in order to appraise the results of the methods of management employed before the regimen of reparative surgery had been instituted. All of the soldiers studied had been wounded at least 50 days earlier, during the mountain and beachhead fighting in Italy in January, February, and March. They had been cared for under relatively adverse conditions, in overcrowded field and evacuation hospitals which were exposed to enemy artillery fire, including that of the "Anzio Annie" railroad gun. Many had been evacuated over water. They had then been treated in crowded general hospitals, some of which were staffed by surgeons relatively inexperienced in military surgery. During this period, the incidence of clostridial myositis reached its height in the Mediterranean theater, and the hazard of this complication was added to the other problems of fractures of the femur.

A total of 235 patients with fractures of the femur was included in the survey. Three (1.3 percent) died after admission to general hospitals, and amputation was required in two other cases (0.85 percent).

In the remaining 230 cases, adequate reduction had usually been achieved, though the position was not optimal in certain subtrochanteric fractures,

fractures of the distal third, and fractures characterized by loss of bone substance. In some cases, the use of the flexed knee position and of tight popliteal slings for fractures of the lower third of the femur had given rise to such complications as skin irritations; thrombophlebitis; and inability to extend the knee after the fracture had united, because of prolonged stretch of the quadriceps muscle. On the whole, the methods employed had not been conducive to early, maximum return of motion in the knee joint. This was partly because of prolonged knee flexion, partly because of heavy scarring in the thigh, and partly because quadriceps and knee exercises had been inadequate.

Forty-two cases (17.9 percent of the total 235 cases) were either infected at the time of the survey or had been considered infected between the 30th and 50th days after wounding. This number included three cases complicated by clostridial myositis, which in each instance had appeared soon after the patients reached the general hospital. Criteria of infection were purulent exudate draining copiously from the fracture site; purulent collections in fascial planes; or daily temperature elevations, usually to 101° F. or over, with malaise, anemia, and other evidences of toxemia. At the time of the survey, sinuses to the fracture site were present in 23 cases.

In each of the 42 infected cases, the infectious process had been managed by apparently adequate drainage. The fact that sinuses to the fracture site were present in only 23 cases 50 days or more after wounding was taken to mean that in the 19 other cases infection had been controlled and that the fracture site had been sealed off by the healing process. Unfortunately, no data were collected on the number of completely healed wounds, chiefly because the objective of the survey was an investigation (1) of the incidence of infection involving fracture sites and (2) of the sequelae of infection.

The survey of these 235 compound fractures of the femur led to the following conclusions:

1. In the light of the severity of these battle-incurred injuries, it was scarcely to be expected that the proportion of either deaths or amputations could be materially reduced below the present levels.
2. The incidence of infection was relatively low, as was the incidence of sinuses to the bones, but further improvement in both respects seemed possible.
3. Better reduction in so-called problem fractures seemed possible of achievement, as well as faster healing of compounding wounds, with minimal scar formation.
4. Improvement in the range of knee motion and in quadriceps-muscle tone seemed possible if more active attention were devoted to both points.

SOURCE MATERIAL

The observations in the remainder of this chapter were either made personally or were derived from reports submitted by the chiefs of orthopedic sections of various general hospitals in Italy, as follows:

164 compound fractures of the femur treated at the 24th and 64th General

Hospitals, plus 535 additional cases studied from the proceedings of disposition boards on file in the Office of the Surgeon. This is a total of 699 cases (series A).

482 compound fractures of the femur treated at the 21st, 33d, and 300th General Hospitals (series B).

Not all data were available in all cases.

High-explosive shells and mine fragments accounted for the injury in 464 of the 699 cases in series A. Small-arms fire accounted for 222 cases (32 percent), and accidental causes for the remainder. The proportion of injuries attributable to small-arms fire in this combined series is somewhat higher than the proportion estimated for battle wounds in general.

The location of the femoral fracture in the 1,181 cases making up series A and B was the proximal third in 331 cases (28 percent), the middle third in 466 cases (39 percent), and the distal third in 384 cases (33 percent). There was thus no great variation in the involvement of the various levels of the bone. Since it is likely that fractures at the junction of the middle third with the upper or the lower segment were classified as fractures of the middle third, the chances are that each third of the bone was affected in almost equal degree.

In the 535 compound fractures of the femoral shaft making up the disposition boards' material in series A, all but 8 of which were combat incurred, there were 41 injuries (7.7 percent) to the sciatic nerve or to the peroneal or the tibial nerve below the bifurcation of the sciatic nerve. This was almost precisely the same as the 7.1-percent incidence in 133 compound fractures of the shaft included in series B, from the 33d General Hospital. In both series, some of the nerve injuries were incomplete.

THE PROGRAM OF REPARATIVE SURGERY

In spite of the usual severity of their wounds and the frequent necessity for a somewhat prolonged stay in forward hospitals after initial wound surgery, soldiers with fractures of the femur generally reached fixed hospitals in the rear within 5 or 6 days after wounding. Those with associated injuries of the abdomen, chest, or head usually did not become transportable as soon. The great majority of these patients, in spite of the intensive preoperative preparation necessary, could usually be submitted to reparative surgery before the 10th day after wounding (the so-called golden period). In one group of 168 cases, for instance, 57 patients (34 percent) underwent reparative surgery on or before the 7th day after wounding, and only 11.6 percent were not operated on until after the 10th day.

Anatomic conditions and the conditions of the battle-incurred fracture and the compounding wound were both favorable and unfavorable for the application of the program of reparative surgery to the management of compound fractures of the femur. Favorable factors were as follows:

1. The regional anatomy was generally favorable, there being a large amount of highly vascularized soft tissue in this region and only a small amount of easily exposed fascial and tendinous tissue. Fascia lata could therefore be

partly excised without seriously affecting function. The heavy soft tissue of the thigh aided in the obliteration of the dead space by pressure dressings. Dependent drainage could be surgically established through posterior fascial planes if a posterior wound was not available.

2. Loss of bone creating a complete segmental defect was uncommon in compound fractures of the femur. When there was partial bone loss, fragments of bone and periosteum left in situ appeared to have excellent powers of regeneration.

3. If internal fixation was indicated, it was facilitated by the size of the femur, while the depth of the location of the bone made it certain that denuded bone and metal would be well covered by soft parts.

4. Plastic procedures designed to accomplish wound healing were facilitated by the abundant, loose skin of the thigh.

Against these favorable factors were the following unfavorable circumstances:

1. Missiles frequently followed paths through the thigh that, because of difficulties of operative position and approach, made them relatively inaccessible. Anatomic considerations made deep exposure of the thigh difficult. As a result, even after what seemed adequate initial surgery, some devitalized tissue almost invariably remained in the wound.

2. The extensive intermuscular fascial planes of the posterior thigh permitted proximal gravitation of purulent exudate.

3. Although immobilization was essential in the management of the femoral fracture, it prejudiced the ultimate range of knee motion. Knee function is an important criterion in the evaluation of end results, and from this standpoint the results achieved in femoral fractures were sometimes less than optimal.

TECHNICAL CONSIDERATIONS

The surgery of battle-incurred compound fractures of the femur followed closely the general pattern for the reparative surgery of compound fractures (p. 83). With the soldier anesthetized, the transportation splinting provided by the forward hospital after initial surgery (usually a $1\frac{1}{2}$ hip spica but occasionally a Tobruk splint) was removed in the operating room. A Kirschner wire was inserted in the lower femur or proximal tibia, its location being determined by the level of the fracture and the site of the wounds. The extremity was then placed in the 90-90-90 position (fig. 51). This operative position, developed by Maj. Benjamin E. Oblatz, MC, and Maj. Joseph D. Godfrey, MC, at the 23d General Hospital, was invaluable for reparative surgery of battle fractures of the femur. It permitted free circumferential access to the thigh and also provided adjustable balanced skeletal traction as an aid to operative reduction of the fracture.

The depths of the wound and the fracture sites were exposed by gentle retraction. Old blood clot, residual devitalized tissue, and totally free bone fragments were removed.

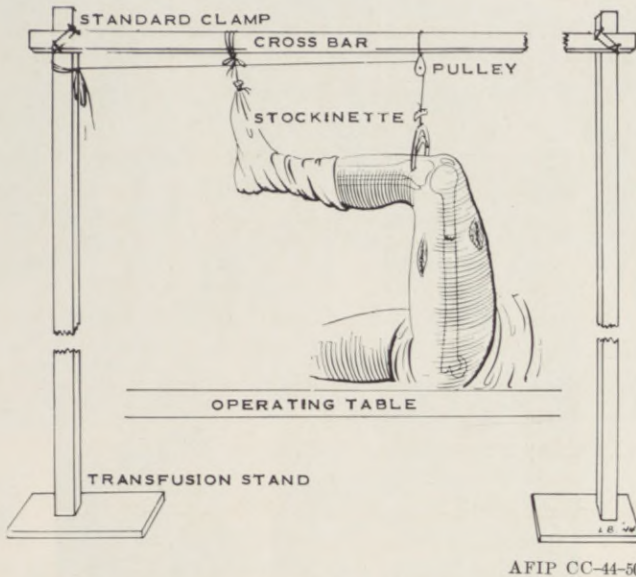
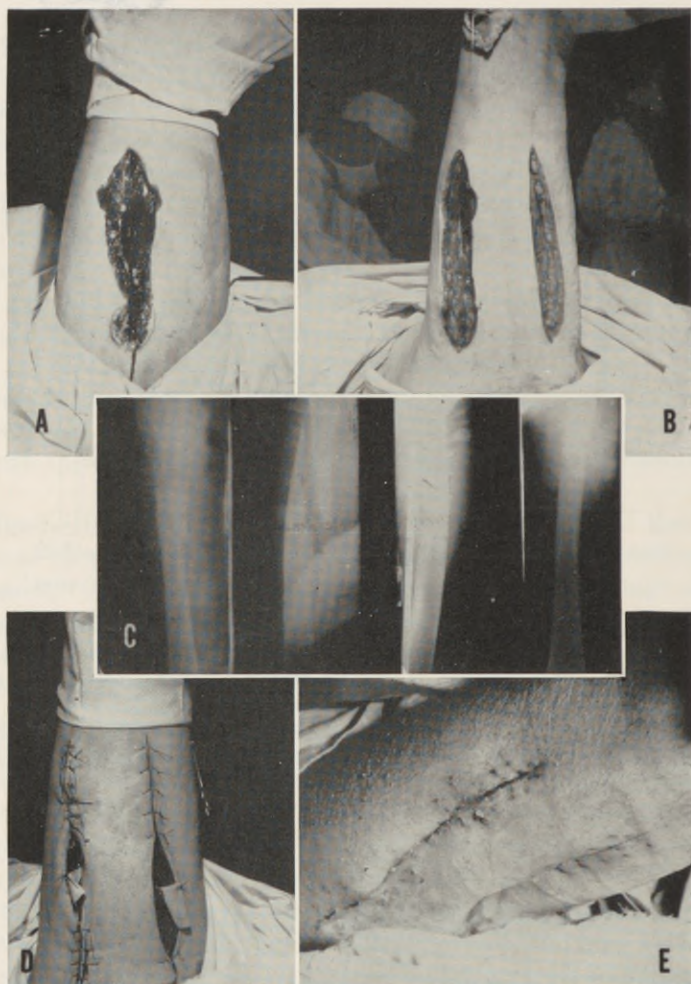

FIGURE 51.—Suspension traction in 90-90-90 position for operation on compound fracture of femur. Kirschner wire shown in upper tibia may also be placed in lower femur. If skeletal traction is not feasible the same position may be maintained by the use of slings under the leg. The 90-90-90 position is an excellent operative position for reparative surgery in injuries of the thigh and femur, since it provides full circumferential access to the part.

A study of the fracture contour by direct vision, together with a study of the roentgenograms, determined whether some form of internal fixation should be employed or whether skeletal traction alone should be depended upon to achieve reduction of the fracture.

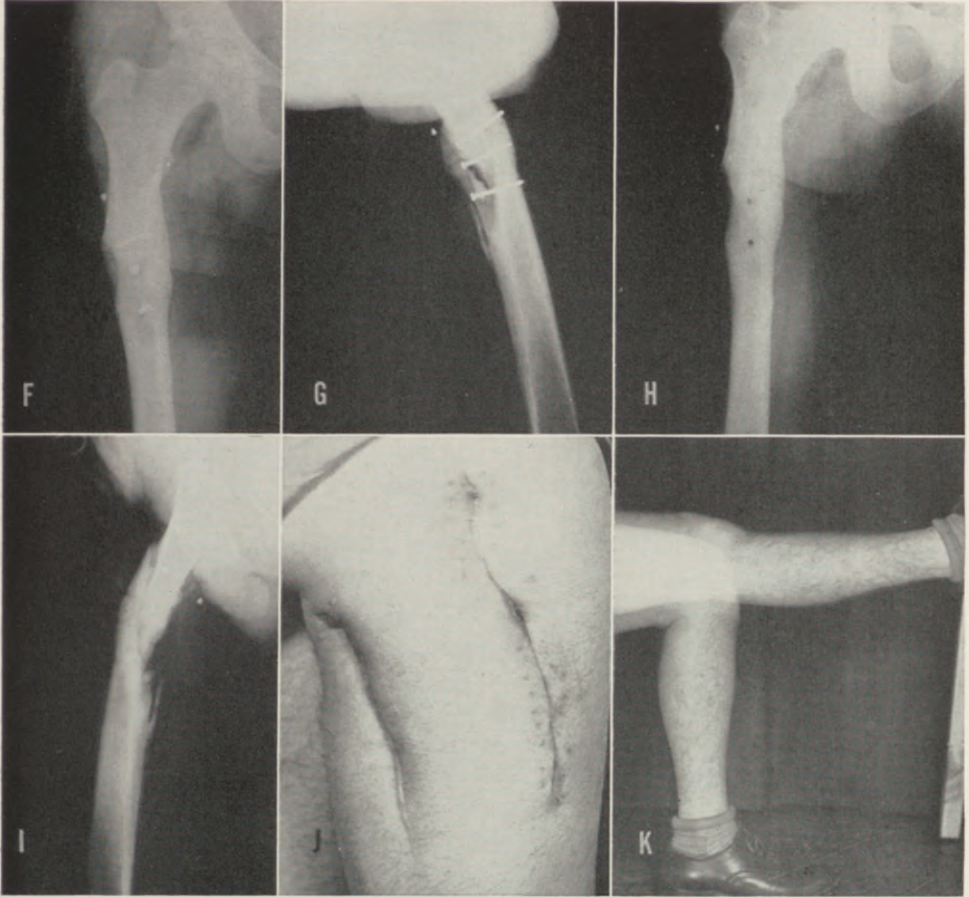
Internal Fixation

The contour of only a minority of the fractures of the femur permitted the effective use of internal fixation. In the majority of cases, therefore, balanced-suspension skeletal traction was the method employed for fracture reduction (figs. 33 and 35). When internal fixation was applicable, it was performed through the compounding wound only if adequate access to the fracture site was permitted (figs. 31 and 35). The standard anterolateral approach was sometimes used but, more frequently, the posterolateral fascial plane was selected (figs. 52 and 34). This plane was considered advantageous because it gave excellent exposure of the shaft of the femur and it could be used for dependent drainage. Moreover, the trauma of the operative procedure was posterior to the bone, and the products of the resulting devitalized tissue were therefore easily drained away.



AFIP Fd-446, Fd-44-65

FIGURE 52.—Management of compound oblique fracture of upper third of right femur by delayed internal fixation, with staged closure of wounds. This patient received initial surgery 7½ hours after wounding, but reparative surgery in the general hospital was delayed until 19 days after wounding because he was afebrile and because of the heavy load of casualties, many of whom required both initial and reparative surgery. A. Appearance of old compounding wound at reparative surgery 19 days after wounding. B. Appearance of limb at completion of reparative surgery. The old compounding wound has been excised. Internal fixation by multiple screws was carried out through the posterolateral surgical incision. Both wounds were left open. C. Roentgenograms before and after internal fixation. The preoperative roentgenograms were made soon after initial surgery, 19 days before the second operation, and do not demonstrate the shortening (1½ inches) which was evident at reparative surgery and which was the indication for internal fixation. D. Partial closure of wounds 7 days after reparative surgery. Each wound has been drained separately; these are not through-and-through drains. E. Appearance of wounds 6 weeks after wounding and 3 weeks after partial staged closure. Although both are almost completely healed at this time, drainage later recurred from the compounding (lateral) wound.



A FIP 3773, 3772, 3809, 3810, 3808, 3807

FIGURE 52—Continued. F. Anteroposterior roentgenogram showing united fracture 6 months after wounding. Note absorption about two lower screws. G. Lateral roentgenogram taken at same time as view F. Note sequestrum. H. Anteroposterior roentgenogram after removal of metal and sequestra 8 months after wounding. I. Lateral roentgenogram taken at same time as view H. In this view, the defect from sequestration on the posterior surface of the femur is clearly shown. J. Solidly healed wounds 4 weeks after removal of metal and sequestrum. K. Range of knee motion 9 months after wounding. The reparative surgery performed on this patient, although unavoidably delayed, followed eminently sound principles. If traction alone had been employed, shortening would almost certainly have resulted. The trauma of internal fixation and the creation of additional devitalized tissue at the first operation of reparative surgery were sound indications for provision of drainage through the two open wounds and for their staged closure. The prompt healing which followed removal of the metal and sequestra was typical of many cases of this kind. (The case was managed by Lt. Col. Roderick E. Begg, MC, and Capt. John E. Manning, MC, at the 46th General Hospital.)

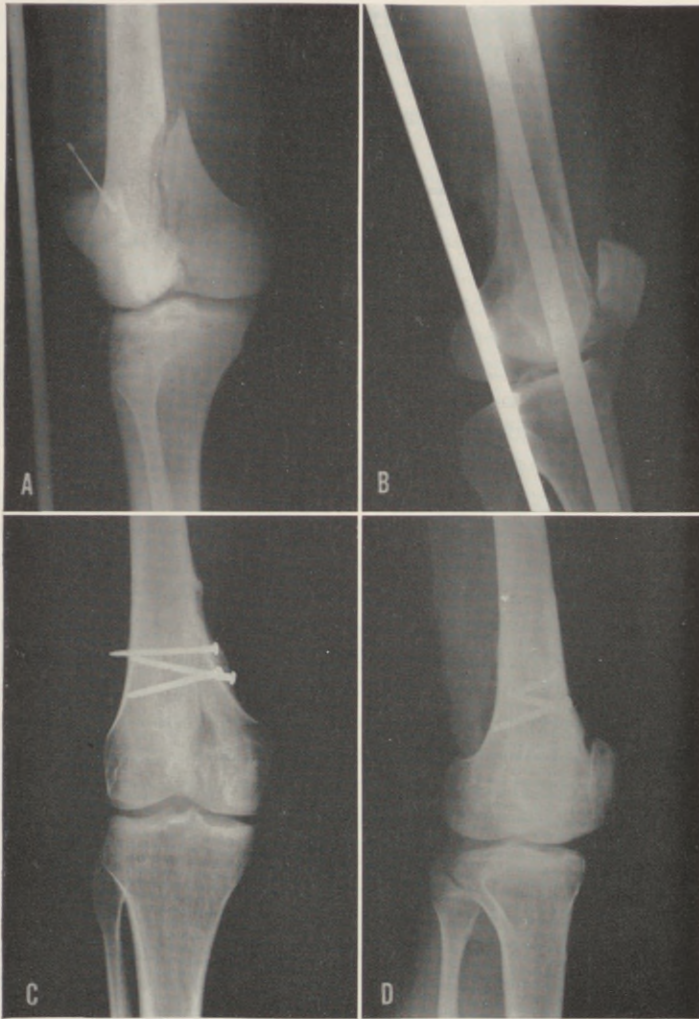The objections to the periosteal stripping necessary in internal fixation were well recognized. On the other hand, the highly vascularized muscular bundles surrounding the femur favored the early reattachment of soft parts to the denuded bone, and there was little hesitancy in performing the stripping required when internal fixation appeared to be useful. Multiple screws were employed in the relatively few fractures with an obliquity permitting stable fixation (figs. 31 and 35). In a larger group, plating, often augmented by additional screws, provided stable fixation (fig. 39). A stabilized internal fixation was considered advantageous for a number of reasons: (1) Optimal reduction of the fracture was assured; (2) subsequent wound care was facilitated; (3) earlier, intensive exercises for the knee joint were possible; and (4) the patient could be transported to the Zone of Interior at an early date, without fear of loss of apposition or of alinement of the fracture. Condylar fractures of the femur were preferably fixed internally to restore joint congruity and to maintain reduction during early joint exercises (fig. 53). The advantages offered by a stabilizing internal fixation thus appeared to outweigh the disadvantages of additional trauma within the wound and the necessary denudation of bone.

In severely comminuted fractures, the judicious use of wire sutures allowed major fragments to be held in apposition. This type of fixation was particularly applicable in fractures with partial loss of substance. It was also valuable in some cases of established infection, in which it was recognized that periosteal stripping should be restricted. The following experiences proved these points:

Capt. John J. Modlin, MC, at the 21st General Hospital, used wire-suture fixation in 33 of a series of 138 fractures of the femoral shaft. In this particular experience, the indications were broadened because of a heavy flow of casualties that made it impossible to render all of the necessary attention to details required for the management of fractures of the femur in balanced skeletal traction. The wire sutures insured apposition of the fragments, and, even though the balanced-suspension skeletal traction could not be adequately adjusted during the first few days after operation to obtain good alinement, it was possible to correct the alinement later. Had apposition of the fragments not been maintained by the wire suture, it is doubtful that late reduction would have been possible.

Maj. Irvin Cahen, MC, 64th General Hospital, reported that internal fixation was used as part of the first reparative operation in 14 of a series of 79 battle fractures of the femur. The fixation was obtained by plating in 8 cases, by multiple screws in 4, and by wire sutures in 2.

In a followup study on delayed internal fixation of battle fractures in the Zone of Interior made by the theater consultant in orthopedic surgery (p. 189), it was found that the procedure had been performed at the first operation of reparative surgery in 93 (64 percent) of 146 fractures of the femur managed by this method. The fixation in this group was by plating in 41 cases (44 percent), by multiple screws in 39 (42 percent), and by wire sutures in 13 (14



U. S. Army photos

FIGURE 53.—Internal fixation of displaced fracture of medial femoral condyle. A and B. Anteroposterior and lateral views of region of knee made in evacuation hospital. Note separation and rotation of medial femoral condyle. C and D. Similar views, 4 months later, showing fracture united in excellent position after internal fixation on 10th day after wounding. Note perfect preservation of contour of articular surface of lower end of femur. Fractures which disturb the relationship of articular surfaces of major joints, as in this injury, require that the fragments be maintained in precise reduction, and internal fixation, performed through the compounding wound at the first operation of reparative surgery, has a definite field of usefulness. (This patient was managed by Lt. Col. George A. Duncan, MC, and Maj. Benjamin W. Rawles, Jr., MC, at the 45th General Hospital.)

percent). The remaining fixations were performed after adequate reduction had not been achieved by skeletal traction.

Wound Management

After the method for maintaining fracture reduction had been determined and internal fixation, if it had been chosen, had been effected, drainage of residual dead space and wound closure were undertaken. Suture of the compounding and operative wounds was performed to the extent that was surgically feasible and was compatible with adequate drainage (figs. 31, 33, 34, and 35). These wounds were not sutured with the major objective of protection of exposed bone. The objectives of wound closure in compound fractures of the femur were early wound healing and minimal scar formation, both of which have a beneficial effect on future function.

Drainage.—It was considered important that some opening, preferably dependent, remain in the wound in most cases to provide a route of egress for the products of possible decomposition of residual devitalized tissue or blood clot. The necrotizing effect of purulent exudate deep in the thigh could thus be avoided. Only very occasionally was drainage omitted.

If posterior wounds were present, they were used for drainage. Otherwise, the posterolateral fascial plane between the biceps femoris and the vastus lateralis was freely incised (figs. 52, 30, 34, and 35). This plane served well for drainage of compound fractures between the level of the base of the trochanter and the level just distal to the junction of the middle and lower thirds of the femur. In high fractures involving the trochanteric region, it was necessary to sever a portion of the gluteus maximus if dependent drainage was to be obtained and the hazard of a pocket of purulent exudate beneath this muscle was to be avoided.

Dependent drainage in the distal third of the thigh was difficult unless a posterior wound was present. Maj. Herbert W. Harris, MC, at the 17th General Hospital, reported some success with a posterolateral incision supplemented by a medial incision anterior to the hamstring muscles. Col. Francis J. Cox, MC, at the 24th General Hospital, considered drainage absolutely essential and established it in all cases. In his technique, the linea aspera was incised, so that there was free communication between a medial thigh space and the posterolateral fascial plane. Maj. Newton C. Mead, MC, at the 12th General Hospital, preferred direct posterior drainage through a channel passing between the hamstring groups to drainage through the posterolateral fascial plane. Fingertip dissection was used from the fracture site to the posterior skin, which was then incised. Damage to the sciatic nerve was thus avoided. In Mead's experience, this method was effective and was not attended by complications.

A posterolateral fasciotomy used for internal fixation was frequently left unsutured for a few days, in order to provide the free drainage permitted by an open wound.

While adequate drainage was considered indicated and important in all these injuries, it was of paramount importance in the presence of dirty wounds and established infection. If considerable dead tissue had been found (and excised) wound closure was postponed. In these cases, suture was often performed several days later, when the wounds were clinically clean.

Postoperative Management

The great majority of the patients with fractured femurs were placed in balanced-suspension skeletal traction immediately upon their return to the ward. This was true even of those whose fractures were stabilized in reduction by internal fixation, in order to facilitate the wound care and to permit an intensive program of knee-joint exercises. The Kirschner wire used in maintaining the operative position in the operating room usually sufficed for traction on the ward. If a different location appeared desirable, a new wire was inserted immediately. The theoretical objections to the location of the wire in either the lower femur or the tibia were disregarded, and the site was chosen that appeared to be the most effective for reduction of the fracture. In general, the lower femur was the location for the wire in fractures of the upper half of the bone and the tibia for fractures of the lower half.

An important early development in the reparative surgery of compound fractures of the femur was the introduction of two-wire or double skeletal traction for fractures of the distal third of the femur (fig. 54). The tibial wire for longitudinal traction was supplemented by a femoral wire for vertical traction, which served to lift the ever-troublesome distal fragment into alignment. This simple method, developed by Captain Modlin and Major Cahen, at separate hospitals, went far to solve the problem presented by lower-third femoral fractures.

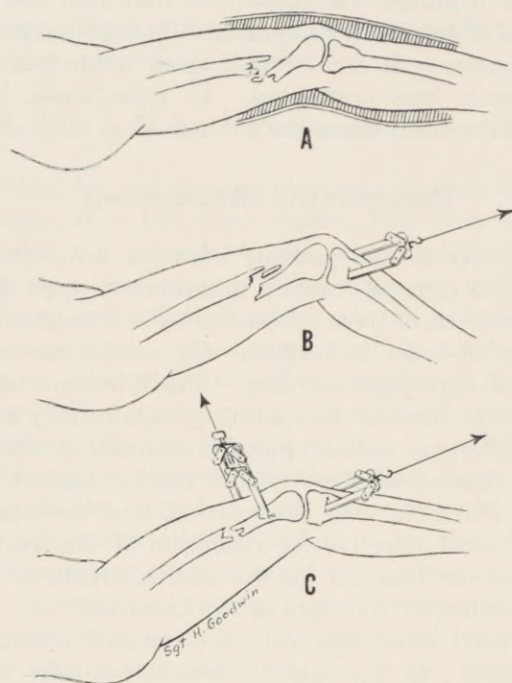
Table 7 shows the location of the wires for traction in 613 compound fractures of the femur. These data do not include cases in which skeletal traction was used after internal fixation.

TABLE 7.—Location of Kirschner wire for skeletal traction in 613 compound fractures of femur

Source	Proximal (femur)	Distal (tibia)	Femur and tibia ¹	Total
21st General Hospital.....	62	88	45	195
64th General Hospital.....	16	16	12	44
Proceedings, disposition boards ²	134	205	35	374
Total.....	212	309	92	613
Percentage.....	34.6	50.4	15.0	100.0

¹ Two-wire technique.

² From files, Office of the Surgeon, Mediterranean Theater of Operations.



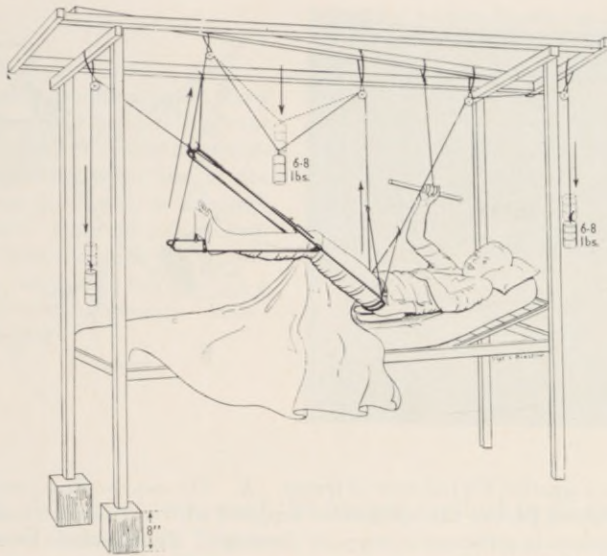
AFIP CB-44-55

FIGURE 54.—Diagrammatic showing of two-wire skeletal traction for battle fracture of femur. A. Deformity on admission to fixed hospital. B. Incomplete reduction in skeletal traction with wire in tibial tubercle. C. Adequate reduction after additional wire has been inserted in lower femoral fragment and vertical lift has been secured.

Technique of balanced-suspension skeletal traction.—Four methods of balanced-suspension skeletal traction for fractures of the femur were used in the Mediterranean theater. Each offered certain advantages and disadvantages. It was considered desirable that flexion of the knee be held to 15° or 20° in order to avoid continuing stretch on the quadriceps muscle, prevent fixation of the ligaments of the knee joint while the joint was in flexion, and facilitate quadriceps-setting exercises. The degree of flexion of the knee was therefore an important consideration in the selection of the method of balanced-suspension skeletal traction.

The four techniques of balanced-suspension skeletal traction included—

1. The Army half-ring splint with Pierson attachment (fig. 55). This method was applicable to fractures of the shaft requiring the pressure of a sling posteriorly as an aid in the maintenance of reduction. It was the preferable method of splinting for two-wire traction for fractures of the lower third of the femur. An outstanding advantage was that it permitted active and passive knee motion with little or no strain at the fracture site. The principal



AFIP CC-44-48

FIGURE 55.—Balanced-suspension skeletal traction by means of half-ring leg splint and Pierson attachment. Note balance as patient raises himself for bedpan. Knee flexion shown is more than advisable.

disadvantages of the method were pressure of the ring on wounds high in the thigh and the inaccessibility of posterior wounds for necessary dressings. The pressure of the ring posteriorly could be avoided by placing it anteriorly. Major Mead made effective use of this modification of the method in fractures of the upper third of the femur with posterior wounds. Pressure of the ring on the anterior superior spine of the ilium was prevented by increasing the weight lifting the upper end of the splint. Access to posterior wounds was easier but still awkward.

2. The Navy (Joldersma) method (fig. 56). This method was excellent for fractures of the upper third of the femur and could be used for the majority in the upper half. After the development of two-wire traction, it was used for some fractures of the lower third. The application of the original setup was cumbersome, but the modifications by Captain Modlin (fig. 57) and Major Albert O. Linch, MC (fig. 58), were excellent simplifications. The principal advantages offered by the Navy method of splinting were ready access to all surfaces of the thigh for subsequent wound care, the ease of nursing care, and the comfort experienced by the patient.

The great disadvantage of the Navy method was that it did not permit knee-joint exercises. Therefore, after sufficient healing of the wound and formation of so-called chewing-gum callus formation at the fracture site, this method was preferably replaced by the Army half-ring splint with Pierson attachment.

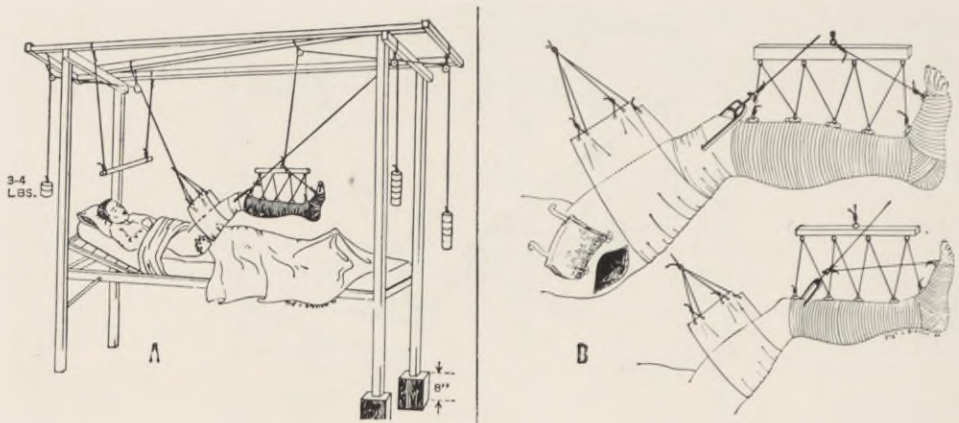


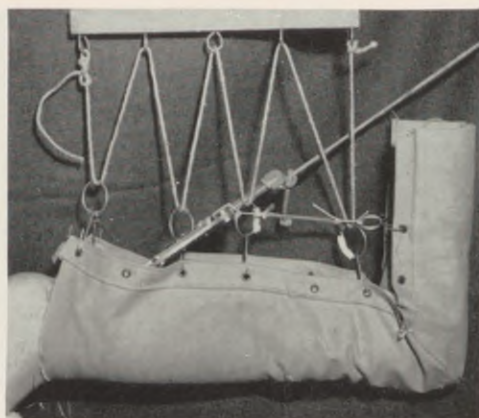
FIGURE 56.—Navy traction for fracture of femur. A. The canvas sling around the posterior thigh is a standard part of the equipment supplied with a Balkan frame. A weight of only 3 or 4 pounds is sufficient to support the thigh. The excellent balance between the traction and the leg suspension maintains alinement, and elevation of the foot of the bed provides countertraction against the weight of the body. B. Details of leg suspension in Navy traction shown in view A. Canton flannel is applied over sheet wadding, each turn overlapping all but about one-quarter inch of the preceding turn. Internal or external rotation of the lower femoral fragment is obtained, in Navy parlance, by moving the pins "inboard" or "outboard." The string, which is of smooth material, glides easily through the safety pins and rings on the crossboard. Note the excellent functional position of the foot.

3. The 90-90-90 method (fig. 59). This method, developed by Maj. Benjamin E. Oblatz, MC, and Maj. Joseph D. Godfrey, MC, at the 23d General Hospital, and mentioned as an excellent operative position (p. 142), was sometimes used for fractures of the upper third of the femur. Its principal advantage was that, like the Navy method, it provided access to wounds high in the posterior thigh. Its outstanding disadvantage was the prolonged flexion of the knee to 90°. There was also danger of distraction. As a technique of balanced-suspension skeletal traction for compound fractures of the femur, the 90-90-90 method had only a limited application. When it was used, it was preferably replaced by a conventional method after 2 or 3 weeks. As a rule, an orthopedic section did not use both the Navy method and 90-90-90 (vertical) traction, since the Navy setup appeared to offer all the advantages of the 90-90-90 method without its disadvantages.

4. Russell traction. This method, which was used very occasionally for fractures of the upper third of the femur, offered no advantages over those already described.

Captain Modlin and Capt. Russell J. Crider, MC, at the 21st General Hospital, in a series of 185 compound fractures of the femur, employed the Army half-ring splint with Pierson attachment in 107 cases (58 percent) and the Navy method in the remaining 78 cases (42 percent). Major Cahen, in

FIGURE 57.—Modlin modification of Navy traction for fracture of femur. Both the application and the removal of the whole setup are facilitated by the use of the canvas sling, and the patient is also kept more comfortable. Note the plasma tubing, extending from the clevis to the foot support, which maintains the foot at a right angle but still permits active motion in the ankle.



AFIP C-44-363


a smaller group of 45 fractures, used the former method in 26 cases, the latter in 17, and Russell traction in 2 cases.

Quadriceps exercises and knee motion.—The early, definitive reduction of fractures of the femur after balanced traction was instituted was considered important in the prevention of deformity and sepsis. Repeated manipulations of the fractures and major adjustments of the traction setup were traumatizing to tissue and prejudicial to healing of the wounds. Quadriceps exercises and a program for knee motion were desirable as soon as the wounds had healed sufficiently and fracture reduction would not be disturbed. In internally stabilized fractures, these objectives could be accomplished about 10 or 12 days after the operation. In fractures managed entirely by skeletal traction, exercises and movement were usually postponed until about 3 or 4 weeks after repair of the wound.

Ideal program.—An ideal program for the management of femoral fractures in skeletal traction, developed by Captain Modlin at the 21st General Hospital in Naples, was as follows:

The anesthesia provided for the surgery of the fracture and wound was continued on the ward while the balanced-suspension skeletal traction was set up. The fracture was manipulated into apposition and alinement, and the traction apparatus was adjusted to maintain the correct position. Roentgenograms were made immediately. If they showed that adequate reduction had not been achieved, the fracture was remanipulated, and the apparatus was adjusted again. Adequate reduction was usually achieved by these procedures, but additional roentgenograms were made the following day, and, if needed, further adjustments of the traction apparatus were made. This routine was followed daily, if necessary, until satisfactory reduction had been achieved. Thereafter, each traction setup was inspected carefully several times each week, and checkup roentgenograms were made every 7 to 10 days.

The patients were all placed on a high-protein, high-caloric diet. The hemoglobin, plasma-protein, and hematocrit values were checked at intervals



AFIP Fd-44-12

FIGURE 58.—Linch modification of Navy traction for fracture of femur. The cumbersome board and string of the original technique are replaced by multiple pulleys. A light metal splint can be substituted for the leather support.

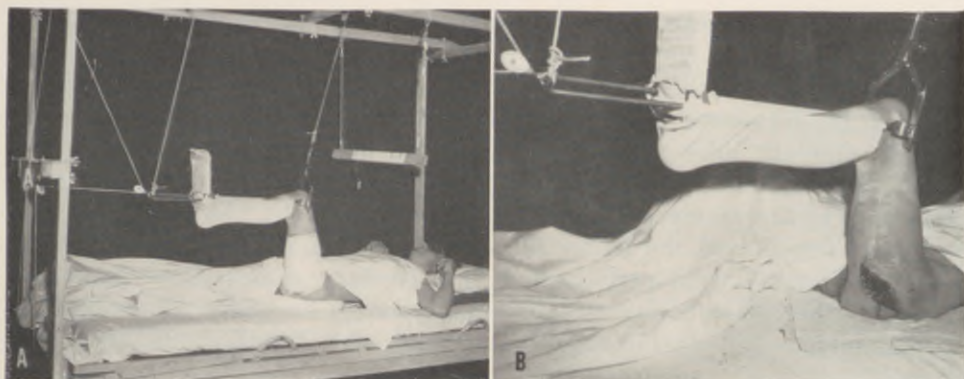
of 3 or 4 days, and blood-replacement therapy was employed to correct deficits.

A supervised program of quadriceps and knee bending exercises was begun at the earliest practical time. This was usually about 3 weeks after wounding. The physical therapists attached to the hospital visited the femur ward 3 times weekly to supervise the program, but exercise periods were conducted daily under the observation of the ward nurses. Competitive exercises among the soldiers with femoral fractures were helpful in stimulating interest.

This regimen was observed to pay dividends in excellent fracture reductions, minimal infection, and good knee motion.

Duration of traction.—Skeletal traction for fractures of the femur was preferably maintained until after clinical stability had become evident and there was roentgenologic evidence of bony union of the fracture or, in the exceptional case, until hope of union in the theater had been abandoned. The usual time in traction for compound fractures of the upper and middle thirds of the femur was about 10 or 11 weeks, although when casualties were heavy the time in traction sometimes had to be shortened. Fractures in the lower third of the femur appeared to unite rapidly and usually required only 6 to 8 weeks in traction. The longer period was considered absolutely necessary in fractures above this level, to avoid late angulation. The late weeks of traction were utilized to improve the range of knee motion.

When sufficient union of the fracture had occurred to permit the discontinuance of the traction, a $1\frac{1}{2}$ plaster hip spica extending only to the iliac crests was applied as transportation splinting for the transfer to the Zone of



U. S. Army photos

FIGURE 59.—Skeletal traction by 90-90-90 suspension method for fracture of left femur.

A. Traction applied. B. Same as view A. Note ease of access to high posterior wound of thigh. This position, because of its possible adverse effect on the knee, should not be maintained for more than 2 or 3 weeks.

Interior. A followup study in the Zone of Interior in 1945 (p. 189) revealed instances of fractures of the femur which had been removed from traction before firm union and which had bowed during transportation in the cast. Several of these fractures had become fixed in angulation during that period. These observations were added evidence that a hip spica will not prevent angulation of a fracture of the femur and that a period of 10 to 12 weeks in traction is required for the majority of these injuries if the optimal result is to be achieved.

Captain Modlin and Captain Crider at the 21st General Hospital reported that in 177 compound fractures of the femur observed at that hospital the average duration of skeletal traction was 12 weeks. Maj. William R. Ferguson, MC, at the 33d General Hospital, reported an average traction time of 90 days in 140 fractures. In the 535 fractures of the femur studied from the proceedings of disposition boards on file in the Office of the Surgeon, Mediterranean Theater of Operations, the average time in traction was only 8.6 weeks. It is known, however, that traction was prematurely discontinued in many of these cases because of the stress of heavy casualty loads.

Other methods of fracture management.—A small but definite number of fractures of the femoral shaft were not adequately reduced in skeletal traction. In these cases, if it appeared that satisfactory apposition and alignment could be achieved by an open reduction and internal fixation, the necessary surgery was carried out. Faulty reduction of the fractures was not accepted if it could be prevented by open reduction and internal fixation. Either the old compounding wound was reopened or a separate operative incision was made. The internal fixation and the subsequent management of the soft-part wound conformed to the basic principles already described.

Ideally, of course, the compounding wounds were healed by the time that operative intervention for the unreduced fracture had been selected, so

that the operative procedure was carried out not on a fracture that was still compound but, in a restricted sense, on a simple fracture. The hazard of infection was therefore minimal. The unreduced fracture was, however, likely to be associated with an unhealed, draining compounding wound or wounds, and not infrequently definite wound infection was present. As a result, the majority of late internal fixations of fractures of the femur were performed in the presence of unhealed wounds. In the 146 internally fixed compound fractures of the femur surveyed in the Zone of Interior (p. 194), 53 (36.3 percent) were performed at a secondary operation of reparative surgery. The compounding wounds were recorded as healed at the time of the fixation in only 5 cases (3.4 percent). They were unhealed in the remaining 48 cases.

Two other methods of managing these major skeletal injuries were used infrequently. One was immobilization in a plaster cast, the other, external fixation.

Plaster hip spicas (usually the $1\frac{1}{2}$ spica, though in one hospital a complete double spica was used) were employed in a few selected cases in which apposition and alinement were excellent on admission. Bone loss, in which distraction of fragments was feared if traction were employed, formed another indication for the application of a plaster hip spica. Several surgeons in the theater preferred the hip spica for fractures associated with a well-drained established infection. Occasionally, heavy casualties and a demand for hospital beds influenced the adoption of the plaster spica as the method of fracture management because it permitted early transfer to the Zone of Interior.

In spite of the usefulness of the plaster hip spica in occasional special cases, observations over the theater led to the conclusion that balanced-suspension skeletal traction, with or without internal fixation, was the preferable method of management in the overwhelming majority of compound fractures of the femur.

External skeletal fixation was not a popular method. In the series analyzed, it was employed only 19 times (table 8).

Distribution of Methods of Fracture Management

Table 8 shows the methods of fracture management used in the several series forming the basis of this study. Although skeletal traction was employed after the great majority of internal fixations, the data for this technique include only cases in which skeletal traction was used without internal fixation.

Table 9 shows the type of metallic internal fixation employed in 284 cases in these series. The 21st General Hospital series is unusual in that 40 of 74 internal fixations of fractures of the femur (54 percent) were performed with wire sutures. This relatively high incidence has already been explained (p. 146). The 24th General Hospital also employed wire-suture fixation in a high percentage of cases.

TABLE 8.—*Selection of methods of fracture management in 1,063 compound fractures of femoral shaft*

Source	Skeletal traction	Internal fixation	Plaster cast only	Russell traction	External skeletal fixation	Total
21st General Hospital.....	152	74				226
24th General Hospital.....	48	27	4		1	80
33d General Hospital.....	112	22			9	143
64th General Hospital.....	43	34		2		79
Proceedings, disposition boards ¹	325	149	52		9	535
Total.....	680	306	56	2	19	1,063
Percentage.....	64	28.8	5.2	.2	1.8	100

¹ From files, Office of the Surgeon, Mediterranean Theater of Operations.

TABLE 9.—*Techniques of internal fixation in 284 fractures of femoral shaft*

Source	Plates	Multiple screws	Wire sutures	Total
21st General Hospital.....	12	22	40	74
24th General Hospital.....	6	8	13	27
64th General Hospital.....	15	13	6	34
Proceedings, disposition boards ¹	87	42	20	149
Total.....	120	85	79	284
Percentage.....	42.3	29.9	27.8	100

¹ From files, Office of the Surgeon, Mediterranean Theater of Operations.

APPRAISAL OF RESULTS

Casualties with fractures of the femur remained in general hospitals a sufficiently long time to allow an appraisal of wound healing (table 10) and, usually, of union of the fracture. Even patients treated by stabilizing internal fixation of the fractures remained for several weeks, and traction for those treated by other methods was continued for 8 to 12 weeks. A fairly long term appraisal of results was possible. Important data on the results achieved from the viewpoint of an overseas theater concerned the deaths, amputations, healed wounds, wounds healed except for small granulated areas without sinus formation to bone, sinuses to bone, infected fractures, and the quality of fracture reductions.

TABLE 10.—*Appraisal of wound healing in 825 compound fractures of femoral shaft at time of disposition*

Source	Status of wounds				Total
	Healed	Healed except for small granulating areas	Sinus formation to bone	Infected fracture sites	
21st General Hospital (experience in Italy only).....	29	23	22	5	79
33d General Hospital.....	70	37	22	4	133
64th General Hospital.....	52	14	12	-----	78
Proceedings, disposition boards ¹	249	219	50	17	535
Total.....	400	293	106	26	825
Percentage.....	48.5	35.5	12.9	3.1	100

¹ From files, Office of the Surgeon, Mediterranean Theater of Operations.

In September 1944, a survey was made in seven general hospitals in Naples and Rome to gather data on the results achieved in compound fractures of the femur after the institution of the so-called reparative triad; that is, penicillin, blood replacement, and precise surgery. The evaluation was made on each patient by the chief of the orthopedic section of the hospital, after overseas management had been completed and transfer to the Zone of Interior was imminent.

Data secured in the 277 cases of compound fractures of the femoral shaft reported in this survey follow:

	Number	Percent
Deaths.....	2	0.7
Amputations (exclusive of those caused by damage of major vessels at wounding).....	2	.7
Infection at some period more than 30 days after wounding (as evidenced by fever and purulent drainage from fracture site).....	35	12.6
Sinus formation to fracture site at time of disposition.....	29	10.5

A comparison of these data with those gathered on a similar group before the advent of penicillin, full blood replacement in the fixed hospital, and reparative surgery (p. 139) revealed no appreciable change in the incidence of deaths and amputations. The incidence of persistent sinus formation was about the same in each group. There was, however, a smaller proportion of infected fractures at some period 30 days after wounding (12.6 percent against 17.9 percent).

Persistent sinuses were undoubtedly indicative of sequestrum formation and were not necessarily a criterion of failure of management. In severely comminuted fractures, with many partially denuded fragments, some sequestration was often inevitable. During the survey in the Zone of Interior in early 1945 (p. 191), it was repeatedly observed that sound wound healing followed removal of sequestra, provided that reasonably healthy soft tissues were available. Therefore, while sequestration was undesirable, its development did not necessarily prejudice the end result.

An accurate appraisal of the quality of reduction of the fractures of the femoral shaft in the series studied was not possible. It is known that adequate reduction was achieved in the great majority of all cases. Improvements in techniques of skeletal traction and the use of an aggressive surgical approach, combined with internal fixation if it was thought advantageous, prevented malposition and malalignment. The concept of the management of these injuries was that (1) the fractures should be reduced and maintained in reduction by whatever means were required; (2) that this objective could be reached without endangering life or limb; and (3) that wound healing would seldom be retarded but, if it were, that the end result, as measured by the function of the extremity, would still be greatly improved. Inadequate fracture reduction was therefore seldom accepted, and the statement that fractures of the femur were usually adequately reduced is regarded as justified.

Data concerning the healing of the wounds in these series have been compiled in table 10. Healing in wounds with small granulating areas was considered satisfactory; there was no opening to the fracture site in these cases, and healing processes had converted the compound fracture into a simple fracture. It is known that many wounds in which granulating areas were recorded on disposition in the theater were healed when the transportation plaster hip spicas were removed in named general hospitals in the Zone of Interior. Infected wounds presented profuse, purulent drainage from the fracture site. These fractures were usually those associated with severe damage and loss of soft tissue. The heavy drainage probably indicated relatively heavy sequestration. Nonunion of the fracture was not necessarily present.

CONCLUSIONS

The regimen of reparative surgery as applied to battle-incurred fractures of the femur in the Mediterranean theater and as evaluated overseas produced minimal sepsis, improved reduction of fractures, earlier wound healing with minimal scarring, and improved quadriceps power and range of knee motion without increased morbidity or mortality. Morbidity, in fact, appeared to have decreased. The final appraisal of the end results could be made only in the Zone of Interior, after the function of the extremity had been resumed. It is believed, however, that the regimen paid rich dividends in the prevention of deformity and the functional restoration of these severely wounded extremities.

Part III. Compound Fractures of the Tibia and Fibula⁵

Although results in certain compound fractures were reasonably satisfactory when the program of reparative surgery was introduced in the Mediterranean theater in the spring of 1944, fractures of the tibia and fibula were not included in the group. The management of the fractures of one bone (the tibia or the fibula) seldom offered difficulties. The management of fractures of both the tibia and the fibula constituted a major problem, which cried aloud for solution, and it is fortunate that both bones were injured in not more than a quarter of all wounds of the leg.

The results being obtained in the theater in the spring of 1944 in fractures of the tibia and fibula did not meet the standards considered desirable and possible in the overseas management of these injuries. For this failure, there were a number of reasons:

1. When manipulation and traction, correctly applied, had failed to achieve adequate reduction, the failure was frequently accepted as the best that could be achieved under the circumstances because operative interference was considered too hazardous. The fear of infection was easy to understand, for there had been a fairly high incidence of locally necrotizing wound infection in wounds involving these fracture sites.

2. Wound discharges often pooled in dead spaces about unreduced fractures of the tibia.

3. Even when healing by granulation proceeded at a rate accepted as normal, it was a slow process and was always attended with scar formation, often of massive degree.

4. When tibial cortex was left exposed, in the expectation that it would be covered by granulations, sequestration almost invariably resulted.

THE REPARATIVE-SURGERY PROGRAM

Compound fractures of the tibia and fibula therefore seemed, at least at first glance, to offer a peculiarly fertile field for the application of the new program of reparative surgery. Its components—surgical closure of compound wounds; adequate reduction of fractures, by surgical measures if necessary; and dependent drainage of residual dead space—were all designed to overcome the chief failures of the earlier, nonoperative plan of management, with healing by granulation. The situation, however, was not as hopeful as it seemed. All the factors which were so favorable to the program in fractures of the femur were unfavorable in fractures of the tibia and fibula because—

1. Injuries of these bones were frequently associated with a significant degree of bone loss. This fact accounted for delays in union and for many

⁵The statistical material in this section was provided by Maj. William R. Ferguson, MC, and Capt. Robert B. Gottschalk, MC, 33d General Hospital; Lt. Col. George A. Duncan, MC, Maj. R. D. Butterworth, MC, Maj. Benjamin W. Rawles, Jr., MC, and Capt. Beverly B. Clary, MC, 45th General Hospital; Maj. Joe M. Parker, MC, and Capt. Francis R. Crouch, MC, 21st General Hospital; and Maj. Otto E. Autofrance, MC, 6th General Hospital.

instances of nonunion and was a serious consideration in an extremity in which full weight bearing and almost full length are essential for normal gait.

2. Many difficulties lay in the way of obtaining and maintaining reduction and fracture union in an extremity in which excellent alinement is almost essential for normal gait. In civilian practice, delayed union or nonunion is not infrequent in fractures of the bones of the leg.

3. The large anteromedial surface of the tibia lies just under the subcutaneous tissue. As a result, the cortex was often exposed at wounding. Since there are no highly vascularized tissues in this area—even the covering skin is thin and light—closure of compounding wounds located over the anteromedial surface of the tibia was always difficult. In addition, there was frequently a significant loss of tissue at wounding, so that closure without tension was often impossible.

4. Posterior dependent drainage of residual dead space was always difficult to obtain in this area unless there was a large compounding posterior wound.

5. The type of combined bone and nerve surgery which gave such excellent results in compound fractures associated with nerve injuries in the upper extremity was not practical in the leg. Fortunately, the incidence of these combined injuries, while somewhat greater than in compound fractures of the femur, was considerably less than in compound fractures of the shaft of the humerus.

These unfavorable factors, while they did not prevent the full utilization of the program of reparative surgery in compound fractures of the bones of the leg, obviously handicapped it before it was instituted.

ANALYSIS OF CASES, 1944-45

The observations in this chapter, in addition to the personal observations, are based on the following collected data:

347 fractures of the tibia, fibula, or both bones treated from June 1944 through May 1945 at the 33d General Hospital.

638 fractures of the tibia, fibula, or both bones treated at the 45th General Hospital during 1944.

279 fractures of the tibia or the tibia and fibula treated at the 21st General Hospital during the last 6 months of its operation.

219 fractures of the tibia, fibula, or both bones treated at the 6th General Hospital from July through December 1944.

654 fractures of the tibia, fibula, or both bones studied from the proceedings of disposition boards in the Office of the Surgeon, Mediterranean Theater of Operations, and filed after 1 May 1944.

Practically all of these 2,137 fractures were managed after the reparative-surgery program became effective throughout the theater in the spring of 1944. As usual, not all desired data were available in all series.

All the hospitals from which material was procured functioned in the Mediterranean theater. The material from the 21st General Hospital, which served as one of the supporting hospitals in the invasion of southern France, also

covers the period after December 1944, at which time it came under the Chief Surgeon, European Theater of Operations.

Fractures of the bones of the leg were the most frequent fractures encountered in the Mediterranean theater. The 638 cases handled at the 45th General Hospital during 1944 may be taken as representative. These cases represented 21 percent of all compound fractures and 24 percent of all compound fractures of the extremities admitted during this period. When fractures of the bones of the hand and foot are excluded from the calculations, the proportion rises to 37 percent. Fractures of the bones of the leg also represented 4.6 percent of all battle injuries treated at the 6th General Hospital from July through December 1944.

The most detailed information on the causes of compound fractures of the tibia and fibula was available from the 654 cases studied in disposition-board proceedings. Details were available for 506 battle injuries and for 116 injuries classified as nonbattle, as follows:

High-explosive shell fragments from artillery, mortars, mines, or grenades accounted for 345 of the 506 battle injuries (68.2 percent). Small-arms fire accounted for the remaining 161 cases.

The 116 nonbattle injuries constituted 18.6 percent of the total series (622 cases) in which this information was available. The largest group of fractures, 71 (61.2 percent), were caused by vehicular accidents. Falls accounted for 17 cases (14.7 percent), injuries from falling objects for 13 (11.2 percent), and airplane crashes during training for 11 (9.5 percent). Explosions accounted for 3 cases and a railroad accident for the remaining case.

Information as to the site of the fracture was available in 1,855 of the 2,137 cases analyzed in this chapter. The tibia alone was fractured in 819 instances (44.1 percent), the fibula alone in 523 (28.2 percent), and both bones in 513 (27.7 percent).

Information as to the presence or absence of associated nerve injuries was complete in 481 of the 498 cases from the 21st and 6th General Hospitals. In this group, there were 13 injuries of the tibial nerve and 47 of the peroneal nerve, a combined total of 60 injuries (12.5 percent). This percentage is to be compared with 7.7 percent in combined injuries in compound fractures of the femur (p. 141) and 41.6 percent in compound fractures of the humerus (p. 128).

WOUND MANAGEMENT

Detailed data are not available on the preoperative management of patients with compound fractures of the bones of the leg in the general hospitals of the Mediterranean theater. It is known, however, that they were usually received in these fixed hospitals by the fifth or sixth day after wounding unless concurrent injuries required a longer stay in forward hospitals. They had usually received one or more transfusions of whole blood in forward areas, but additional transfusions were usually required, in the amount of 1,000 to 2,000

cc., before hematocrit readings reached the minimum level (40) regarded as safe for surgery.

In the absence of specially unfavorable circumstances, the reparative operation could usually be undertaken well before the 10th day after wounding. In 100 consecutive cases treated at the 33d General Hospital, the average was 6 days. In 297 cases studied in disposition-board proceedings, the average was 8.5 days.

Management of the wound in compound fractures of the tibia and fibula presented certain special problems. The first had to do with bone fragments. Completely detached fragments of cortical bone were frequently found free in the large marrow cavity of the tibia. Because they were potential sequestra, their removal was imperative. Sharp, projecting ledges of bone were removed by rongeur.

The second problem had to do with wound closure. Loss of tissue was frequent. Even when the skin edges could be brought together without tension, healing was often prejudiced by dead space, which was usually present and which often could not be obliterated or effectively drained. In the early days of the reparative-surgery program, wound closure was often made more difficult by the use, in forward hospitals, of longitudinal incisions, with a long transverse axis, through the center of the combat wound. The crucial type of defect which resulted was almost impossible to close satisfactorily. Eventually, surgeons in forward hospitals recognized this difficulty and thereafter converted such wounds into a modified Z by the use of proximal and distal incisions made from opposite corners. Closure was greatly simplified when such an incision was used at initial wound surgery.

It required discriminating judgment in many cases to decide to close the wound, perhaps with the aid of relaxing incisions or the advancement of flaps (figs. 36 and 40), or to leave it partially or completely open, in the expectation that the defect would heal by granulation (fig. 42). The importance of covering all denuded cortical bone, and preferably the entire fracture site, with soft parts was well recognized and was a major objective of wound closure in compound fractures, but deliberate acceptance of the closed plaster technique, with healing by granulation, was sometimes the wiser choice when there was extensive loss of soft tissue or when dead space was present that could not be obliterated.

Even if closure was considered safe, drainage was always necessary in wounds of the leg because some residual dead space was invariably present and deep abscess formation was always a possibility if drains were not used. It was found best to provide drainage by soft rubber tissue or fine-mesh gauze and to allow the drain to emerge from the residual dead space through the sutured wounds. Attempts at dependent drainage through the posterior compartment of the leg were seldom successful, and the trauma of the incision or erosion from the drainage material introduced the risk of damage to regional vessels and nerves. When the compounding fractures were anterior, as they

usually were, the solution of the problem was to keep the patient in the prone position for a week or 10 days after wound closure. This position effectively prevented puddling of blood and wound exudate in the bony defect.

When the decision was made to leave the wound partially or completely open, the defect was loosely filled with dry, fine-mesh gauze, and the patient was nursed in the prone position for a week or 10 days.

Still another contingency that had to be considered in injuries of the leg was how to manage a wound that had required extensive revision at the first operation of reparative surgery. In such cases, the best plan was to leave the wound open for 5 to 7 days after operation, to take advantage of the good drainage provided by the wide-open incision. In some hospitals, this plan was routine in fractures of the tibia and fibula managed by internal fixation. When delayed closure was undertaken at the appropriate time, which might be 14 days or more after wounding, it was usually possible to close the skin edges without tension by the use of relaxing incisions or by shifting of flaps of skin. The newly created skin defects were usually covered with split-thickness skin grafts at the same operation.

FRACTURE MANAGEMENT

Fractures of the Tibia or the Fibula

As has already been stated, fractures of either the tibia or the fibula seldom introduced problems of management, particularly when the injury was in the fibula. Even when it was in the tibia, plaster immobilization usually met the needs of the situation. The majority of United States orthopedic surgeons entered upon military duty with the expectation of managing all fractures of the tibia and fibula, whether alone or in combination, chiefly by plaster. Reports from the Spanish Civil War and reports of British surgeons of their experiences earlier in the war supported this point of view.

All plaster casts on the leg were so applied as to hold the knee and ankle joints in physiologic position. The arches of the foot were well molded. Unless muscle or nerve injury required support of the toes, the plaster was trimmed back to the metatarsal heads, so that full flexion of the toes would be possible. A wire or plaster loop incorporated in the cast protected the foot from the pressure of bed clothing and other trauma.

Fractures of the fibula.—The management of fractures of the fibula was simple unless the external malleolus was destroyed. In many such cases, only molding in plaster was possible. Bone loss in the shaft was seldom of significance. Immobilization in plaster was provided for several weeks but was not necessarily maintained until bony union was complete. The early removal of the cast permitted muscle and joint exercises during the final stages of fracture healing and played an important part in reducing the period of disability.

Compound fractures of the fibula were among the few compound battle fractures that allowed the return of soldiers to full duty status in a theater of

operations. In 155 fractures of the fibula treated at the 45th General Hospital, about 40 percent of the soldiers were returned to their original duty status.

Fractures of the tibia.—Fractures of the tibia in the middle or the upper third were usually managed by plaster immobilization, to maintain alinement. The intact fibula acted as a strut to secure the normal length.

Fractures of the lower third of the tibia offered more difficulties. The two-pin plaster technique of external skeletal fixation was occasionally employed to insure full length and to avoid a varus deformity of the foot. This complication usually occurred only in fractures in this location.

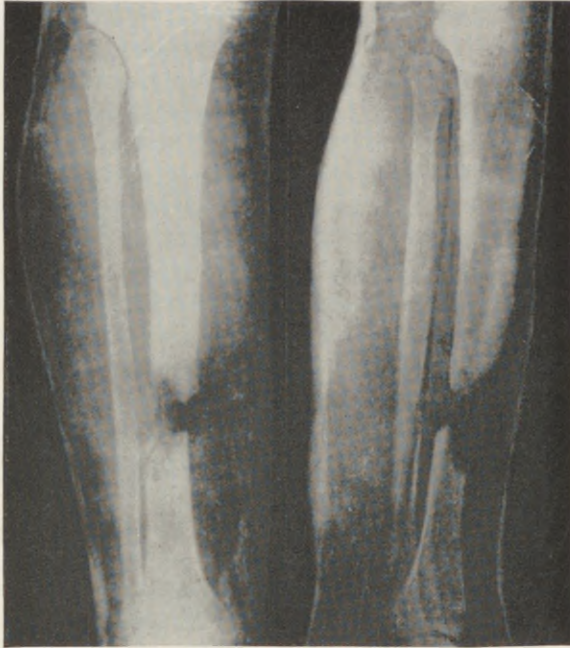
Internal fixation was employed in a few fractures of the upper third of the tibia with spread of the condyles or with forward displacement of a fragment to which the patellar tendon was attached. It was also used in a few fractures of the tibia at other levels. This technique was used in 1.5 percent of 158 fractures of the tibia treated at the 33d General Hospital, in 4.3 percent of 277 cases treated at the 45th General Hospital, and in 4.7 percent of 277 cases studied from disposition-board proceedings.

When bone loss had created a segmental defect in the tibia, the decision had to be made whether (1) to osteotomize and shorten the intact fibula in order to secure contact of the tibial fragments or (2) to leave the fibula intact in the expectation that the bony defect in the tibia could be repaired by grafting at reconstructive surgery (fig. 60). In a number of cases, the fibula was shortened. A number of other cases were observed in which it was thought that it would have been well to use this technique, since the shortening of the extremity would not have exceeded an inch. Another advantage of this technique was that deliberate shortening of the extremity sometimes permitted better approximation of the soft tissues. On the other hand, reports from Zone of Interior hospitals indicated that a high proportion of bone-grafting operations for segmental defects of the tibia were successful. In cases in which shortening would have exceeded an inch, it was therefore the general policy to permit the fibula to remain intact in expectation of later bone grafting.

Fractures of the Tibia and Fibula

Manipulative reduction with plaster immobilization was sufficient for the management of many fractures of both bones of the leg. If the fractures were severely comminuted, this often meant the acceptance of about a centimeter of shortening. The method presented one definite pitfall—late angulation within the cast, which could occur after edema had disappeared, atrophy of muscle and fatty tissue had ensued, and the cast had ceased to be a snug fit.

Fractures of both the tibia and fibula with segmental defects resulting from loss of bone at wounding or surgery provided a major problem. Unless shortening would be excessive, it was usually desirable to achieve contact of the bony fragments. When, however, the defect exceeded an inch or at the most an inch and a half, it was usually preferable to allow it to persist, in an effort to maintain tibial length. Damage to soft parts, which was usually



U. S. Army photo

FIGURE 60.—Anteroposterior and lateral roentgenograms showing fracture of right tibia with segmental loss of 1 to 1½ inches of bone. The fibula was intact. Union of the tibia was finally obtained after 2½ years of hospitalization spent in staged plastic procedures on the soft tissues, including split-thickness skin grafting followed by pedicle grafting, and two bone-grafting procedures.

severe, further complicated the issue. The difficulties of wound management, the persisting dead space created by the bony defect, the prejudicial effect of the dead space on wound healing, and the limitation of function to be expected in an extremity that had been so severely damaged, all had to be weighed in the decision whether to shorten the extremity, maintain length mechanically, or, in the occasional case, amputate the limb. When, as just noted, information reached the theater that bridging bone grafts were proving very successful in the Zone of Interior, the scales were usually weighted in favor of preservation of length in the borderline cases in which amputation did not appear to be indicated, and the technique most applicable to the particular case was selected.

Techniques of fracture management.—In addition to plaster alone, four other methods of fracture management were employed in the Mediterranean theater in compound fractures of the tibia and fibula (tables 11 and 12):

1. Skeletal traction in a cast was employed effectively in a number of hospitals. The usual plaster immobilization was supplemented by traction obtained by means of a wire or pin inserted in the os calcis and incorporated

into the cast (figs. 61 and 62). When traction was maintained for about 6 weeks, the risk of late angulation, which has just been mentioned, was greatly reduced. Stability frequently developed during this period, and apposition

TABLE 11.—*Fracture management in 622 compound fractures of tibia and tibia and fibula*¹

Technique	Fractures		Total cases
	Tibia cases	Tibia and fibula cases	
Cast.....	277	167	444
Cast traction.....	2	45	47
Two-pin fixation in cast.....	1	11	12
Internal fixation tibia.....	13	80	93
Plating.....	² (6)	(59)	(65)
Screws.....	(5)	(20)	(25)
Wire.....	(2)	(1)	(3)
Plating fibula.....		9	9
External fixation.....	2	11	13
Amputation.....		4	4
Total.....	295	327	622

¹ Data were secured from proceedings of disposition boards on file in the Office of the Surgeon, Mediterranean Theater of Operations. The technique was not stated in 32 other cases studied.

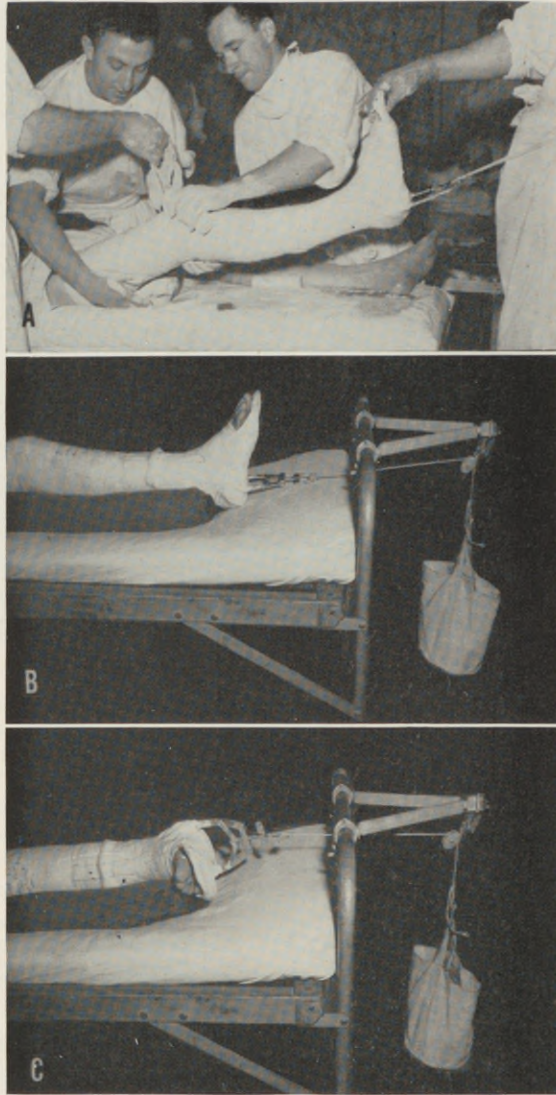
² Figures in parentheses are subtotals.

TABLE 12.—*Fracture management in relation to level of tibial injury in 621 compound fractures of tibia and tibia and fibula*¹

Technique	Level of tibial fracture			Total
	Proximal third	Mid third	Distal third	
Cast.....	143	146	154	443
Cast traction.....	11	9	27	47
Two-pin fixation in cast.....	2	6	4	12
Internal fixation tibia.....	11	48	34	93
Plating.....	² (4)	(36)	(25)	(65)
Screws.....	(7)	(11)	(7)	(25)
Wire.....		(1)	(2)	(3)
Plating fibula.....	2	2	5	9
External fixation.....	1	11	1	13
Amputation.....	1		3	4
Total.....	171	222	228	621

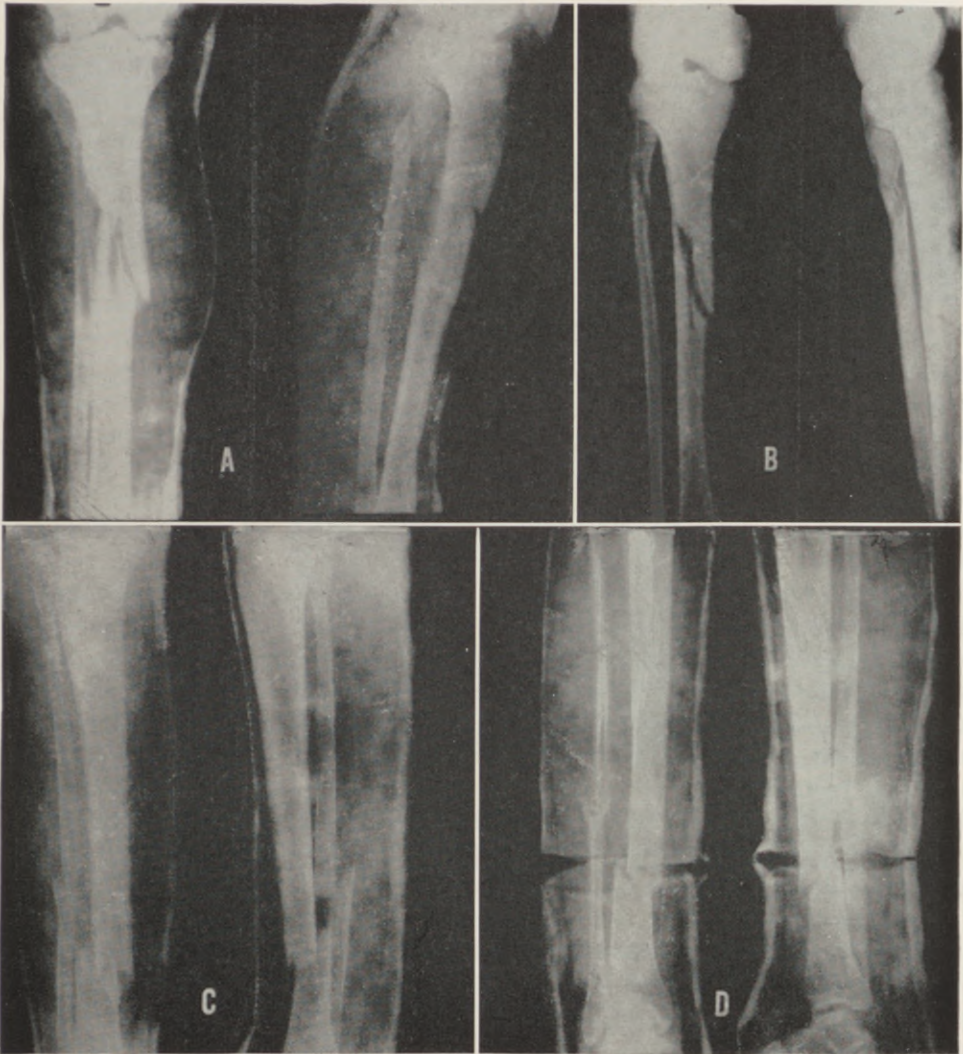
¹ Data were secured from proceedings of disposition boards on file in the Office of the Surgeon, Mediterranean Theater of Operations. The level of the tibial fracture was not stated in 33 other cases studied.

² Figures in parentheses are subtotals.



AFIP 54-3045

FIGURE 61.—Skeletal traction in cast for fractures of both bones of leg. A. Application of cast. Constant traction is exerted on musculature of leg through Kirschner wire by means of muslin bandage or rope tied to bow on wire and passed around hips of assistant, who leans backward. The fracture has been reduced by manipulation. The plaster cast is well padded from the fracture site upward. Ideally, reduction is obtained by manipulation and traction at the time the cast is applied and is maintained by traction. Note functional position of foot. B. Traction with patient recumbent. Cast has been wedged for alinement. C. Traction with patient on right side.



U. S. Army photos

FIGURE 62.—Roentgenologic results of skeletal traction in cast. A and B. Anteroposterior and lateral views of fractures of both bones of right leg at junction of upper and middle thirds before and after skeletal traction in cast. Note length and alignment obtained by this method, which also aids in obtaining apposition, though manipulative reduction is also important in all but grossly comminuted fractures. C and D. Same views of fractures of both bones of right leg at junction of middle and lower thirds.

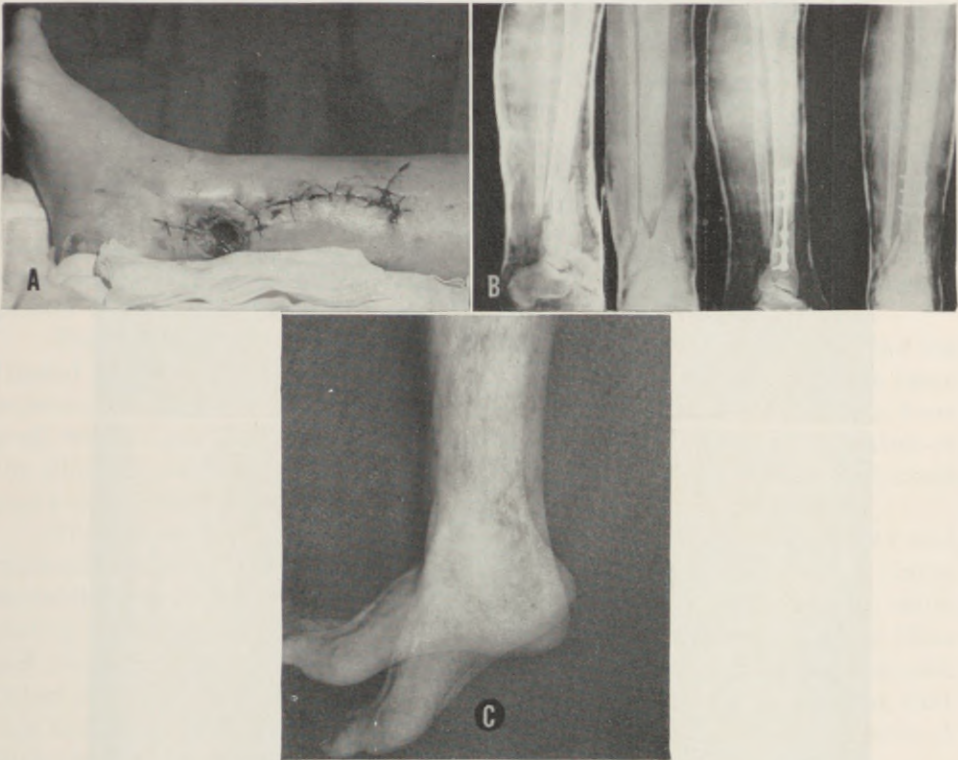
was well maintained. Traction supplement of the plaster technique should probably have been employed more frequently than it was. In a number of instances observed in the Zone of Interior in the spring of 1945, late angulation had occurred in both bones of the leg when only plaster immobilization was used. Roentgenograms made shortly before evacuation had showed the fractures to be well reduced, and the angulation had apparently occurred in the 3 to 4 weeks occupied by transfer over water and to the Zone of Interior hospital after landing. In some instances, the angulation had become fixed, and manual correction was not possible.

2. Two-pin stabilization in plaster involved merely the addition of pins to the plaster technique. This method was enthusiastically employed at one hospital in the theater but had a very limited use in other hospitals. It was chiefly employed in fractures with segmental defects in which it was desired that almost full length be maintained. The majority of surgeons preferred not to employ this technique in the absence of very specific indications. They did not regard it as effective in maintaining reduction, and they realized the hazards of persistent distraction, breakage of pins, and infection, which were associated with it.

3. External skeletal fixation, of which the two-pin plaster technique is really a modification, was steadily gaining in favor in the closing days of the war as an acceptable method of managing severely comminuted fractures of the tibia and fibula, including those with bone loss (p. 207). In several hospitals, the half pins were inserted in the major fragments as the first step of fracture management at the reparative operation. Then, while the fracture site was exposed, reduction was accomplished under direct vision, and the stabilizing bars were locked to maintain it. Finally, a long leg plaster cast, in which the apparatus was incorporated, was applied. The cast held the foot in correct position and increased the stability of the reduction.

4. It had been hoped, when the program of reparative surgery was introduced in the Mediterranean theater in the spring of 1944, that the problems of management of fractures of both bones of the leg would be solved in large measure by the use of internal fixation. This hope was only partly realized (figs. 63, 64, 65, 32, and 36). In the majority of injuries, comminution was too severe to make the technique feasible, while periosteal stripping in a region of poorly vascularized soft tissue continued to be hazardous, in spite of penicillin protection and refinements of surgical technique. Fractures in which coverage of denuded bone was difficult were usually unsuitable for management by this technique. In spite of these objections, the judicious application of plates, screws, or wire sutures in selected cases, particularly those in which it was possible to cover exposed bone and metal by healthy soft parts, resulted in improved and often stabilized reductions.

Wires sutures permitted major fragments to be held in approximation and insured some degree of apposition. Fixation by this method and by screws was considered less hazardous than plating, but plating was not infrequently utilized, in spite of the added risk, to obtain the benefit of better stabilization.

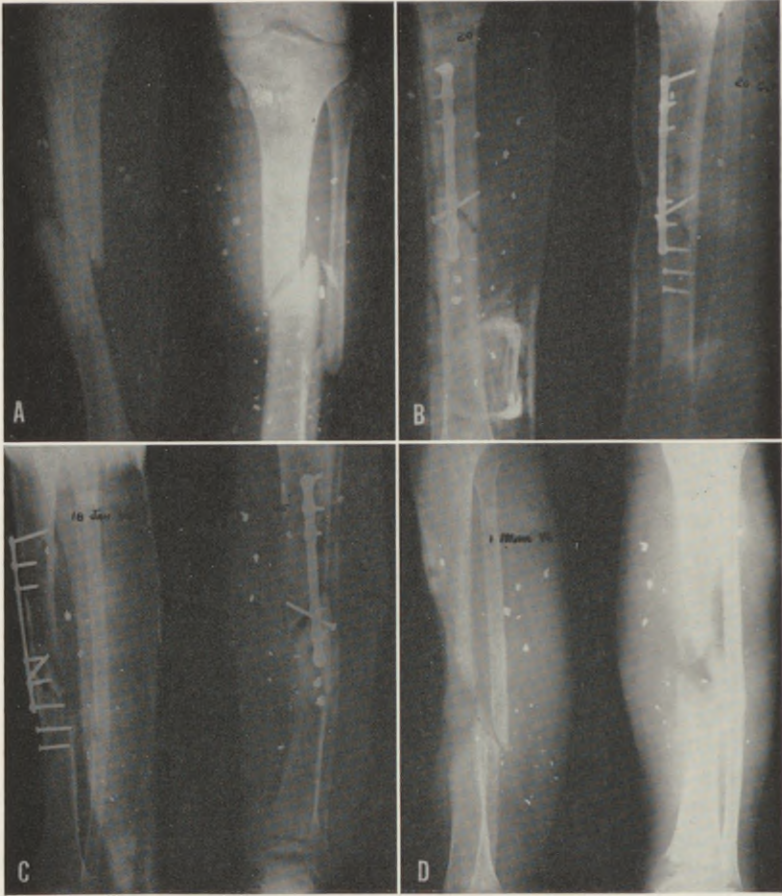


AFIP C-44-290

FIGURE 63.—Management of compound comminuted fractures of lower third of right tibia and fibula by delayed internal fixation of tibia. Ligation of the posterior tibial artery was necessary at initial surgery. A. Appearance of wound after reparative surgery 9 days after wounding. The wound has been only partly closed, to provide for drainage after internal fixation of the tibia by plating, on the indication of bone loss at the site of the fracture in the fibula. B. Preoperative and postoperative roentgenograms showing loss of bone at fracture site before reparative surgery and position of fractures after plating of tibia. C. Range of ankle motion 13 months after wounding. Anteroposterior and rotated anteroposterior roentgenograms showed fractures solidly united and in good alinement 12 months after wounding. Removal of metal and several small sequestra was necessary for satisfactory wound healing.

The elective choice of internal fixation by plating was justified in this case because of (1) the difficulties ordinarily experienced in fractures of the lower third of the tibia and (2) the availability of soft parts to cover the denuded bone. The end result was excellent. (The case was managed at the 21st General Hospital by Maj. Newton C. Mead, MC, and Capt. Francis R. Crouch, MC.)

Toward the end of the war, it began to be recognized that it was a better plan to stage the procedures: Wound healing was accomplished as promptly as possible, and then, if adequate reduction had not been attained, plating was carried out through a surgical incision. A certain number of fractures, however, continued to present such combined problems of fracture reduction and wound



Lovell GH 27243

FIGURE 64.—Management of compound comminuted fractures of middle third of left tibia and fibula by delayed internal fixation. A. Roentgenograms made at evacuation hospital shortly after wounding. B. Roentgenograms made at general hospital after stabilization of fracture of tibia by a long plate and an additional transfixion screw. These roentgenograms reveal a second fracture, located more distally, not seen on the original films (view A). A few days later, this fracture was fixed in reduction by two screws. The wound, which had been closed at both the original and the second operation, did not heal. C. Roentgenograms made in Zone of Interior hospital, $3\frac{1}{2}$ months after wounding. Note nonunion of fractures and massive sequestration. At this time, the wound was gaping down to the plate. D. Roentgenograms made 6 weeks later, after removal of sequestra and metal. Wound healing was obtained after this operation. Note loss of bone by sequestration.

This case clearly illustrates the hazards of plating of the tibia. The advantages offered by this technique when it is used before wound healing has occurred do not justify the risks entailed. In this case, wound healing did not occur and there was massive sequestration of the bone which had been denuded at operation.

management that early plating through the compounding wound seemed justified, in spite of the risk involved.

Internal fixation of the fibula (figs. 66 and 67) was employed in several hospitals when a transverse or oblique fracture of that bone was associated with a comminuted fracture of the tibia. Plating, in effect, converted the combined fractures into a fracture of only the tibia; the stabilized fibula acted as a strut, maintaining tibial length and holding the tibial fragments in adequate reduction. Both metal and bone were easily covered by soft tissue, and wound healing was seldom a problem. Plating was usually accomplished through a separate surgical incision. After operation, the limb was put up in a long leg plaster cast.

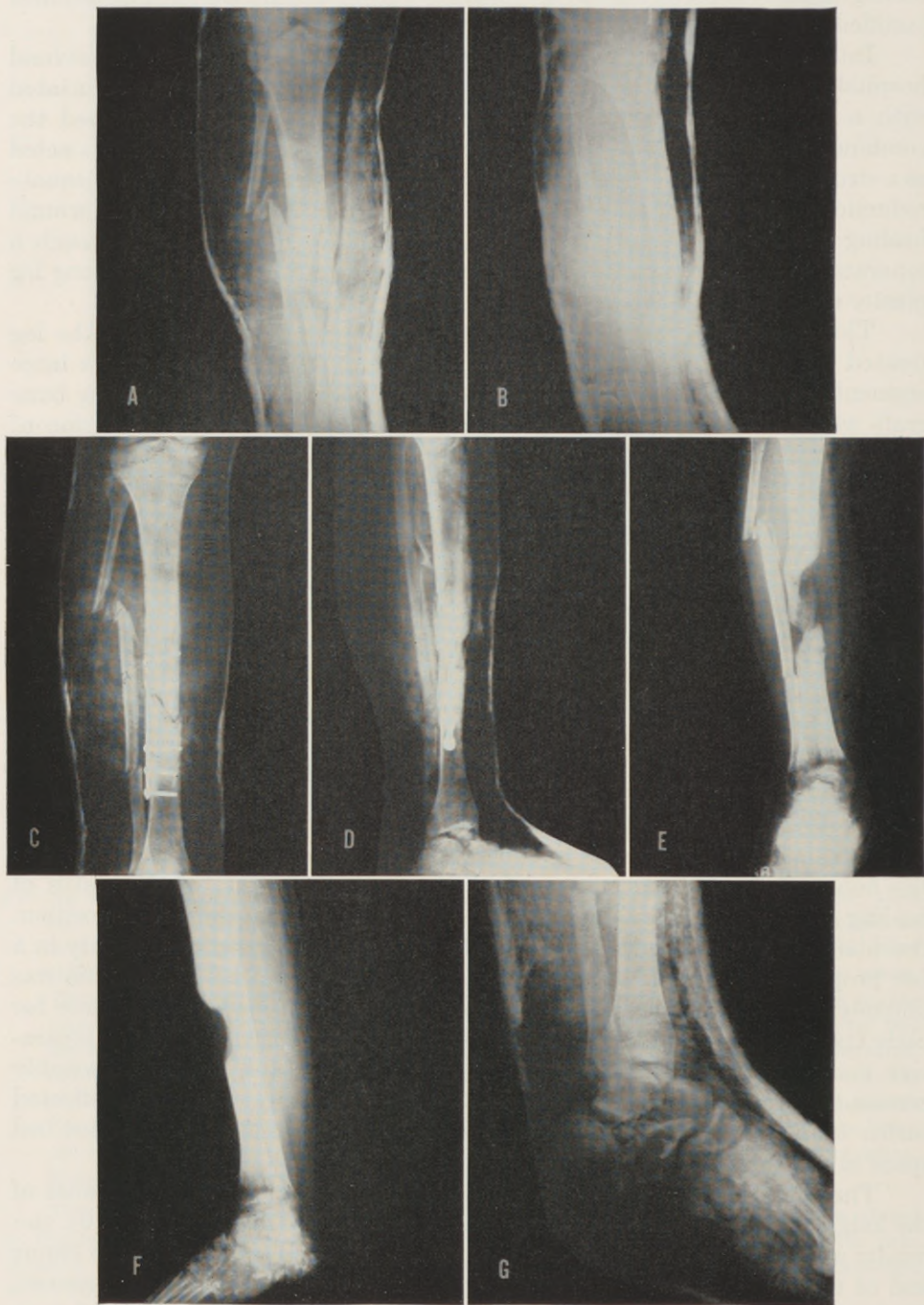This technique was used in 9 of 179 fractures of both bones of the leg treated at the 45th General Hospital. In 4 cases, the indication was a large segmental defect of the tibia, for which it was expected that a bridging bone graft would later be employed. In the other 5 cases, adequate reduction of the tibia was not possible by other methods. The fixation in 7 of the 9 cases was accomplished through the compounding wound.

The surgeons at this particular hospital believed that the simplicity and minimal hazard of this technique, combined with the feasibility of early transportability to the Zone of Interior with no fear of loss of reduction, made plating of the fibula the method of choice for combined fractures of the tibia and fibula whenever the contour of the fibular fracture permitted its use. Other surgeons, with somewhat less enthusiasm, accepted the concept that this technique had a limited application in the management of fractures of both bones of the leg.

EVALUATION OF RESULTS

Evaluation of the results of reparative surgery of compound fractures of the bones of the leg was necessarily limited to observation of the status of healing of the wounds and of reduction of fractures at the time of disposition. A soldier with a compound fracture of the fibula could be returned to duty in a fair proportion of cases. A soldier with a compound fracture of the tibia was unlikely to be of further military usefulness and was usually a candidate for early transfer to the Zone of Interior. Transfer was effected as soon as reparative management of the wound had been completed and it was reasonably certain that reduction would not be lost in transit. It was sometimes effected earlier than was desirable because heavy influxes of casualties demanded bed space in the theater.

The consensus throughout the theater was that on the whole, because of the handicaps attendant upon the management of these fractures (p. 160), the results were inferior to those accomplished in compound fractures of the femur and of the bones of the upper extremity. It was generally agreed, however, that they were far superior to the results which had been accomplished before



Schick GH 8793

FIGURE 65. (See opposite page for legends.)

the introduction of the reparative-surgery program. Necrotizing wound infection had become infrequent. Fracture reduction was improved. Complete wound healing was obtained in a large number of cases. In other cases, in which healing was incomplete, the size of the defects left to heal by granulation had been greatly reduced.

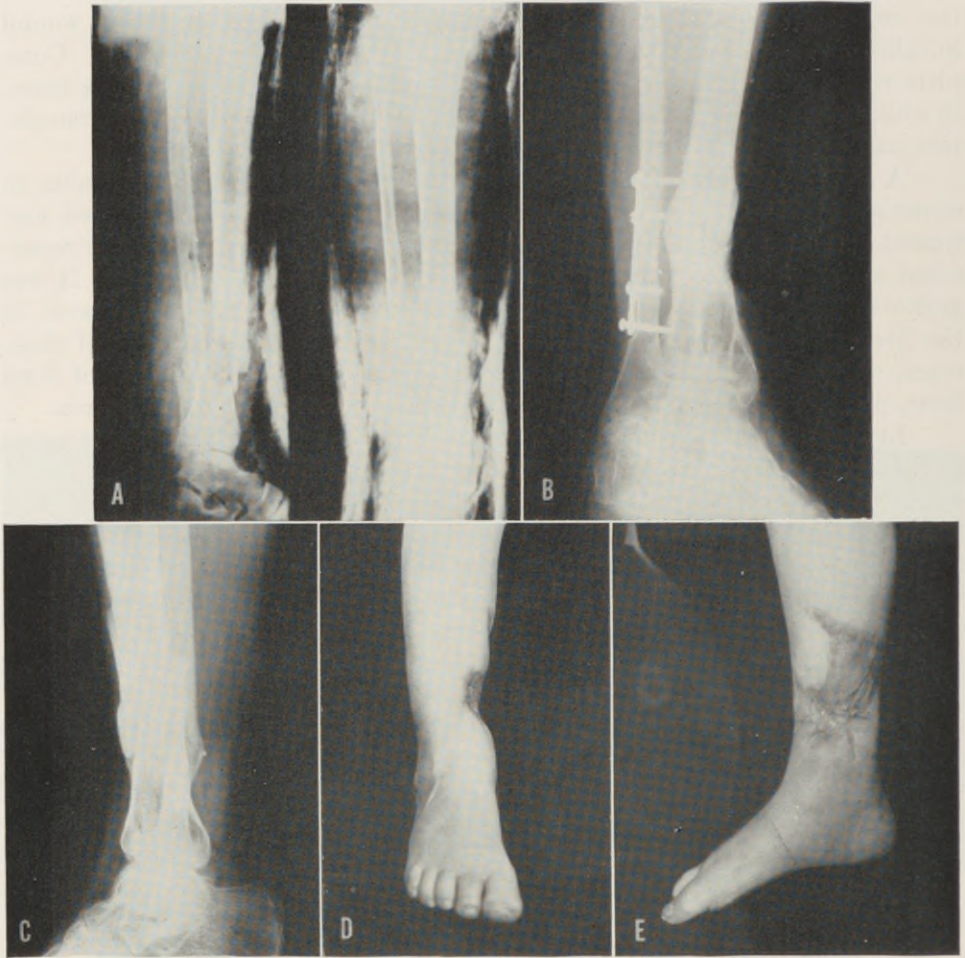A high incidence of sequestration was considered almost inevitable in comminuted fractures of the tibia. When it occurred, sinuses formed and wound healing was not accomplished. Removal of the sequestra was recognized as a function of reconstructive surgery in the Zone of Interior. It was performed only on special indications, and in correspondingly few cases, in the Mediterranean theater. It was generally believed that, in most of these cases, satisfactory healing of the wounds would occur after removal of dead bone, provided that sufficient healthy soft tissue was available in the area.

In the 279 fractures of the tibia or the tibia and fibula which were treated at the 21st General Hospital, the tibia was fractured in 191 cases and the tibia and fibula in 88. The proximal third of the bone was involved in 81 cases and the distal third in 55; the knee joint was involved in 53 of the former group and the ankle joint in 12 of the latter. One hundred and ninety of the wounds were clinically clean on admission. In the remaining 69 cases in which this information was available, the wound contained necrotic tissue, and there was a heavy exudate.

Details of wound management were available in 270 cases in this series. Complete suture without drainage was carried out in 81 cases, partial suture or suture with drainage in 143 cases, and suture with skin graft in 7 cases. Thirty wounds were left open. Amputation was necessary in 9 cases, in 1 instance

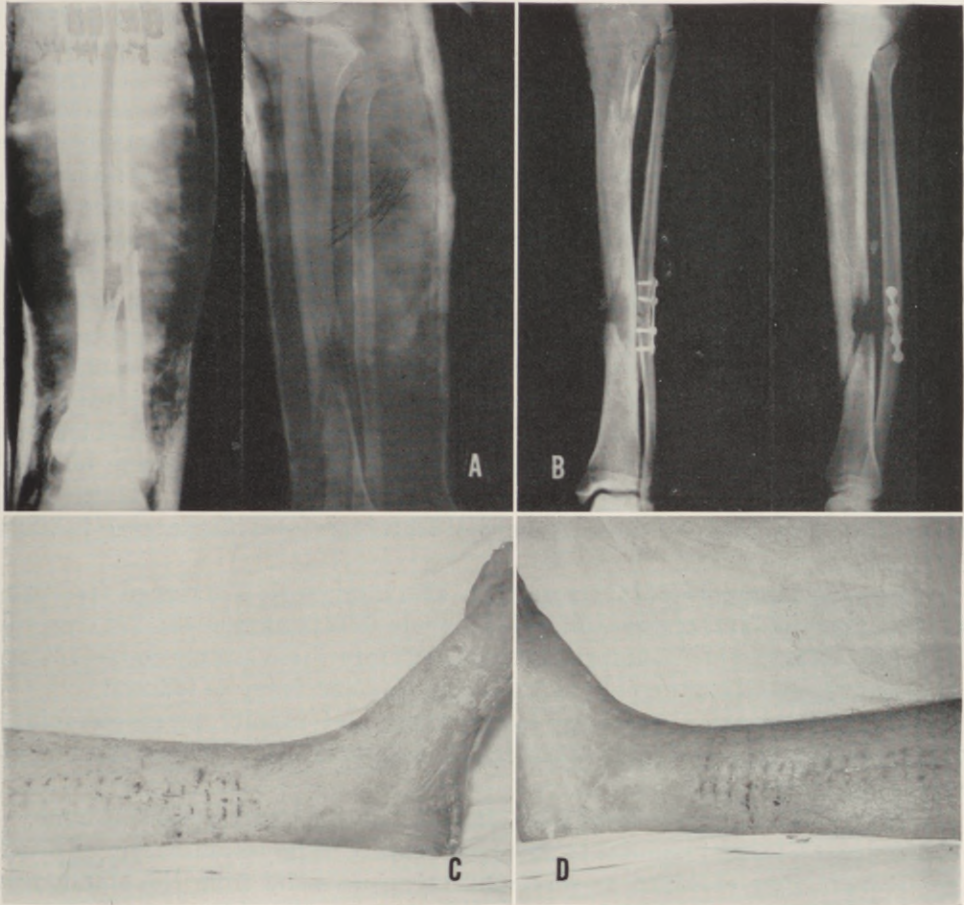
FIGURE 65.—Management of compound comminuted fractures of right tibia and fibula by internal fixation of tibia; bilateral compound comminuted fractures of right os calcis and talus. A. Anteroposterior roentgenogram made in general hospital several days after wounding, showing fractures of tibia and fibula. B. Lateral roentgenogram, same. C. Anteroposterior roentgenogram showing fractures of bones of leg after internal fixation of tibia by plating through the compounding wound, which was closed. D. Lateral roentgenogram, same. E. Anteroposterior roentgenogram after removal of metal and sequestra in Zone of Interior hospital. Wound healing did not occur until after this procedure. The fracture is united, but heavy sequestration has reduced the strength of the bone. F. Lateral roentgenogram made at same time as view E. G. Roentgenogram showing severe distortion of bones of heel shortly after wounding. This roentgenogram is to be compared with view F, in which the destruction in these bones 6 months after wounding is well demonstrated.

As this case is viewed in retrospect, the severe trauma to the right foot and leg might well have been considered a justification for amputation in all echelons. Perhaps the fact that the trauma was bilateral was regarded by the surgeon as a contraindication. Since traction was not possible, the choice of internal fixation probably seemed justified. On the other hand, plating of the tibia is always hazardous because of the necessary periosteal stripping and the resulting denudation of bone, for coverage of which highly vascularized soft parts are not available in this area. The ever-present possibility of massive sequestration such as occurred in this case would seem to indicate that nonplating methods are preferable in such injuries.



AFIP (Mayo GH) 876-4, 6, 5, 1, 3

FIGURE 66.—Management of severely comminuted fracture of right tibia, with nearly transverse fracture of fibula, by plating of fibula. A. Anteroposterior and lateral roentgenograms of bones of leg made at general hospital. At reparative surgery 7 days after wounding, the fibula was stabilized by plating and thus served as a strut for the tibia, the fragments of which were maintained in apposition and alinement. At the same operation, a large wound over the medial aspect of the leg was partly closed, and the remaining defect was loosely packed. Two and a half weeks later, with the plated fibula as an aid in maintaining reduction of the tibia, the unhealed portion of the wound was successfully covered with a split-thickness graft. B and C. Anteroposterior and lateral views made in general hospital in Zone of Interior several months later. Fracture is firmly united. D. Frontal view of leg showing healed wounds with extensive loss of soft tissues. E. Medial view. (This patient was managed by Maj. Herbert W. Harris, MC, and Capt. Edwin L. Mollin, MC, at the 17th General Hospital.)



AFIP CA-44-522

FIGURE 67.—Management of transverse fracture of left fibula and comminuted fracture of tibia, with loss of bone, by plating of fibular fracture. A. Anteroposterior and lateral roentgenograms before reparative surgery. B. Same as view A, with patient still on operating table, after plating of fibula. Without benefit of plaster immobilization, the tibia is now held at almost full length and in almost perfect alignment. C. Compound wound of tibia 16 days after suture at reparative surgery. Note complete healing. D. Healed operative incision used for plating of fibula, soundly healed after same lapse of time. (This patient was managed by Maj. Joe M. Parker, MC, and Capt. Francis R. Crouch, MC, at the 21st General Hospital.)

because of a knee-joint infection and clostridial myositis complicating a severe fracture of the upper end of the tibia. In the remaining cases, the amputation was performed for circulatory causes.

Methods of fracture management could be ascertained in 264 cases, including 9 cases in which the fracture was incomplete and immobilization was not required. The remaining cases were treated by plaster-cast immobilization in 206, in 22 of which both bones were fractured; by cast traction in 23 cases, in all of which both bones were fractured; and by internal fixation in 26 (14 by screws, 9 by wire, and 3 by both techniques).

The status of the wound when the patients were evacuated was unknown in 100 cases in this series, because of the tactical necessity for speedy evacuation. In 40 of the remaining 170 cases (23.5 percent), the wounds were completely healed. In another 49 cases (28.8 percent), the wounds were healing, and there was no opening to the bone. In 59 cases (34.7 percent), in all of which the closed plaster technique had been used, the fracture site was exposed, but the wound was clean and healing appeared to be in progress. In the other 22 cases, the wound was not healed, and both bone and soft tissue were frankly infected.

Results accomplished overseas were also studied in a series of fractures of the tibia (132) and of the tibia and the fibula (80) treated at the 33d General Hospital. These 212 fractures were classified into three groups (table 13) on the basis of severity of damage to the soft tissue and bone, as follows:

Group A.—Extensive damage to soft tissue, and, usually, severe comminution of bone. In many cases there had been loss of soft tissue or of bone at wounding.

Group B.—Moderate soft-tissue damage, severe comminution of bone.

Group C.—Slight damage to soft tissues, little or no comminution of bone.

Results were classified as successful or unsuccessful from the standpoint of wound management and fracture management. Wound management was

TABLE 13.—*Severity of injury in relation to location of fracture in 132 compound fractures of the tibia and 80 of the tibia and fibula*¹

Location	Severity of injury			Total
	Group A	Group B	Group C	
Proximal third.....	26	20	16	62
Mid third.....	36	20	5	61
Distal third.....	43	22	15	80
Not stated.....	3	3	3	9
Total.....	108	65	39	212

¹ These cases were managed at the 33d General Hospital.

regarded as successful when the wound was either completely healed or completely healed except for small areas of healthy granulation tissue, with the fracture site well sealed off. Management was regarded as unsuccessful when there was an open, draining wound or a sinus leading to the fracture site. These criteria were exacting, since in highly comminuted battle fractures sinuses usually led only to sequestra's forming from fragments of bone partially denuded at wounding. Leaving these fragments in situ also introduced this possibility. Wound healing had not been achieved in these cases, however, and they were considered instances of unsuccessful wound management.

Fracture management was considered successful when the fragments were held in adequate apposition, length, and alinement for the special bone injury. It was considered unsuccessful when reduction was inadequate.

By these criteria (tables 14, 15, and 16), wound healing was considered successful in 167 of these 212 compound fractures of the tibia and fibula. Fracture management was successful in 207 cases. When the criteria of success are combined, 166 cases were successful from the standpoint of wound healing and fracture management, and only 4 were unsuccessful from both aspects.

TABLE 14.—*Results in relation to severity of injury and technique of wound management in 132 compound fractures of the tibia and 80 of the tibia and fibula*¹

Technique	Successful				Unsuccessful			
	Group A	Group B	Group C	Total	Group A	Group B	Group C	Total
Revision:								
Complete.....	72	47	21	140	13	4	-----	17
Incomplete.....	3	8	16	27	20	6	2	28
Total.....	75	55	37	167	33	10	2	45
Suture:								
Complete.....	45	41	30	116	3	5	-----	8
Partial.....	16	8	3	27	20	2	2	24
No suture ²	14	6	4	24	10	3	-----	13
Total.....	75	55	37	167	33	10	2	45

¹ These cases were managed at the 33d General Hospital.

² Closed plaster technique.

Early in the reparative-surgical program, the depths of the wound, including the fracture site, were not routinely exposed, and there is no doubt that totally detached fragments of bone and tags of dead tissue were left in situ. As experience increased, it was increasingly appreciated that the entire wound must be freed of dead tissue. The improved wound healing in the cases in which

additional debridement was carried out (89 percent, against 49 percent in the cases not completely explored) furnished substantiating evidence of this fundamental principle of reparative surgery.

TABLE 15.—*Results in relation to severity of injury and technique of fracture management in 132 compound fractures of the tibia and 80 of the tibia and fibula*¹

Technique	Successful				Unsuccessful			
	Group A	Group B	Group C	Total	Group A	Group B	Group C	Total
Plaster cast.....	92	61	37	190	3	1		4
Internal fixation.....	10	2	2	14	1			1
External fixation.....	2	1		3				
Total.....	104	64	39	207	4	1		5

¹ These cases were managed at the 33d General Hospital.

TABLE 16.—*Combined results of wound and fracture management in relation to severity of injury in 132 compound fractures of the tibia and 80 of the tibia and fibula*¹

Results	Severity of Injury			Total
	Group A	Group B	Group C	
Wound and fracture management successful.....	75	54	37	166
Only wound management successful.....		1		1
Only fracture management successful.....	29	10	2	41
Wound and fracture management unsuccessful.....	4			4
Total.....	108	65	39	212

¹ These cases were managed at the 33d General Hospital.

Part IV. Compound Fractures of the Foot

All hospitals in the Mediterranean Theater of Operations had frequent admissions for compound fractures of the bones of the foot. At first glance, this fact might seem to violate the axiom that the proportion of injuries in any given area of the body bears a general relation to the proportion of body surface which the area represents. Although the foot constitutes a relatively small portion of the lower limb and an absolutely small part of the total body surface, admissions for compound fractures of the bones of the foot made up from 18

to 20 percent of all compound fractures managed in general hospitals. At the 45th General Hospital, for instance, during 1944, the 565 compound fractures of the bones of the foot represented 19.3 percent of all compound fractures treated during that year. The os calcis was injured in 101 cases, the tarsals in 146, the metatarsals in 224, and the bones of the toes in 94. The explanation of the large numbers of fractures of the foot was chiefly the extensive and extremely effective use of land mines by German troops.

On the surface, it would not seem that compound fractures of bones of the foot would be of great significance. They are not inherently lethal, it is true, but they account for an enormous amount of disability, even when they are of minor severity, and, when they are extensive, they may permanently destroy a soldier's military usefulness. At the best, a man with a compound fracture of a bone of the foot, unless only a smaller toe was involved, could not be expected to return to duty within the theater holding period of 90 to 120 days. As a result, most patients with such injuries had to be evacuated to the Zone of Interior. It is perfectly fair to say that if an enemy could succeed in producing compound fractures of bones of the foot in most of their opponents, a very large expenditure of medical service would be required for their management and only an insignificant number of the soldiers could return to fight again.

Of the compound fractures which affected only a single toe, a fair proportion were the result of self-inflicted gunshot wounds. The battle-incurred injuries varied all the way from relatively simple fractures to completely disorganized fractures of the tarsus, with massive soft-tissue compounding wounds. Injuries of this type were most often caused by land mines.

WOUND MANAGEMENT

Initial surgery in wounds of the foot was conducted according to the general principles of debridement as far as the regional anatomy permitted. Usually, all that could be done was to remove large foreign bodies and obviously dead tissue.

The anatomy of the foot, unfortunately, also militated against all but the most limited application of the program of reparative surgery, for a number of reasons: Some degree of tension is normal in the skin of the foot, particularly on the plantar surface. For this reason, the swelling which ordinarily occurs in the tissues after wounding and initial surgery is of more significance in the foot than in most other areas. Finally, the soft tissues of the foot possess generally inferior qualities of healing, even when there has been no great loss of tissue, and in many of these injuries the loss had been considerable.

As a result of these considerations, delayed primary closure of wounds of the foot, even when tissue loss had been small, was usually limited to occasional wounds of the dorsal surface. It was seldom possible to close wounds on the plantar surface. The best that could be done, in most cases, was to place a few sutures in the angles of the wound, cover exposed cortical bones and tendons, and accept healing by granulation.

The fact that most wounds could not be closed did not, of course, contraindicate the routine performance of other steps of the reparative operation. Grossly displaced and rotated fragments of bone could often be replaced manually in their normal position at this time.

The wounds were dressed with fine-mesh gauze, preferably impregnated with vaseline or some water-soluble ointment, to promote drainage from the depths of the wound. Dry gauze, which was preferred in other locations, was less satisfactory when it was used in wounds of the foot.

FRACTURE MANAGEMENT

Manipulation under full vision, as just noted, was a simple and effective method of management of many fractures of the foot. It was usually effective in fractures of bones of the small toes, with immobilization maintained by dressings. It was also sometimes useful in bones of the great toe, but fractures in this area required special management because this toe is essential for locomotion, and residual disability is highly undesirable.

Banjo traction was the preferred method of management when the proximal phalanx of the great toe was comminuted and fragments were overriding or when there was significant displacement of a major fragment, particularly a fragment which included a portion of an articular surface. A small Kirschner wire was introduced into the distal phalanx of the toe from the dorsal to the plantar surface, passing through the toenail. A boot cast extending to the metatarsal heads was then applied to hold the foot at 90° in neutral version. A heavy loop of wire was incorporated in the cast, and traction was accomplished by rubber bands extending from it to the Kirschner wire. This simple method permitted access to compounding wounds for dressings and at the same time minimized the deformity caused by the fracture.

Fractures of the metatarsal bones had to be prevented from uniting in dorsal angulation. If this were permitted, the metatarsal heads would be excessively prominent in the ball of the foot, and callus formation and pain on walking would be inevitable. Healing of all metatarsals in full length and in as nearly perfect alinement as possible was necessary for the heads of these bones to continue to serve as points of weight bearing. These results could be accomplished in most fractures of the metatarsals by simple manipulative molding and immobilization in a boot cast. If any significant degree of shortening was present after manipulation or if it was impossible to maintain proper alinement, banjo traction was instituted through one or more of the toes by the technique just described.

Fractures of the tarsus could be managed only by manipulative molding and immobilization in a boot cast. In this type of injury, the healing of the compounding wound was of greater concern than the management of the fracture, and the reduction of the fracture had to be conducted with this consideration in mind.

Compound fractures of the tarsus, especially when the os calcis was involved, were a source of prolonged disability. Functional results were seldom optimal and were often actually poor. Although conservatism was ordinarily practiced, many orthopedic surgeons, when they reviewed their experience, wondered whether this had been the wisest course. They could recall many cases of extensive bony disorganization and persistent infection, with continuing destruction of bone or loss of weight-bearing skin on the plantar surface of the heel, in which conservative measures had been employed but in which amputation might have been the wiser course. In some of these cases, amputation was eventually performed in the Zone of Interior but only after the soldiers had been hospitalized for months and even years.

The same course of events was sometimes observed in fractures of the astragalus. Early amputation in this type of case would have lessened the period of disability and saved considerable hospitalization and medical effort which, in the end, achieved no results at all. It should be emphasized, of course, that amputation was never carried out in a case in which the vascular supply to the distal portion of the foot appeared adequate and in which there was a reasonable chance of preserving a functioning, weight-bearing extremity.

POSTOPERATIVE MANAGEMENT

Postoperative management in compound fractures of the bones of the foot treated in plaster after reparative surgery required bed rest, with the injured extremity elevated, for at least 7 to 10 days, to reduce edema of the foot and toes, prevent infection, and promote wound healing. When this plan was followed, the edema originally present subsided promptly, often to such a degree that a new plaster boot had to be applied.

Since the majority of these casualties were of no immediate military usefulness, they were usually evacuated to the Zone of Interior as soon as possible after reparative surgery. This was, as a rule, within 2 to 3 weeks after wounding. A snug boot cast was adequate for transportation splinting.

CHAPTER VI

Delayed Internal Fixation of Compound Battle Fractures—A Followup Study in the Zone of Interior

During the first 16 months' experience in the Mediterranean Theater of Operations, manipulative reduction followed by immobilization in a plaster cast or continuous skeletal traction proved satisfactory, or reasonably satisfactory, methods of management for a major portion of the combat-incurred fractures. Inadequate reduction, however, was by no means infrequent. It was particularly common in fractures involving the condylar and articulating portions of the large joints, fractures of both bones of the forearm and both bones of the leg, fractures in which loss of bone had caused segmental defects without contact of fragments, and fractures accompanied by massive loss of soft tissue. Even though the position obtained by repeated efforts at manipulative reduction or continuous skeletal traction had often not been satisfactory in these groups of injuries, inadequate reduction was accepted because of the fear that operative intervention would incite systemic infection or at least a severe wound infection with prolonged osteomyelitis.

For these reasons, delayed internal fixation of compound battle fractures was seldom performed during this period. On occasion, when adequate reduction had not been achieved by nonoperative methods, open reduction and internal fixation were performed, even though the wound was unhealed. The results were encouraging in a small series at one hospital, but in another series, at a different hospital, they were poor. A study of these cases and of sporadic cases treated in this way in other hospitals did not produce evidence that would warrant recommendation or approval of the procedure.

Even though it was realized that there would be a place for delayed internal fixation in the management of problem fractures once wound management was better understood, its use in the Mediterranean theater was forbidden by directive in November 1943. Section IV of Circular Letter No. 48, issued 18 November 1943 from the Office of the Surgeon, Headquarters, North African Theater of Operations, read as follows:

IV. DELAYED OPEN REDUCTION AND INTERNAL FIXATION OF COMPOUND FRACTURES WITH OR WITHOUT SECONDARY SUTURE OF WOUND.

1. This procedure is still under trial with reference to indications, hazards, and incidence of serious complications. Its use is restricted to special groups authorized to assume the responsibility as a special study.

At this time, there were no groups in the theater authorized to make such studies. For one thing, further investigation of the problem and further experience in wound management as a whole were necessary before internal fixation could be considered an advisable technique. For another, it was thought desirable to wait to test the technique until adequate supplies of penicillin were available, as a safeguard against invasive infection.

The use of delayed internal fixation in the Mediterranean Theater of Operations as a part of the reparative surgery of compound fractures began in March and April 1944, during the hectic days of Anzio and Cassino. Its use was first permitted in the 300th, 23d, and 21st General Hospitals, in which penicillin therapy had been made available as an adjuvant to an aggressive surgical program. The patients treated by internal fixation fell into two groups, as follows: (1) Those with unreduced fractures and unhealed wounds, who had previously been treated unsuccessfully by other methods; and (2) those recently admitted from evacuation hospitals after initial wound surgery, with no previous attempts at reduction of the fractures. The progress of each of these patients was followed carefully and, when necessary, the theater holding period was abrogated to permit prolonged observation, in an effort to assure that later recommendations concerning the use of internal fixation would be soundly based.

The results of the initial test of delayed internal fixation as they were observed in the spring of 1944 were extremely satisfactory. Moreover, when the first 14 cases so treated were studied later in the Zone of Interior, it was found that in 10 instances the fractures had united and the wounds had healed without removal of the metal. The final results were equally satisfactory in the other four cases, although it had been necessary, in order to expedite healing of the wounds, to remove the metal and sequestra. The results were particularly impressive in seven in which established wound infection had been present when stabilization of the fracture was undertaken.

The immediate results as obtained in the 300th, 23d, and 21st General Hospitals by the use of delayed internal fixation warranted its recommendation, on specific indications, as part of the program of reparative surgery of compound fractures. It was pointed out, however, that the use of this technique was not, in itself, an objective of the program. The measures designed to obviate infection and achieve wound healing included (1) the excision of dead tissue as part of revision of wounds in general hospitals; (2) the closure of compounding wounds, especially to cover denuded bone; and (3) adequate drainage of residual dead space or of unexcisable bits of devitalized tissue. All these measures were of greater importance in the program than internal fixation of fractures. Internal fixation would have been doomed to failure if the other essential surgery had been ignored.

Internal fixation was neither advisable nor feasible in the majority of compound battle fractures because of severe comminution. The fractures which would permit its use were in the minority. Internal fixation was therefore reserved for specific indications, as will be pointed out shortly (p. 190).

TECHNICAL CONSIDERATIONS

Internal fixation was frequently used at the first operation of reparative surgery, but it was also employed later, after other methods had failed. It was often used at the first reparative operation (1) in fractures about the joints, to secure anatomic replacement of the articular surfaces; (2) in fractures of the long bones located deep in muscle tissue, particularly fractures of the femoral shaft or upper radius; (3) in fractures which experience had shown were difficult to hold in reduction by other means, such as fractures of the olecranon process associated with massive soft-tissue loss; and (4) in fractures in which there had been segmental loss of bone and in which contact of the fragments could not otherwise be secured.

Internal fixation was accomplished in three ways, as follows: (1) By standard plating, (2) by multiple screws, and (3) by wire sutures. Slotted plates and intramedullary pins were postwar developments. The only type of metal available in overseas hospitals was 18-8 chrome-nickel stainless steel. Fixation by multiple screws (2 or more) was often particularly useful in oblique fractures. This technique required little or no additional periosteal stripping and was therefore associated with minimal trauma. When the fracture could not be stabilized rigidly because of comminution, one or more wire sutures were used to hold major fragments in apposition. They could usually be placed without additional stripping of the periosteum.

Intimate contact of the bony fragments was essential for sound union and was regarded as of such importance that in occasional cases, in order to secure it, the extremity was deliberately shortened, to overcome segmental loss and permit approximation of the fragments. The same plan was sometimes adopted when there were deficits of nerve trunks or muscles without segmental loss of bone. Removal of bony fragments permitted approximation of nerve or muscle bundles in these injuries and was undertaken with the idea of accomplishing maximum functional restoration of the whole extremity rather than merely achieving a united fracture.

Although the operation was sometimes performed through the compound wound, this technique had two disadvantages: (1) The metal was placed on bone which was usually devoid of periosteum. (2) It was also placed at the bottom of dead space created by the excision of devitalized muscle. It was therefore usually better, especially when a plate was applied, to utilize a separate surgical incision, which permitted coverage of the bone and metal by periosteum and soft parts.

The routine procedure for the management of these casualties in a fixed hospital must be clearly understood. Every patient was prepared for reparative surgery, usually 5 to 10 days after wounding. He was anesthetized in the operating room, where the plaster cast and dressing applied after initial surgery were removed. The extremity was cleansed, prepared, and draped. The operating room was set up for any surgery which might be indicated on a compound fracture.

The wound was then thoroughly visualized by gentle retraction. All residual dead tissue was excised, and the depths of the wound were cleansed of old blood clot. The fracture site was exposed. In the great majority of cases, reduction was attempted by traction or manipulation, but internal fixation could be employed at this time, as part of the first procedure of reparative surgery, if its advantages were evident, as, for instance, in condylar fractures of joints, oblique fractures of long bones which were easily reducible, or segmental defects due to bone loss. Wound closure, usually with drainage, completed this stage of reparative surgery.

If later roentgenograms showed that adequate reduction had not been achieved by traction or manipulation and if the contour of the fracture permitted, internal fixation could be performed at another operation, perhaps after wound healing.

Delayed internal fixation was not reserved for the ideal case. On the contrary, it was frequently employed in compound fractures that were major problems under any plan of management, as, for instance, an avulsion of the soft parts of the arm which exposed the shaft of the humerus for several inches or a grossly displaced, infected fracture of the femur, with a huge soft-part wound, 66 days after surgery. These are situations hardly included in the realm of reparative surgery.

SURVEY OF RESULTS

After the program of reparative surgery of compound fractures, including internal fixation on special indications, had been extended to all general hospitals in the Mediterranean theater, the results of this procedure were closely checked. In the majority of cases, they were regarded as satisfactory. The incidence of wound infection had apparently not been increased. Drainage had usually not been prolonged. Ultimate scar formation was expected to be less. Fracture reduction was certainly improved. There seemed, therefore, every reason to hope that there would be considerable improvement in both anatomic and functional end results in the fractures in which this method was employed.

One disturbing fact was that, in spite of frequent warnings to the contrary, a few surgeons in the theater had accomplished internal fixation by plating in a relatively large number of fractures of the tibia. The consultant in orthopedic surgery had repeatedly pointed out that anatomic conditions in this area do not permit satisfactory coverage of the denuded bone by vascular soft parts. The risk of massive sequestration after the application of a plate had also been emphasized. This was particularly true because of the stripping of the periosteum necessary when the plate was applied to the anteromedial surface of the bone. The surgeons who, despite these warnings, attempted to manage fractures of the tibia by plating often found that they had created for themselves major problems in closure of the wound, even when fixation had been carried out through a separate surgical incision. Results observed in the Mediter-

anean Theater of Operations in the management of compound fractures of the tibia by internal fixation were far less satisfactory than the results achieved by this method in fractures of any other long bone.

On the whole, the results observed in cases in which internal fixation had been used seemed highly satisfactory when the patients were examined before evacuation to the Zone of Interior. The results, in fact, seemed particularly good when they were evaluated in the light of the problems which had to be solved in these cases. Overseas observation, however, did not settle the question of end results. For that, investigation in the Zone of Interior was necessary. Previous attempts to secure followup data had not been successful. The Surgeon, Mediterranean Theater of Operations, therefore requested that the consultant in orthopedic surgery for the theater be ordered to the United States, to carry out, among other observations, a survey of casualties with compound fractures who had been treated in the Mediterranean theater by delayed internal fixation and who were then in Zone of Interior hospitals. This survey was carried out in the spring of 1945, with the cooperation and assistance of the Surgical Consultants Division, Office of The Surgeon General.

Materials and Methods

The survey was conducted in 24 general hospitals in the United States between 16 March and 26 April 1945. The 332 fractures surveyed had been managed in 18 general hospitals in the Mediterranean theater, by approximately 50 orthopedic surgeons. The material thus represented a cross section of the battle experience and surgical proficiency of the theater. The majority of the patients had undergone operations in which delayed internal fixation had been performed between 4 June 1944, the date of the fall of Rome, and 1 November 1944, the date of the approximate conclusion of the fighting on the Gothic Line.

Two hundred and ninety-five case reports, representing three hundred fractures, were assembled as follows:

1. From personal examination of patients still hospitalized or still required to report for observation to outpatient clinics.
2. From a study of records of patients still hospitalized but presently absent on furlough or pass.
3. From a study of the records of patients who had been referred to convalescent hospitals, returned to duty, or given a Certificate of Disability discharge.

In each instance, the total record was studied, from wounding to the date of the investigation, and all roentgenograms were examined. The case reports made up as a result of these investigations included, as far as possible, the following data: The precise diagnosis of the bone injury; the diagnoses of associated injuries which might have influenced fracture management; an appraisal of the indication for internal fixation; the type of fixation (plate, screw, wire suture); the time interval between wounding and fixation; the

status of the wound at the time the fixation operation was performed; the surgical approach to the fracture (through the compounding wound or through a separate surgical incision); the presence of wound infection at the time of the fixation operation; the presence of associated nerve injuries; the results achieved from the standpoint of wound healing and bony union; the time at which wound healing and bony union were achieved in relation to the time of the fixation operation; and whether removal of metal and sequestra had been necessary.

Another group of 32 patients consisted of soldiers who had been demobilized, were in convalescent hospitals which were not visited, or had been returned to duty. Their status indicated, with reasonable assurance, that their wounds were healed and their fractures united, which meant that optimal results had been accomplished. Their records, however, were lacking in certain basic data, including the kind of fixation employed and the indication on which operation had been done. These cases, therefore, are necessarily omitted from some of the tabulated presentation of results.

The material secured from this survey is presented chiefly in the form of tabular data, with special emphasis on the results obtained to the date of the investigation in relation to (1) the indications for internal fixation, (2) the technique of fixation employed, and (3) the area of injury. Certain other data are also discussed.

No true controls exist for this series. In all the hospitals surveyed, a serious effort was made to secure data on comparable cases treated by methods other than internal fixation, but the information had not been compiled and could not be obtained. A number of patients were observed, however, whose results might have been improved if internal fixation had been used to stabilize their fractures. In a number of instances of malunion and nonunion in femoral fractures studied roentgenologically, the contour of the fractures suggested that this technique might have been feasible and might have given better results. In a number of fractures of the humerus with segmental defects, it was also thought that union might have been achieved if bony apposition had been maintained by metallic internal fixation.

Definition of Terms

Indications.—Indications for the internal fixations performed in this group of fractures were classified as obligate and elective. The terms carry their own definitions.

Obligate indications included the following:

1. Bone loss which either had produced a segmental defect without contact of the fragments (figs. 38 and 43) or was associated with persistent distraction of the fragments (figs. 30 and 50). In either event, union could not be expected without corrective measures.

2. Fractures about the joints, particularly condylar fractures of the knee or elbow. Reparative measures were necessary in this type of fracture to accomplish joint congruity (fig. 53).

3. Massive soft-tissue loss which precluded routine measures of closure and required staged procedures. Fixation of the fracture was part of the attempt to achieve wound healing.

4. Associated nerve injuries which required, for optimum results, early stabilization of the fracture, sometimes with deliberate shortening of the bone to permit approximation of the severed nerve ends (fig. 39).

5. Failure to achieve and maintain adequate reduction by manipulative measures or traction (figs. 30 and 50). Malunion, delayed union, or nonunion was inevitable in such cases in the absence of corrective measures.

The operations performed under the last mentioned indication were obviously performed after failure of other methods of treatment. In all other operations done on obligate indications, internal fixation was sometimes performed at the first operation of reparative surgery and sometimes later, in many instances after the wound had healed.

All indications which were not obligate were regarded as elective. Elective operations were carried out at the first procedure of reparative surgery.

Results.—Results were classified as favorable, unfavorable, and incomplete, as follows:

Favorable.—This category was further divided into—

1. *Group A.*—In this group of optimum results, the fractures united in perfect, or almost perfect, anatomic alinement, and the wounds healed solidly and promptly, without sequestration and without removal of the metal used in the fixation (figs. 31, 34, 35, and 43). In several fractures of the femur and of the tibia, the metal was removed later, either as a prophylactic measure or because slight evidences of absorption were detected around the screws. Its removal, however, was not necessary to accomplish either wound healing or bony union (figs. 30, 36, and 52).

2. *Group B.*—In this group, the fractures united promptly in adequate reduction, and wound healing occurred satisfactorily after metal and sequestra had been removed (figs. 32, 50, and 63).

Unfavorable.—This category was further divided into—

1. *Group C.*—In this group, union of the fracture occurred promptly but with massive sequestration, and metal and large sequestra had to be removed before wound healing was obtained (figs. 64 and 65). All cases in the C group were fractures of the tibia, a bone in which, as already pointed out, plating is always associated with some risk. The massive sequestration which occurred threatened bony continuity and introduced the risk of refracture when weight bearing was resumed. The risk thus introduced, because of loss of bony strength, made it necessary to use braces for several months (fig. 65).

2. *Group D.*—In this group, wounds healed without sequestration or removal of metal, but bony union had not occurred at the time of the survey.

The results are classified as unfavorable for this reason.¹ From the standpoint of wound healing, management was successful. The fact of nonunion, of course, must be evaluated against the chances of the same result if internal fixation had not been performed (fig. 44).

3. *Group E.*—In this group of fractures, wound healing did not occur, and in most instances fracture union was not achieved, until both sequestra and metal had been removed. The time required for both wound healing and bony union therefore exceeded normal expectancy.

4. *Group F.*—In this group, fractures did not unite, and wounds did not heal. In several instances, wound healing occurred after removal of metal and sequestra, but it was expected that bone-grafting procedures would be necessary in all cases to accomplish bony union (fig. 64). As in group D, these results must be evaluated against the probability of similarly unsatisfactory results if internal fixation had not been employed.

Incomplete.—In these fractures (group G), it was thought that satisfactory end results would eventually be secured, as the fractures were well united. Wound healing, however, had not occurred at the time of the survey. In some instances, plastic procedures on the wound would obviously be necessary, in addition to sequestrectomy and removal of metal, before healing could be expected to occur. In other instances, it was felt that, if metal and sequestra were removed, the same excellent results would follow this secondary procedure as had followed it in another group (B) in the series (fig. 52).

Results in relation to indications for internal fixation are presented for the whole series in tables 17 and 18, and for regional injuries in tables 19, 20, 21, and 22.

Results in Relation to Technique

Results of internal fixation in relation to technique are presented in table 23. As it shows, plating was used in slightly over half of the 332 compound fractures of the long bones included in this survey. The largest proportion of entirely satisfactory results (groups A and B) was obtained with multiple screws; results were excellent in 82 of 95 such cases. There were 21 absolute failures (failure of wound healing and nonunion of the fracture) at the time of the survey in the 168 fractures treated by plating, against 4 absolute failures in 69 fractures treated by wiring. There were no absolute failures in the 95 fractures fixed by screws. There were a number of instances in the unfavorable categories in which it was thought that with the passage of time better results than were then apparent might be achieved.

¹ This category of results was classified as satisfactory in the original report, on the ground that, although the fracture was ununited, the wound was healed and that the chief purpose of the survey was to determine the status of wound healing in fractures treated by delayed internal fixation. Because of the possibility of misunderstanding (since an ununited fracture cannot be considered a satisfactory result), this category of results has been moved to the unsatisfactory group of cases, in the exercise of the editorial function. The author of the volume, who conducted the survey, does not regard the results achieved as entirely unsatisfactory, since this group of cases demonstrated that the use of delayed internal taxation in open or compound fractures due to gunshot wounds did not cause a high incidence of infection. In the great majority of cases, the wound and fracture both healed in due time. It should be remembered that this survey does not represent a study of end results but is rather a progress report; in some instances, sufficient time had not elapsed from the date of internal fixation to permit final evaluation of either wound healing or fracture healing. [Editor's note.]

TABLE 17.—Results of internal fixation performed on obligate indications in 135 compound fractures ¹

Fracture	Favorable		Unfavorable				Incomplete	Total
	A	B	C	D ²	E	F	G	
Humerus.....	24	6	-----	4	1	4	3	42
Radius and ulna.....	11	4	-----	1	-----	2	-----	18
Femur.....	31	7	-----	3	2	7	7	57
Tibia and fibula.....	7	5	-----	1	-----	3	2	18
Total.....	73	22	-----	9	3	16	12	135

¹ See text, pp. 191-192, for code of results.

² See footnote 1, p. 192.

TABLE 18.—Results of internal fixation performed on elective indications in 165 compound fractures ¹

Fracture	Favorable		Unfavorable				Incomplete	Total
	A	B	C	D ²	E	F	G	
Humerus.....	17	2	-----	-----	-----	-----	2	21
Radius and ulna.....	6	1	-----	1	-----	1	-----	9
Femur.....	51	17	-----	2	3	2	4	79
Tibia and fibula.....	27	10	8	2	-----	6	3	56
Total.....	101	30	8	5	3	9	9	165

¹ See text, pp. 191-192, for code of results.

² See footnote 1, p. 192.

TABLE 19.—Results of internal fixation in relation to indications in 67 compound fractures of humerus ¹

Indications	Favorable		Unfavorable				Incomplete	Total
	A	B	C	D ²	E	F	G	
Obligate.....	24	6	-----	4	1	4	3	42
Elective.....	17	2	-----	-----	-----	-----	2	21
Unknown.....	4	-----	-----	-----	-----	-----	-----	4
Total.....	45	8	-----	4	1	4	5	67

¹ See text, pp. 191-192, for code of results.

² See footnote 1, p. 192.

TABLE 20.—Results of internal fixation in relation to indications in 31 compound fractures of radius and ulna ¹

Indications	Favorable		Unfavorable				Incomplete	Total
	A	B	C	D ²	E	F	G	
Obligate.....	11	4		1		2		18
Elective.....	6	1		1		1		9
Unknown.....	4							4
Total.....	21	5		2		3		31

¹ See text, pp. 191-192, for code of results.² See footnote 1, p. 192.TABLE 21.—Results of internal fixation in relation to indications in 146 compound fractures of femur ¹

Indications	Favorable		Unfavorable				Incomplete	Total
	A	B	C	D ²	E	F	G	
Obligate.....	31	7		3	2	7	7	57
Elective.....	51	17		2	3	2	4	79
Unknown.....	10							10
Total.....	92	24		5	5	9	11	146

¹ See text, pp. 191-192, for code of results.² See footnote 1, p. 192.TABLE 22.—Results of internal fixation in relation to indications in 88 compound fractures of tibia and fibula ¹

Indications	Favorable		Unfavorable				Incomplete	Total
	A	B	C	D ²	E	F	G	
Obligate.....	7	5		1		3	2	18
Elective.....	27	10	8	2		6	3	56
Unknown.....	14							14
Total.....	48	15	8	3		9	5	88

¹ See text, pp. 191-192, for code of results. This table includes 13 fractures in which the fibula was plated.² See footnote 1, p. 192.

TABLE 23.—Composite results of internal fixation in relation to technique and location of fracture in 332 compound fractures of long bones¹

Technique and location	Favorable		Unfavorable				Incomplete	Total
	A	B	C	D ²	E	F	G	
Plating:								
Humerus.....	16	3	-----	1	1	3	1	25
Radius and ulna.....	9	2	-----	1	-----	3	-----	15
Femur.....	41	12	-----	2	5	7	5	72
Tibia and fibula ³	16	10	6	1	-----	8	2	43
Fibula and tibia ³	10	1	-----	2	-----	-----	-----	13
Total.....	92	28	6	7	6	21	8	168
Screws:								
Humerus.....	10	3	-----	-----	-----	-----	1	14
Radius and ulna.....	2	-----	-----	-----	-----	-----	-----	2
Femur.....	39	7	-----	1	-----	-----	6	53
Tibia and fibula ³	19	2	2	-----	-----	-----	3	26
Fibula and tibia ³	-----	-----	-----	-----	-----	-----	-----	-----
Total.....	70	12	2	1	-----	-----	10	95
Wire:								
Humerus.....	19	2	-----	3	-----	1	3	28
Radius and ulna.....	10	3	-----	1	-----	-----	-----	14
Femur.....	12	5	-----	2	-----	2	-----	21
Tibia and fibula ³	3	2	-----	-----	-----	1	-----	6
Fibula and tibia ³	-----	-----	-----	-----	-----	-----	-----	-----
Total.....	44	12	-----	6	-----	4	3	69
Grand total.....	206	52	8	14	6	25	21	332
Percentage.....	62.1	15.7	2.4	4.2	1.8	7.5	6.3	100.00

¹ See text, pp. 191-192, for definition of terms.

² See footnote 1, p. 192.

³ Tibia and fibula—plating of tibia. Fibula and tibia—plating of fibula.

Sequestration was apparently the chief hazard associated with internal fixation (fig. 64). It occurred in slightly over a third of the cases surveyed and, case for case, seemed more extensive than might have been expected in the light of cases in which this procedure had not been used. Experience overseas had shown that in the ordinary course of events sequestration was practically always limited to areas of bone which had, presumably, been denuded at wounding; these areas were increased by the periosteal stripping necessary when internal fixation by plating was used. In some cases surveyed in the Zone of

Interior, failure of wound healing was clearly attributable to delay in removal of sequestra as well as metal. Since the fractures were well united in all of these cases, there seemed no reason for having postponed the secondary surgery which was obviously necessary.

Sequestration was only occasionally massive when screw or wire fixation was used. When it occurred with these techniques, it did not seem to interfere with union of the fracture. In such cases, it would probably have occurred no matter what method of fracture management had been employed. There was no doubt, however, of the tendency toward sequestra formation when plating was employed. It occurred in 69 of the 168 fractures treated by this technique and was sometimes so massive that the resulting bony defect could be compensated for only by bone grafting.

Sequestration seemed less likely to occur, particularly when plates were used, if the internal fixation was done through a separate incision rather than through the compounding wound. It was also thought that wound healing occurred more promptly if the operation was performed through a separate incision.

Other Data

The details of 29 fractures in which internal fixation was performed in the presence of established wound infection are presented in table 24. The average time from wounding to operation in these cases was 36 days.

Only 37 nerve injuries were recorded in these 332 fractures, 21 in fractures of the humerus, 6 in fractures of the radius and ulna, 9 in fractures of the femur, and 1 in a fracture of the tibia and fibula. Only 1 nerve injury in 88 fractures of the tibia and fibula seems unlikely; other nerve injuries probably occurred and were not recorded.

TABLE 24.—*Results of internal fixation in 29 compound fractures with established wound infection*¹

Fracture	Favorable		Unfavorable				Incomplete	Total
	A	B	C	D ²	E	F	G	
Humerus.....	1			1			1	3
Radius and ulna.....		1				1		2
Femur.....	9	3		2	2	4	1	21
Tibia and fibula.....			1			1	1	3
Total.....	10	4	1	3	2	6	3	29

¹ See text, pp. 191-192, for code of results.

² See footnote 1, p. 192.

Refracture, which in each instance involved the femur, occurred 7 times in these 332 fractures. In 6 of the 7 refractures, the second fracture occurred at a point at which there had been bone loss at the site of the original injury. In the seventh refracture, the bone loss had been caused by sequestration. In four instances, there was no obvious cause for the second fracture. In two instances, the refracture followed falls, and in the remaining instance it followed manipulations to secure motion of the knee joint. In spite of the complication of the second injury, the end results were good to excellent in all seven refractures.

Generally speaking, although no statistics were collected to prove it, it was thought that the range of knee motion following rigid internal fixation (that is, by plates and screws) of fractures of the femur, when surgery was supplemented by a program designed to achieve maximum functional results, exceeded the range achieved in comparable injuries managed by other methods. The range of knee motion, however, varied with the level of the fracture. Knee motion was excellent in some fractures of the upper half of the femur. It was less good in many fractures of the lower half and was particularly unsatisfactory in fractures of the lower third. In many cases, the explanation of less than satisfactory knee function was failure to institute a program of knee motion after the patient reached the Zone of Interior in a hip spica. The omission of this program simply failed to capitalize on one of the decided advantages of internal fixation.

It was interesting to observe the results in patients who had come from the 21st General Hospital in the Mediterranean theater, which was known to have an excellent program of postoperative knee motion in effect on its fracture wards. Whether the patients with fractured femurs from this hospital had or had not been managed by internal fixation, the range of knee motion, case for case, was superior to the range of motion observed in patients from other hospitals.

CONCLUSIONS OF THE SURVEY

It was concluded from this survey of internal fixation carried out in hospitals in the Zone of Interior that, when this procedure is used on correct indications and is performed by the correct technique, it has a definite, if limited, place in the management of battle-incurred compound fractures of the long bones in fixed hospitals overseas. The term "correct indications" implies that the operation is performed only as an adjuvant measure and within the strict limitations of reparative surgery. Failure to institute surgical measures to forestall infection and favor wound healing invariably prejudices the results.

There were no deaths and no amputations in these 332 fractures. The overall results were satisfactory to excellent with two groups of exceptions, fractures associated with massive soft-tissue loss and fractures of the tibia and fibula managed by plating.

In the light of the results achieved in this series and evident in this survey, conclusions concerning the results possible of achievement by delayed internal fixation may be stated as follows:

1. Nonunion can be prevented in fractures with segmental defects or persistent distraction, as is evidenced by the achievement of bony union in 27 of 39 such fractures in this series.

Varying degrees of malunion, delayed union, or nonunion can be prevented in many cases in which inadequate reduction was achieved by other measures. This is evidenced by the achievement of bony union in good apposition and alinement in 64 of 75 such fractures in this series.

Bony union, with optimal reduction, can be achieved in condylar fractures about the knee and elbow. This result was achieved in all 15 such fractures in this series.

The obvious advantages of well-stabilized optimum reduction can be achieved in fractures which lend themselves to rigid stabilization, and satisfactory wound healing may be achieved in many cases, provided that fixation is accomplished by multiple screws, with minimal periosteal stripping. Union was accomplished in good position in all 95 fractures thus managed in this series. Wound healing was accomplished without sequestration or removal of metal in 71 of these fractures and was accomplished after their removal in another 14.

When plating is the method of fixation, bony union and satisfactory wound healing must be anticipated in a smaller proportion of cases. In 168 fractures managed by this technique, bony union was accomplished in 140. Wound healing was accomplished without sequestration or removal of metal in 99 fractures and was accomplished after their removal in another 34.

Improved apposition of fragments can sometimes be provided by the use of wire sutures, and favorable results may be anticipated in many instances. When this technique was used in this series, bony union was accomplished in 59 of 69 fractures. Wound healing, without sequestration and without removal of metal, was accomplished in 50 fractures, and in another 12 the wound healed after metal and sequestra were removed. Four fractures in which wire sutures were used were absolute failures, and three others were incomplete at the time of the survey.

2. The chief hazard of delayed internal fixation, namely, increased sequestration, may be explained by the periosteal stripping which the procedure entails and by its interference with readherence of soft parts to denuded bone. Other observations indicate that sequestration of bone in nonfixed battle fractures is practically always limited to bone that was probably denuded at wounding. Sequestration occurred in a little over a third of the fractures in this series, but comparable data in a control series are not available.

The sequestration which occurred in this series when screw or wire-suture fixation was used was seldom massive, did not seem to interfere with union of the fracture, and probably would have occurred in many cases if the fractures had been managed by other methods.

Massive sequestration occurred in 41 of the 168 fractures which were managed by plating, with retardation of attainment of full strength of the bone. In some fractures managed by plating, a massive defect may be created which is reparable only by bone grafting.

3. Unless the fracture contour permits rigid fixation by screws or unless wire sutures appear advantageous, it is best to attempt reduction by traction or manipulation and strive for early wound healing. When wound healing has been accomplished, fixation by plating or some other technique is relatively safe. Wound healing occurred by this plan in 20 of 21 fractures in this series, without sequestration or removal of the metal.

Excellent results may be expected in fixations of the long bones of the upper extremity if severity of bone loss or of the soft-tissue injury does not prejudice the chances of union and wound healing. Massive soft-tissue loss had occurred in this series in 5 of 7 failures of internal fixation of fractures of the upper extremity, and bone loss had occurred in the other 2 fractures.

Fixations of the femur, performed on correct indications, by means of multiple screws or wire sutures and with minimal periosteal stripping, may be expected to give excellent results. In this series, there were no failures in fractures of the femur fixed by screws. Bone loss was responsible for the two failures with wire-suture fixation. One of the patients, in addition, had suffered a massive loss of soft tissue. The risk of the periosteal stripping necessary when plating is employed makes it preferable to delay fixation until after wound healing unless the indications and anticipated advantages overshadow the hazard.

Fixation of the tibia by multiple screws or wire suture may be expected to give very satisfactory results. Periosteal stripping should be kept to a minimum. There were only two unfavorable results in the fractures in this series fixed by screws; in both, heavy sequestration occurred. The single entirely unfavorable result in the fractures fixed by wire sutures was expected, ultimately, to be favorable; only 4 months had elapsed since wounding, and it was thought that the fracture would eventually unite. Plating of the tibia should be reserved until after wound healing. Eight of the nine failures in fixations of the tibia, and six of the eight massive sequestrations, occurred after plating of this bone. A more extensive use of wire sutures to maintain approximation might have improved results.

When both tibia and fibula are fractured, plating of the fibula may be a useful procedure, and one which is relatively safe. It maintains length and alinement, aids in achieving apposition of tibial fragments, and provides some degree of immobilization of the fracture of the tibia.

4. Internal fixation, when used as an adjuvant to the management of unreduced, infected compound battle fractures, may aid in the control of infection and in achieving the best result which can be obtained in the circumstances. In the 29 infected cases in this series (table 24), bony union was achieved in good alinement in 20, and wound healing occurred without further

sequestration in 13. In 13 additional cases, wound healing occurred after removal of sequestra and metal.

This followup study of 332 compound fractures, all but 13 of which were combat incurred, revealed satisfactory to optimal results in 258 cases (77.7 percent). These 258 fractures illustrate the optimum results which could have been achieved. They include 21 fractures in which removal of metal and sequestra had not yet been performed but in which excellent results could be expected after secondary surgery had been carried out. They do not include eight fractures of the femur in which massive sequestration had occurred but in which there seemed reason to hope that satisfactory weight-bearing extremities would eventually be secured.

ANALYSIS OF UNFAVORABLE RESULTS

The 53 fractures classified as unsuccessful fall into 4 groups:

Eight operations, all performed on elective indications (group C). In this group, union of the fracture occurred promptly, but metal and massive sequestra had to be removed before wound healing was obtained. All cases in this group were fractures of the tibia, in which plating is always associated with some risk. The massive sequestration which occurred threatened bony continuity and introduced the risk of refracture when weight bearing was resumed. This risk made it necessary to use braces for several months longer than was necessary in the A and B groups.

Fourteen operations, nine performed on obligate and five on elective indications (group D). In this group, union had not occurred at the time of the survey, and, for this reason only, the results are classified as unfavorable.² From the standpoint of wound healing, the result was successful. The fact of nonunion, furthermore, must be evaluated against the chances of the same result if internal fixation had not been performed.

Six operations, three performed on obligate and three on elective indications, in which wound healing did not occur and, in most instances, union of the fracture was not achieved, until both sequestra and metal were removed (group E). The time required for both wound healing and bony union therefore exceeded normal expectancy.

Twenty-five operations, sixteen performed on obligate and nine on elective indications, in which fractures did not unite and wounds did not heal (group F). The fractures in this group represent the only absolute failures in the series, and, even in it, wound healing occurred in several instances after removal of metal and sequestra. It was expected, however, that bone-grafting procedures would be necessary in all cases to accomplish bony union. As in group D, these results must be evaluated against the probability of similarly unsatisfactory results if internal fixation had not been employed.

² See footnote 1, p. 192.

These unfavorable results, to consider the fractures from the separate standpoints of wound healing and bony union, include 14 fractures in which wound healing occurred but bony union did not; 8 fractures in which bony union occurred but wound healing was obtained only after metal and massive sequestra were removed (all fractures of the tibia); 6 fractures in which wound healing did not occur and bony union was usually not achieved until both sequestra and metal were removed; and 25 fractures in which neither union of the fractures nor wound healing was accomplished.

In the 53 unfavorable cases, 19 operations were performed on the femur, 20 on the tibia and fibula, 9 on the humerus, and 5 on the radius and ulna. Twenty-five were performed on elective and twenty-eight on obligate indications.

Certain of these cases warrant special comment:

In 2 operations on the femur performed on obligate indications, 1 managed by plating and 1 by wiring, the indication was segmental bone loss so extensive that nonunion was regarded as probably inevitable by more conservative methods. In a third fracture, which was managed by plating, previous management had been unsuccessful. The fracture was double, and the large rotated central fragment could not be reduced. When the patient was surveyed, the proximal fracture was well united, and it was thought that the distal fracture might still unite. In spite of the unsuccessful result in this case, the use of internal fixation was regarded as both justified and advantageous.

In one of the elective operations on the femur, the fracture, which was mildly comminuted, was only partly stabilized by screws and wire sutures; the operation had been performed in an infected field. The patient had already undergone amputation of the foot on this side and amputation of the contralateral leg for infection. He was observed only 4 months after wounding, and it was thought that the fracture might still unite. In another unsatisfactory operation, the major fragments of the severely comminuted femur were sutured in apposition. The wound was infected, the infection extending into the joint, and the fracture site had to be drained by dependent drainage. The failure of union in this case could not be attributed to internal fixation.

In one operation on the tibia and fibula, classified as unfavorable because of nonunion although the wound healed promptly, the failure must be charged against poor technique; examination of the roentgenograms taken overseas showed that the bone had been plated with the fragments distracted. In another operation, a 4-inch defect in the tibia had been strutted by plating the fibula, in expectation of a later bone-grafting operation. In a third operation, nonunion was explained by bone loss and unsatisfactory contact of the fragments.

In three unfavorable operations on the humerus, all managed by wiring, there was segmental bone loss. It is interesting that in 10 similar operations in the series union was achieved by the same technique. In another operation, plating was performed 25 days after wounding, when wound healing was complete, because conservative measures of fracture management had failed to achieve satisfactory reduction.

In a fracture of the bones of the forearm in which internal fixation failed to produce union even though the wound healed, the indication for operation was bone loss. The ulna was intact, but there was a 1-inch segmental defect in the radius. A wire suture was applied to help maintain alinement, without any real expectation that union could be accomplished. In another patient, with a fracture of the radius and a double fracture of the ulna, the indication was elective. A Steinmann pin which had been passed down the medullary canal of the ulna had to be removed at the end of 3 weeks, and the radius was plated at this time. When the patient was observed in a Zone of Interior hospital, neither fracture of the ulna had united and reduction was poor, but it was thought possible that union of the radius might still be accomplished.

In the 25 operations regarded as absolute failures, 16 were performed on obligate and 9 on elective indications. The failure in each case must be evaluated in the light of the severity of the problem and the indications for fixation. When the 25 fractures are analyzed from this standpoint, the conclusion is reached that 2 fractures had been improved by internal fixation; 8 had not been, though progress had not been retarded; and 13 (3.9 percent of the 332 fractures in the series) had been harmed by the operation. In the two remaining fractures, a final evaluation from this standpoint was not possible at the time the survey was made.

EDITOR'S NOTE.—It should be emphasized again, as the author has noted already (p. 191), that fixation of the tibia with plates and screws yielded the highest percentage and the greatest number of unfavorable results in the open fractures treated by internal fixation. Unfortunately, these techniques are the easiest to accomplish. These facts should be brought home to every medical officer. Otherwise, the tibia will continue to serve as a boobytrap for the unwary, incompletely trained surgeon, with the wounded soldier as the victim.

CHAPTER VII

External Skeletal Fixation of Fractures in the Communications Zone¹

The experience with external skeletal fixation in the management of battle-incurred compound fractures in the Mediterranean Theater of Operations in World War II is of historical interest only. Apparatus for external skeletal fixation became available in the theater for certain general hospitals and a smaller number of specially authorized station hospitals in the summer and fall of 1943. Almost as soon, however, as the method began to be used, it became evident that its indiscriminate use in military surgery was attended with pitfalls and hazards and that its application must be rigidly restricted. For these reasons, it had a very limited use in the Mediterranean theater, and this report chiefly concerns the special hospitals in which it was employed.

The restrictions placed upon the use of external skeletal fixation in combat-incurred compound fractures were specified in Circular Letter No. 48, Office of the Surgeon, North African Theater of Operations, 18 November 1943.² In substance, they were as follows:

External skeletal fixation is a highly specialized technique of fracture management, to be used only in carefully selected cases, only on special indications, and only by surgeons trained and experienced in its application. If an indication arises for its employment in a hospital whose staff does not include a surgeon with these qualifications, the patient must be transferred to a hospital in which trained personnel is available.

Only under emergency conditions may a patient be transferred from one hospital to another with apparatus for external skeletal fixation in place. If the transfer is not avoidable, he must be assigned to a hospital whose staff includes a surgeon trained in its use. Evacuation to the Zone of Interior with the apparatus in place is not permissible. If further immobilization is required, the patient must be held in an overseas hospital until the pins can be removed and more conventional methods of splinting substituted.

ANALYSIS OF CASES

Circular Letter No. 48 also provided that the clinical record of each patient treated by external skeletal fixation must be forwarded, through channels, to the Surgeon, North African Theater of Operations, after treatment had been

¹ Data for this chapter were collected by Maj. Herbert W. Harris, MC, and Capt. Edwin L. Mollin, MC, 17th General Hospital.

² See appendix, pp. 312-316.

completed. The record was to cover all details of the case, including the date and circumstances of wounding; a complete description of the fracture and of the compounding wound if the fracture was compound; the initial treatment; the indications for external skeletal fixation; the length of time required to apply the apparatus and reduce the fracture; the number of roentgenograms required; the date, character, and extent of any distraction observed; the occurrence of infection about the pins; other complications; the date of removal of the apparatus; the subsequent management of the injury; and the disposition and end results.

These instructions, unfortunately, were not universally carried out, and the complete data which it had been hoped would be accumulated in the Office of the Surgeon therefore did not become available. In an effort to supply the deficiency and determine the extent of the usage of external skeletal fixation and the results achieved by it, a survey was carried out early in 1945, on the orders of the Surgeon, in each of the general and station hospitals in which the apparatus had been made available.

Four of the general hospitals in which provision had been made to employ external skeletal fixation treated no cases at all by it. Another hospital used the method in a few cases early in 1943 and had such poor results that it abandoned the technique entirely. The records were not available for some 35 cases treated in 2 general and 1 station hospital which left the theater in August 1944 to support the invasion of southern France.

The final report, therefore, covers only 8 general and 2 station hospitals and includes only 146 cases, all treated in 1944 and all recorded in sufficient detail to permit a reasonably satisfactory analysis. Some 20 other cases treated in these hospitals by external skeletal fixation had to be discarded because of paucity of data. Representative experiences are presented in tables 25, 26, and 27.

After a full year of experience with external skeletal fixation used according to the instructions set forth in Circular Letter No. 48, there was no unanimity of opinion concerning the merits of the technique. The small group of surgeons who had seen no place for it in civilian practice had been unwilling to give it a trial under military circumstances. Surgeons who had had an extensive previous experience with it and had therefore expected that it would have a wide application in both simple and compound combat-incurred fractures for the most part changed their opinion and restricted or discontinued its use. On the other hand, a group of surgeons with limited experience with the technique in civilian orthopedic practice believed that it offered decided advantages in carefully selected cases, and a number of them, as their military experience increased, actually broadened the indications.

Complications.—Drainage from the sites of the pins was fairly frequent in these 146 cases but could usually be terminated by removal of the pins. Osteomyelitis was reported at the sites of the pins in only two cases in the series. In one instance, it developed about a pin far removed from the wound and must be considered a primary infection. In the other case, it extended

from a severely infected compound fracture of the os calcis to a lower pin in the tibia. In both instances, wound healing was obtained after removal of dead bone and the institution of drainage. The only other serious complication in the series was an abscess which developed about a lower femoral pin; it responded promptly to drainage.

TABLE 25.—*Essential data on 14 fractures treated by external skeletal fixation, 33d General Hospital, 1944*

Fracture	Indication	Complications	Results
Lower third humerus, compound, comminuted.	Elective (plated).....	Mild infection about pins.	Union.
Lower third humerus, simple, comminuted.	Elective.....	do.....	Do.
Middle third humerus, compound, comminuted.	Comminution, skin grafting.....	Do.
Middle third ulna, simple.....	Extensive burns.....	Delayed union.
Ulna, compound, comminuted, dislocation head radius.	Malposition fragments, both bones.....	Union, stiff elbow.
Radius and ulna, compound, comminuted.	Comminution, displacement.....	Mild infection about pins.	Union.
Proximal third radius and ulna, compound, comminuted.	do.....	do.....	Nonunion.
Middle third femur, simple, comminuted.	Elective.....	Unknown.
Proximal third femur, simple, comminuted.	Comminution, malposition, shortening.....	Mild infection about pins.	Do.
Middle third femur, simple, comminuted.	Overriding, displacement.....	do.....	Do.
Middle third femur, simple.....	Elective.....	do.....	Early callus at evacuation.
Do.....	Overriding, displacement.....	do.....	Unknown.
Middle third femur, compound, comminuted.	do.....	do.....	Do.
Do.....	Displacement, shortening.....	do.....	Do.

TABLE 26.—*Essential data on 27 fractures treated by external skeletal fixation, 26th General Hospital, 1944*

Fracture site	Cases	Average duration of fixation	Results			
			Union	Delayed union	Nonunion	Unknown
	<i>Number</i>	<i>Days</i>				
Tibia, fibula.....	¹ 11	68	3	3	3	1
Tibia.....	1	18	1			
Femur.....	6	81.2	3	2		1
Humerus.....	3	49.6	2			1
Radius, ulna.....	3	52.8	2		1	
Radius.....	1	27	1			
Metacarpal.....	1	Unknown				1
Resection knee joint.....	1	52	1			
Total.....	27	61.39	13	5	4	4

¹ Amputation was required in 1 case, on indications not related to fracture management.

TABLE 27.—*Essential data on 25 fractures treated by external skeletal fixation, 17th General Hospital, 1944*

Fracture	Indication	Complications	Results
Radius, wrist, simple	Comminution		Union.
Radius, wrist, dislocation	Maintenance length and alignment at radial carpal joint.		Do.
Do.	Vertical fracture, reduction not possible in plaster.		Union, full duty.
Radius, wrist, simple, comminuted	Comminution		Union.
Radius, ulna, simple	Elective		Do.
Radius, ulna, lower third, compound, comminuted.	Comminution	Irritation (no infection).	Nonunion ulna, delayed union radius.
Femur, compound, comminuted	do.		Union.
Do.	Comminution, bone loss, traction failure.	Osteomyelitis at site of pin.	Do.
Femur, distal third, compound, comminuted.	Comminution, rotation distal fragment, to supplement traction.		Do.
Do.	do.		Do.
Do.	Rotation distal fragment.		Unknown.
Do.	Rotation distal fragment, to supplement traction.		Union.
Femur, compound, comminuted, into knee joint.	Fixation after resection of knee joint.		Do.
Femur, tibia, compound, comminuted, infected knee joint.	do.	Infection about pin in tibia.	Do.
Femur, lower third into knee joint, tibia and fibula, compound, comminuted.	Fixation after resection of knee joint.		Union resected knee, nonunion tibia.
Femur, compound, comminuted, tibia and fibula into knee joint.	do.		Union.
Femur, compound, comminuted, into knee joint.	do.		Do.
Femur, lower third, simple	Traction failure in alignment of short distal fragment; supplemental to skeletal traction.	Mild irritation about proximal pin.	Do.
Femur, lower third, compound, comminuted.	Traction alone failure; supplemental to traction.		Do.
Femur, simple, mid shaft	Failure to control distal fragment in traction; supplemental to traction.		Do.
Do.	Elective	Bowing fascial slough at site of pin.	Delayed union. ¹
Femur, proximal third, compound, comminuted.	Traction failure: supplemental to traction.		Union.
Femur, supracondylar, compound, comminuted.	To correct rotation distal fragment; supplemental to traction.		Do.
Femur, condyles, compound, comminuted.	Fixation after resection of knee joint.		Do.
Compound dislocation, infection ankle joint.	Fixation after resection of ankle joint.		Unknown.

¹ After replacement by skeletal traction.

Comment

The results of this analysis, together with discussions with the surgeons who had used the method, confirmed the opinion that external skeletal fixation has only a limited application in the management of combat-incurred

fractures in overseas hospitals. Under special circumstances, it was thought to be a useful adjuvant to standard methods of treatment, and, in certain cases it might be the method of choice, but the indications were seldom regarded as absolute.

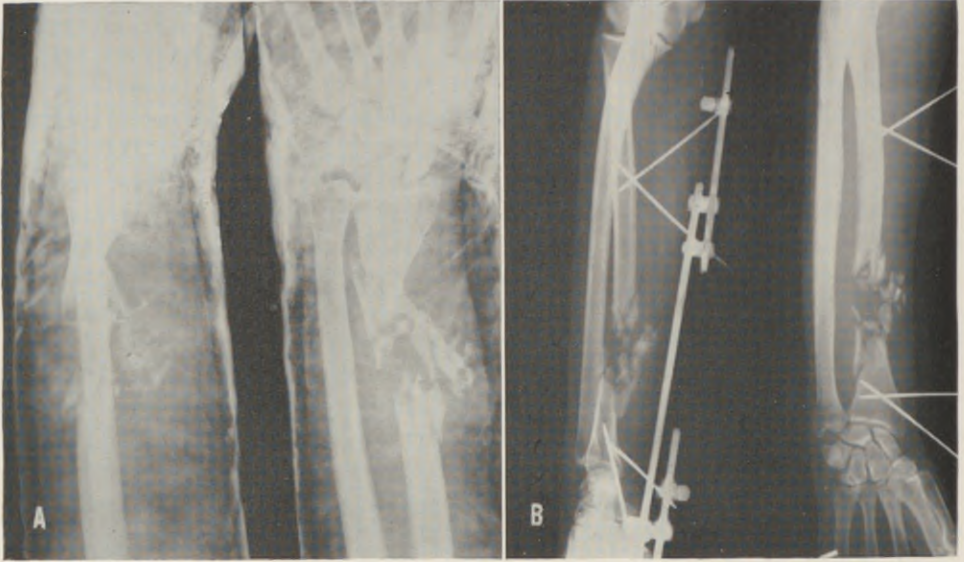
There were a number of clear-cut contraindications to the use of external skeletal fixation in simple fractures in which it might have been the method of choice in civilian practice. They included (1) the length of time required to insert the pins and reduce the fracture; (2) the exacting care required to avoid loss of reduction and to prevent the development of complications during healing; and (3) the necessity for holding the patient in the hospital in which the pins had been applied until they could be removed. These were all matters of real importance in busy military hospitals.

The application of external skeletal fixation in compound battle fractures was similarly limited although under certain circumstances it was thought that the time and care which the method required might be compensated for by the results that might be achieved.

The World War II experience suggests that this technique might be applicable, in carefully selected cases, in the following situations:

1. Fractures of long bones with severe comminution and loss of substance. Fractures of this kind have always been a problem in military orthopedic surgery. Loss of bone at wounding or the necessary removal at operation of fragments totally devoid of soft-tissue attachments might leave a partial or complete hiatus, sometimes of 2 or 3 inches. In these circumstances, it was difficult to maintain apposition of the fragments by plaster or traction, and comminution made internal fixation impractical. External skeletal fixation permitted stabilization of the fragments in apposition under direct observation. There was some loss of length, it is true, but in the upper extremity this is not a matter of importance. In the lower extremity, loss of length is serious. When it was expected to exceed an inch or an inch and a half it was therefore sometimes considered advisable, even if the fragments could have been approximated, to brace them apart until wound healing had been obtained, in preparation for a bridging bone graft at a later reconstructive operation. In this way, shortening could be minimized. External skeletal fixation sometimes served this purpose very well. It was similarly effective when loss of substance had been extensive in an occasional fracture of a single bone in the forearm or the leg.

2. Persisting malalignments of fractures. External skeletal fixation proved useful in a few subtrochanteric and supracondylar fractures of the femur in which reduction could not be obtained by skeletal traction, presumably because of persistent and unopposed muscle tension. An analysis of the cases included in the survey showed that this technique had been the method of choice in a number of such fractures after skeletal traction had failed. It was necessary, however, that additional immobilization be provided by skeletal traction or by a hip spica. Stability was lost in a number of cases in which this precaution was not observed.



AFIP C-45-770

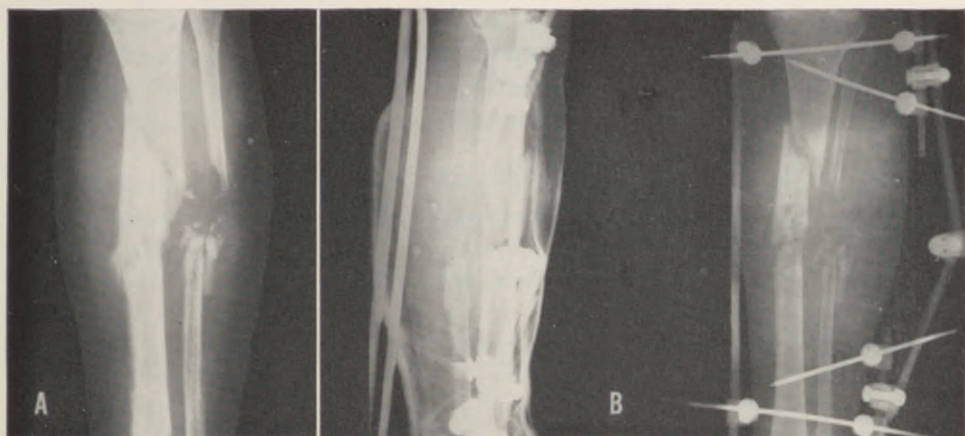
FIGURE 68.—Management of compound comminuted fracture of left radius, with loss of bone substance and median-nerve palsy, by external skeletal fixation. A. Compound comminuted fracture of distal third of radius. Note loss of bone substance. B. Maintenance of reduction of fracture by external skeletal fixation.

Five weeks after the fixation apparatus had been applied, the wounds were well healed; they had been left open at the original operation and were later closed with the aid of pinch skin grafts. The pins were removed 2 months after wounding, after moderate drainage had developed about them. Roentgenograms showed only scanty callus at this time, but the fracture was in excellent alinement, and the patient had good finger motion except for the area affected by median-nerve palsy.

In this case, external skeletal fixation preserved alinement and bone length while the soft tissues were healing. It also allowed motion of the adjacent joints to a much greater degree than would have been possible had the extremity merely been immobilized in plaster.

3. Compound comminuted fractures of the tibia and fibula. In this type of fracture both maintenance of reduction and wound healing were frequently difficult when the more usual methods of management were employed. In a few cases, the fractures could be reduced under full vision and locked in position by external skeletal fixation. A reinforcing plaster cast was also used. Some surgeons felt that this combined technique produced better results than plaster immobilization alone.

4. Comminuted fractures of both bones of the forearm. For a number of reasons, these fractures constituted one of the most difficult problems of military surgery. In a few cases, the difficulty was overcome by the use of external skeletal fixation, which produced improved apposition and alinement of the fragments.



AFIP C-45-775

FIGURE 69.—Management of segmental compound comminuted fractures of proximal third of left tibia and fibula by external skeletal traction. A. Roentgenogram of fractures. B. External skeletal apparatus in place.

When the cast was changed 1 month after wounding, the wound was granulating, but the crest of the tibia was exposed. Ten days later, all bone was covered with granulating tissue, and clinical union was apparent. The pins were removed as soon as the new cast had hardened thoroughly. When the cast was again changed at another hospital 30 days later, the wound was healed, and the fracture site, although not rigidly solid, felt well fixed. In spite of the severity of the injury, length and alignment were preserved in the tibial fracture.

5. Comminuted fractures of the lower radius (fig. 68), in which shortening and collapse of the fragments often introduced a number of problems. External skeletal fixation was occasionally effective in maintaining length and normal joint alignment in both simple and compound fractures with severe comminution. A reinforcing cast was neither necessary nor desirable. When the apparatus was in place, motion of the fingers and of the thumb was possible. The results achieved in this type of injury suggested that external skeletal fixation was sometimes the procedure of preference.

6. Burns or other wounds which required multiple staged operative procedures and in which repeated access to the wounds was necessary. Windows cut in casts did not always provide the exposure required, and frequent changes of cast would have resulted in loss of position of the fracture, while the manipulations necessary to restore position would have prejudiced the healing of both fracture and wound. External skeletal fixation provided maintenance of reduction while delayed closure, skin grafts, and other procedures were carried out.

7. Segmental fractures. Segmental fractures (fig. 69) with displaced central fragments are usually difficult to reduce. The two such cases included in this series, one a fracture of the tibia and fibula and the other a fracture of the femur, were both managed successfully by external skeletal fixation.

8. Resection of the knee and ankle joints (p. 231). In an occasional case of this kind, external skeletal fixation resulted in stable approximation of the bone surfaces and permitted repeated access to the wound for such procedures as were necessary to accomplish wound healing. A reinforcing plaster spica was used.

As this list of indications shows, external skeletal fixation had a limited application in the management of battle fractures, its chief use being on a few specialized indications or as a supplement to other methods. In the great majority of cases, combat-incurred fractures were much better managed by other methods, and there was little or no need for apparatus for this method in a theater of operations.

CHAPTER VIII

Wounds of Joints¹

HISTORICAL NOTE

Pool, who wrote the section on wounds of the joints in the history of the United States Medical Department in World War I,² stated that the evolution of the management of these injuries by Allied medical officers fell into three well-defined stages:

1. Débridement; drainage; irrigation with antiseptic solutions; immobilizations. 2. Débridement; Carrel-Dakin treatment of the joint; immobilization. 3. Débridement; lavage of the joint with Dakin's solution or ether; joint suture, with drainage of the joint for about 24 hours; immobilization; passive movements and massage in 8 to 10 days.

According to Pool, the poor results accomplished in joint injuries in the early years of World War I could be attributed to—

* * * an undervaluation, on the part of surgeons, of the resistance to infection which the synovial membrane of a joint offers, a failure to comprehend the proper operative procedures, and the universal employment of prolonged immobilization.

Certainly a realization of the importance of the three chief features that characterized the final program; namely, debridement, complete closure of the joint, and early motion, developed slowly. In the early years of the war, surgeons hesitated to close a wounded joint for fear of enclosing a potential septic process. Drainage tubes were therefore used freely. In November 1917, however, the Interallied Surgical Conference, when it met in its third session,³ concluded that "complete closing of joint wounds is universally approved." Early in the war, repeated efforts were made to obtain chemical sterilization of the joint cavity by the use of various antiseptic methods and solutions, including, somewhat later, the Carrel-Dakin method. Eventually, there was general agreement that sterilization could not be achieved by these methods and that drainage tubes not only failed to drain the joint but also caused considerable harm by trauma to the intra-articular structures and by inviting secondary infection. Drainage of the compounding wound was, of course, an entirely different matter.

¹ The data in this chapter on wounds of the knee joint were collected by Maj. Herbert W. Harris, MC, and Capt. Edwin L. Mollin, MC, 17th General Hospital; Maj. Howard B. Shorbe, MC, 70th General Hospital; and Lt. Col. George A. Duncan, MC, and Maj. Benjamin W. Rawles, MC, 45th General Hospital. The data on wounds of the hip joint were collected by Maj. Spencer A. Collom, Jr., MC, 300th General Hospital.

² Pool, Eugene H.: *Wounds of Joints*. In *The Medical Department of the United States Army in the World War*. Washington: Government Printing Office, 1927, vol. XI, pt. 1, pp. 317-341.

³ Conclusions of the Interallied Surgical Conference, 3d session. In *The Medical Bulletin, War Medicine, 1917-18*, vol. I, pp. 77-78.

Finally, immobilization for long periods was the rule in the early days of the war. Willems, whose work was done chiefly at La Panne in Belgium, provided the principal exception to this position.⁴ He contended that early, active motion was essential in all penetrating wounds of the joint and particularly in wounds of the knee joint, regardless of whether or not infection was present. He considered early motion, in fact, as especially essential in infected wounds of the knee joint, his contention being that by motion purulent exudate was "squeezed" out of the recesses of the joint, without the traumatizing effect of drainage tubes, while continued motion prevented ankylosis and favored full functional restoration. Some of his results were brilliant. Pool mentioned the Willems method approvingly but supplied no supporting data. In spite of the results Willems was able to achieve, his concepts spread very slowly, and the general opinion continued to be that early active motion was even more impractical when suppurative arthritis was present than it was in uncomplicated penetrating wounds of the knee joint. The theory was generally accepted, however, that motion should be begun reasonably early, which usually meant within 10 days of injury.

Resection of joints that were the site of suppurative arthritis following penetrating wounds had been practiced in all recorded wars preceding World War I, including the War of the Rebellion. In World War I, the French used this method extensively. It was sometimes employed as a primary prophylactic procedure, to eliminate the risks of infection and subsequent generalized sepsis and to avoid the necessity for amputation. In other instances, it was used as a secondary procedure in joint wounds complicated by suppurative arthritis. The high death rate and the high amputation rate reported for wounds of the major joints in all previous wars and in the early phases of World War I furnished ample rationale for this practice, particularly in severely comminuted fractures extending into the joint. The operation, however, found little favor with either British or American surgeons in World War I, though Pool stated that it had a limited application, to be determined by individual indications, in cases of suppurative arthritis not progressing satisfactorily under more conservative methods of management.

The civilian experience with wounds of the joints between World War I and World War II is in no sense comparable to military experiences. Neither in number nor severity do civilian wounds compare with battle-incurred wounds. Furthermore, the suppurative arthritis observed in civilian practice is usually bloodborne, in contrast to the predominantly traumatic etiology of the variety observed after battle-incurred wounds.

In peacetime practice, suppurative arthritis continued to be treated between the wars by parapatellar drainage or, less often, by posterior drainage, combined with immobilization of the part by splints or by plaster casts. The Willems method of early mobilization, which some surgeons continued to use after World War I, gradually lost favor and was eventually discarded

⁴ See footnote 2, p. 211.

entirely. Occasional surgeons practiced aspiration of the joint. Others advocated a small arthrotomy incision and lavage of the cavity followed by complete closure. Sulfonamide therapy, which was introduced shortly before World War II began, was thought to be beneficial.

Both Jolly⁵ and Trueta,⁶ on the basis of their separate experiences in the Spanish Civil War, had concluded that the best method of management of war wounds of the joints seen in forward hospitals was (1) adequate debridement and removal of foreign bodies, (2) thorough lavage of the joint cavity, (3) suture of the synovial membrane or the capsule, and (4) immobilization of the part either in plaster or in a standard splint. There were differences of opinion as to how long immobilization should be continued in fixed hospitals, but there was general agreement that either passive or active motion should be instituted after the danger of suppurative arthritis had passed and as soon as the state of the soft-tissue wound permitted it. Joint injuries that were essentially compound fractures of the bones entering into the articulation were immobilized in the position least undesirable from the standpoint of future function, it being accepted that in such cases some residual limitation of motion was inevitable. Operation was not regarded as necessary in instances of perforating bullet wounds; in these cases it was assumed that bone damage was minimal.

In World War II, just as in World War I, joint resection was rather extensively practiced by French surgeons, who employed it, as in the earlier war, to forestall amputation due to infection in severely damaged joints, as well as in suppurative arthritis. Russian and German surgeons also employed resection of the joint, but the British seldom resorted to it.

GENERAL CONSIDERATIONS

It is surprising, in view of the extreme seriousness of wounds of the joints in military surgery, how few directions for their management were provided for United States Army medical officers. Technical manual Guides to Therapy for Medical Officers (TM 8-210), published 20 March 1942, merely stated that wounds of the joints should be treated as compound fractures. The item was even less useful than it might have been because the text was not indexed. Orthopedic Subjects,⁷ one of the Military Surgical Manuals published by the Subcommittee on Orthopedic Surgery of the Committee on Surgery, Division of Medical Sciences, National Research Council, contains less than half a page on the subject:

If the wound involves a joint, this should be opened widely at the time of the incision of the skin and fascia and the joint should be thoroughly explored. Loose fragments of

⁵ Jolly, D. W.: *Field Surgery in Total War*. New York: Paul B. Hoeber, Inc., 1941.

⁶ Trueta, J.: *Treatment of War Wounds and Fractures With Special Reference to the Closed Method as Used in the War in Spain*. New York: Paul B. Hoeber, Inc.

⁷ *Orthopedic Subjects*. Prepared and edited by the Subcommittee on Orthopedic Surgery of the Committee on Surgery of the Division of Medical Sciences of the National Research Council. *Military Surgical Manuals*, Philadelphia & London: W. B. Saunders Co., 1942.

bone and any foreign material present in the joint should be removed. Any soiled bone exposed in the wound should be excised. The joint may or may not be irrigated with physiologic salt solution, depending on the choice of the surgeon. In most instances it is possible to clean the joint adequately without irrigation. The wound should then be dried, the joint cavity should be sprinkled liberally with one of the sulfonamide drugs and the wound should be treated as has been described in the case of fractures not involving joints. The vaseline gauze packing should extend down to the joint cavity. In most instances the synovial membrane can be closed with fine catgut. In wounds which are not very recent, or which are in questionable condition, the joint should be left open. As a rule, no attempt should be made to suture the capsule or ligaments exposed in the wound and severed. The joint should be immobilized in a plaster-of-paris cast as described previously.

An accurate record of wounds of the various joints does not exist for World War II. This is chiefly because compound fractures adjacent to and involving the joints were so often present concurrently. When this happened, the injuries were likely to be recorded as fractures rather than as wounds of the joints. Certain corrections, of course, can be read into certain statistics. Thus a compound fracture of the femoral condyles necessarily involved the structures of the knee joint, just as a compound fracture of the head of the humerus necessarily involved the structures of the shoulder joint. These adjustments, however, were not possible when the level of the fracture was not stated, as it frequently was not, and in these circumstances the record of joint involvement was permanently lost.

There was never any question as to the potential seriousness of all wounds of the joints in World War II. Any damage, no matter how slight, had to be regarded as prejudicial, in some degree, to future function. The injuries varied from small penetrating depressions which carried the articular cartilage into the underlying cancellous bone to extensive compound comminuted fractures of the bone ends making up the joint. Often the damage amounted to complete destruction of all articular structures. Even if the damage was slight, suppurative arthritis was a possibility in every wound of a joint. At the best, its development invited ankylosis. At the worst, it endangered the survival of the extremity and sometimes the survival of the patient. Every injury of a joint had to be managed with the possibility of these consequences in mind.

Since the overwhelming majority of wounds of the joint were compound fractures of the bones entering into the articulation, the management of these wounds by United States Army surgeons in World War II, as might have been expected, went through the same process of evolution as has been described for the management of compound fractures. Since wounds of the knee joint are far and away the most important of these injuries, the development of a standard policy of management chiefly concerned them and can be most conveniently and logically described in connection with them. The management of wounds of the hip joint also introduced certain special considerations which are briefly described in a separate section.

WOUNDS OF THE KNEE JOINT

Since the knee joint and the hip joint are the major weight-bearing joints of the body, any injury to either joint is serious. A penetrating wound produced by a missile usually results in intra-articular damage. The trauma is usually sufficient to affect future function to some degree, and each wound is a potential instance of suppurative arthritis. Once suppurative arthritis is established, the infectious process often endangers both life and limb, and fusion of the joint is often the best that can be hoped for.

Frankau, who wrote the section on gunshot wounds of the joints in the official British history of World War I,⁸ confirmed these generalizations. In the first months of the war, he said, the results were "lamentable." The amputation rate for wounds of the knee joint not complicated by fractures was 60 percent. It rose to at least 80 percent when a concurrent fracture was present. The case fatality rate was always high, though, as methods of management improved, it fell to 8 percent. The amputation rate was also reduced; it fell from 25 percent in 1916 to 7 percent in 1917.

In view of the results in World War I, one can understand the point of view expressed in Buxton's⁹ report on 273 wounds of the knee joint treated in one fixed hospital during the second and third Libyan campaigns in World War II; namely, that an incidence of 34.8 percent for suppurative arthritis, an amputation rate of 4.4 percent, and a death rate of 1.8 percent could well be regarded as "excellent." Buxton attributed these results to the small size of the causative missiles in this series, as well as to the feasibility of early operation and the availability of systemic sulfonamide therapy. When, however, such results as these are fairly regarded as "excellent," it is easy to see why wounds of the knee joint should be classified among the most serious of all battle injuries.

The majority of wounds of the knee joint in World War II were caused by high-explosive shell fragments, including artillery and mortar shells, grenades, mines, and boobytraps. These missiles were responsible for 222 of the 271 wounds of the knee joint observed at the 45th General Hospital in the Mediterranean theater. Forty-two of the remaining forty-nine injuries were caused by bullet wounds, six were noncombat injuries which had occurred in traffic accidents, and one injury was incurred in an airplane crash.

Early Plans of Management (Before February 1944)

In the early months of United States participation in World War II, wounds of the knee joint were managed as the judgment and experience of the individual medical officer dictated, rather than by theaterwide policies. In

⁸ Frankau, C. F. S.: Gunshot Wounds of the Joints. *In* History of the Great War Based on Official Documents. Medical Services Surgery of the War, London: His Majesty's Stationery Office, 1922, vol. II, pp. 297-325.

⁹ Buxton, St. J. D.: Gunshot Wounds of the Knee Joint. *Lancet* 1:681-684, 20 May 1944.

the best treated cases, the plan of management included prompt, thorough debridement; through lavage of the joint cavity; the introduction of sulfonamide powder into the cavity; closure of the synovial membrane or capsule; and immobilization, usually in a long leg plaster cast. If initial surgery had been greatly delayed or if frank infection was present when the patient was first seen, closure of the synovial membrane was usually omitted, in an attempt to provide drainage. If the joint was severely damaged, the wound was usually extended and left open for drainage, but at this period in the war extensive intra-articular debridement was not performed. Primary resection as practiced by the French in this type of injury was not carried out, even when the joint had been destroyed. Although this program of management was extremely conservative, few secondary amputations seem to have been necessary.

Even in the early days of United States participation in World War II, the importance and desirability of complete closure of the joint were fully established, though the practice was not extended to infected cases. Once the joint was closed, the intra-articular cartilage was protected, the hazard of secondary intra-articular infection was obviated, and better subsequent function could be hoped for. It was also thought, though no direct proof existed, that closure of the joint permitted the presumptive bactericidal properties of the synovial fluid to act more effectively.

When the casualty reached a fixed hospital, the plaster was removed; the wound was dressed and again left open for drainage; and immobilization, usually by plaster, was reinstated. It was not until the principles of reparative surgery had become firmly established that it became customary to suture the wounds of the soft part at the second operation, sometime between the 5th and 10th days after wounding, as surgical limitations permitted.

The duration of immobilization varied with the extent of bone damage. When it was not extensive, passive and active motion was instituted as promptly as it was thought to be safe in the special case. The Willems principle of immediate motion was almost never used. The feeling was that the advantages of a few days of additional immobilization and rest for the part would expedite wound healing and that the advantages of prompt wound healing would outweigh any advantages likely to be derived from early forced active motion.

Complications were infrequent when damage to the joint was minimal or even moderate, especially in joints without cartilaginous or bony damage. Even in these favorable cases, however, it was noted at the general hospitals that, when closure of the synovial membrane had been omitted, healing was frequently slow and there was more impairment of joint function than might have been predicted from the degree of initial damage. In other cases of minimal or moderate damage, prolonged infection, with slow destruction of the joint, sometimes occurred. In such cases, though the joint was doomed, open drainage usually prevented the development of toxemia and systemic sepsis. Precise figures are not available, but it was recognized that cases of

this sort were not infrequent, both in overseas hospitals and in hospitals in the United States.

On the whole, joints operated upon early and thoroughly, with closure of the synovial membrane and institution of immobilization, were usually free from infection (fig. 70). The term "early," however, was relative. The timelag from wounding to initial surgery usually exceeded 12 hours. In one typical series of 384 wounds of the knee joint, it averaged 16.5 hours. When operation was done so long after wounding, forward-area surgeons in the early months of the war, fearful of the consequences of infection in a closed joint, frequently assumed that infection might already be present and therefore left the joint open for drainage. Observations at the hospitals in the rear showed that patients who were treated in this way sometimes did well but that in many cases infection was prolonged and the joint was completely destroyed. These could not be regarded as satisfactory results, even though few amputations were necessary and loss of life was negligible.

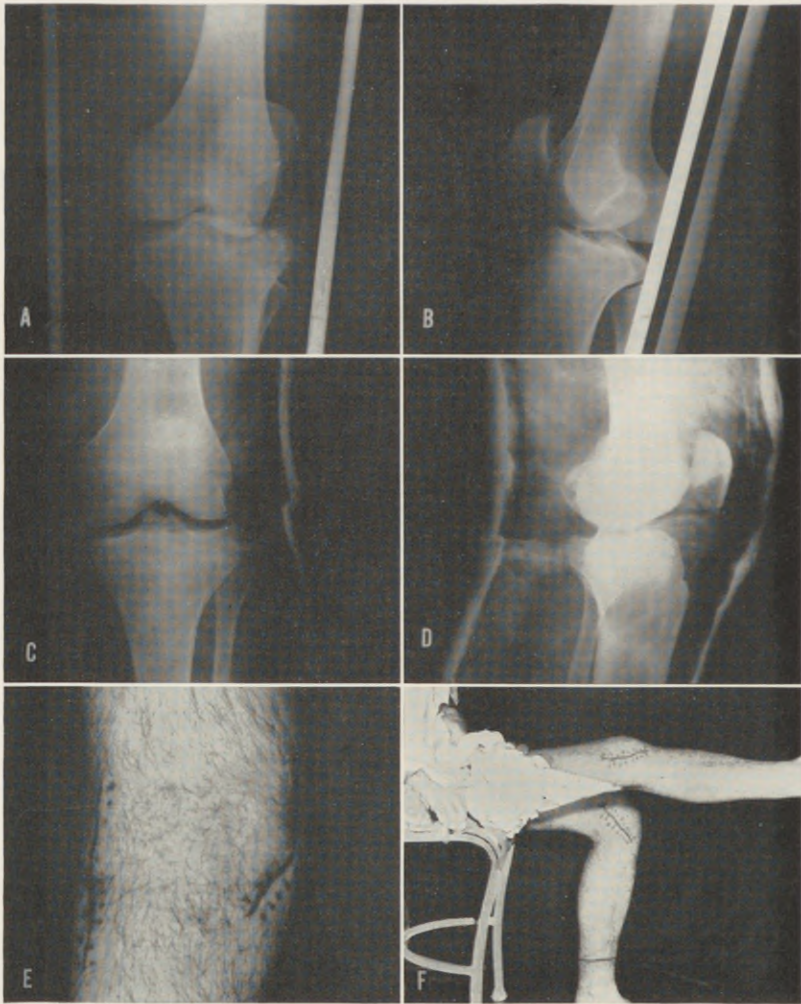The Formative Stages in Development of Standard Concepts of Management (March-April 1944)

In the early spring of 1944, there was a sharp rise in the incidence of suppurative arthritis following wounds of the knee joint treated in several of the general hospitals in the Naples area. It was possible to trace the cause, at least in part, to a wave of surgical conservatism among forward-area surgeons at the Anzio beachhead. Part of this conservatism was apparently deliberate. Part of it was to be explained by the extremely difficult combat conditions under which forward surgeons were then working. Whatever the explanation, the results were the same. In many instances, surgical exposure of the joint was inadequate, intra-articular debridement was incomplete, and infection in the joint was the consequence.

The increased incidence of suppurative arthritis in the group of casualties just described focused particular attention upon wounds of the knee joint and their possible complications. Shortly afterward, as part of the early formative stages of the program for the adjuvant use of penicillin in the management of battle wounds, a number of wounds of the knee joint with potential infection or early established infection were studied in several general hospitals in the Naples area. All the wounds had been sustained from a few days to a few weeks earlier. Observations made on these 35 cases brought out the following facts:

1. No infection had occurred in cases which had been treated by complete initial surgery, closure of the synovial membrane or capsule, and adequate immobilization.

2. Suppurative arthritis of varying degrees of severity, with prolonged drainage and slow destruction of the articular surfaces, was observed in several cases in which intra-articular damage at wounding had been only minimal to moderate but in which excisional surgery had been inadequate and in which



AFIP CA-45-872

FIGURE 70.—Staged management of wound of left knee joint. A and B. Anteroposterior and lateral roentgenograms made in evacuation hospital before initial surgery, showing damage to lateral condyle of tibia. At initial surgery, the knee joint was opened medially and laterally and thorough debridement was performed. The synovial membrane and capsule were closed, penicillin solution was instilled into the joint, and immobilization was provided by a single hip spica. C and D. Anteroposterior and lateral roentgenograms made in fixed hospital 6 days later. The hip spica used as transportation splinting is still in place. Aspiration of the joint at this time showed no evidence of infection. The soft-part wounds were therefore sutured, and immobilization was continued. E. Appearance of healed wounds 2 weeks after reparative surgery. Because the wounds healed promptly, active and passive motion could be instituted promptly. F. Range of flexion and extension (90°) 5 weeks after wounding. The application of the principles of staged surgical management to this injury prevented wound infection and produced a highly satisfactory functional result.

the joints had been left open for drainage. The reaction closely resembled that observed in joints destroyed by the missile.

3. Compound comminuted injuries of the patella were particularly likely to be followed by infection.

4. In each of 15 cases complicated by infection of varying degrees of severity, unexcised, devitalized, traumatized intra-articular cartilage was present.

Nineteen patients with wounds of the knee joint (all then available) were managed by an aggressive regimen of surgery, blood transfusions, and penicillin at the 21st, 23d, and 45th General Hospitals in the medical center at Naples and at the 17th General Hospital several miles away, as follows:

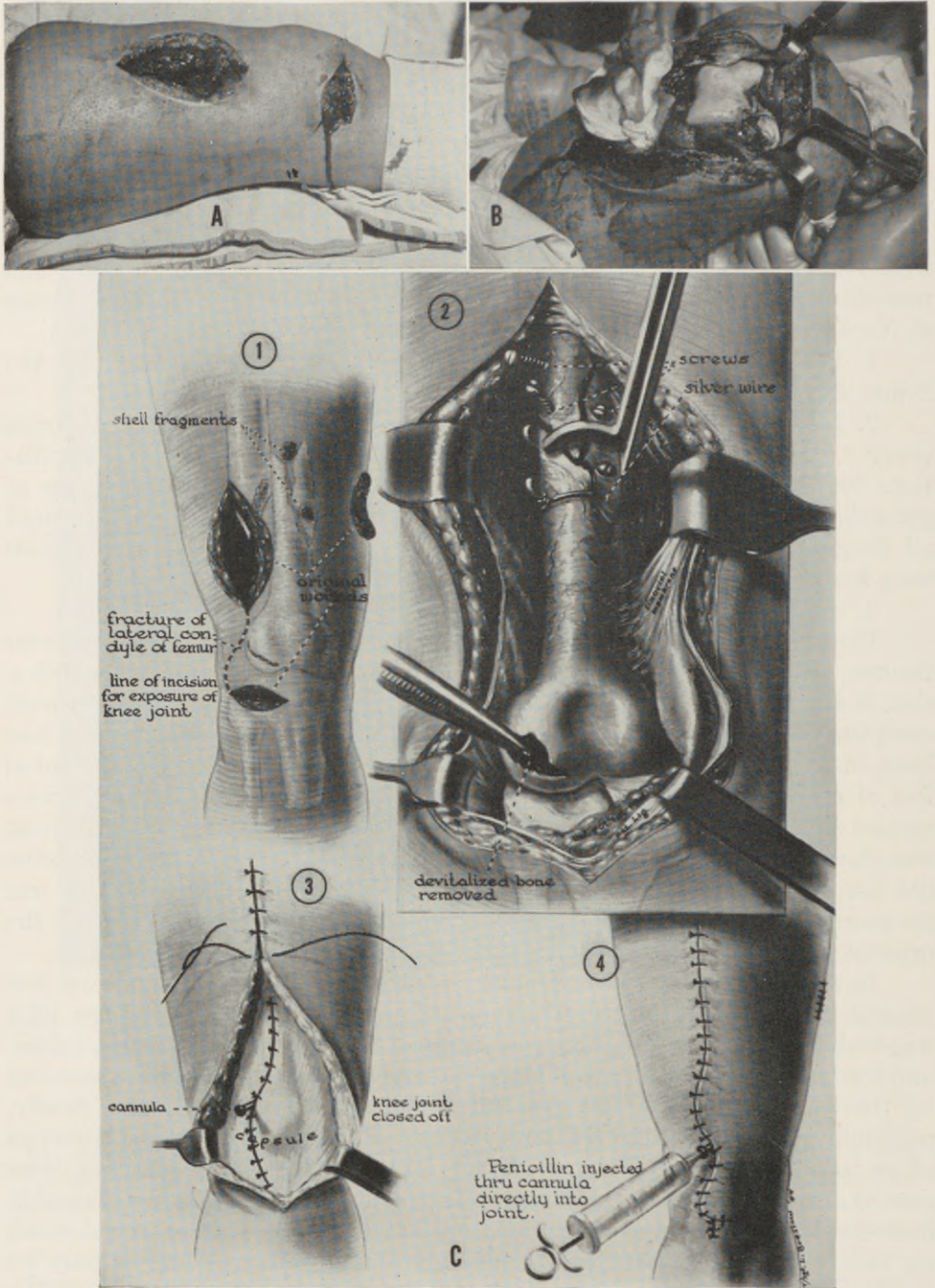
1. Blood transfusions were given in amounts sufficient to maintain the hematocrit level at 40 or over.

2. Penicillin was given intramuscularly in doses of 25,000 to 50,000 units every 3 hours. Systemic administration was supplemented by local instillations into the knee joint in amounts of 5,000 units per cubic centimeter of physiologic salt solution. Systemic administration was always continued until all danger of continuing infection was past and, as a rule, until the wounds were healed.

3. Surgically, these 19 cases were managed as follows:

In eight cases, in which there was roentgenologic evidence of intra-articular trauma, the knee joint was explored. There was no definite evidence of infection in any of these cases, but exposure at initial wound surgery had not been complete and exploration was undertaken to be certain that debridement had been adequate. In four cases, it had been. In the other four cases, potential foci of infection, in the form of devitalized areas of articular cartilage, were excised (fig. 71). The joint cavity was then thoroughly irrigated, the joint was closed, and penicillin was instilled into the cavity. Suppurative arthritis did not ensue in any of these eight cases, and in each case joint function was no more greatly affected than it had already been by the trauma of the original wound.

In six wounds, in which definite, established suppurative arthritis was present but in which joint destruction had not yet occurred, the knee joint was widely exposed. The joint was cleansed of all devitalized tissue, debris, and foreign material, after which blood clot and purulent exudate were removed by thorough irrigation. The synovial membrane was sutured, and, finally, penicillin was instilled into the joint cavity. For the next week, at intervals of 24 to 48 hours, aspiration, irrigation, and reinstallation of penicillin were carried out. Attempts at aspiration were usually fruitless because remarkably little fluid accumulated between treatments. Infection was controlled in all six cases, and, again, the ultimate function of the joint was limited only by the damage caused by the missile at the time of wounding (figs. 72, 73, and 74).



AFIP C-44-265, CA-44-322

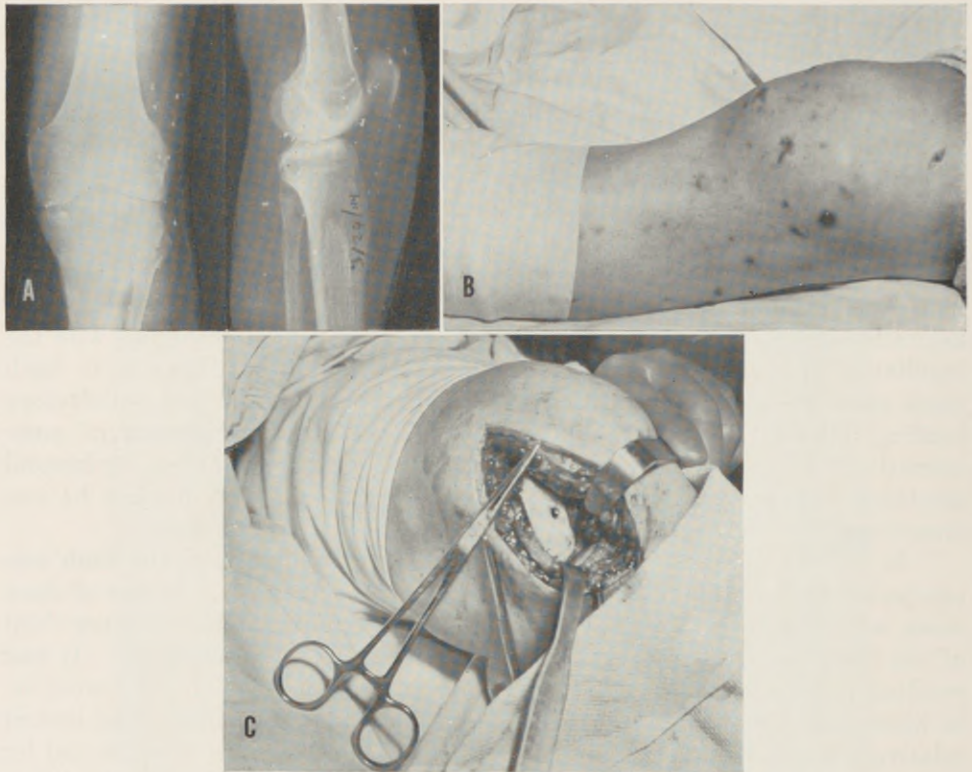
FIGURE 71. (See opposite page for legends.)

In two cases, in which subacute infectious processes had been present for several weeks, the knee joint was reopened. A comminuted fracture of the patella was present in one of these cases. In the other, purulent exudate was dripping into the joint cavity from an infected fracture of the lower third of the femur. In both cases, necrosis of the articular cartilage had been caused by the infection and was not the direct consequence of wounding. All necrotic areas were curetted, and the edges of the cartilage left in situ were trimmed free of loose tags. The menisci, which were devitalized and friable, were also removed. The patella was resected in the first of the cases. After the cavity had been thoroughly irrigated, the synovial membrane was closed, and the aspiration-instillation regimen just described was instituted, beginning with the instillation of penicillin solution on the operating table. Results in both these cases were good. Infection was promptly controlled, and satisfactory healing followed delayed wound closure. The desirable program of post-operative mobilization was hampered in both cases by the complicating femoral fractures, but each of these patients had 10° to 20° of motion when he was transferred to the Zone of Interior, as well as at a later examination.

In the three remaining cases, infection which endangered the limb was eradicated by resection of the knee joint (figs. 75, 76, and 77). In one of these cases, which was associated with a contralateral amputation in the upper third of the thigh, sepsis was severe enough to endanger the patient's life. It had resulted from infection of a compound fracture of the medial tibial condyle, in which the line of fracture extended into the joint. The injury had looked relatively innocent but was poorly debrided. All three cases were treated by excision of the infected, necrotic bone and cartilage; resection of the joint; and staged procedures directed at wound healing. The infection was controlled, the wounds healed satisfactorily, and bony fusion was progressing when the patients were evacuated from the theater.

4. The joint was immobilized after operation by a single plaster spica or a Tobruk splint. Movement was permitted when healing was progressing satisfactorily and it was thought that all danger of a flareup of infection was past.

FIGURE 71.—Staged management of penetrating wound of right knee joint associated with comminuted fracture of lower third of femur. A. Wounds of knee and lower third of thigh observed in operating room just before reparative surgery. The small size of the wound of the knee joint makes it clear that intra-articular surgery has not been adequate. B. Extensively damaged medial condyle of femur seen on adequate exposure of joint. All devitalized articular cartilage was removed through this wide arthrotomy incision. The incision was extended proximally, and the comminuted fracture of the femur was fixed with multiple screws. C. Steps of reparative surgery. The aggressive surgical attack on this injury, which had been inadequately treated at initial wound surgery, undoubtedly forestalled suppurative arthritis and was followed by prompt wound healing. The femur united firmly and in perfect condition.



AFIP C-44-292

FIGURE 72.—Management of early established suppurative arthritis superimposed on multiple penetrating wounds of left knee. For reasons which are not clear, possibly because of the multiplicity of the penetrating wounds, this knee joint was not explored and debrided at initial surgery. A. Anteroposterior and lateral roentgenograms made in fixed hospital 10 days after wounding. B. Appearance of knee on same date. Note the bulging of the knee and the multiple wounds, from all of which pus oozed. C. Medial arthrotomy incision through which several areas of damaged articular cartilage were excised, together with several metallic foreign bodies embedded in the condyles of the femur and the partially devitalized medial meniscus. Areas of devitalized articular cartilage and the friable lateral meniscus were removed through a lateral arthrotomy incision. After thorough irrigation of pus and exudate, the synovial membrane was sutured in each incision, and the joint was filled with penicillin. A hip spica was applied for immobilization. The synovial fluid was aspirated, and the joint was irrigated and filled with penicillin daily during the next 5 days, through a window in the cast. Systemic and local signs of infection rapidly subsided. Skin closure of each wound was carried out 12 days after the arthrotomy incisions were made. All signs of infection disappeared, and the wounds healed promptly. When the patient was evacuated to the Zone of Interior 5½ weeks after wounding, the range of motion was 30° from full extension. He was furnished with a removable splint for use at night, to maintain full extension of the leg at the knee as a precaution against flexion contracture.

Standard Plans of Management (After May 1944)

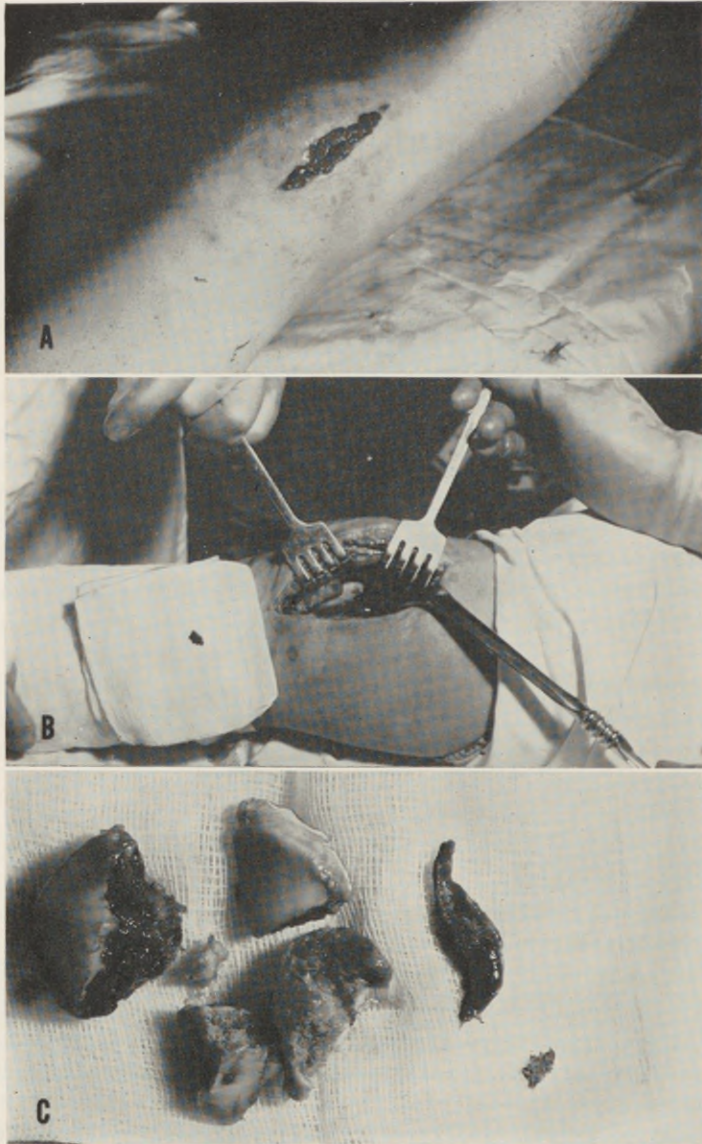In the first months of the Mediterranean theater, as already noted, there was no theaterwide policy for wounds of the knee joint; each surgeon managed them in the light of his individual experience and training. As might have been expected, however, the differences between methods were more in details than in the basic pattern, which was generally as has just been described. The results accomplished during this early period seemed susceptible of improvement, particularly in the cases in which infection was present. That results could be improved was evident in the 19 injuries of the knee joint in which penicillin was tested in the Mediterranean theater and which were observed at about the time the reparative-surgery program for wounds of the soft tissues was becoming theaterwide. It was natural that this plan should be extended to wounds of the knee joint and that it should eventually become the standard plan of management for all wounds in this area, whether penetrating or perforating and whether or not they were complicated by infection. At the end of World War II, the surgical management of wounds of the knee joint had for all practical purposes come back to the concept enunciated by Pool in World War I;¹⁰ that is, thorough debridement and immediate closure of the joint wound. The contribution of World War II was the extension of this program to the infected knee joint.

Initial wound surgery.—Wounds of the knee joint, which were priority-two injuries, were treated at initial wound surgery by the same regimen as all other wounds, with such modifications as the location and character of the injury required. It was essential, for instance, to perform the operation on an operating table which could be broken at the knee; satisfactory exposure was otherwise difficult. Circumferential draping was used. A tourniquet was often applied to secure a dry surgical field.

The incision and its extent were determined by the necessities of the special case. A separate arthrotomy incision was frequently better than approach through the battle wound. It was essential that the excisional procedure should include the removal of all foreign bodies, including loose bone chips; damaged menisci, and loose, fragmented and devitalized cartilage. Defects in the condyles were trimmed evenly. It was usually the wisest plan to excise a comminuted patella.

After thorough irrigation of the joint cavity, the synovial membrane, with the capsule, if possible, was sutured, and penicillin solution was instilled into the cavity. When loss of soft tissue precluded suture of the membrane or capsule, flaps of fascia or skin were rotated to secure the desired coverage. The joint was left open only when the extent of the damage made return of any joint function obviously impossible. In cases of this kind, it was always best to excise the remaining cartilage, which, since it was poorly nourished, avascular,

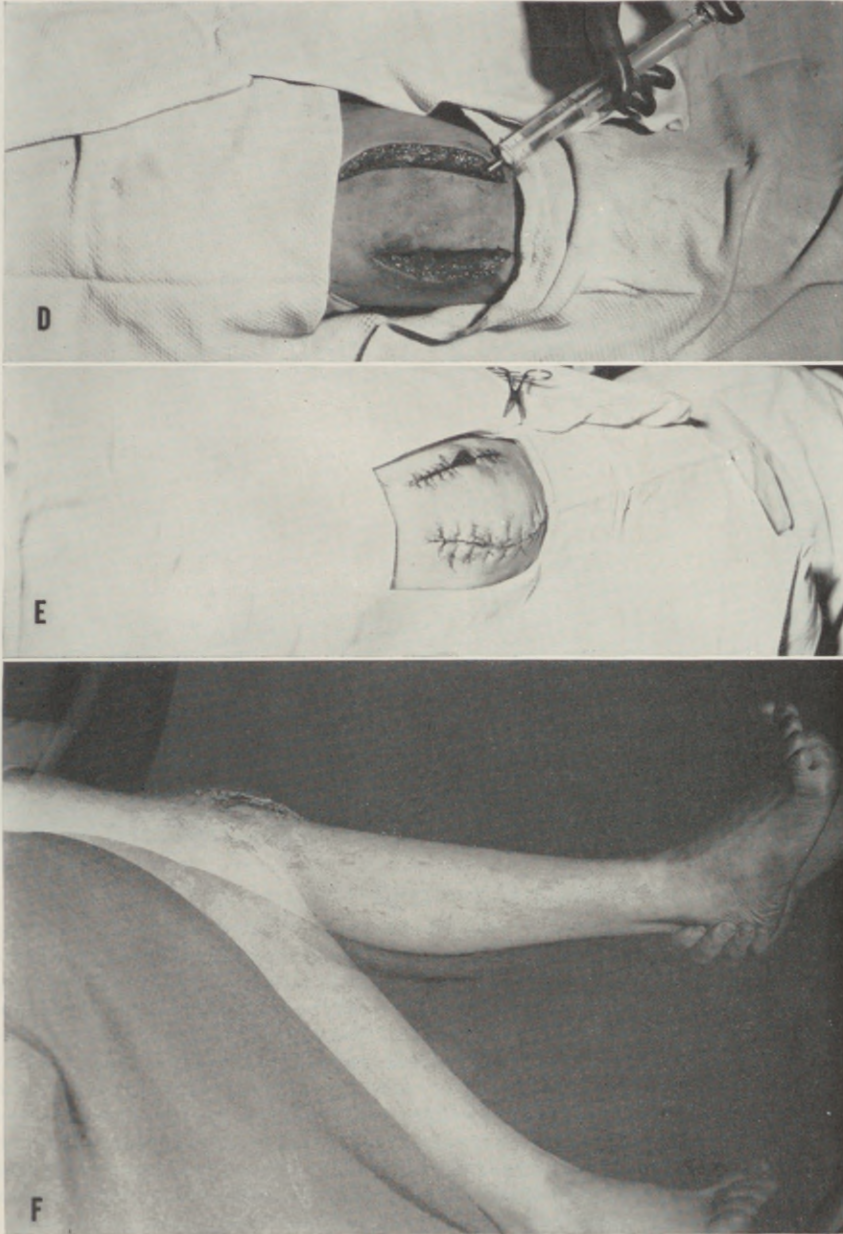
¹⁰ See footnote 2, p. 211.



AFIP Fd-448

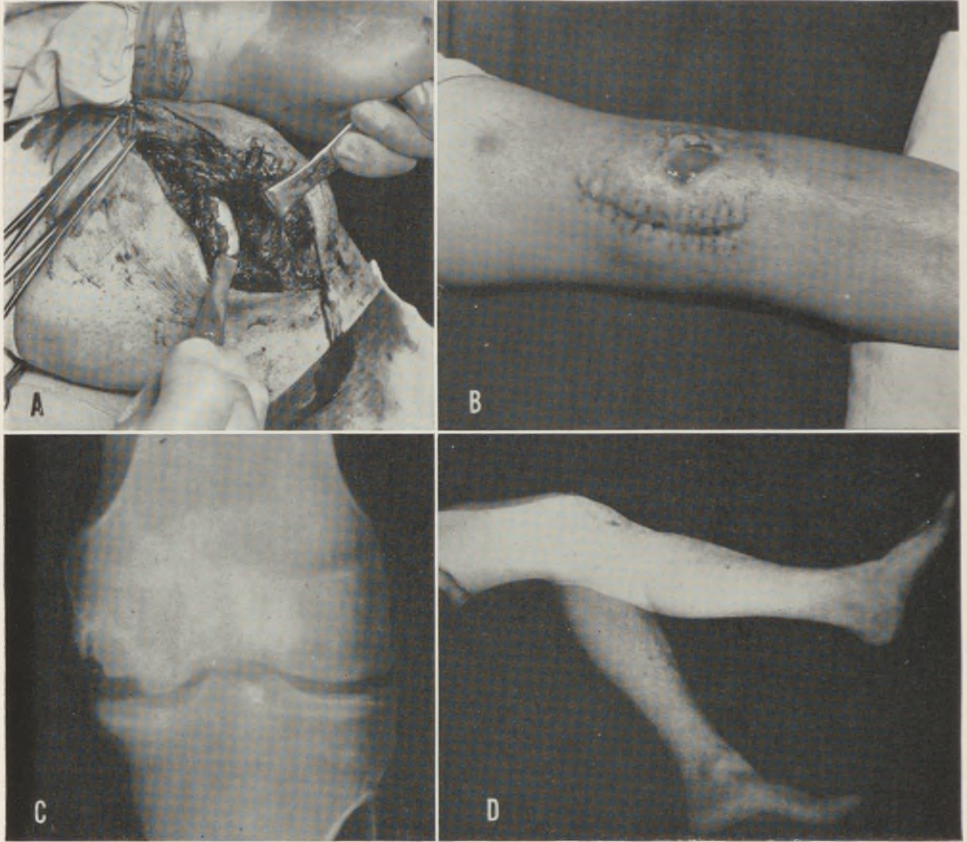
FIGURE 73.—Management of early established suppurative arthritis following wound of knee joint and comminuted fracture of patella. Ten hours after injury, wound was opened and a foreign body removed; joint was irrigated, capsule closed, penicillin instilled into joint and given systemically; immobilization by long leg cast. Initial debridement had been incomplete. Signs and symptoms of suppuration developed and persisted after patient was admitted to fixed hospital a week later, in spite of continuation of penicillin. A. Swollen joint, granulating wound, and draining pus, 15 days after wounding. B. Medial arthrotomy incision, with inflamed synovial membrane and partially necrotic cartilage of comminuted patella visualized. Bit of cloth shown on gauze sponge was removed from joint, together with coagulated fibrinous exudate in quadriceps pouch. Severely comminuted fragments

(Continued on opposite page.)



AFIP Fd-448

of patella were excised. C. Fragments of patella, some fibrinous exudate, and bit of cloth removed from joint. D. Instillation of penicillin into joint, through arthrotomy incision, after closure of synovial membrane and capsule. Old wound, which had broken open as result of infection, was excised; capsule was closed. E. Wounds, after suture, through window in cast, 6 days later. F. Degree of active extension and flexion of leg at knee 3 weeks later. Quadriceps power is sufficient to extend knee. Hand supports foot for photograph. Wounds healed promptly.



AFIP CA-44-523, C-44-454, 92494, 92493

FIGURE 74.—Management of suppurative arthritis superimposed on moderately severe high-explosive shell fragment wound of left knee. At initial surgery 7 hours later, the knee joint was opened, and a foreign body embedded in the articular surface of the medial femoral condyle was removed. The joint capsule was sutured after irrigation of the cavity, and penicillin was instilled. In the fixed hospital 5 days later, local and systemic signs of suppurative arthritis were observed. The joint was aspirated and irrigated on two occasions, and penicillin solution was instilled into it. Four days later the temperature was 101° F.; the knee was swollen, boggy, and tender, and a seropurulent discharge exuded; maggots were crawling in the wound. A. Exposure of joint through proximal extension of old wound. Note intense hyperemia of synovial membrane and edge of damaged articular cartilage. Maggots were present in the joint cavity, which was thoroughly cleansed by irrigation. A piece of woolen cloth was removed, together with the devitalized area of articular cartilage, about an inch in diameter, which lay beneath it and which had been depressed into the condylar defect. The defect was trimmed evenly. The medial meniscus, although dull in

(Continued on opposite page.)

and traumatized, was a potential focus of infection. The remaining joint injury was then really only a compound fracture.

The same principles of exposure and debridement were employed in indirect injuries of the joint produced by fractures extending into the joint, to insure that no debris, loose fragments of bone, or blood clots were left in the cavity.

Immobilization was accomplished by a single hip spica or a Tobruk splint, with the knee in 10° to 15° flexion. Systemic penicillin therapy and the aspiration-instillation regimen of joint management were instituted and were continued as long as indications existed. Postoperative instillation was carried out with a large needle, through a window in the cast.

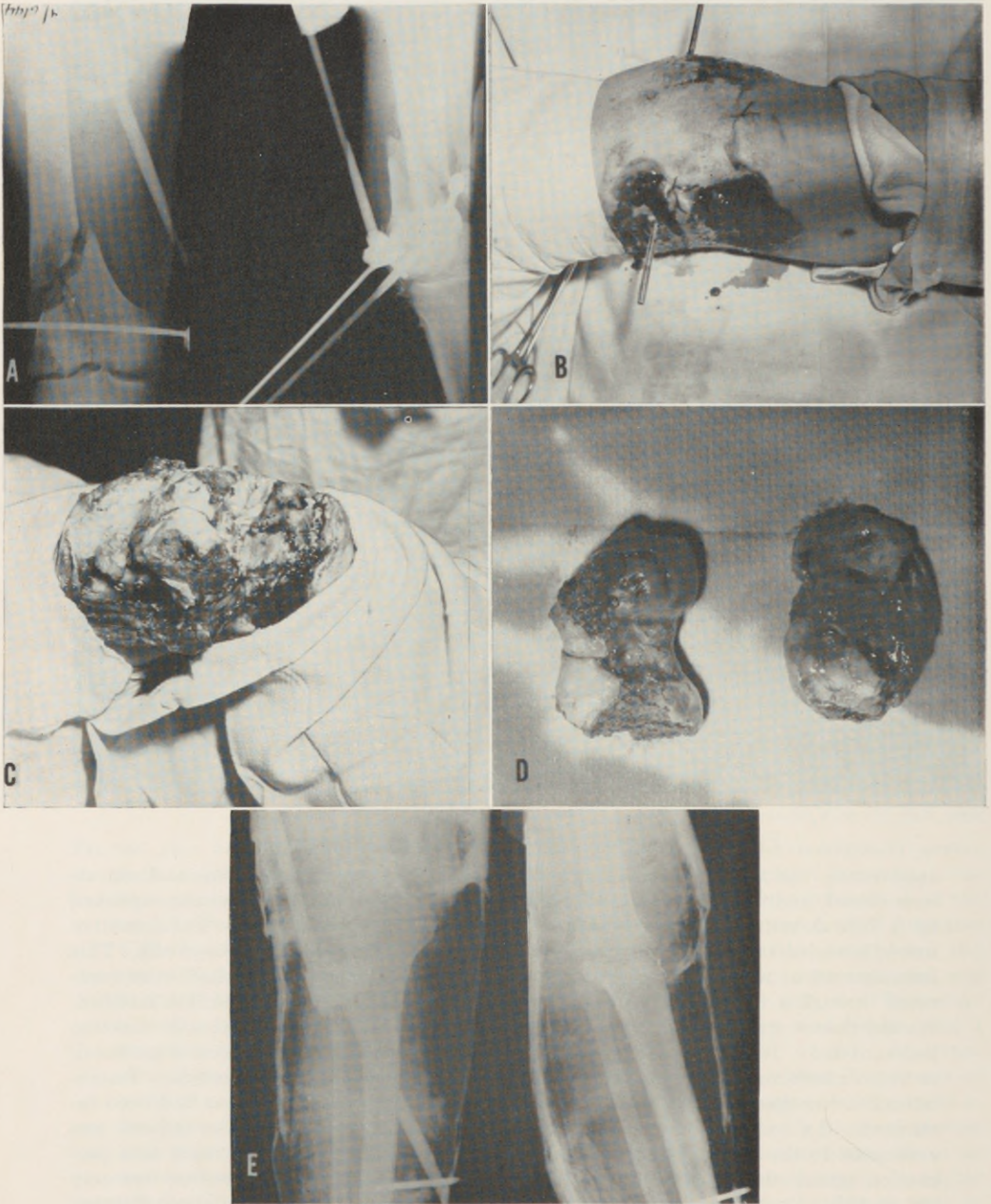
Reparative wound surgery.—Reparative surgery was undertaken at the general hospital 4 to 6 days after wounding. At this time, the cavity was again aspirated and irrigated, and penicillin was reinstilled, but the joint was not reopened unless there was reasonable doubt concerning the adequacy of initial wound surgery. If there was doubt, exploration was undertaken, as a precaution against the development of suppurative arthritis, and such additional excisional surgery as proved necessary was performed (fig. 71). The joint was well irrigated before it was closed, and skin closure was effected by the usual technique.

If for any reason reparative surgery could not be performed promptly after the patient's arrival at the general hospital, the aspiration-instillation routine was carried out until operation could be performed.

Immobilization was continued for 10 to 14 days after delayed primary suture. Then active mobilization of the joint was instituted, usually with the patient in balanced suspension in an Army half-ring leg splint, with Pierson attachment. Motion was progressively increased from the position of full extension, to avoid flexion contracture.

FIGURE 74. (*Legend continued from opposite page.*)

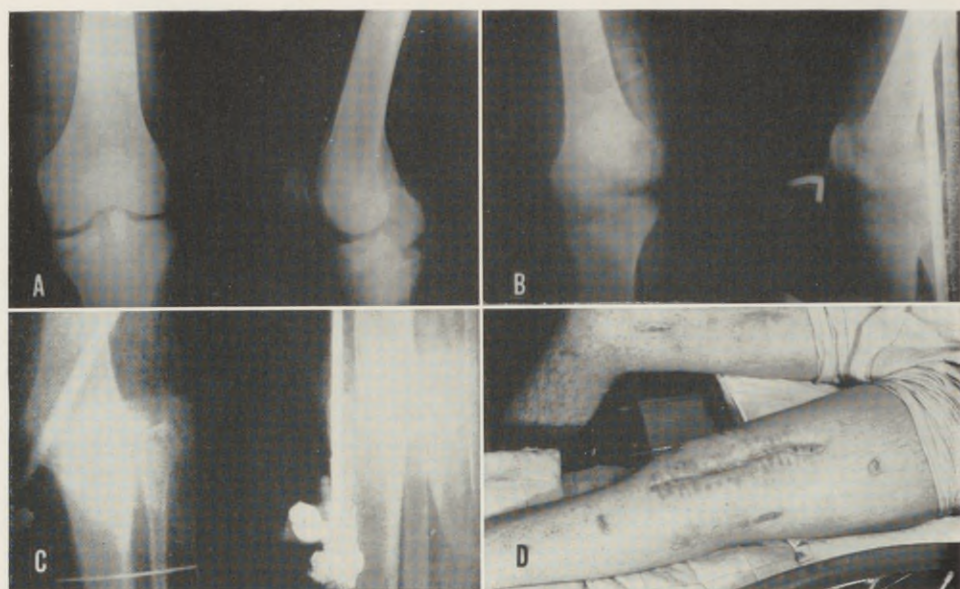
appearance, was not friable and was left in situ. The synovial membrane and capsule were closed, and the joint was filled with penicillin. Immobilization was accomplished by a Tobruk splint. B. Appearance of region of joint 3 weeks later. The operative wound is healed, but there is an unhealed area of partial loss of skin over the patella. This loss occurred at wounding. For 2 days after operation, synovial fluid had been aspirated through a window in the cast, the joint cavity irrigated, and penicillin instilled. Wound closure was possible 5 days after operation, by which time all signs of infection had subsided. It was necessary, however, to leave a small gap in the center unclosed, to avoid excessive tension on the skin margins of the lateral surgical incision. Immobilization was discontinued 2 weeks later; meantime, quadriceps exercises had been instituted. Six weeks after the operation for suppurative arthritis, the patient was evacuated to the Zone of Interior with removable splinting for use at night as a precaution against flexion contracture. At this time the range of active motion was only 10° to 15° . C. Anteroposterior roentgenogram made a year after wounding, showing extent of damage to medial condyle of femur. D. Range of active motion in knee a year later. Complete extension is possible but is not shown in this photograph.



AFIP C-44-298

FIGURE 75. (See opposite page for legends.)

FIGURE 75.—Management of suppurative arthritis of right knee joint, superimposed on damage resulting from severe perforating wounds. Injury included compound comminuted supracondylar and condylar fractures of femur and patella, with laceration of patellar tendon. Resection of joint. At initial surgery, it was recognized that the joint had been partially destroyed, and the comminuted patella was excised. In an endeavor to stabilize the condylar fragments as much as possible, a Steinmann pin was passed through them and brought out through the medial and lateral wounds, though the use of skeletal fixation in forward areas was not a recommended policy. When the patient was received at the general hospital on the 11th day after wounding, the joint and fracture site were bathed in purulent exudate. Efforts to control the suppurative process were not successful. A. Anteroposterior and lateral roentgenograms made just before reparative surgery. B. Appearance of knee just before reparative surgery, 3 weeks after wounding. C. Exposure of joint. The degree of destruction is such that restoration of function is obviously impossible. The Steinmann pin was removed, and the fracture site in the lower end of the femur was reduced and fixed by 2 screws. The almost totally destroyed condyles of the femur and the proximal end of the tibia were then excised. An external skeletal-fixation apparatus was applied to the extremity to maintain apposition of the femur and tibia. The operative wound was partly closed, so as to cover all exposed bone, and rubber-tissue drains to the dead space were inserted. A single hip spica was applied, incorporating the external skeletal-fixation apparatus. D. Articular surfaces of resected femur and tibia. Note destruction of articular cartilage. E. Anteroposterior and oblique roentgenograms of resected knee joint in plaster cast. Note wire suture used to help maintain apposition of fragments. Nine days after resection, the wounds were clean, but the edges were not suitable for suture. The wound margins were trimmed back to healthy tissue, and old granulation tissue was excised. Five days later, at a third operative procedure, a small protruding portion of the external condyle was chiseled away, and the wounds were closed. Wound healing was obtained except for a persistent small sinus to the region of the internally fixed fracture. This man was evacuated to the Zone of Interior 6 weeks after operative resection of the infected knee joint. When he was observed several months later by the consultant in orthopedic surgery for the Mediterranean theater, the fracture had united, and the knee joint was fused. The wounds were well healed except for the small sinus just mentioned. When the fixation screws and sequestrum to which the sinus led were removed, prompt healing occurred. In this case, a knee joint hopelessly destroyed by the initial injury and superimposed suppurative arthritis was managed by early resection, and the optimal result which could be expected for such an injury was achieved within a minimum period of time. Internal fixation of the fracture of the distal end of the femur was an essential part of the surgery; for technical reasons, stabilization of the fracture was necessary before resection could be performed. External skeletal fixation, while useful in maintaining stability during the staged surgical procedure, was insufficient in itself for adequate immobilization, so after each operation the apparatus was incorporated in a single hip spica.



U. S. Army photos

FIGURE 76.—Management of severe suppurative arthritis superimposed on moderately severe damage to articular cartilage of left knee joint. Compound comminuted fracture of middle third of right femur. Resection of left knee joint. At initial surgery, high-explosive shell fragments were removed from the joint, which was irrigated and closed. Penicillin solution was instilled, and penicillin was given systemically. A hip spica was used for immobilization. At the fixed hospital, the right femur was placed in skeletal traction after the compounding wounds were closed. Aspirations, irrigations, and re-institutions of penicillin, the correct routine for the management of such wounds in a fixed hospital, were not instituted, and an infectious process developed and continued until the patient was extremely ill and the knee joint was grossly infected. A. Anteroposterior and lateral roentgenograms before initial surgery. Size and location of foreign bodies indicate considerable trauma to the articular cartilage. B. Anteroposterior and lateral roentgenograms 2 months after wounding, showing ravages of infectious process in joint. After proper preoperative preparation, the knee joint was resected. The resected surfaces were stabilized in reduction by the use of external skeletal-fixation apparatus, over which a single hip spica was applied. All wounds were left open for drainage but were closed 2 weeks later. C. Anteroposterior and lateral roentgenograms of resected knee joint, showing incomplete bony fusion about 2 months later. The bone destruction by the infectious process in this instance amounted to 3 inches and can be attributed not only to incomplete initial surgery but to failure to institute the proper regimen promptly in the fixed hospital when infection became evident. Re-arthrotomy should have been done at once. D. Healed wound several months later in the Zone of Interior.

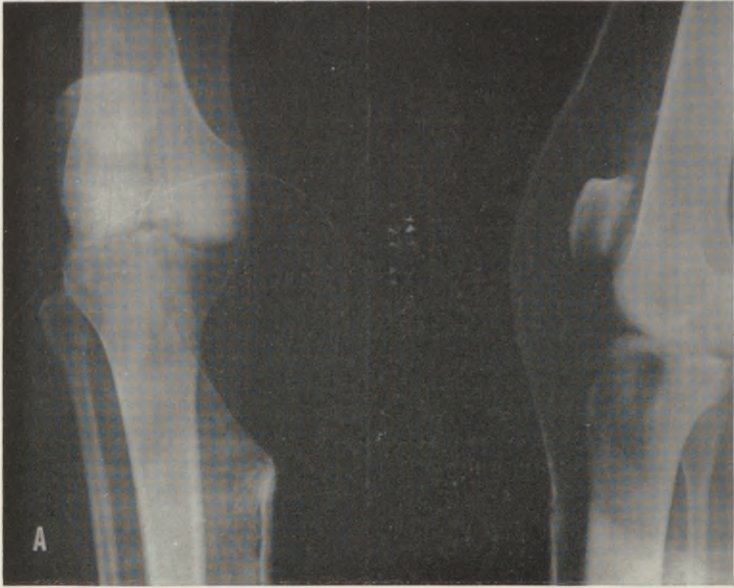
Management of infected knee joints.—The signs and symptoms of impending or established infection within the joint were chiefly pain, swelling, fever, and malaise. In the occasional case, if the manifestations were slight and if it appeared that initial wound surgery had been adequate, the aspiration-instillation routine with penicillin solution was carried out for a day or two, in the hope of aborting the infection. If the attempt was unsuccessful, no further time was lost. The joint was opened widely, was thoroughly cleansed of dead tissue and blood clot, was completely closed, and was filled with penicillin before it was immobilized (figs. 72, 73, and 74). Only when hope of a functioning joint had been entirely abandoned was the arthrotomy wound left open for drainage. The edges of the skin wound were freshened at this time, but closure was delayed until 5 or 6 days later. The usual postoperative regimen, including instillations of penicillin solution, was instituted.

Resection of the knee joint.—Resection (figs. 75, 76, and 77) was limited to joints hopelessly destroyed either by the initial trauma or by infection. If it was performed on the indication of joint destruction, it was preferably carried out at the evacuation hospital, with the objective of preventing chronic infection and promoting wound healing. Resection for infection was occasionally necessary in a forward hospital, but the necessity for it on this indication more often became evident in fixed hospitals. The amount of bone excised at operation and the resultant shortening of the limb were predetermined by the extent of bone loss and the degree of destruction inherent in the trauma or the infectious process. Because of the shortening which resulted from the operation, the resected surfaces were designed to conform in extension rather than in slight flexion.

Results of the Reparative-Surgery Program

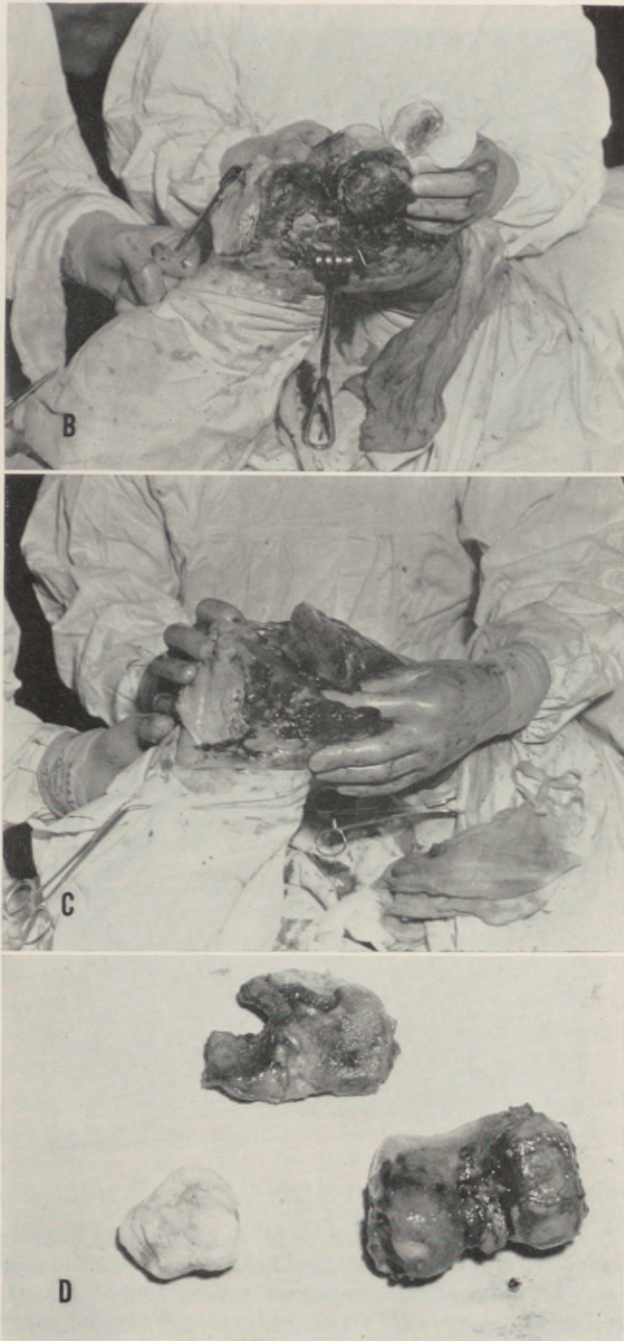The reparative-surgery program for wounds of the knee joint had its first theaterwide application in May 1944, with the beginning of the Cassino-Rome campaign. Its results were immediately apparent. The incidence of wound infection in wounds of the knee joint dropped sharply. If infection was already present when patients were received in general hospitals, appropriate surgery and intensive postoperative care almost always controlled the process. A functioning joint, limited only by the damage done at wounding, was the usual result. Chronic infection seldom occurred except in joints hopelessly destroyed by trauma. For all practical purposes, the chief problem of wounds of the knee joint had been solved. The surveys described below furnished data to substantiate these conclusions.

Disposition-board proceedings.—An examination of disposition-board proceedings for 1944, on file in the Office of the Surgeon, Mediterranean Theater of Operations, showed that in none of the 1,073 amputations performed for all causes had the operation been required for infection or sepsis following a properly managed wound of the knee joint (fig. 71).



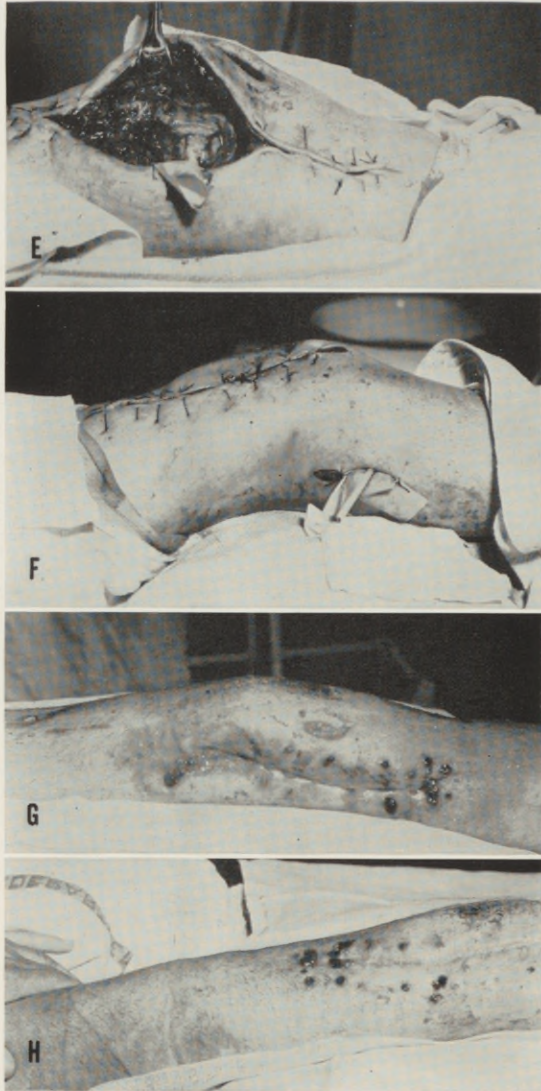
AFIP C-44-236

FIGURE 77.—Management of long-standing suppurative arthritis of right knee joint superimposed on penetrating wound which damaged proximal end of tibia. Radical resection of joint. The left lower extremity had been amputated traumatically in the middle third of the thigh by the same shell explosion that caused the injury to the right knee. Forty hours after injury, the traumatic amputation was completed by the open circular method and other wounds were debrided, but little was done to the penetrating wound compounding the injury of the knee joint. After the patient was admitted to the fixed hospital 14 days later, signs and symptoms of sepsis were constant, there being no response to bilateral parapatellar incisions, penicillin therapy, blood transfusions, and immobilization. Pus extended up the fascial planes of the thigh, and incision and drainage were necessary. A. Anteroposterior and lateral roentgenograms 10 weeks after injury, showing complete destruction of right knee joint. At this time, the patient was quite toxic, temperature elevations to 102° and 103° F. occurred daily, and amputation was seriously considered as a lifesaving measure. B. Interior of knee joint after exposure at operation 76 days after wounding through longitudinal incision extended proximally to drain another abscess in the thigh. The patella, which has been excised, is held beside the destroyed femoral condyle for demonstration purposes. All articular surfaces in the joint were found totally destroyed by the septic process. The healthy ends of the femur and tibia left after excision were held in approximation by a suture of stainless-steel wire placed anteriorly. Old wound edges were excised, but closure was not done. A hip spica provided postoperative immobilization. C. Resected joint. Shortening was of no consequence in this case because the opposite leg was already amputated. D. Dead, infected bone and cartilage excised from joint.



AFIP C-44-236

FIGURE 77. (See opposite page for legends.)



AFIP C-44-259. C-44-329

FIGURE 77—Continued. E. Partial closure of medial wound, with drainage, 6 days after first operation, after evident control of septic process. F. Closure of lateral wound at same operation. Drainage of abscess of calf. The depths of each wound were thoroughly irrigated before suture. G and H. Healed medial and lateral wounds 6 weeks later. Healing was entirely satisfactory, except for occasional small granulating areas. There were no sinus tracks. Local and systemic sepsis had been eliminated, and the patient was rapidly gaining weight and strength. A new hip spica was applied for transfer of the patient to the Zone of Interior.

In 271 wounds of the knee joint studied from the same disposition-board proceedings, the cases were divided into those treated before the final drive for Cassino and Rome, which began 11 May 1944, and those treated after that date.

In the 73 cases which made up the earlier group and which were treated by the original techniques, the incidence of infection in general hospitals was 27.4 percent. In the 198 cases treated after the reparative program had become effective, the incidence of infection was 5.4 percent.

In the earlier group, the infectious process continued in 8.2 percent of the cases until the joint had been completely destroyed, while in another 8.2 percent of the infected cases the end result was not known. There were only 4 instances (2 percent) of complete joint destruction in the later series, and in 3 of these the recommended regimen for the management of early infection had not been instituted. In the remaining case, damage at wounding had been so severe that resection of the knee joint was necessary.

General hospitals.—Reports from individual hospitals showed that when initial wound surgery had been adequate, results in wounds of the knee joint were greatly improved.

At the 17th General Hospital, 194 wounds of the knee joint were analyzed, in 128 of which initial surgery had been adequate and in 66 of which it had not been.

In 119 of the 128 cases in which initial surgery had been adequate, there was no evidence of infection when the patients were received in the fixed hospital, and closure of the wounds of the soft parts could be proceeded with at once.

In 4 of the other 9 cases, in all of which infection was present, the process was controlled without surgery by the aspiration-instillation routine with penicillin solution. In two cases, secondary arthrotomy was performed, with excision of intra-articular devitalized tissue, and in another case incision and drainage controlled the infection. In these seven cases, a functioning knee joint was obtained. In the two remaining cases, bone damage had been extreme. Resection of the knee joint was necessary in one case and amputation of the limb in the other, primarily because of trauma.

In the 66 cases at the 17th General Hospital in which initial wound surgery had apparently not been complete, 16 joints were found to be infected when the wounds were exposed. In eight cases, infection was controlled satisfactorily by arthrotomy and secondary debridement. In another case, in which bone damage was severe, prolonged drainage was instituted through the open wound, without expectation that satisfactory function would ultimately be obtained. In the other seven cases, in all of which bone damage was extreme, resection of the joint was necessary in five cases and amputation in the other two. The results in the five resections were as satisfactory as this procedure permits.

The 70th General Hospital received 45 patients with wounds of the knee joint after the Po Valley campaign, at the end of the fighting in Italy. Reparative surgery was rendered on an average of 7.7 days after wounding. In eight of these cases, arthrotomy was performed for exploratory purposes and to complete intra-articular debridement, on the indication of impending infection. Recovery was uneventful in all. In the only two cases in the whole group in which infection became established, the process spread from infected fractures adjacent to the joint, a supracondylar fracture of the femur in one instance and a fracture of the upper tibia in the other.

Resection of the knee joint.—It is known that 31 resections of the knee joint (figs. 75, 76, and 77) were performed in the Mediterranean Theater of Operations by United States Army surgeons; 24 of the operations were on United States Army personnel.

Two of these operations were performed at initial wound surgery on the indication of extensive trauma.

In six operations, all on French colonial soldiers and all at the 9th Evacuation Hospital, which was then serving as a fixed hospital, initial wound surgery had not been adequate, and severe suppurative arthritis had followed relatively minor injuries caused by penetrating wounds. In each of these cases, it was thought that the infection present seriously endangered the vitality of the limb.

In 3 other resections, the indication was also severe suppurative arthritis, superimposed in 1 case on minimal intra-articular damage and in 2 cases on moderate damage.

In the remaining 20 cases, the indication for resection was traumatic destruction of the joint, with impending or early established infection.

The results in these 31 cases were satisfactory within the limitations of resection of the knee joint. There were no deaths. Rapid improvement invariably followed the operation. Most of the patients were evacuated to the United States with well-healed wounds, and nine are known to have had clinically stable limbs before they left the theater. In every case, it had been possible, without special difficulty, to achieve apposition of the bony structures in the position of function. The shortening of the limb, which varied from 1 to 3 inches and which averaged $1\frac{1}{2}$ inches, was dictated by the bone loss from trauma or infection.

In a followup survey of various procedures conducted in the Zone of Interior early in 1945, it was possible either to examine or to secure accurate information about eight patients who had been subjected to resection of the knee joint overseas. In seven cases, the indication for the resection was traumatic destruction of the joint, followed by infection. In the eighth case, the original damage was moderate, but the joint had been destroyed by infection.

In this case, as well as in six others, the wounds were healed. In the remaining case, there was a sinus to a condylar fracture just above the joint.

Fusion was satisfactory in six cases, including the case in which the joint had been destroyed by infection; one of these patients was at a convalescent hospital and ready for a Certificate of Disability discharge. In another case, fusion seemed to be occurring, but only 3 months had elapsed since operation. In the remaining case, in which there was no evidence of fusion, it was thought that bone grafting would be required.

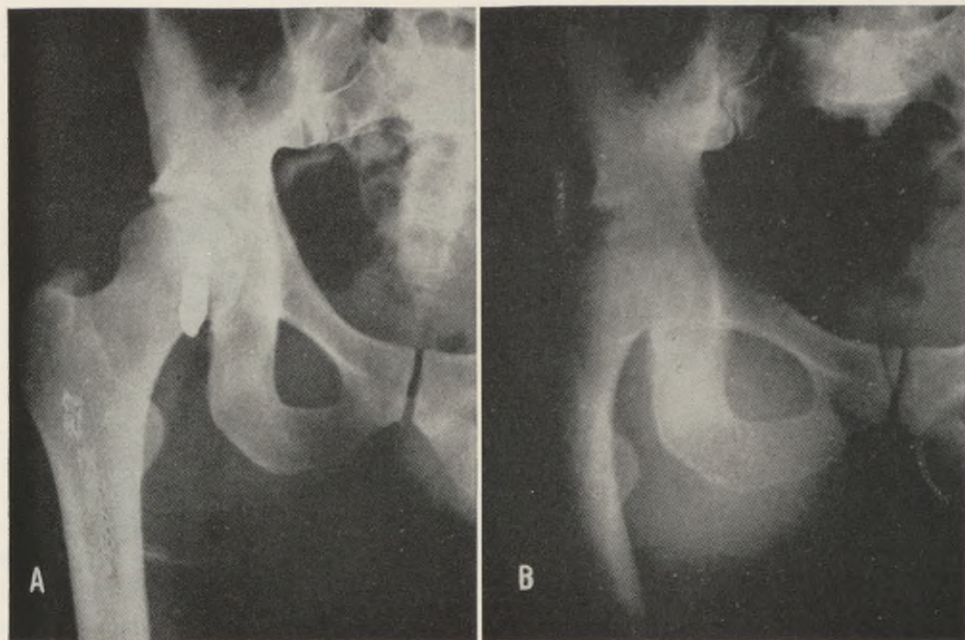
The results in this small group of cases further confirmed the impression that resection of the knee joint has a definite, but fortunately limited, application in the management of severely traumatized and infected wounds of the knee joint encountered in military surgery.

WOUNDS OF THE HIP JOINT

Wounds of the hip joint (figs. 78, 79, and 80) presented even more difficult problems in military surgery than wounds of the knee joint. Because they affected one of the two major weight-bearing joints of the body, they were always serious, even when the injury was not extensive. The immediate case fatality rate was high, probably not because of the injury to the hip joint but because of associated injuries to overlying and adjacent major blood vessels. Later deaths were the result of associated intra-abdominal wounds, particularly wounds of the rectum or the urinary bladder. Such combinations of injuries were frequent, and their management taxed the ingenuity of forward- and rear-area surgeons alike.

The management of wounds of the hip joint produced the least satisfactory results obtained in skeletal injuries in World War II. For this, there were a number of reasons: (1) The damage at wounding was often sufficient to destroy the joint and in itself was often enough to cause ankylosis. (2) Infection was frequent. If the articulating surfaces of the femur and acetabulum had been damaged, as they had been in many cases, drainage was likely to be prolonged, and there was often evidence of systemic absorption and toxemia. (3) The high incidence of suppurative arthritis observed in general hospitals in cases in which trauma had been slight or moderate suggested that initial wound surgery had frequently not been adequate. In some of these cases, the joint was completely destroyed by the infectious process. (4) The principles of excisional surgery were the same for the hip joint as for all other joints, and their application to wounds in this area was equally necessary.

On the other hand, the hip joint is not readily accessible, and adequate debridement required wide exposure and precise anatomic orientation. Initial wound surgery, in short, was a procedure of magnitude, with which the average forward surgeon had usually had a limited experience if he had had any at all. The availability of a consultant in orthopedic surgery to the army surgeon (p. 5) might have contributed to the improvement of initial wound surgery in compound fractures of the hip joint and to a consequent improvement in the end results of these complicated injuries.



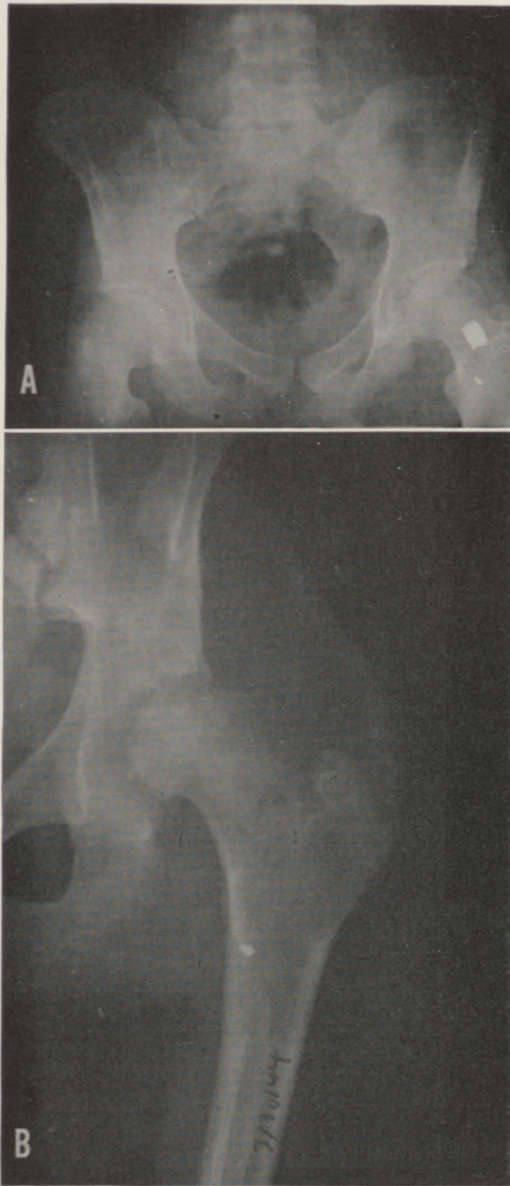
U. S. Army photos

FIGURE 78.—Management of suppurative arthritis superimposed on high-explosive shell fragment injury of hip joint. Initial surgery in this patient was inadequate; the hip joint was not opened, and the foreign body was not removed. Suppurative arthritis ensued, not controlled by removal of the foreign body 10 days later, without thorough intra-articular debridement. A. Anteroposterior roentgenogram of pelvis and hip joint in evacuation hospital showing high-explosive shell fragment lying in articular cartilage of head of femur. B. Anteroposterior roentgenogram of pelvis and hip joint 4 weeks later, showing hip joint totally destroyed from infection.

Survey of Cases, January 1945

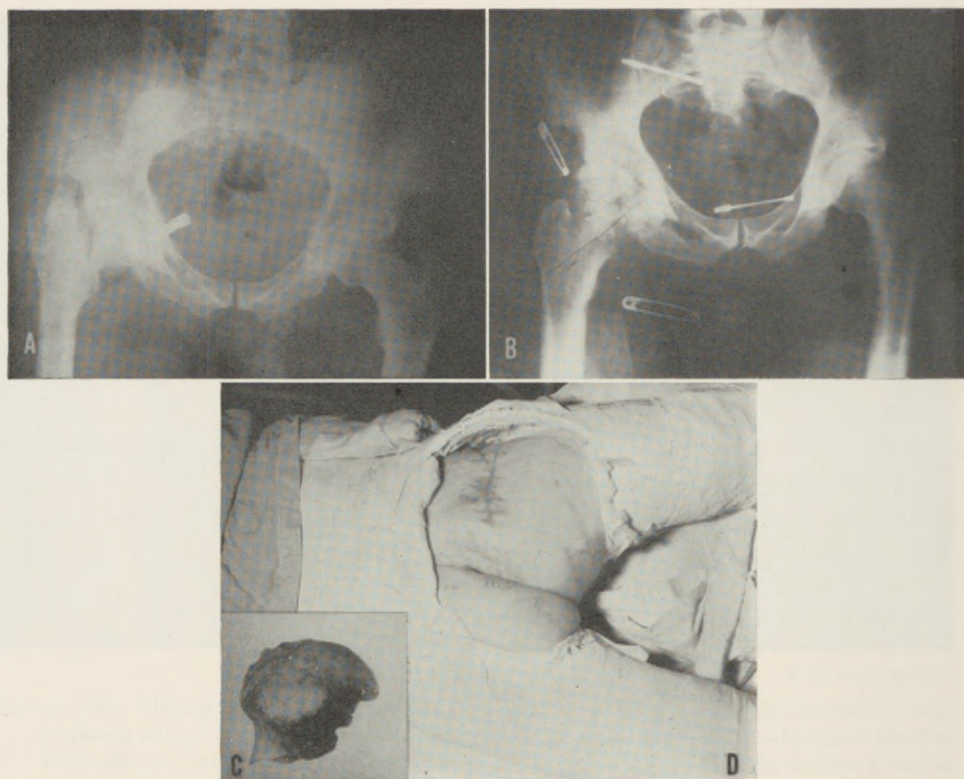
The results achieved in the treatment of wounds of the hip joint in the Mediterranean theater were recognized as so unsatisfactory that, in January 1945, a survey was undertaken, on orders of the theater surgeon and at the request of the consultant in orthopedic surgery, to collect precise data concerning them. At this time, 15 casualties with injuries of the hip joint were hospitalized in the general hospitals of the Naples base area, the ratio being 1 to 250 patients then hospitalized for all battle-incurred injuries. In addition, a search revealed 24 previous admissions for this cause in which the hospital records contained data sufficiently detailed for analysis. The material for the survey thus consisted of 39 cases.

No case was accepted for this analysis unless there was roentgenologic evidence of trauma to bone or cartilage, on the reasonable assumption that a missile which penetrated the hip joint would inevitably produce some skeletal damage. A joint was classified as infected (1) if there was roentgenologic evi-



AFIP C-44-358

FIGURE 79.—Management of suppurative arthritis superimposed on high-explosive penetrating wound of left buttock, hip joint, and neck of femur. Life-endangering thoracic injury permitted only minimal debridement of wound of buttock in initial surgery. Arthrotomy of hip joint was omitted. Suppurative arthritis could not be controlled, even after removal of intra-articular foreign body a week after wounding. No effort was made at this time to cleanse joint of debris or to insure good posterior drainage. A. Anteroposterior roentgenogram showing foreign body overlying neck of femur. A lateral view demonstrated that missile had perforated femoral neck and come to rest anteriorly. B. Anteroposterior view of left hip joint, showing total destruction by infection 6 weeks after wounding. Patient was transported to ZI in hip spica before infection was controlled.



AFIP FB-447, Fd-45-19

FIGURE 80.—Management of suppurative arthritis of right hip joint, following damage to neck and head of femur by high-velocity missile. A. Anteroposterior roentgenogram of pelvis and hips made in evacuation hospital, showing fracture of neck of femur and retained foreign body. At initial wound surgery, the wound of entry was debrided, after which the joint was explored and the bullet and some loose bone fragments were removed. A hip spica was applied as transportation splinting. In the fixed hospital, the extremity was placed in balanced-suspension skeletal traction. Infection was persistent, and wound healing was not obtained. B. Anteroposterior roentgenogram made in fixed hospital 5 weeks after wounding, showing dead femoral head and destruction of hip joint by infectious process. Soon after this film was made, the joint was opened through a posterior approach, and all dead bone was removed. The joint cavity was thoroughly irrigated, and the operative wound was sutured. A drain was inserted down to the old hip-joint cavity. Immobilization was obtained by a hip spica which extended to the knee on the opposite side. C. Dead head of the femur, which was removed along with other fragments of bone and cartilage. D. Healed wound, 3 weeks after surgery on infected hip joint. The drain was removed 5 days after this operation, and healing occurred promptly. All signs of systemic toxemia also disappeared promptly.

dence of progressive destruction, (2) if the patient presented the manifestations of toxemia, or (3) if there had been prolonged drainage from the joint. An unhealed compounding wound was not regarded, in itself, as evidence of joint infection.

It is unfortunate that little precise information could be secured concerning the initial wound surgery performed in these 39 cases. In 13 cases, in which no infection had occurred, it could be ascertained that foreign bodies had been removed in several instances and that the joint capsule had been closed in two instances. In most of the 39 cases, however, including 26 cases of undoubted infection by the criteria just stated, the location and extent of the wounds suggested that exposure sufficient to permit adequate excision of devitalized tissue had seldom been accomplished.

Certain observations made in this survey seemed highly significant. They are as follows:

1. All six patients with concurrent intra-abdominal injuries also had infections of the hip joint. The origin of the infection seemed obvious; it was assumed to have resulted from cross-infection from the associated injuries, in most of which the intestines were involved.

2. Eighteen of the 19 patients with damage to the articular cartilage, 17 of the 21 with involvement of multiple components of the hip joint, and 15 of the 19 with severe comminution had infections of the hip joint. These data, especially in the light of the similar data available for wounds of the knee joint (p. 219), clearly pointed to traumatized, devitalized, poorly nourished, unexcised articular cartilage as the focus of infection.

3. The timelag from wounding to initial wound surgery, while prolonged, was substantially the same, on the average, in both the infected and the uninfected group of cases (16 versus 17 hours). The timelag from wounding to reparative surgery was, however, considerably longer in the infected group, 12 days compared with 7 days in the uninfected group.

4. It was known that penicillin had been given in 22 of the 26 infected cases and in 12 of the 13 uninfected cases.

5. In the 13 cases in which no infection was present, surgery in general hospitals had consisted only of wound closure.

6. In 10 of the 26 infected cases, no additional surgery was performed in the general hospitals. The procedures performed in the other cases, after infection was evident and in an attempt to accomplish wound healing, included additional debridement (3 cases); additional drainage (3 cases); sequestrectomy (4 cases); excision of the head of the femur (2 cases); removal of foreign bodies and drainage, exploration of a sinus, and skin grafting (1 case each); and closure of the wound (1 case). In spite of these additional operations, wound healing was accomplished in only 2 of the 26 infected cases.

Early Plans of Management

Before the development of the program of reparative surgery, in the spring of 1944, patients with wounds of the hip joint, after initial wound surgery in a forward hospital, were transported to general hospitals in double hip spicas, extending only to the knee on the intact side. Transportation was usually possible within 5 to 6 days unless concurrent wounds required that the holding period be extended to 10 or 15 days, or even longer. Since established infection of the hip joint may become evident within 5 to 6 days, some wounds were infected before the patients ever left forward hospitals.

After the patients reached the general hospital, the transportation spica was removed, the wound was dressed, and another spica was applied to hold the joint in a few degrees of abduction and external rotation and in about 30° flexion. Should ankylosis occur, this was the most desirable position. In occasional cases, skin traction or skeletal traction was used for a few weeks before the spica was reapplied. If suppurative arthritis developed, it was usually managed by open drainage, after which the patient was put up in plaster immobilization or in skeletal traction.

Later Plans of Management

The results of the survey undertaken in January 1945 confirmed the impression that the unsatisfactory results secured in wounds of the hip joint in the Mediterranean theater were chiefly caused by an inadequate approach to the problem. Confirmatory evidence was secured later in the year, when the theater consultant in orthopedic surgery was able to question the chiefs of various orthopedic sections in the hospitals in the Zone of Interior visited for another purpose (p. 189). Formal data were not compiled, but the unanimous opinion was expressed that, in the great majority of cases, infection of the hip joint was the result of retention of dead tissue and that it could not be controlled until this tissue had been removed by direct surgical attack.

Early in 1945, an ideal regimen was worked out for wounds of the hip joint, based on aggressive surgery, adjunct chemotherapy, and liberal blood replacement. It was to include the following:

1. Adequate exposure of the articulation, which, as already mentioned, was frequently a difficult technical procedure.
2. As complete debridement as possible, followed by immobilization of the extremity.
3. Transportation to a general hospital as rapidly as possible.
4. Reparative operation as soon as preoperative preparation could be completed. If there were no evidences of infection, the operation was to be limited to closure of the wound.
5. If signs of infection became evident in the forward hospital, radical secondary surgery was to be performed, as in wounds of the knee joint (p. 231).

Wide exposure and thorough debridement were recommended, with, if necessary, dislocation of the hip to secure adequate exposure. Since the operation was not an emergency, the services of an orthopedic surgeon qualified to undertake such extensive surgery were to be obtained. They were practically always available in the same or at some nearby hospital.

6. If infection became evident after the patient reached the general hospital, the same sort of aggressive surgery was recommended. Here, qualified orthopedic surgeons were always available. Removal of devitalized bone and cartilage and of foreign material was to be carried out, as at initial wound surgery. Sometimes the removal of the dead and fractured femoral head would constitute, in effect, a resection of the joint. Elective resection for suppurative arthritis, as practiced by continental surgeons, is not known to have been performed by United States medical officers.

It was realized that the proposed regimen represented a radical solution of the problem of wounds of the hip joint. It was also realized that the excision of devitalized bone and cartilage, with dislocation of the hip, if necessary, to secure adequate exposure, might be followed by partial or complete restriction of joint function. On the other hand, it was felt that the hazard of secondary surgery, under the protection of penicillin and blood replacement, could not possibly exceed the risk of severe infection of the joint, which might destroy life as well as limb.

In the isolated cases in which this plan was followed, the results were as good as could have been expected under the circumstances, which were frankly disadvantageous. The program had, however, no theaterwide application. Almost as soon as it had been set up, the German armies in Italy capitulated, and fighting ended. In the light of the knowledge available at the end of the war, this program was felt to be the best plan possible for the management of wounds of the hip joints in future conflicts.

WOUNDS OF THE SMALLER JOINTS

In the great majority of wounds of the shoulder, elbow, wrist, and ankle joints, the policy of closing the synovial membrane or capsule, which eventually became theater policy, could not be practiced at initial wound surgery because of the extensive loss of soft parts and the bony destruction which had occurred at the time of wounding. Whenever it was possible, closure was effected after thorough excisional surgery had been carried out and the joint cavity had been irrigated. Transportation splinting was in accordance with the practices outlined for wounds in the special areas affected.

Primary resection of the smaller joints was seldom if ever performed as a deliberate procedure at initial wound surgery. In many instances, however, what was in effect a traumatic resection had already occurred when the articulating components were blown away at wounding. This frequently happened at the elbow joint and happened less often at the shoulder and wrist joints.

As the importance of complete excisional surgery became more and more clearly understood, debridement of the badly damaged joint, in the occasional case, at least, amounted to resection.

The management of wounds of the smaller joints in general hospitals was essentially the same as the management of compound fractures in the special region affected. Early in the war, the plaster was removed; the wound was dressed and left open; and immobilization was again instituted, usually by plaster of paris. Later, when the principles of reparative surgery had become established, it became the practice, as in all other soft-tissue wounds, to suture the wound of the soft tissue over the joint if possible, preferably between the 5th and 10th days after wounding. The closure was more often closure over a compound fracture extending into and involving a joint than closure over a joint injury.

The old Willems method of early active motion was almost never employed in wounds of the shoulder, wrist, elbow, and ankle joints, though immobilization was discontinued just as soon as it was considered surgically sound from the standpoints of wound healing and fracture healing. This was usually between the second and third weeks after wounding, unless a fracture made further immobilization necessary.

Suppurative arthritis was seldom a complication of penetrating wounds of the smaller joints of the upper extremity unless intra-articular damage had been considerable. In the ankle, suppurative arthritis was frequently superimposed on the original wound if destruction of the articulating portions of the joint had been extensive. The infection was usually treated by open drainage and immobilization by plaster in the position of election. The best that could be hoped for in most cases was spontaneous or surgical fusion of the joint.

Secondary resection was seldom done as an elective procedure for suppurative arthritis of the shoulder, wrist, and ankle joints. In most of the cases in which it was performed, it was, in effect, little more than delayed excisional surgery. At the 21st General Hospital, in which it was employed in a number of cases on the indication of severe infection, it was thought that the operation probably had a limited field of usefulness in suppurative arthritis of the elbow joint superimposed on severe trauma.

CHAPTER IX

Amputations¹

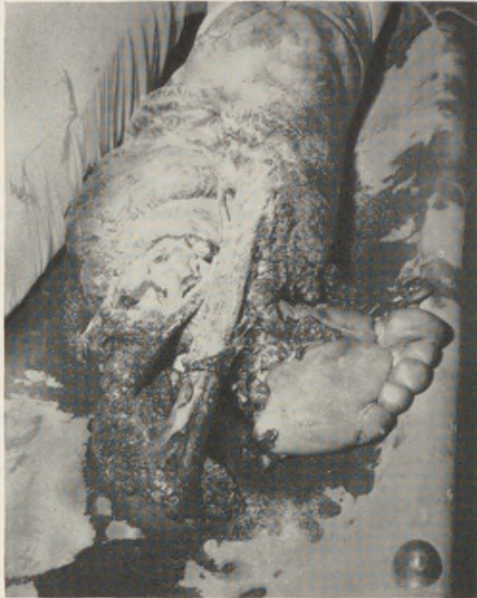Throughout the 2½ years of land warfare in the Mediterranean Theater of Operations, the attitude toward amputation was one of extreme conservatism on the part of all medical officers—in mobile medical units as well as fixed hospitals in rear areas. Because of the tremendous possibilities of modern reconstructive surgery, the operation was almost never performed unless the extremity was damaged beyond salvage or unless, after salvage had been attempted, conditions developed which endangered life or made further efforts to save the limb futile. Severe compound fractures of the heel bone and of the bones of the leg or thigh associated with extensive loss of bone were clearly extremely serious injuries, but they were not, in the absence of other indications, considered indications for amputation. United States practices of conservatism in such severely wounded lower extremities were in some contradistinction to the surgical policies practiced by medical officers of some of the other warring nations.

The theater policy for amputations was set forth explicitly in Circular Letter No. 46,² 29 August 1944, Office of the Surgeon, North African Theater of Operations. This letter was merely the official statement of a policy which had been in effect for more than a year and the general principles of which had been established earlier in 1943. Details of technique were described in this circular letter, and it was emphasized that casualties who required amputation should be told before operation, whenever their condition permitted, why this procedure was necessary. It was also suggested that, as soon as the patient was surgically comfortable and mentally receptive, an interview with a psychiatrist or chaplain might be useful. These instructions were based on the fact that about 1 in every 5 patients could be expected to exhibit psychic reactions, often depressive in type, a few days after operation.

Particular attention was to be paid in this and other interviews to what the soldier might reasonably expect in the way of aid. He was to be told of the amputation centers which had been established in the Zone of Interior, the prosthetic appliances which were available, and the economic and other aid which he could be assured of receiving. Fortification of this kind before the patient became the target of sympathetic family and friends, the circular letter pointed out, might tip the scales in favor of rehabilitation, while its omission might result in lifelong disability and resentment.

¹ The data in this chapter on amputations in United States Army casualties were collected by Maj. Benjamin W. Rawles, MC, 45th General Hospital. The data on amputations in German prisoners of war were collected by Maj. George S. Hopkins, MC, and Capt. C. R. Brott, MC, 2d Auxiliary Surgical Team.

² See appendix, pp. 326-331.



AFIP CA-44-158

FIGURE 81.—Destructive injury of entire left leg from landmine explosion. Note how the foot has been driven halfway up the leg. An injury of this sort is a true traumatic amputation.

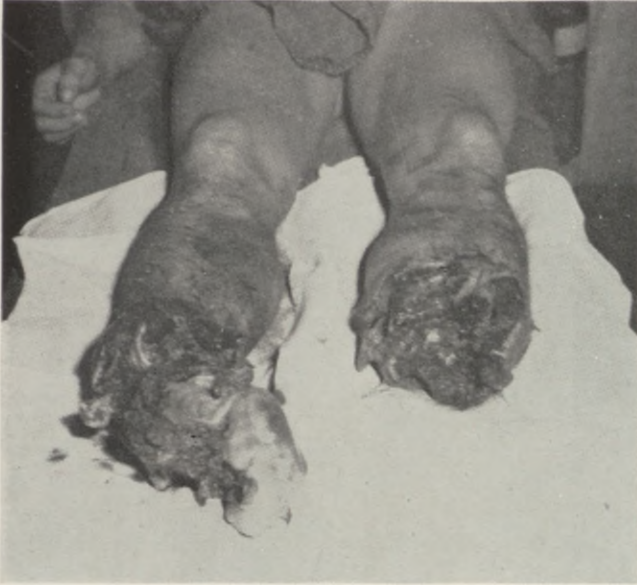INDICATIONS

Amputations were performed either primarily or secondarily. The great majority (p. 269) were performed primarily, at initial wound surgery, and chiefly in forward hospitals.

Indications, which did not differ from the usual indications for amputation except from the standpoint of the degree of trauma, were as follows:

1. Trauma at wounding (figs. 81, 82, and 83), in which the extremities were blasted off, blown off, torn off, or shot away. In such cases, the surgeon's function was merely revision of an amputation that had already occurred. Damage to the extremity of such a degree that future function was obviously hopeless also warranted amputation. In many cases of this kind, major blood vessels were interrupted, but vascular insufficiency per se was not considered the indication for amputation; the damage to the extremity, aside from vascular damage, was regarded as sufficient indication for the operation.

2. Vascular insufficiency per se. In this type of case, the reason for amputation was the interruption of a major blood vessel, with resulting impending or actual gangrene. Amputation on this indication was usually performed in fixed hospitals, though in some cases it was a secondary operation in an evacuation hospital.



U. S. Army photo

FIGURE 82.—Bilateral traumatic amputations of legs resulting from land-mine explosion. Appearance of the injuries before initial wound surgery, which obviously can consist only of completion of the traumatic amputations.

3. Infection. In this group of cases, amputation was necessary to control infectious processes, usually clostridial myositis, or was indicated because excision of tissue which had become necrotic had been so extensive that the extremity which was left was damaged beyond hope of function. Amputation on this indication was often undertaken to prevent loss of life.

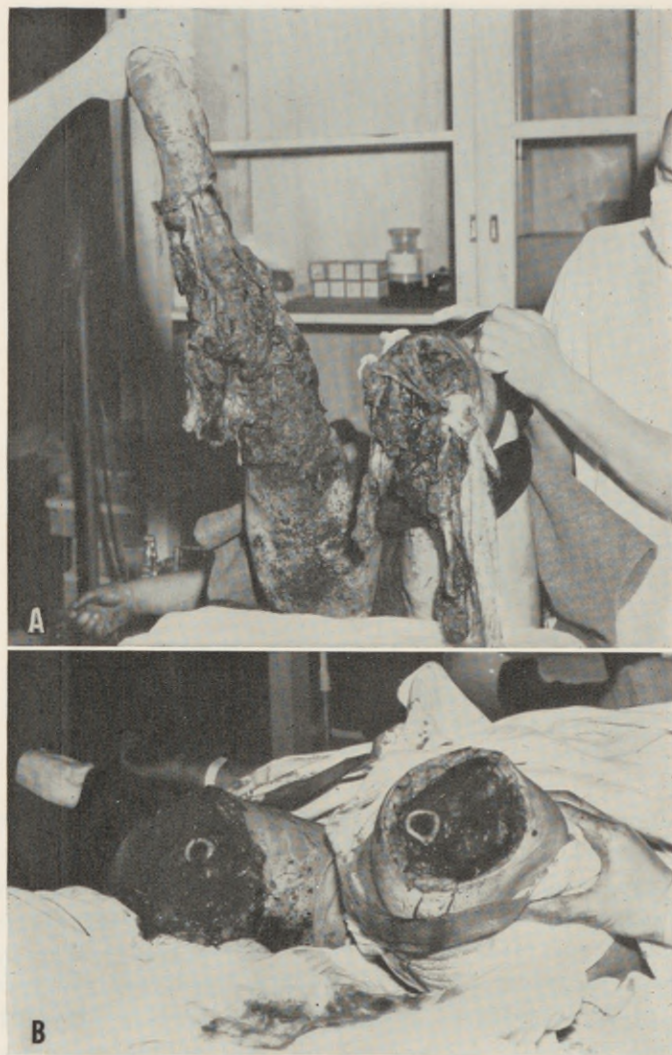
4. Disease, including malignant tumors, trenchfoot, thrombosis, tuberculosis, and other conditions. Amputation for these causes was uncommon in an overseas theater.

TECHNICAL CONSIDERATIONS

It was the official surgical policy in World War II that the open circular (so-called guillotine) amputation be employed routinely.³ This policy was set forth explicitly in Circular Letter No. 46, Office of the Surgeon, North African Theater of Operations, as already noted.

The technical details of the operation were fully described in this circular letter, the basic direction being that open circular amputation be used routinely and that it be performed at the lowest possible level of viable tissue. The only exceptions to the latter requirement were that proximal amputation

³ Circular Letter No. 91, Office of the Surgeon General, U. S. Army, 26 Apr. 1943, subject: Amputations.



AFIP CA-44-634

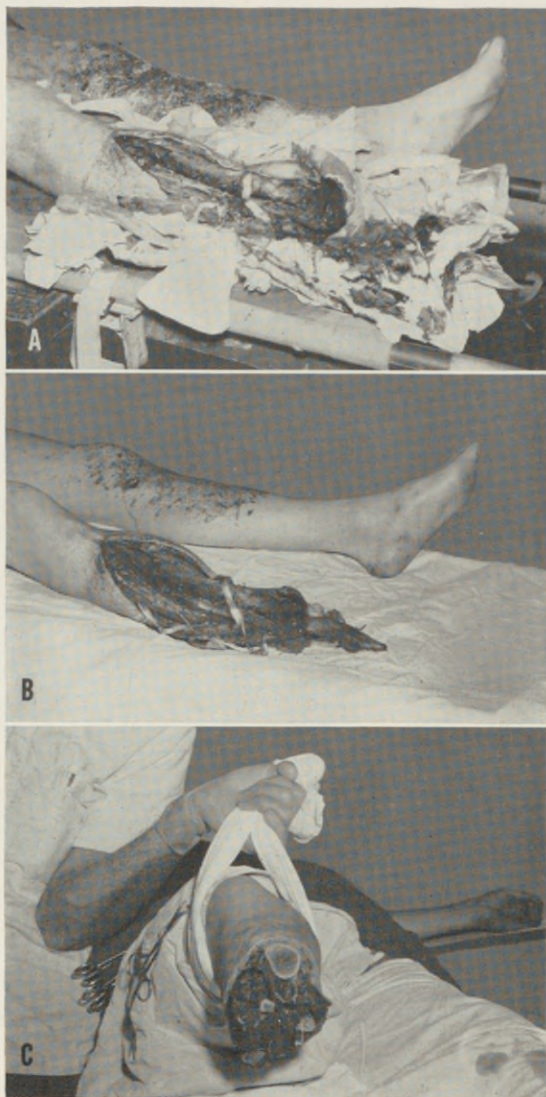
FIGURE 83.—Bilateral injuries of lower extremities resulting from land-mine explosion. On the left side, there has been a traumatic amputation through the thigh. On the right side, damage to the thigh and leg is so extensive that only primary amputation is possible. A. Appearance of injuries before initial wound surgery. B. Appearance of injuries after initial wound surgery. The right lower extremity has been amputated through the middle third of the thigh by the open circular technique. The stump of the left thigh has been shaped so as to present a similar circular stump.

might be performed in preference to disarticulation and that such modifications as good judgment dictated were permitted in amputations of the upper extremity.

In practice, amputation at the lowest level of viable tissue not infrequently came into technical conflict with amputation by the open circular technique (fig. 84). These recommendations, in practice, could be applied concurrently only in cases in which the saw line was determined by the level of viability of soft tissue. This was generally true in amputations performed on the indication of vascular insufficiency, as well as in some amputations for clostridial myositis. When trauma was the indication, as it was in the great majority of amputations, especially those performed in forward areas, the extensive compound fractures present almost invariably determined the level of the saw line. Only in the very occasional case was it found expedient to amputate through a long bone which was the site of a proximal fracture. Some viable muscle and skin were, as a rule, present below the level of the fracture or fractures that determined the saw line, and the use of the circular technique necessarily meant their sacrifice. In such cases, therefore, amputations were not performed at the lowest level of viable tissue.

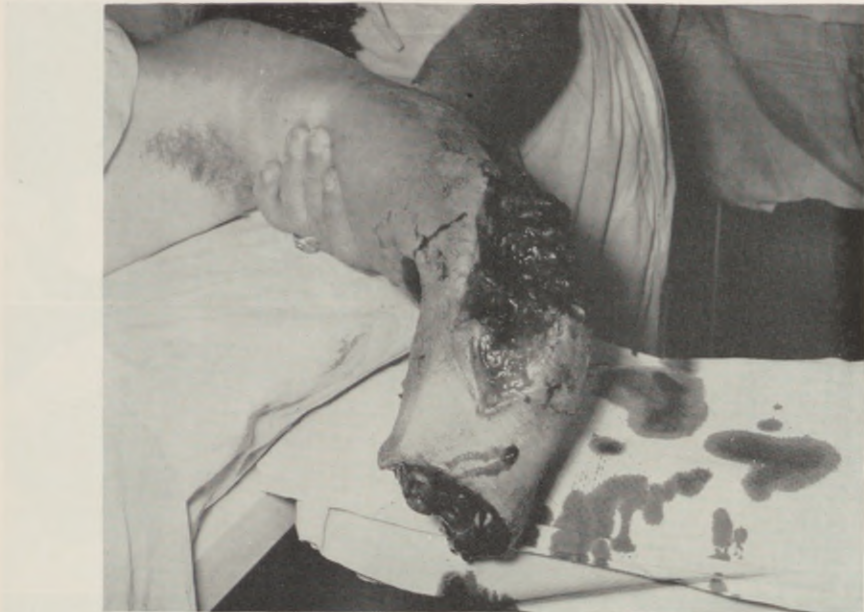It was not easy, in some instances, to ascertain the true lowest level of viable tissue. This was well expressed in the report of an orthopedic team attached to the 2d Auxiliary Surgical Group, which pointed out that "where to amputate" sounded simple when it was followed by the statement "at the lowest possible level." In extremities that had been blasted off or undergone extremely severe trauma, the report continued, muscle tissue might be found damaged for a distance of several inches above the site of the wound, and selection of the amputation site might be a matter of considerable difficulty. Often the muscle varied in color from deep red to purple and was congested, swollen, and noncontractile while its blood supply was apparently adequate. In most such cases, it was the policy not to select the higher level of undamaged and clean tissue for the amputation site but to choose, instead, the lower level, where there was no doubt that the muscle, while damaged, was still viable. The risk involved in this policy was overcome by watching the patient very carefully for signs of further necrosis or of the development of clostridial myositis.

That these and other problems were usually solved with discretion and judgment is shown by the infrequency of reamputations in the Mediterranean theater (fig. 85). The conservative attitude expressed in the report just cited was theaterwide, and it is doubtful that any appreciable number of amputations were done at an unnecessarily high level.



AFIP CA-44-600

FIGURE 84.—Traumatic amputation of right leg, multiple penetrating wounds of left leg, caused by high-explosive shell fragments. A. Appearance of wounds in evacuation hospital after removal of emergency splinting and dressings. B. Appearance of wounds after preparation for initial surgery. Note large posterior flap of apparently viable skin on right leg. The tibia is completely fractured in the mid third. C. Appearance of stump of right leg after amputation by prescribed open circular technique, with sacrifice of flap of skin seen in view B. The level of amputation approaches the critical level at the junction of the upper and middle thirds of the leg. The salvage of the presumably viable flap of skin might have permitted delayed wound closure and avoided a later undesirable reamputation at a higher level in a Zone of Interior hospital.



AFIP CA-44-403

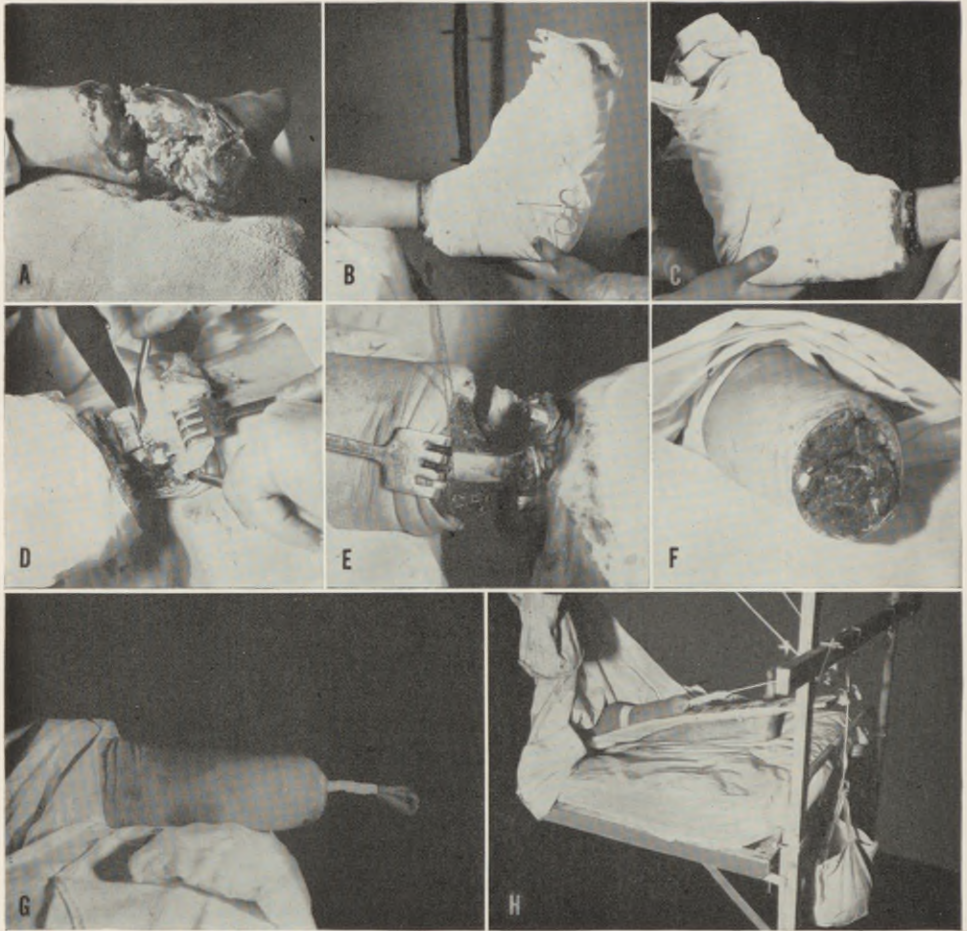
FIGURE 85.—Amputation stump of left forearm, at junction of upper and middle thirds. The severe compound fracture of the lower end of the humerus, associated with the loss of soft tissue, was considered an indication for reamputation just below the middle of the upper arm.

The required technique of circular amputation was as follows:

*** A circular incision is made through the skin at the lowest level compatible with viable tissue and the skin is allowed to retract; the fascia is then incised at the level to which the skin has retracted. The superficial layer of muscle is then cut at the end of the fascia and permitted to retract. At its point of retraction, the deep layers of muscle are cut through to the bone. After the deep muscles have retracted the periosteum of the bone is cleanly incised and the bone sawed through flush with the muscles. No cuff of periosteum is removed as in a closed amputation. Bone denuded of periosteum will sequestrate if infection is present and a ring sequestrum often results when the periosteum has been removed. It is important also that no periosteum be elevated or torn from the bone in the stump by rough handling.

The standard technique for the open circular type of amputation was followed in the theater (fig. 86). Early in the war, some surgeons were inclined to use the so-called meat-cleaver method, but this error was corrected by educational endeavors to demonstrate the proper inverted-cone stump. As experience increased, this error disappeared.

Circular Letter No. 46 directed that the end of the stump be dressed with fine-mesh gauze, so applied that the gauze did not overlap the skin edges. Skin traction was then applied immediately (fig. 87) either by a stockinet cuff attached with ace adherent or by adhesive tape. Traction was best obtained by a light plaster cast with a wire ladder banjo (fig. 88). The cast



AFIP Fd-44-2

FIGURE 86.—Technique of open circular amputation. A. Severe injury in region of right ankle, with established infection, for which secondary amputation was performed in a fixed hospital. Note destruction of heel. B. Lateral view of circular incision through skin, which has retracted. C. Medial view of incision of fascia and muscles at level to which skin has retracted in view B. D. Incision of periosteum, sawing of tibia, at level to which muscles have retracted in view C. E. Lateral view of section of fibula with Gigli saw at level slightly proximal to stump of tibia. In the open circular technique, no particular effort is made to section the fibula $\frac{3}{4}$ to 1 inch above the end of the tibia, as is done at definitive reamputation or revision of the stump. F. Open concave circular stump at completion of amputation. G. Stockinet applied in fixed hospital after dressing of open circular stump. H. Skin traction provided by means of weight attached to rope which passes over pulley and extends from stockinet attached to skin; lower extremity rests on half-ring leg splint. This is the most effective means of traction on the skin following open circular amputation.

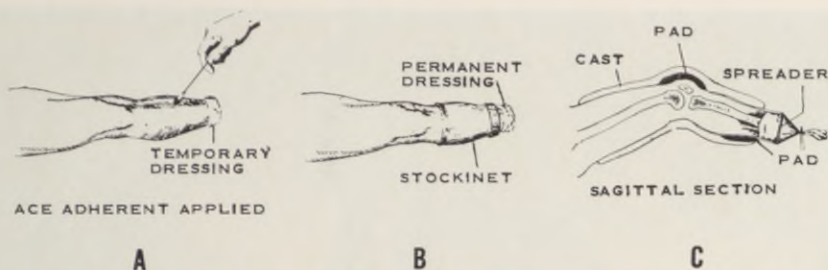


FIGURE 87.—Steps in application of skin traction after amputation of leg.

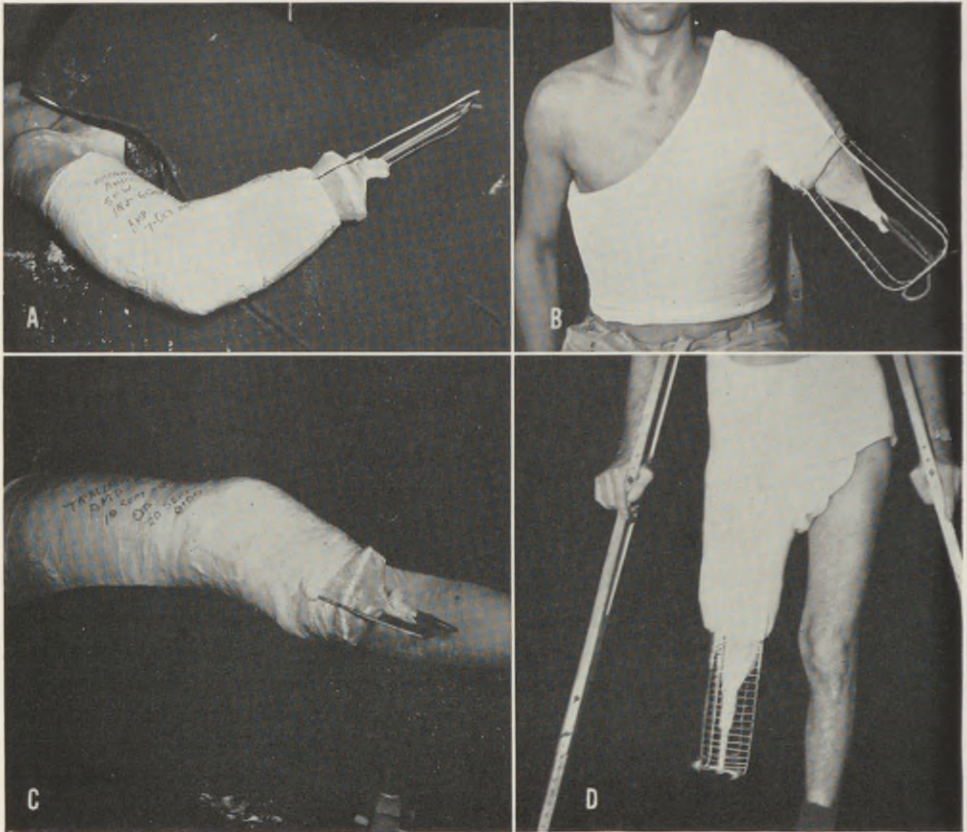
always incorporated the joint above the amputation; a spica, for instance, would be used after a thigh amputation. Alternatively, if an Army half-ring splint was used in amputations of the lower leg, a posterior plaster-of-paris splint was provided from the mid thigh to beyond the stump, to prevent flexion contracture of the knee. The plasma tubing formerly employed was generally replaced by the elastic cord provided for this purpose in 1944 (fig. 89).

Reparative surgery.—Circular Letter No. 46 directed that all amputations in the thigh and all in the leg at or near the site of election should be treated by continuous skin traction after the patient reached a general hospital. Secondary suture or skin grafting of the terminal defect, with or without revision, was forbidden. It was recommended that the cast or splint be removed in the fixed hospital and that 6 to 10 pounds of traction be maintained over a pulley at the foot of the bed. Traction was to be continued for at least 6 weeks, until all layers of soft tissue had been firmly fixed by scar formation.

Traction during evacuation to the Zone of Interior, for which amputees were given priority by air as soon as they became transportable, was provided by stockinet and a banjo plaster.

Closure of wounds in the lower third of the leg, which was well below the site of election, and in the upper extremity was permitted by secondary suture in general hospitals provided that the wound was clean and the operation was done under penicillin protection. If closure was not feasible, skin traction was maintained.

When the reparative-surgery program proved successful in the Mediterranean theater, it was natural that enthusiasm for it should lead to an extension of its principles to the amputation stump. The application of these principles in the management of compound fractures had amply demonstrated that closure of muscles and other soft parts over exposed bones prevented the access of organisms to the deeper tissues and fracture site, reduced scar formation, and simplified as well as shortened the period of healing (figs. 90, 91, 92, 93, 94, 95, and 96). In deference to the recommendations of The Surgeon General and the judgment of surgeons at the amputation centers in the Zone of Interior, an extensive clinical trial of reparative surgery as applied to circular flaps was



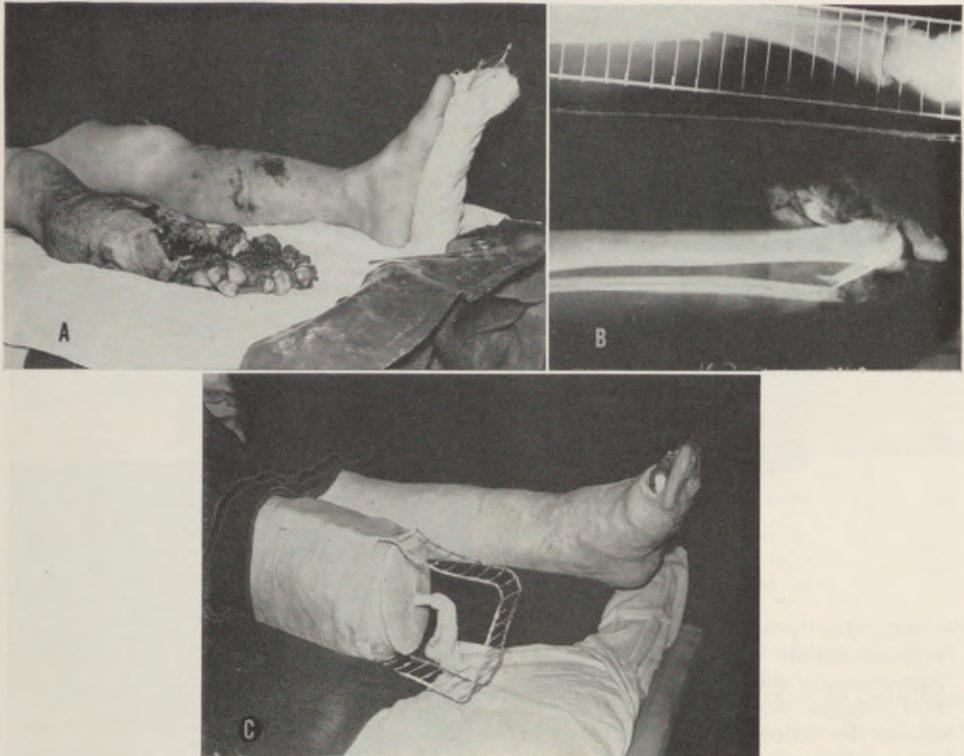
AFIP CA-44-633, CA-44-199, CA-44-600, Fd-44-28

FIGURE 88.—Use of plaster cast incorporating banjo made of wire ladder splint or steel rod, to which elastic traction is provided from stockinet fixed to skin. A and B. Upper extremity. C and D. Lower extremity.

not undertaken. Delayed closure was strictly forbidden in Circular Letter No. 46 in amputations of the thigh and of the leg unless it could be carried out well below the site of election. In amputations of the lower third of the leg and of the upper extremity, closure by suture was permitted whenever it was surgically feasible. As a matter of fact, as already mentioned, modifications of technique were permitted in all amputations of the upper extremity in order to secure early closure.

The number of cases in which the reparative-surgery program was applied in amputations was far too small to permit any conclusions concerning results. The data from three general hospitals, however, are recorded, for this small group of cases, all handled in 1944, might serve as a reference point should the problem arise in another war.

At the first hospital, 77 of 338 casualties with major amputations (22.7 percent) were submitted to suture of the stump before evacuation to the Zone



AFIP CA-45-736, CA-45-738

FIGURE 89.—Traumatic amputation of right leg, compound fracture of both bones of left leg, caused by land-mine explosion. A. Appearance of wounds in evacuation hospital. B. Anteroposterior roentgenograms of both legs before initial surgery. C. Transportation splinting after initial surgery, which included completion of the traumatic amputation of the right lower extremity by the open circular technique. After the ace adherent used to fix the stockinet to the skin has dried, elastic traction to the wire ladder splint will be provided.

of Interior. Twenty-one of the stumps were covered by skin grafts after fixation of the tissues had been obtained and skin traction was no longer effective. Healing was regarded as satisfactory in all of these cases.

At the second hospital, 39 of 251 amputation stumps (15.5 percent) were sutured, 18 before the 12th day after wounding and 21 after that time. Wound healing was regarded as satisfactory in all of these cases.

At the third hospital, delayed primary suture or skin grafting was carried out in 63 of 129 major amputations (49 percent). The results are unknown in 28 of the 63 cases. In 29 of the other 35 cases, healing was known to be complete; 27 of the 35 were managed by delayed primary suture. It should be understood that failure of healing in the remaining six cases did not imply infection but merely that granulating areas, most of which were inconsequential, were present. The hospital records were incomplete in the 28 cases in which

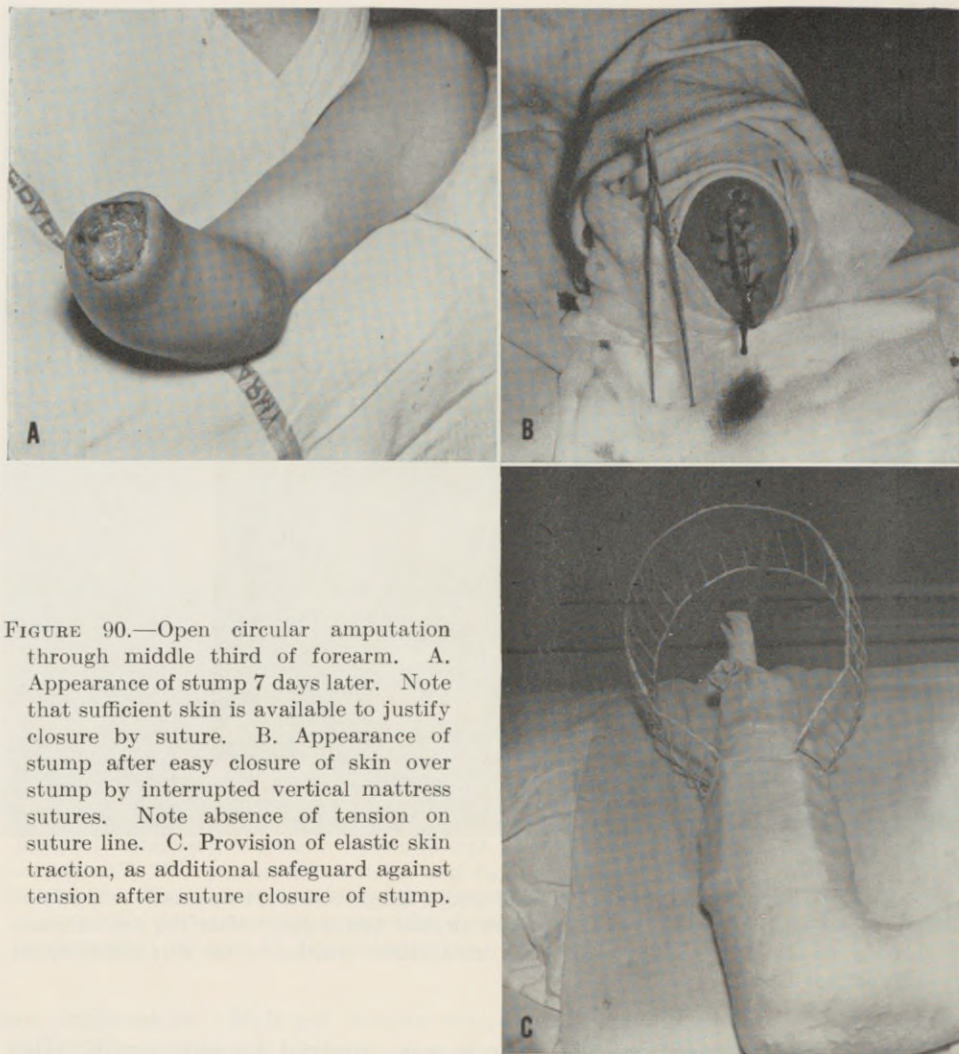


FIGURE 90.—Open circular amputation through middle third of forearm. A. Appearance of stump 7 days later. Note that sufficient skin is available to justify closure by suture. B. Appearance of stump after easy closure of skin over stump by interrupted vertical mattress sutures. Note absence of tension on suture line. C. Provision of elastic skin traction, as additional safeguard against tension after suture closure of stump.

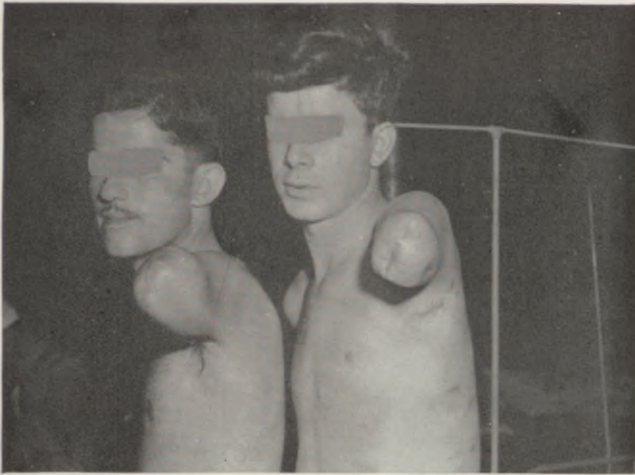
AFIP CA-44-540

the results are listed as unknown, but such data as could be secured suggested that healing was also likely to be satisfactory in most of this group.

Whenever the stump was closed, skin traction was maintained for 7 to 10 days after amputation, in order to reduce tension on the suture line.

An important point about the cases just discussed and about the other cases in the theater in which delayed primary suture was employed is that there was no known fatality in any of the series. No instance of clostridial myositis or other serious infection was reported, and there was no reported reamputation.

Even though the end results are unknown in so many of the cases in which reparative surgery was employed, the facts which have just been stated are



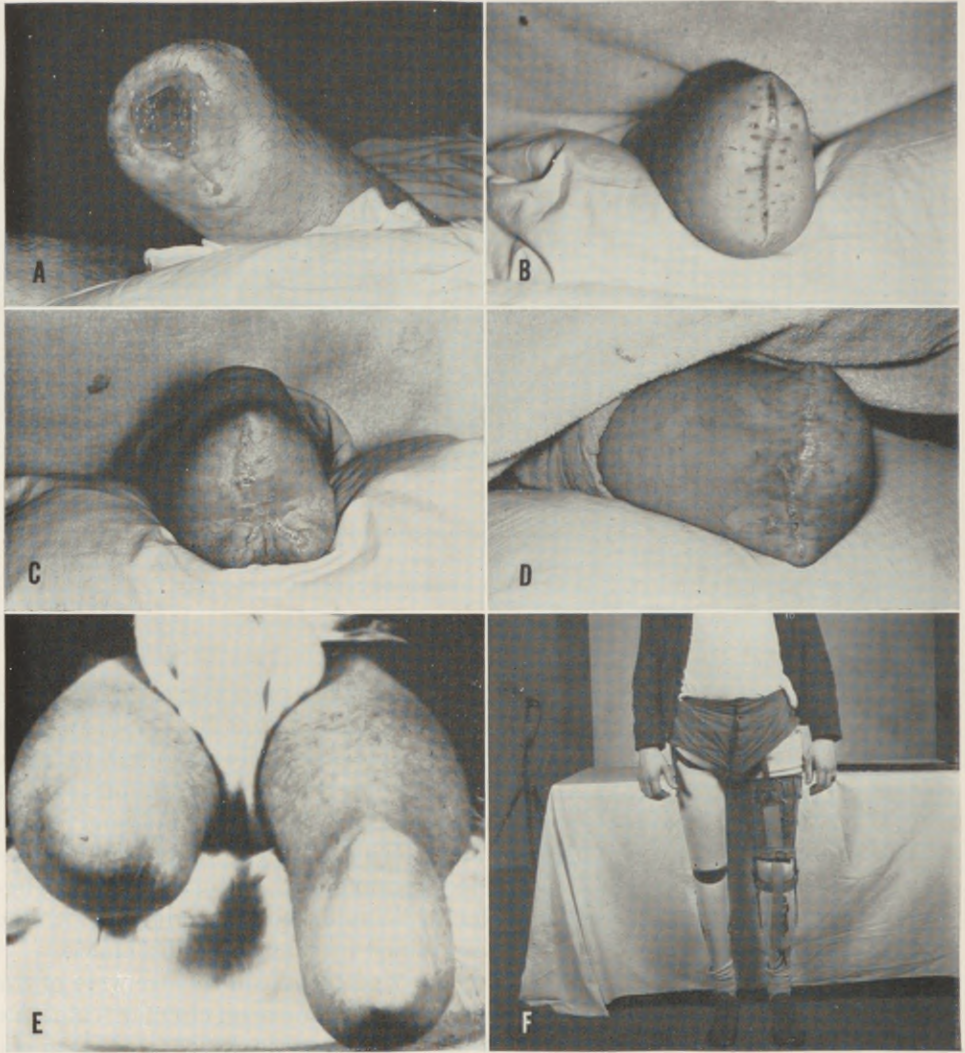
AFIP CA-44-543

FIGURE 91.—Healed stumps $3\frac{1}{2}$ weeks after amputation by open circular technique. Both patients had sufficient skin available for closure of the wound at reparative surgery 6 days later.

significant. The good results and, more important, the absence of fatalities and of invasive infections, were accomplished under a definite handicap, that the stump after a circular amputation is not plastically adapted to early closure of the skin and soft tissues by suture. For a fair test of the program, it would have been necessary to preserve normal skin, in the form of short flaps, when the initial operation was performed. This was not permitted. Moreover, as already mentioned, the specified technique of amputation not infrequently required the deliberate sacrifice of normal skin extending below the level of the saw line which had been determined by trauma to the bone.

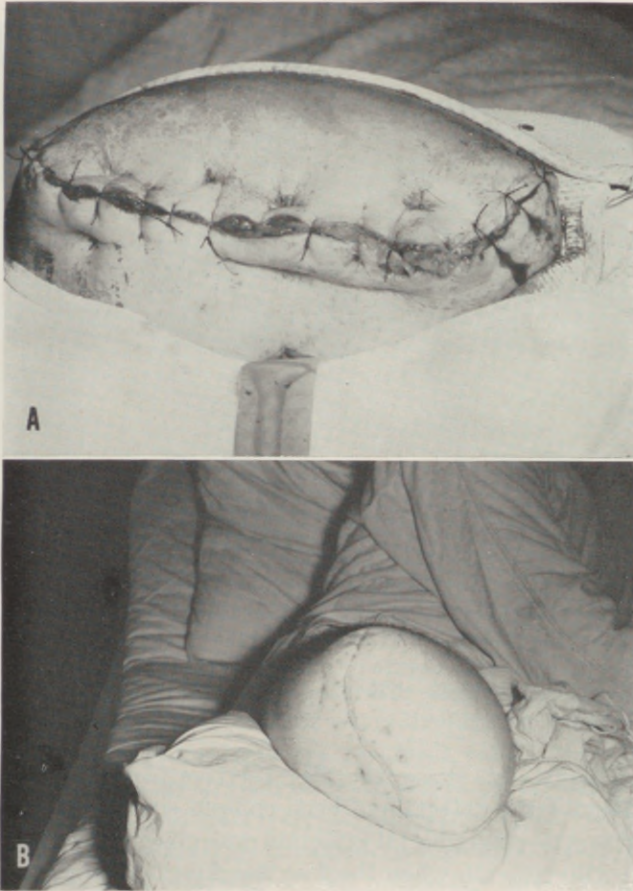
For these reasons, many surgeons in the Mediterranean theatre were of the opinion that the directive for routine amputation by the open circular technique might well have been somewhat modified. There was no desire to shorten the bone in order to permit the fashioning of flaps. It was merely desired to preserve as flaps all viable skin and soft parts, to facilitate early staged repair without tension.

Traction during evacuation.—Early in the war, the skin traction secured with adhesive tape and the Army half-ring or full-ring hinged splint proved unsatisfactory for transportation. Universal adoption of the banjo traction cast, with stockinet and skin adherent (p. 25), greatly improved the situation. Traction was examined just before the casualty was evacuated and was re-applied if necessary. The apparatus also had to be checked at regular intervals during the course of transportation and readjusted if it became displaced. Priority air evacuation to the Zone of Interior was provided for amputees as soon as they became transportable.



AFIP CA-44-539, CA-44-538; U. S. Army photos

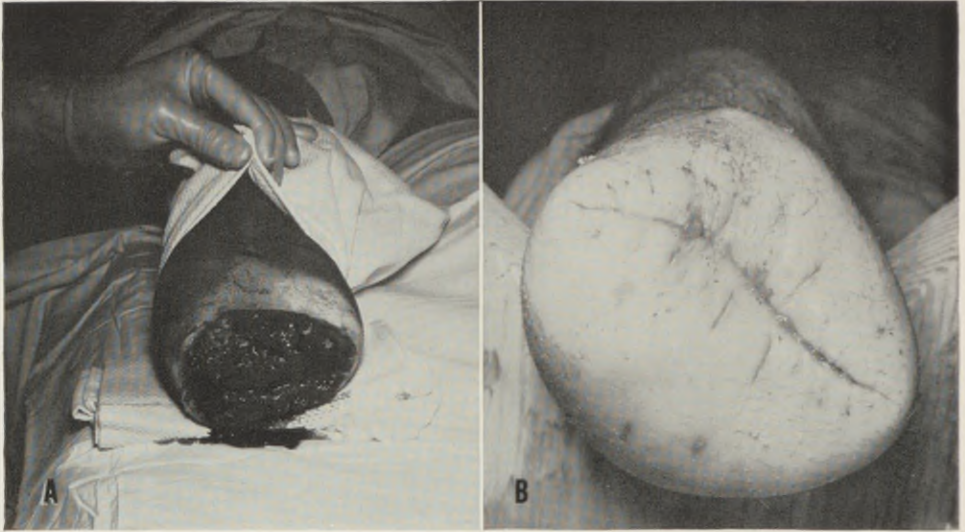
FIGURE 92.—Closure of amputation stumps. The 2 soldiers whose 4 amputated lower extremities are shown in these illustrations sustained their injuries at the same time, from the same shell, while they were in the same foxhole. A. Appearance of granulating stump of upper third of left leg 5 weeks after amputation. Skin traction had been maintained since operation. B. Healed stump of mid third of right leg in same patient shown 5 weeks after amputation and about 2 weeks after suture. C. Healed stump of upper third of left leg in second patient 1 month after suture. D. Healed stump of right thigh in same patient 1 month after suture. E. Stumps of same patient after revision and conditioning for prostheses in amputation center in Zone of Interior. F. Rehabilitated patient shown in views C, D, and E after fitting of prostheses.



AFIP CA-44-500, CA-44-542

FIGURE 93.—Closure of amputation stump. A. Closed stump of thigh 6 days after amputation by open circular technique and application of skin traction. B. Completely healed stump 26 days after closure.

Revision of the stump.—It is known that revision of the amputation stump was necessary in the Zone of Interior in 95 percent or more of all amputations. Whether a wider use of closure of the stump by reparative surgery would have reduced this proportion substantially is a matter of speculation. A reduction of any consequence might not have been achieved. Revision of the stump before the fitting of the prosthesis might still have been desirable. The objective of overseas surgery, to accomplish a healed wound before evacuation of the patient to the Zone of Interior, would, however, have been achieved to a greater degree than was accomplished under the directives in effect.



AFIP CA-44-360, CA-44-428

FIGURE 94.—Closure of amputation stump. A. Appearance of stump of right leg after amputation just below the middle. The stump had been in traction for 4 weeks. B. Appearance of stump 16 days after closure by suture. Note that healing was complete except for two small granulating areas. There was no sinus formation.

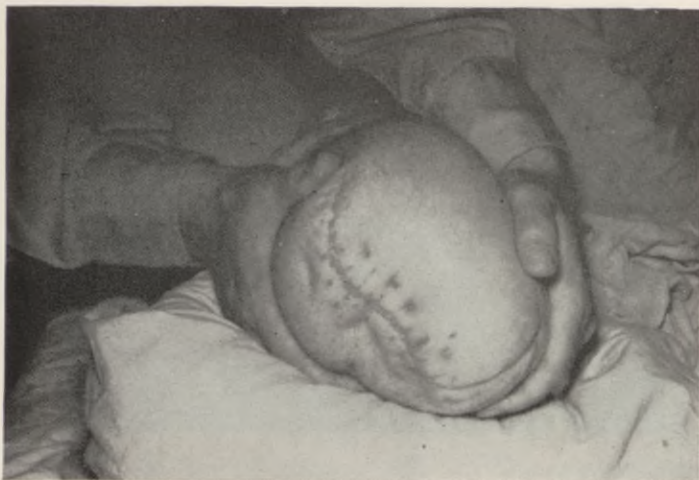It seemed likely that there would be relative technical advantages at the revision operation if the defects had been completely healed for several weeks; if scar formation was negligible; if infection was absent; and if skin was ample, in comparison with revision when the scar was firm and when granulation areas were present. The crucial test would have been in revision of amputations at critical levels in the lower femur and upper tibia, when further sacrifice of bone length was undesirable but would have been unavoidable if the end of the stump was covered with scar tissue and if normal skin was not available.

ANALYSIS OF CASES

The data discussed in the next several pages are derived from the following sources:

1. Two hundred and eighty-three major amputations performed on 271 United States Army casualties in 1943, and 1,096 major amputations performed on 1,000 United States Army casualties in 1944-45, a total of 1,379 amputations performed upon 1,271 casualties.

These cases were secured, without selection, from the proceedings of hospital disposition boards for the years in question. Since disposition boards are created only in fixed hospitals, it is obvious that the cases concern only those amputees who had survived the shock of wounding and who had recovered sufficiently to become transportable to the rear. There were no fatalities in



U. S. Army photo

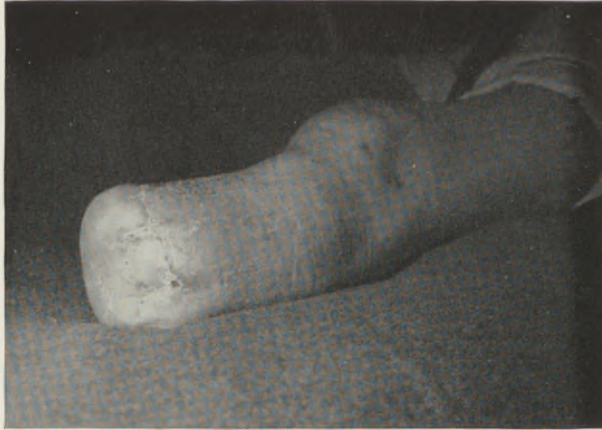FIGURE 95.—Amputation by open-flap technique, with closure of flaps without tension 6 days later, at reparative surgery. Appearance of stump showing complete healing 23 days after wounding.

either the 1943 or the 1944-45 series. Deaths of amputees in fixed hospitals were infrequent, and fatal cases did not reach disposition boards.

2. After captured German military hospitals came under control of the Surgeon, Fifth U.S. Army, at the end of hostilities in the Mediterranean theater in 1945, 1,389 major amputations were performed on 1,332 German prisoners. As soon thereafter as practical, all prisoners of war who required medical care were collected in a large hospital center previously established by German forces in Merano, Italy. The maximum enemy patient census during the period of United States Army responsibility for medical care was in the neighborhood of 20,000.

The statistics analyzed do not include amputations of the hand distal to the wrist joint or amputations of the foot distal to the junction of the middle and distal thirds of the metatarsal bones. Disarticulations at the ankle, knee, wrist, and elbow were tabulated as proximal amputations, while disarticulations at the shoulder were tabulated as amputations of the upper arm. As in all collected series, many items are lacking in many cases, particularly in the prisoner-of-war series and, to a lesser extent, in the series from 1943 disposition-board proceedings.

Site of amputation.—The site of amputation in both United States and German casualties was usually the lower extremity (tables 28 and 29). The large number of amputations of the lower extremity among United States troops in 1944-45 is to be explained by the increasing use of land mines by the enemy as they retreated up the Italian peninsula in the last year of the war. In the 1943 series (table 30), land mines accounted for about 15 percent of all amputations, while in 1944-45 they accounted for almost 36 percent.



AFIP Fd-45-17

FIGURE 96.—Amputation through leg near site of election, with preservation of long posterior viable flap of skin. Seven days after amputation, the flap was sutured to the anterior skin margin. Healed stump 24 days after wounding.

This same explanation may hold for the slightly higher proportion of lower-extremity amputations in United States as compared with German troops. The land mines which the Germans used so extensively as defensive weapons often played havoc with United States troops, but some Germans were also injured in their own minefields (table 31).

The 1,096 amputations performed on 1,000 United States soldiers in 1944-45 represented 927 amputations of single limbs, 84.6 percent of the total number. There were 73 double amputations (146 limbs) and 23 second-level amputations (reamputations). In the German series of 1,389 amputations, there were only 57 double amputations (114 limbs), representing 4.1 percent of the total number. In addition, one German soldier suffered the loss of three limbs; both forearms had to be amputated, and one leg was amputated at the thigh. There was no similar instance in the United States Army series, and there were no quadruple amputations in either series.

Numerous other serious injuries complicated the wounds for which amputation was required in the 1944-45 United States Army series (table 32). The majority of injuries, fortunately, were limited to the skeletal system and could be treated by ordinary methods of fracture management. In 12 instances, the additional fracture was in the same extremity as that in which amputation was necessary. Comparable data were not available for the 1943 United States Army series or for the prisoner-of-war series.

Causative agents.—There were only 5 amputations for disease in the combined United States Army series (table 30), 2 of them in the same patient, for trenchfoot. This is about what would be expected, since soldiers with

TABLE 28.—*Sites of amputation in 1,379 separate operations on United States Army troops*

Site of amputation	1943		1944-45	
	Amputations	Percent	Amputations	Percent
Arm:				
Upper third.....	14	43.8	¹ 47	47.0
Middle third.....	13	40.6	24	24.0
Lower third.....	5	15.6	² 29	29.0
Total.....	32	100.0	100	100.0
Forearm:				
Upper third.....	(³)	-----	16	24.6
Middle third.....	(³)	-----	17	26.2
Lower third.....	(³)	-----	⁴ 32	49.2
Total.....	48	-----	65	100.0
Thigh:				
Upper third.....	9	10.1	34	13.2
Middle third.....	28	31.5	61	23.7
Lower third.....	52	58.4	⁵ 162	63.1
Total.....	89	100.0	257	100.0
Leg:				
Upper third.....	53	46.5	118	18.5
Middle third.....	(³)	-----	157	24.6
Lower third.....	61	53.5	⁶ 363	56.9
Total.....	114	100.0	638	100.0
Foot:				
Upper third.....	(³)	-----	19	52.7
Middle third.....	(³)	-----	17	47.3
Total.....	-----	-----	36	100.0
Total, upper extremity.....	80	28.3	165	15.1
Total, lower extremity.....	203	71.7	931	84.9
Total, both extremities.....	283	100.0	1,096	100.0

¹ Including 9 amputations at the shoulder joint.

² Including 4 amputations at the elbow joint.

³ No cases in the special category or no data on breakdown of the site available.

⁴ Including 9 amputations at the wrist joint.

⁵ Including 18 amputations at the knee joint.

⁶ Including 8 amputations at the ankle joint.

TABLE 29.—*Sites of amputation in 1,389 separate operations on German prisoners of war*

Site of amputation	Amputations	Percent
Arm.....	¹ 190	13.7
Forearm ²	³ 125	9.0
Total.....	315	22.7
Thigh:		
Upper third.....	⁴ 114	8.2
Middle third.....	193	13.9
Lower third.....	⁵ 200	14.4
Total.....	507	36.5
Leg:		
Upper third.....	128	9.2
Middle third.....	175	12.6
Lower third.....	142	10.2
Total.....	445	32.0
Foot ²	122	8.8
Total, upper extremity.....	315	22.7
Total, lower extremity.....	1,074	77.3
Total, both extremities.....	1,389	100.0

¹ Including 11 disarticulations at the shoulder joint and 4 at the elbow.

² No data on breakdown of site.

³ Including 41 disarticulations at the wrist.

⁴ Including 24 disarticulations at the hip joint.

⁵ Including 79 disarticulations at the knee joint.

recognized diseases are not sent into a combat zone. There were 29 amputations for disease in the German prisoner-of-war series (table 31). No details concerning these operations were available.

In both the United States Army and the German series, the great majority of amputations were performed for trauma, and most of the trauma was battle incurred (tables 30, 31, and 33). Although the number of United States Army troops in the theater was smaller in 1943 than in 1944-45, the proportion of accidental injuries was larger (table 30), a fact which can be explained in two ways: In North Africa, where most of the early fighting occurred, supply lines were long, and extensive travel by train and motor vehicle was necessary. This was also a period of extensive training for combat, and the number of soldiers injured by accidental explosions of live ammunition might be expected to be greater than in a period of more active combat.

TABLE 30.—*Agents of wounding and causes of amputation in 1,271 United States Army troops* ¹

Agents and causes	1943		1944-45		Total	
	Cases	Percent	Cases	Percent	Cases	Percent
Wounded in action:						
Shell fragments, artillery, mortar, grenade.....	132	48.8	534	53.4	666	52.3
Mines.....	41	15.1	359	35.9	400	31.5
Small arms, machinegun, etc.....	21	7.7	36	3.6	57	4.5
Other.....	13	4.8	8	.8	21	1.7
Total.....	207	76.4	937	93.7	1,144	90.0
Accidental injuries:						
Vehicles.....	15	5.5	15	1.5	30	2.4
Explosions, live ammunition.....	19	6.9	13	1.3	32	2.5
Bullets.....	8	3.0	13	1.3	21	1.7
Train, trolley.....	7	2.6	8	.8	15	1.2
Mines.....	4	1.5	6	.6	10	.8
Machinery (crushing injuries).....	1	.4	3	.3	4	.2
Thermal burns.....			1	.1	1	.1
Other.....	9	3.3			9	.7
Total.....	63	23.2	59	5.9	122	9.6
Disease:						
Trenchfoot.....			2	.2	2	.1
Osteogenic sarcoma fibula.....			1	.1	1	.1
Thrombosis ²			1	.1	1	.1
Tuberculosis.....	1	.4			1	.1
Total.....	1	.4	4	.4	5	.4
Grand total.....	271	100.0	1,000	100.0	1,271	100.0

¹ These 1,271 troops required a total of 1,379 amputations.
² Of popliteal artery, secondary to ligation of saphenous vein.

The explanation of the slightly larger proportion of amputations caused by shell fragments and similar agents in the German prisoner-of-war series, than in the United States Army series, is probably heavier United States Army fire. The effect of land mines has already been mentioned. The larger proportion of injuries from small-arms fire in German prisoners of war is perhaps to be explained by the strafing from United States planes which the German troops suffered while they were retreating in the last months of the war.

Except for the category of trauma, all these groups are small, and the statistical differences are not significant. On the other hand, personal observa-

tions indicate that most of the explanations which have just been advanced are valid.

Indications.—When the indications for which individual amputations were performed are considered (tables 33, 34, and 35), certain differences between German and United States surgical practices suggest themselves. To consider only the operations for which indications are known in the United States Army series (table 33), 1,027 amputations—more than three-quarters of the total number—were performed for trauma, both combat connected and accidental. In the German prisoner-of-war series (table 35), the corresponding figure was 874 operations, not quite two-thirds of the total number. In the United States Army series, 195 operations (14.5 percent) were performed for

TABLE 31.—*Agents of wounding and causes of amputation in 1,332 German prisoners of war*¹

Agents and causes	Cases	Percent
Wounded in action:		
Shell fragments, artillery, mortar, grenade, bomb-----	804	60.4
Mines-----	242	18.1
Small arms, machinegun, etc-----	182	13.7
Total-----	1,228	92.2
Accidental injuries-----	48	3.6
Disease-----	29	2.2
Unknown causes-----	27	2.0
Grand total-----	1,332	100.0

¹ These troops required a total of 1,389 amputations.

TABLE 32.—*Complicating injuries in 1,000 United States Army amputees, 1944-45*

Complicating injury	Site of amputation							
	Leg	Thigh	Foot	Forearm	Arm	Leg and thigh	Both legs	Thigh and forearm
Fracture opposite extremity-----	77	22	3	2	6			
Additional fracture same extremity-----	6	1	2	1			1	¹ 1
Fracture upper extremity-----	16	10	1			1	2	
Fracture lower extremity-----				1	3			
Spine, abdomen, chest, or combined-----	12	3		2	6			
Total-----	111	36	6	6	15	1	3	1

¹ Fracture of humerus in same extremity as injury requiring amputation.

TABLE 33.—Indications for amputation in 1,344 of the 1,379 operations following wounds or injuries in United States Army troops ¹

Indication	Combat-connected				Accidental				Total	
	1943		1944-45		1943		1944-45			
	Amputations	Per cent	Amputations	Per cent	Amputations	Per cent	Amputations	Per cent	Amputations	Per cent
Trauma.....	121	64.3	803	78.2	53	80.3	50	79.4	1,027	76.4
Vascular insufficiency.....	43	22.9	131	12.8	11	16.7	10	15.9	195	14.5
Infection.....	24	12.8	93	9.0	2	3.0	3	4.7	122	9.1
Clostridial myositis.....	² (21)	-----	(61)	-----	(2)	-----	(2)	-----	(86)	-----
Other.....	(3)	-----	(32)	-----	-----	-----	(1)	-----	(36)	-----
Total.....	188	100.0	1,027	100.0	66	100.0	63	100.0	1,344	100.0

¹ Data were not available for the other 35 operations.

² Figures in parentheses are subtotals.

TABLE 34.—Indications for 843 primary and 243 secondary amputations in United States Army troops, 1944-45 ¹

Indication	Primary		Secondary		Total	
	Amputations	Percent	Amputations	Percent	Amputations	Percent
Trauma.....	² 805	74.1	44	4.0	849	78.1
Vascular insufficiency.....	35	3.2	106	9.8	141	13.0
Infection.....	3	.3	93	8.6	96	8.9
Clostridial myositis.....	³ (1)	-----	(62)	-----	(63)	-----
Other.....	(2)	-----	(31)	-----	(33)	-----
Total.....	843	77.6	243	22.4	1,086	100.0

¹ Exclusive of 4 amputations performed for disease and 6 operations in which the indications are unknown.

² Including 1 amputation for thermal burn.

³ Figures in parentheses are subtotals.

vascular insufficiency. In the German series, the number of operations performed for this reason was 82, not quite 6 percent. The differences in the proportions of cases performed on the indication of infection is striking. In the United States Army series, 122 operations, about 9 percent, were performed on this indication; in 86 instances the infection was clostridial myositis. In the German prisoner-of-war series, 403 operations, almost 30 percent of the total number, were performed for infection. All 86 primary operations performed on the indication of infection were for clostridial myositis.

TABLE 35.—Indications for 962 primary and 427 secondary amputations in German prisoners of war

Indication	Primary		Secondary		Total	
	Amputations	Percent	Amputations	Percent	Amputations	Percent
Trauma.....	874	63.0	-----	-----	874	63.0
Vascular insufficiency.....	2	.1	80	5.8	82	5.9
Infection.....	¹ 86	6.2	² 317	22.7	403	28.9
Disease.....	-----	-----	30	2.2	30	2.2
Total.....	962	69.3	427	30.7	1,389	100.0

¹ Clostridial myositis.

² Variety of infection unknown.

It should be pointed out again that vascular insufficiency was considered to be the indication for amputation in primary operations when the records indicated that the limb would have survived if the blood supply had not been interrupted. This group of operations, therefore, includes all instances of gangrene, including wet gangrene with superimposed infection, and all instances of infection in which the infection followed the interruption of a major artery.

In the United States Army series, the proportions of amputations done on various indications changed in the following manner as the war progressed:

In 1943, trauma of all kinds was responsible for 174 amputations, slightly under two-thirds of the total number of operations (283) (tables 28 and 33). In 1944-45 the proportion had risen to more than three-quarters (853 of 1,096 operations) (tables 28 and 33).

In 1943, injury to a major artery was responsible for just over 19 percent of all amputations (54 of 283) (tables 28 and 33). In 1944-45, the proportion was 12.9 percent (141 of 1,096 operations) (tables 28 and 33).

Infection was responsible for about the same proportion of amputations in both series, 9.2 percent (26 of 283 operations) (tables 28 and 33) in 1943, and 8.8 percent (96 of 1,096 operations) in 1944-45 (tables 28 and 33).

The increasing proportion of amputations in which trauma was the indication and the decreasing proportion in which vascular insufficiency was the indication may fairly be assumed to reflect the better judgment and increased skill of United States Army surgeons as their experience increased. With increased experience in the management of vascular injuries, the limb was undoubtedly saved in some of the later cases in which, if they had been observed earlier, amputation would have been performed. The decrease in this category of indications may also be attributed to better control of infectious processes after initial surgery became more competent, penicillin had become available, and the practice of liberal blood replacement had become general.

One not too speculative explanation for the disproportionately large number of amputations for infection in the German prisoner-of-war series is that the quality of United States Army medical care was better. An extremely important part of the explanation is that all of these German wounded were managed under the adverse conditions of wholesale retreat and surrender, when medical care can never be on a high professional level.

Timing.—More than three-quarters of the United States Army casualties who required amputations were operated on primarily, with trauma as the chief indication (table 34). Trauma was also the principal reason for about 20 percent of the secondary operations (44). In almost two-thirds of the secondary amputations for infection, the indication was clostridial myositis.

In the German series (table 35) the proportion of casualties operated on primarily was somewhat less than in the United States Army series (table 34), and the proportion of cases in which infection was the indication for immediate amputation was considerably larger. In the cases in which secondary amputation was performed, infection was responsible for a considerably larger proportion of cases than vascular insufficiency, which is the reverse of the situation in the United States Army series.

Multiple amputations.—In the 85 multiple amputations in the combined United States Army series (table 36), there are 8 separate combinations of operation. In 74 cases, however, the amputations were both on the lower limbs, and in all but 2 of the remaining cases one of the amputations was also on a lower limb.

TABLE 36.—Combinations of levels in 85 multiple amputations in United States Army casualties

Levels	1943	1944-45	Total
Both legs.....	7	30	37
Leg and thigh.....	3	18	21
Both thighs.....	1	12	13
Leg and foot.....		3	3
Thigh and forearm.....		4	4
Leg and forearm.....		3	3
Arm and forearm.....		2	2
Thigh and arm.....	1	1	2
Total.....	12	73	85

Primary amputations were performed on the indication of trauma in 147 of the 170 limbs, and 6 limbs were removed secondarily for the same reason. One amputation was done primarily for clostridial myositis, and seven of the secondary operations were done for this cause. All of the remaining operations were performed secondarily, 3 for other varieties of infection, 4 for gangrene following trenchfoot, and the other 2 for vascular insufficiency.

In the German prisoner-of-war series, the indications for the 114 multiple amputations were trauma in 68 limbs, infection in 28, and vascular insufficiency in 7. The causes in the remaining 11 operations are unknown.

Seventy-six of the eighty-five double amputations in the United States Army series (90 percent) were required by combat-incurred trauma, shell fragments and land mines being responsible in all but one case. The comparable figures for the German series of multiple amputations are 54 cases (94.7 percent) with shell fragments (30) and land mines (22) responsible for all but 2 of the cases.

Reamputation.—Reamputation was necessary at a higher level in only 23 of the 1,096 amputations performed in United States Army hospitals in 1944-45. All but two were on the lower extremity. The majority of the secondary operations were for infection (16), chiefly clostridial myositis (13), which was usually superimposed upon the trauma for which the first amputation had been done. The original trauma had been caused by mines in 15 cases and by shell fragments in 7. In the remaining case the trauma was accidental.

Details on reamputations are not available in the 1943 United States series nor in the prisoner-of-war series.

CHAPTER X

Noncombat Orthopedic Lesions¹

In addition to wounds involving the bones and joints, patients in the hospitals of the Mediterranean Theater of Operations presented, almost from the day it came into existence as the North African Theater of Operations, two other groups of orthopedic lesions.²

The first of these lesions was the simple type of fracture which resulted from the many kinds of trauma to which a soldier in an overseas theater was subjected behind the fighting lines. These injuries were sustained, for the most part, in the performance of such tasks as are commonly a part of noncombat activities. A considerable number were sustained during athletic contests and other recreational activities.

This type of fracture needs no extended discussion. Most of them were treated by simple manipulation and plaster immobilization, supplemented, occasionally, by simple forms of traction. Open reduction and internal fixation were performed on the same indications as in civilian practice. The attitude was conservative, and these special techniques were not resorted to unless adequate reduction had not been accomplished by simpler measures.

The second group of non-combat-incurred lesions comprised the orthopedic disabilities ordinarily seen in civilian practice, including painful feet, painful backs, painful and unstable knees, recurrent dislocations of the shoulder, and old fractures of the carpal scaphoid bone. Some of these conditions were known to exist before the soldiers were inducted. They sometimes caused only minimal disability during the training period in the Zone of Interior but produced such disability under conditions of combat that the soldiers frequently reported on sick call and had to be hospitalized for investigation, evaluation, and treatment. In some cases, the disability was of such long standing and so evident that one wondered how the patients had ever been classified for overseas duty. These lesions were of military importance because of the disability which they caused, their chronic and recurrent character, and the two serious consequences to which they gave rise in an active theater of combat; namely, loss of manpower and utilization of hospital-bed space and of other medical facilities.

Early in the North African experience, it was not at all unusual for soldiers hospitalized with these complaints to state that they had suffered considerable

¹ The material in this chapter is largely based on a survey made by Maj. Newton C. Mead, MC, 12th General Hospital, after V-E Day.

² The injuries described in this chapter were sometimes produced during combat, as the result of falls and other accidents, but they were not produced by missiles, and for convenience of reference they are therefore described as noncombat lesions.

difficulty from them during training but that appropriate therapy had permitted them to continue on duty. Sometimes a soldier would state that he had duly reported his trouble when he was given his final physical examination before embarking for overseas, and that the existence of the condition had been verified, but that the examining officer had said that he would be reclassified overseas for limited duty. Many of these men were never of combat usefulness. Some of them were of limited usefulness even on limited duty. A few were promptly returned to the United States, as being completely unfit for any sort of duty in an overseas theater. There are no supporting statistical data for any of these statements, but they are substantiated by the observations of many of the orthopedic surgeons who served in the theater.

The early confusion in respect to these noncombat orthopedic conditions was probably unavoidable. As the war progressed, the situation was gradually rectified and in the last year only a small percentage of the soldiers who reached the Mediterranean theater had conditions of sufficient seriousness to warrant classification to limited duty. If a policy of similar strictness had been in effect throughout the war and if these disabilities had been diagnosed and properly evaluated in the Zone of Interior, time, effort, and expense would have been saved, and badly needed hospital-bed space would have been conserved overseas.

GENERAL PRINCIPLES OF MANAGEMENT

Soldiers with the noncombat type of orthopedic lesions were more closely studied in fixed hospitals. When the difficulties became apparent in forward areas, every effort was made to screen out those whose complaints were trivial and functional and to return them promptly to duty. Under the stress of a heavy combat load, however, this was not always possible, for these complaints frequently required a great deal of time for investigation and evaluation. As a result, the majority of the patients had to be transferred back to fixed hospitals. This was unfortunate. Experience in all fields throughout the war clearly indicated that the farther to the rear soldiers were evacuated, the more difficult it was to return them to combat duty.

As this statement suggests, the psychogenic factor played an important part in these complaints and greatly increased the problems of management and disposition. This group of patients did not consist of malingerers in the ordinary sense of the term. These men honestly regarded their disabilities as sufficiently serious to prohibit their participation in heavy duty and in combat. Liaison between orthopedic and neuropsychiatric medical officers was obviously called for and proved very profitable, though it was not until the winter of 1945 that concrete steps were taken to stop the practice of sending numbers of these soldiers from forward areas to fixed hospitals. At this time, as part of the neuropsychiatric program in the theater, a reinforced field hospital platoon was designated and set up under the supervision of Maj. (later Lt. Col.) Calvin S. Drayer, MC, consultant in neuropsychiatry,

Office of the Surgeon, Fifth U.S. Army, close to the division area, to receive patients with chronic or vague complaints directly from clearing stations. The professional staff of this field hospital platoon consisted of various specialists, among them an orthopedic surgeon. All were men of judgment and experience. When soldiers complaining of orthopedic conditions were admitted to this platoon, they were quickly but thoroughly studied and screened. When observation seemed to establish or made it seem likely that there was ground for the soldier's complaints, he was evacuated to a fixed hospital in the rear for further investigation and possibly for treatment. Otherwise, he was promptly sent back to the line. This plan of management made it possible to return a large number of soldiers to combat status without their ever leaving the forward area.

At the fixed hospital, the emphasis was always upon rapid evaluation of the complaints of these patients, with an equally prompt decision as to their disposition. In civilian practice, the emphasis in such conditions is upon precise diagnosis and the institution of therapy. Only later is any prognosis made as to the duration of temporary disability or the extent of permanent disability. In overseas hospitals, the first consideration was whether the complaints had a physical basis and, if so, whether it was of sufficient seriousness to prevent the soldier's immediate return to a duty status. If the answer was "No," the surgeon's first duty was to discuss his condition with the patient and to make it clear to him that his disability was not sufficient to prevent him from performing his military duties. The question at issue was whether he could perform them adequately. If it was thought that he could, he was promptly returned to combat duty.

If a clear-cut decision could not be arrived at promptly, a detailed routine of investigation was begun, including roentgenologic examination and laboratory studies. While it was in progress, physical therapy was often instituted, in an effort to relieve symptoms and shorten the period of hospitalization. When the diagnostic routine was completed, the patient was again evaluated, and disposition was accomplished, the preference being given to duty status whenever it was felt that he could assume the necessary duties and could continue to perform them. Patients who could not be returned to duty at once were kept in the hospital and were treated as intensively as possible. Reevaluation was carried out after the lapse of 10 days to 2 weeks, and final disposition was then accomplished. A soldier who could not be rehabilitated within this period was unlikely to be of further combat usefulness.

The essential factor in this routine of evaluation, treatment, and disposition was the promptness with which it was carried out. The whole military experience showed that, in such conditions as these, prolonged hospitalization and treatment were seldom more effective in salvaging a soldier for duty than were shorter periods. The more prolonged the hospitalization, in fact, the more difficult it was to return soldiers to duty status, whether the condition was acute, chronic, or recurrent.

The soldier who really needed treatment was given the benefit of all the standard treatment appropriate to his condition, but he was disposed of just as promptly as good orthopedic practices permitted. The first and paramount mission of the Medical Corps is to maintain the fighting strength of the Army. This objective required the salvage of all possible manpower, together with the most efficient possible use of all hospital and other medical facilities, including the time of medical officers. Undoubtedly, in an occasional instance, some injustice was done, and soldiers were returned to active duty too soon. This worked no individual hardship, however, for those who had real complaints promptly reported to sick call again. The general policy was considered highly effective. It provided full medical care for those who really needed it, while at the same time it reduced the days lost from duty for soldiers who had mild forms of orthopedic lesions and who really needed no hospitalization and no treatment beyond explanation and reassurance.

THE MANAGEMENT OF PAINFUL BACKS AND FEET

Lesions of the back and the feet were the two non-combat-connected orthopedic complaints most commonly encountered in overseas theaters. They accounted for a considerable loss of manpower but need no extended discussion because, in spite of their importance, no new techniques were developed for their management and no special studies were made from which conclusions concerning them could be drawn.

Painful Backs

When a soldier complaining of back pain was admitted to a general or station hospital, the routine was (1) to take a careful history, with particular reference to the time and circumstances of the first appearance of the disability; (2) to make a physical examination; and (3) to obtain anteroposterior, lateral, and oblique roentgenograms of the lumbar and sacral spine. In many cases in which there was organic reason for the complaint, the chief diagnostic evidence was roentgenologic. Mild arthritic changes were not considered disabling in themselves. Moderate or extensive changes were considered confirmatory of the clinical complaints, and treatment was promptly instituted. If the symptoms were not promptly relieved, possible transfer to limited-duty status was considered. Congenital anomalies, other than spondylolisthesis or evidence of extensive structural weakness, were not considered disabling in themselves. Bone tumors and destructive lesions were practically always regarded as justification for evacuation to the Zone of Interior for continued hospitalization and definitive treatment. A clinical syndrome suggesting rupture of the intervertebral disk was a special problem, which is discussed in the neurosurgical volume of this series.

Treatment for painful backs was usually limited to bed rest on a hard bed, with movement minimized by the use of a board between the mattress and

the springs, and physical therapy consisting of infrared heat and massage. Simple braces and supporting canvas belts were sometimes made in the hospital braceshops. They were useful for soldiers who had been on limited duty or who were being assigned to it, but these devices were never effective in returning a soldier with a painful back to combat duty.

In the majority of chronic complaints referable to the back, maximum symptomatic improvement was usually obtained in about 2 weeks, and with few exceptions it was possible to determine by this time whether disposition should be to combat duty or to a limited-duty status. In acute back strains, a longer period of treatment was often justified, but maximum symptomatic improvement was usually obtained by the end of the third or fourth week, and disposition could be made with assurance by that time.

Painful Feet

Painful feet were more of a problem than painful backs. Soldiers with symptomatic flat feet who were admitted to clinics or hospitals raised questions of disposition rather than treatment. Such measures as rest and physical therapy were of no value. Arch supports did not reach the Mediterranean theater until early in 1944. They provided some relief for soldiers on duty in rear areas but appeared to be of little value in returning to combat duty soldiers who complained of their feet. There were numerous complaints about these supports, the most frequent being that they were too high in the longitudinal arch and often caused pain from excessive pressure. It was frequently possible to remedy these defects in the braceshops of general hospitals, but the general impression was that the use of arch supports was of limited value in the management of painful feet in a theater of operations.

Surgical intervention for hallux valgus was seldom undertaken overseas. The operation only occasionally made possible the return of a patient to combat duty, and after the first months of the war it became the rule to assign patients with this condition to limited duty if they proved unfit for combat and to make the disposition without surgery.

Operation on a single hammertoe on an otherwise normal or almost normal foot was frequently carried out by standard techniques. In most such cases, the soldier could be returned to full duty. Operation was seldom undertaken for hammertoes associated with a flat metatarsal arch and with dorsiflexion of all the toes. Experience promptly showed that surgery seldom permitted full-duty disposition and that the wisest plan was to assign the soldier to limited duty without surgery.

March fractures accounted for a certain proportion of painful feet observed overseas, though most such fractures occurred during training in the Zone of Interior. This subject is discussed in detail elsewhere in this series. It might be said here that while weight bearing was not permitted if it was painful, there was an increasing tendency overseas to omit prolonged immobilization from the routine of treatment. In some instances, a plaster boot was worn for a few weeks, but many times only a metatarsal pad was applied.

SURVEYS OF MANAGEMENT OF NONCOMBAT ORTHOPEDIC LESIONS

Surveys were carried out in the Mediterranean theater for three special types of injuries; namely, recurrent disabilities of the knee, including injuries of the semilunar cartilage and loose bodies in the joint (osteochondritis dissecans); recurrent dislocations of the shoulder; and simple fractures of the carpal scaphoid bone. The purpose of each of these investigations was the same—to determine what success had been achieved in restoring to a useful duty status the patients who had been subjected to surgery. The cost of treatment to the Army, in terms of utilization of hospital days, was investigated in each survey.

An attempt was made to follow up patients who had received surgical treatment for meniscus injuries, in order to determine, at least by inference, how they had stood up under the duties to which they were assigned. Results in other lesions were evaluated simply on the basis of hospital disposition. The classification and disposition of patients employed in the Mediterranean theater in 1944 and 1945 were as follows:

Category A covered soldiers whose physical condition was considered as qualifying them to perform full military duty, without any restrictions. Those who required a preliminary period of conditioning, up to 6 weeks, before being returned to full-duty assignments, were temporarily classified as A₂.

Category B covered soldiers who were capable of limited service, according to the degree and manner specified by the hospital disposition board. This classification was frequently invalidated by failure of the units to which they were assigned to observe the specifications. The subcategory B temporary covered soldiers who were expected to prove eligible, after a certain period of conditioning, for reclassification to Category A. Only disposition boards in general hospitals were authorized to place officers in class B.

Category C covered soldiers who could not be restored to any duty status within the holding period permitted in the theater. These patients were evacuated to the Zone of Interior. Disposition to category C was authorized only in general hospitals or in station hospitals acting in the capacity of general hospitals.

Soldiers who were classified to full duty in the Army had to be able to perform full duty. In the very nature of ground combat, there could be no relief from certain strenuous duties and no halfway performance of them. In the Army Air Forces, the situation, for obvious reasons, was rather different, and disposition in hospitals devoted exclusively or almost exclusively to Army Air Forces personnel could be carried out by somewhat different criteria. For one thing, patients returned to duty with the Air Forces were quartered in relatively comfortable barracks, easily accessible to the hospital, in sharp contrast to the foxholes and pup tents which were usually the lot of infantrymen. The situation was roughly similar to that of a civilian industrial community. Hospitals supporting the Army Air Forces were not usually in the direct chain of evacuation from the front lines and were therefore not constantly crowded with battle casualties, as were the other hospitals included in

these surveys. Their work, for this reason, could be conducted somewhat along the lines of a civilian hospital.

There were also other differences. The Army Air Forces had its own flight surgeons, whose responsibilities were entirely toward its own personnel. These surgeons had opportunities to become acquainted with the men, they were familiar with their duties, and they could control and supervise their activities during periods of rehabilitation. Because they were in a position to judge what duty a patient just released from the hospital was capable of assuming, disposition of Army Air Forces personnel was often made to class A duty, with the tacit understanding that there would be a period of conditioning and rehabilitation under the flight surgeon's supervision before full duty was actually attempted. This arrangement eliminated the period of reconditioning at a replacement center which ground troops often had to undergo and which was always unpopular. Furthermore, there was never any necessity in the Army Air Forces for heavy marching or for ground operations over unfavorable terrain. Finally, although precise evaluation is impossible, the morale factor undoubtedly played an important part in the generally better results secured in elective surgery in the Army Air Forces.

In 1944, the Army Air Forces discontinued class B duty and placed personnel returning to duty in either class A or class C. This was a feasible plan in that branch, whose duties, while exacting and hazardous, were very different from the duties of ground troops. Many patients who were placed in class A in the Army Air Forces would have been placed by practical necessity in class B had they belonged to other branches of the service.

INTERNAL DERANGEMENTS OF THE KNEE

1943 Survey

Early in the North African campaign, the management of internal derangements of the knee joint in a theater of operations was recognized by certain orthopedic surgeons as a problem which needed investigation. An investigation of a series of operations performed before 15 July 1943 was therefore undertaken (by Maj. Oscar P. Hampton, Jr., MC) in 2 general and 6 station hospitals in the Mediterranean Base section. Special attention was paid to the followup, which was concluded as of 1 November 1943. Whenever possible, the patients were traced to their current assignment.

This investigation covered 150 arthrotomies of the knee joint, 140 undertaken for lesions of the semilunar cartilages and 10 on the indication of osteochondritis dissecans. The medial cartilage was removed in 120 cases, the lateral cartilage in 12, and both cartilages in 4. In four cases, although the joint was opened, neither cartilage was removed. These 150 patients spent an average of 72 days in the hospital. At the time the survey was concluded, five were still hospitalized, the average period of hospitalization to that date being 95 days.

The results of the remaining 145 arthrotomies were as follows:

Returned to full duty after spending an average of 53 days in the hospital, 67 patients (46 percent).

Returned to limited duty after spending an average of 89 days in the hospital, 56 patients (39 percent).

Evacuated to the Zone of Interior after spending an average of 83 days in the hospital, 22 patients (15 percent).

Of the 84 combat troops included in the 150 cases, 28 were returned to full duty and 42 to limited duty, 12 were evacuated to the Zone of Interior, and 2 were still hospitalized at the conclusion of the survey.

These figures require further analysis. They show, first of all, that, after the expenditure of an average of 72 days of hospitalization per patient, there was less than an even chance of restoring the soldier to combat duty or, if he had been on limited duty, of making him fit for combat duty. They show, next, that 2 of every 3 patients who had been combat troops could not be returned to their former status.

Finally, the hospital-stay days require analysis. The average period of hospitalization for the whole series, 72 days, is low because it includes a number of extremely early dispositions. One combat soldier, for instance, was returned to his infantry division on the eighth postoperative day, and 10 others were returned in less than 30 days. Obviously, these dispositions cannot be accepted at their face value; any duty disposition made within less than 6 or 8 weeks after arthrotomy must have necessitated some restriction of duty. In a number of the hospitals surveyed, other patients were observed whose disposition had been effected within unusually short periods and who had had to be hospitalized for reclassification.

In the light of these facts, it was concluded that arthrotomy for a torn semilunar cartilage in an overseas theater of operations was often of very doubtful value. If a soldier had a disability of such seriousness that he could not perform combat duties, it was probably more sensible to downgrade him to limited duty, without operation, than to spend the time and effort and utilize the hospital-bed space required to restore him to full duty, since the chances of success were no more than 50 percent and since the chances of his being able to perform full duty further reduced the percentage.

Establishment of Theater Policy

Circular Letter No. 48, Office of the Surgeon, North African Theater of Operations, published 18 November 1943,³ took full cognizance of these facts. Its substance was as follows:

1. Operations for repair or reconstruction of the collateral or cruciate ligaments of the knee or for recurrent dislocation of the patella were forbidden.

³ See appendix, pp. 312-316.

2. Excision of a semilunar cartilage or of joint mice was permitted, but only in selected cases, in which there had been careful evaluation of the patient's age; the findings on roentgenologic examination; the relative stability of the joint; and, most important of all, the soldier's mental outlook.

3. Operation was not to be performed for primary injuries of the semilunar cartilage unless the knee was locked and could not be unlocked either by gentle manipulation or by skin traction for 5 or 6 days. In all other cases, treatment was to be limited to pressure support, rest, graduated to protected weight bearing and then full weight bearing, and carefully supervised quadriceps exercises for 2 to 10 weeks. These soldiers were to be returned to duty as soon as symptomatic relief was obtained.

4. Arthrotomy was to be performed only for (1) persistently locked knees and (2) unlocked knees if the disability made it impossible for the soldiers to perform noncombat duty. The latter indication was to be employed only in exceptional cases.

5. Soldiers with recurrent disability in which the knee was not locked or in which it could be unlocked by conservative management were to be returned to duty. If, however, the total disability in any calendar year exceeded 90 days, they were to be returned to the Zone of Interior.

6. Operations for the removal of a cartilage from each knee or for the removal of both cartilages from one knee were to be performed only on the written recommendation of a disposition board in a general hospital.

7. Elective arthrotomy was to be performed only on the orthopedic services of general hospitals. The patient was to be held, for a minimum of 6 weeks in the hospital in which the operation was performed, to permit the operating surgeon to supervise the regimen of postoperative exercises and graded motion which were essential to good results. If prevailing evacuation policies did not permit holding for this length of time, the operation had to be performed in a hospital farther to the rear. After 6 weeks in a general hospital, the patient was to be transferred to a convalescent hospital for further supervision. Full instructions for the continuation of corrective exercises were to be sent with him.

The implications of these policies were perfectly clear. If a soldier with an injured meniscus or other knee disability could perform any type of duty in his present condition, he was to be placed in the appropriate classification and returned to duty. If he could not perform even limited duty satisfactorily because of frequency of recurrence of the difficulty or persistent locking of the knee, he was to be considered a possible candidate for surgery unless there were contraindications to operation. If these existed, he was to be returned to the Zone of Interior. Among these contraindications were arthritic changes of any considerable degree, definite cruciate relaxation, and age (usually over 30 years). Operation was not to be undertaken if the soldier showed any signs of hypochondriac tendencies or emotional instability. In short, all cases for surgery were to be selected on an individual basis, and no elective surgery on the knee was to be done routinely.

1944 Survey

In order to secure additional statistical data concerning the management of knee disabilities, the Surgeon, Mediterranean Theater of Operations, directed all general and station hospitals in the theater to submit specified information for 1944 for inclusion in Essential Technical Medical Data for March 1945.⁴ Similar requests were made of the 6 general and 8 station hospitals which were formerly in the Mediterranean theater but which had been sent to the European theater after the invasion of southern France. Hospitals which did not submit the data as directed were visited by Maj. Newton C. Mead, MC, on the order of the Surgeon, Mediterranean Theater of Operations, in the summer of 1945, after the fighting had ended, in order to secure the required statistics.

A direct followup of these patients would not have been practical, but an indirect followup was possible. The Central Postal Directory Service supplied their current Army or civilian addresses, with the dates of transfer, and also supplied information concerning the dates of transfer to other theaters or of evacuation to the Zone of Interior. If the soldier had been sent to the Zone of Interior, it was frequently possible to determine whether he had been evacuated from a hospital, sent home on furlough, or assigned to new duty. These data permitted reasonable assumptions as to the type of duty performed since operation and, in many cases, based on the length of time spent on each assignment, permitted assumptions as to the efficiency of his performance.

The reports of the Adjutant General's Office on theater strength and on the number of weekly admissions for injuries provided background material against which the importance of injuries of the meniscus could be assessed.

Material from the 26th General Hospital (129 cases) was analyzed separately. This hospital supported the Army Air Forces, and such hospitals, as already pointed out, occupied a somewhat special position.

Essential data.—In the 14 general and 22 station hospitals of the Mediterranean theater which were surveyed by the plan just described, there were 1,527 admissions for injuries of the meniscus during 1944. Elimination of duplicate admissions, of cases in which the records were too fragmentary for use, and of the 129 Army Air Forces cases reduced the number to 960 cases. Six hundred and eighty-four of these nine hundred and sixty patients were treated conservatively in the theater or returned to the Zone of Interior for surgery, and 276 were submitted to arthrotomy in the theater.

The 684 patients treated conservatively spent 18,588 days in the hospital, an average of 27.2 days per soldier. Their disposition was as follows:

Discharged to category A (full military duty), after spending a total of 5,961 days, and an average of 22 days, in the hospital, 271 patients (40 percent).

Discharged to category B (limited duty), after spending a total of 9,922 days, and an average of 30.72 days, in the hospital, 323 patients (47 percent).

⁴ The data could not be secured early enough for publication in the March report and were analyzed personally later, after all the material became available.

Classified to category C (evacuation to the Zone of Interior), after spending a total of 2,705 days, and an average of 30 days, in the hospital, 90 patients (13 percent).

The 276 patients treated by arthrotomy were classified as follows on their discharge:

To category A, after spending an average of 57.2 hospital days, and an average of 46.15 postoperative days, in the hospital, 132 patients (48 percent).

To category B, after spending an average of 74.61 hospital days, and an average of 60.15 postoperative days, in the hospital, 120 patients (43 percent).

To category C and returned to the Zone of Interior, after spending an average of 86.71 hospital days, and an average of 69.79 postoperative days, in the hospital, 24 patients (9 percent).

The proportion of patients returned to category A duty after arthrotomy was substantially the same in both 1943 (46 percent) and 1944 (48 percent). The difference in those returned to category B duty in the 2 years was also not great (39 percent in 1943 and 43 percent in 1944). What is more significant is that these percentages do not differ very greatly from the percentages of patients returned to category A duty (40 percent) and category B duty (47 percent) in 1944 without operation. To express it differently, even the very careful selection of cases practiced in 1944 did not materially improve the chances of returning a soldier to useful duty in the theater after arthrotomy, while it took at least twice as long to accomplish by surgical measures substantially the same results as could be achieved without surgery.

The reduction in hospital-stay days, including postoperative-stay days, in 1944 as compared with 1943, undoubtedly reflected a better selection of cases for surgery. The averages were often considerably increased by unsuccessful attempts at conservative therapy, which in some instances lasted as long as 90 days. It is not entirely accurate to charge this time against surgical cases, but the error, such as it is, cannot be avoided. A more or less prolonged trial of conservative therapy will usually be necessary in the management of a condition so difficult to evaluate as the recurring meniscus syndrome. The decrease in hospital-stay days in 1944 was largely due to the elimination from the surgical series of patients with atrophic quadriceps muscles, relaxed collateral ligaments, and a tendency to psychoneurosis and emotional instability. These are the patients who always remain in the hospital for long periods of time after operation.

It is unfortunate that the basis of comparison and the estimation of results in these two series must be classes of disposition, but in the 1943 series no figures on actual duty performance could be secured for comparison. Furthermore, the classification to duty at the time of discharge from the hospital did not necessarily indicate the type of duty to which the soldier would be assigned when he left the replacement depot or conditioning camp.

When the 1944 survey was undertaken, there was a general feeling in the theater that the performance of the patients returned to duty—and particularly to full duty—was probably less good than the discharge classifications would

seem to imply. The attempt at followup studies in the 1944 survey was intended to settle this question by the indirect evidence of the length of time the soldier remained in the particular duty to which he had been assigned.

This information was available in 269 of the 276 cases in which arthrotomy was performed. The length of the followup ranged from less than 3 months to 9 months. Duty of less than 3 months was not regarded as evidence of satisfactory performance. On these criteria, when the investigation was concluded, 109 of the 132 troops assigned to full duty (82.6 percent) were still performing their duties satisfactorily, as were 105 of the 120 assigned to limited duty (87.5 percent). If these figures can be accepted at their face value, the results of arthrotomy in selected cases in 1944 were reasonably satisfactory.

Results of arthrotomy in the 26th General Hospital.—The 26th General Hospital, as already noted, was surveyed separately because of its predominantly air personnel. The orthopedic section of this hospital made the diagnosis of injury of the semilunar cartilage 224 times in 1944. One hundred and nineteen patients were hospitalized, of whom 65 were treated conservatively and 54 by surgery. Fifty-two of the surgical histories were sufficiently detailed for analysis.

The 65 patients treated conservatively spent an average of 15.74 days in the hospital, as compared with an average of 27.2 days for the 684 patients treated conservatively in other branches of the service. A total of 95 percent were discharged to full or limited duty (chiefly full duty) as compared with a total of 87 percent (chiefly limited duty) in ground troops.

The 52 arthrotomized patients spent an average of 42 days in the hospital and an average of 29 postoperative days, against 64 days and 52 days, respectively, for ground troops. Ninety-eight percent were discharged to full or limited duty (chiefly full duty) against 91 percent for ground troops. At the end of the survey, 76 percent of those discharged to duty were known to be performing their duties, against 71 percent for ground troops. The probable reasons for better results in elective surgery in Army Air Forces patients have already been discussed (p. 277).

Previously arthrotomized soldiers.—Seventy patients who had previously been subjected to arthrotomy were admitted to hospitals in the Mediterranean theater during 1944. It had been expected that a great deal of useful information could be obtained from this group, but the expectation was not realized. The surgery had been performed in overseas hospitals in only 16 cases, and only in these cases was it possible to learn the details of the previous operations. If, however, this small group is representative, it suggests that arthrotomy in an overseas theater is an operation of doubtful value, for only 5 of the 16 could be returned to duty after their period of hospitalization. The other 11 were sent back to the Zone of Interior, in 8 instances specifically because of unstable joints or severe synovitis.

In 19 other cases, the soldiers had demonstrated their ability to perform useful duty after surgery, at least for a certain period of time. Most of them had done full duty, for an average of 15 months. The results of surgery,

however, were not permanent. When they were discharged from the hospital on their second admissions in 1944, only 4 of the 19 could be reassigned to full duty, and 7 had to be returned to the Zone of Interior. Moreover, of the 12 assigned to some duty in the theater, only 9 were still assigned to it at the time of the followup investigation in 1945.

Comment.—Although the statistical data in this survey were disappointing, they were sufficient to indicate trends and to substantiate, in large part, clinical impressions. The important considerations of the study were as follows:

1. The frequency of these knee injuries was greater than had been realized. Statistics furnished by the Adjutant General's Office, Mediterranean Theater of Operations, indicated that on any given day in the theater 4,811 patients were hospitalized as the result of nonbattle injuries and that injuries of the meniscus were responsible for approximately 2.81 percent of these admissions. These figures took no account of the large number of patients with this type of injury who were under treatment while on a duty status in the orthopedic clinics throughout the theater. The inclusion of these figures would have increased the proportion of meniscus injuries, though by how much is not known.

2. Many of the difficulties were the result of old athletic injuries. A surprising number were blamed on obstacle courses in basic training. A good many of the more recent injuries were caused by falling or by twisting the knee on night problems or on patrols on rough or mountainous terrain. Some injuries were traced back to precipitate motions while under fire and in this sense were combat incurred. Drunkenness was an influential factor in a few cases.

3. Accurate diagnosis was often difficult because the history, sometimes deliberately and sometimes unconsciously, was colored by the soldier's desire to use the knee injury as a means of avoiding combat dangers. The symptoms of a trick knee were sufficiently well known to occasional soldiers for them to be able to recite histories which, although false, were extremely convincing. The surgeon had to keep an open mind, so that his experiences with actual malingerers and with patients who exaggerated their complaints would not lead him, unconsciously, into considering all soldiers in this unfavorable light.

4. The diagnostic problems raised by the unreliability of many histories were increased by the meager objective evidence which these patients so often presented. One of the most useful objective signs was atrophy of the quadriceps; this process tends to occur rapidly after any knee injury, and its absence always led to suspicion of the seriousness of the soldier's complaints.

5. Although roentgenograms were made routinely, they were usually negative. They were chiefly useful in ruling out chip fractures and osteochondritis dissecans.

6. Generally speaking, a patient who presented himself with a locked knee which could not be unlocked by a few days of traction became an automatic candidate for surgery. He was totally disabled, and he could become of military usefulness only when the acute condition was relieved. Manipulative reduction under anesthesia was substituted for arthrotomy if there was any

contraindication to the joint operation. If the roentgenograms revealed osteoarthritis, manipulative reduction was usually used.

The patients whose knees were either unlocked on admission or could be readily unlocked with traction sometimes told a story of recurrent locking. The problem in these cases was not one of diagnosis but one of expediency. The decision to perform operation or withhold it had to be based on the possibility of the individual soldier's future usefulness in the theater and the length of time it would take in the hospital and in rehabilitation for him to achieve a duty status. Statistics for the theater indicated that even in carefully selected cases, return to full military duty could be accomplished in less than half of all arthrotomized patients. Of the surgical cases surveyed in 1945, 82.6 percent of the 132 troops assigned to full duty were successfully performing their duties from 3 to 9 months after operation. Only 16 of the 109, however, 14.7 percent, were serving with infantry units, in which the need was greatest and combat was most arduous and most dangerous.

Routine classification for temporary limited duty for all arthrotomy cases, with special care in assignment to duty, might have been a better solution than the attempt, so soon after surgery, to distinguish between soldiers fit for full duty and those fit only for limited service. This plan would have been effective, however, only if each case could have been carefully reviewed within a minimum of 90 days by a board of medical officers well versed in knee-joint surgery. Such a policy would have resulted in shortened hospitalization and more satisfactory final disposition of these patients. Without a specially qualified disposition board, it would not have been effective, and the system employed probably gave about as good results as could have been expected.

7. The prognosis for arthrotomy for knee injuries was much less favorable in overseas hospitals than civilian experience might suggest. One reason was that the patients could not receive the close personal attention from the surgeon which is so desirable in such operations. A postoperative routine of quadriceps exercises, for instance, often had to depend for its success on such attention as overworked ward personnel could give to it; when battle casualties were numerous, attention to such refinements was necessarily scant. The chief difference between military and civilian practice was that some soldiers regarded the hospital as a haven from the dangers of battle, and their cooperation in rehabilitation exercises was a good deal less than enthusiastic.

The comparison between a football player with a knee injury and a soldier with the same type of injury, although often made, was never sound. Because athletes can return to violent activity on the football field within 6 to 8 weeks after meniscectomy, it did not follow that soldiers could return to combat duty within a similar period of time. The circumstances are widely different. The injured athlete, outside of the game, is in the hands of a trainer and has access to heat lamps, massage, and other forms of therapy. When he goes on the field, his knee is well strapped. He remains in the game for only brief periods at first and may be removed on the first indication of trouble. Even at its

roughest, a football game is divided into alternate periods of action and rest, and at the most only an hour is spent in actual play.

The lot of an infantryman is very different. He must carry heavy packs and equipment many miles over rough ground or mountainous terrain, often in darkness, often in rain, snow, or mud. He cannot, like the football player, leave the game. He must continue until his mission is accomplished, even if his knee swells and is painful. When he has an opportunity to rest, it is likely to be in a wet foxhole, often in cold and freezing weather. The commanding officer of a combat unit cannot always, like a football coach, consider his men first and the outcome of combat next. He must utilize every man at his disposal. A man unable to keep up with his comrades is a liability.

The chief fallacy of the comparison concerns morale. The football player, anxious to retain his place on the team, cooperates in every effort at rehabilitation. The infantryman has only his sense of duty to urge him back to combat. Every instinct of self-preservation makes him call attention to any symptom from his knee. It requires a man of strong character to return to combat and to stay in it in spite of a knee which swells and becomes painful when it is overtaxed. This is why such stress was put upon a favorable mental attitude as an absolute prerequisite to surgery of the knee joint in any theater of operations.

Technical considerations.—Techniques of meniscectomy were practically the same in all hospitals in the Mediterranean. Tourniquets were used universally. A straight, short incision medial or lateral to the patella was also used universally; sometimes it was curved into a J or a reverse J. Retractors were employed, of such shapes as to minimize intra-articular trauma.

An attempt was always made to remove as much of the cartilage as possible through the anterior incision. A separate posterior incision was sometimes made to insure that it had been entirely removed. The trend to total removal of the cartilage through two incisions became somewhat more marked as the war progressed. When the cartilage was entirely in the intercondylar notch or when it could be placed in it after lateral dissection, total removal was effected, for all practical purposes, through an anterior incision only. If a half inch or so was left in situ, no difficulties need be expected. When, however, the cartilage could not be displaced into the notch, it was best to make a separate incision posteriorly to remove the remaining inch or inch and a half. The majority of surgeons excised the fat pad only if it was swollen and appeared chronically inflamed. Routine removal was not practiced because postoperative effusions, which required aspiration, seemed somewhat more frequent when the pad was removed.

One hospital which used sulfanilamide powder in the joint in about half of its cases discontinued the practice when postoperative synovial thickening was found to be more frequent than in the cases in which the sulfa drug was omitted. One or two hospitals used a posterior plaster slab for a week, but pressure dressings alone were most often employed.

Preoperative and postoperative quadriceps exercises were always stressed. One or two hospitals permitted weight bearing on the second or third postoperative day and encouraged rapid return to complete ambulation. The majority of surgeons preferred to delay weight bearing until 7 to 10 days after operation and to keep the patient on crutches for the next 2 or 3 weeks. Whatever the practice, care was always taken to see that the ability to extend the knee completely was not lost.

JOINT MICE (OSTEOCHONDRITIS DISSECANS)

Loose bodies in the joint and osteochondritis dissecans are conveniently discussed together. They are related clinically and the terms were often used interchangeably on the histories examined in Mediterranean-theater hospitals. It must not be inferred, of course, that all loose bodies observed were the result of osteochondritis dissecans. The term is technically reserved for those cases in which a definite defect of the articular surface is demonstrable by roentgenograms or at operation. The defect may contain an avascular osteocartilaginous body, or the affected nodule may have been extruded into the joint cavity.

Osteocartilaginous loose bodies were not seen frequently enough in Mediterranean-theater hospitals to be regarded as a common cause of disability. They were, however, encountered often enough to warrant the adoption of a policy for their management.

Data sufficient for evaluation of the usual methods of treatment in this condition were secured from the 12th, 33d, and 45th General Hospitals. A total of 29 arthrotomies was performed for joint mice in these 3 hospitals over the same period in which about 84,500 patients were admitted for all causes. Of the 29 operations, 22 were on the knee, 4 on the elbow, and 3 on the ankle joint.

Avascular nodules were removed from craters in the femoral condyle in 4 of the 22 arthrotomies on the knee joint; the crater was then curetted, and overhanging articular cartilage was removed. Two patients were discharged to limited duty, and the other two were evacuated to the Zone of Interior. Ten of the remaining patients, who presented defects of the patella or who required no treatment of the crater, were discharged to full duty, and five others with the same conditions were discharged to limited duty. The disposition of three other patients in this category is unknown.

Three of the four patients operated on for loose bodies in the elbow joint were returned to full duty. The disposition of the fourth case is unknown. All three patients subjected to arthrotomy of the ankle joint were classified to limited duty.

Statistical conclusions would not be warranted in so small a number of cases, but discussions with many orthopedic surgeons in the Mediterranean theater permit certain generalizations. Disposition to appropriate duty without arthrotomy was recommended when the loose body was not producing

symptoms and did not change its position on repeated roentgenologic examination. This policy avoided the loss of service time and conserved hospital space and medical effort. If the symptoms were troublesome, the policy depended upon the joint affected. In a non-weight-bearing joint such as the elbow, which was otherwise adequate, the results of surgery were likely to be good and return to duty reasonably prompt. If a weight-bearing articular surface was affected, especially if the defect was large, it was unlikely that the results would be good enough and return to duty prompt enough to justify operation in an overseas theater. In any event, surgery for joint mice and osteoarthritides was permitted only by qualified orthopedic surgeons, only in general hospitals, and only after complete investigation of the patient as well as his orthopedic status.

RECURRENT DISLOCATIONS OF THE SHOULDER

The lack of uniformity in the management of recurrent dislocations of the shoulder in the hospitals of the North African theater early in the war was officially eliminated in November 1943 when Circular Letter No. 48 was issued from the Office of the Surgeon, North African Theater of Operations. A previous history of recurrent dislocation of the shoulder was not to be accepted *per se* if it rested on the soldier's testimony. Instead, diagnosis was to be made only if a history of one or more episodes, preferably with supporting roentgenologic evidence, appeared on the Army medical record. Operation was to be undertaken only with the written approval of the disposition board of a general hospital following demonstration that the disability was such as to prevent noncombat duty and then only when the soldier's age and mental attitude offered reasonable prospect of military rehabilitation.

Guided by these general instructions, an experienced surgeon was permitted to formulate his own policies of management and select such surgical techniques as he preferred.

Survey of cases.—In an effort to determine the effectiveness of this policy, a survey of the cases observed in the theater in 1944 was carried out in 1945, by the plan already described for derangements of the knee joint. The survey covered the experiences of 16 general and 25 station hospitals. Five other hospitals were not surveyed, for one reason or another, but it was not thought that the small number of patients missed would in any way alter the value of the investigation. Data were not available from all hospitals for all items desired.

In all, there were 314 admissions for this cause during 1944, 71 of which were duplicate admissions, which reduced the number of cases to 243. Thirty-eight of the 243 patients were treated by surgery and 205 by conservative measures. Operation would have been justified in almost all of these patients in civilian life, and the fact that only 15 percent were submitted to surgery indicates an extremely conservative attitude toward surgery for recurrent dislocations of the shoulder in a theater of operations.

The 205 patients treated without operation on whom information as to disposition was available spent a total of 3,566 days in the hospital, which is an average of 17.4 days. Disposition was as follows:

Discharged to full duty, after spending a total of 1,224 days, and an average of 13.02 days, in the hospital, 94 patients (46 percent).

Discharged to limited duty, after spending a total of 1,736 days, and an average of 21.17 days, in the hospital, 82 patients (40 percent).

Classified to category C, after spending a total of 606 days, and an average of 20.9 days, in the hospital, 29 patients (14 percent).

The 30 (of 38) patients treated surgically on whom information as to disposition is available spent a total of 1,874 days in the hospital, which is an average of 62.47 days. Disposition was as follows:

Discharged to full duty after spending a total of 515 days, and an average of 51.5 days, in the hospital, 10 patients.

Discharged to limited duty after spending a total of 1,359 days, and an average of 67.95 days, in the hospital, 20 patients.

There were no category C dispositions in this group. If the original category A and B dispositions could have been maintained, on which matter there is no information, these are reasonably satisfactory results.

One hundred and twenty of the 205 patients not operated on were discharged from general hospitals and 85 from station hospitals. The proportionate distribution of the various types of disposition showed considerable differences in the two types of installation. In the 16 general hospitals included in the survey, 30 percent (36) of 120 patients were classified as category A, 50 percent (60) as category B, and 20 percent (24) as category C. In the 25 station hospitals, the respective proportions were 68 percent (58) category A, 26 percent (22) category B, and 6 percent (5) category C. Both the total and the average-stay days were also materially fewer in the station hospitals.

At first glance, it is hard to see why the results in the station hospitals should be, apparently, so much more favorable than in the general hospitals. Superiority of treatment does not explain it, for the same conservative measures, chiefly rest and physical therapy, were used in both. Analysis of the preliminary figures seems to furnish the explanation, which is that considerable number of the patients discharged from the general hospitals had been transferred to them from station hospitals, chiefly, it would seem, because they presented problems of management and disposition. These patients required a longer time for investigation and in general represented a less favorable group of cases. They therefore, it is reasonable to assume, not only increased the average period of hospitalization in general hospitals but also required a greater percentage of category B and C dispositions in those institutions. It also seems probable that the attitude toward disposition was more conservative in general hospitals and the criteria for category A disposition somewhat stricter, than in station hospitals. Disposition in noncombat injuries of all sorts was always a matter of judgment, not of rules, and neither documentary nor statistical data are available to confirm or disprove this reasoning.

It should be borne in mind, in interpreting these statistics, that most admissions to station hospitals were noncombat troops and that admissions to general hospitals were combat troops plus transfers from station hospitals. Station hospitals would therefore be expected to make more category A dispositions.

Comment.—The relative frequency with which recurrent dislocation of the shoulder was encountered in the Mediterranean Theater of Operations was frankly surprising to some orthopedic surgeons, who regarded the number of cases as disproportionately great in comparison with civilian experience. As a matter of fact, the actual number of cases observed was considerably greater in 1944 than the 243 upon which this discussion is based. This number makes no allowance for the soldiers treated on a duty status in dispensaries and outpatient clinics. What proportion of the total cases is represented by the 243 cases treated in hospitals it is not possible to say. It is clear, however, that these soldiers furnished a serious medicomilitary problem. Their disability made them an actual loss to their organizations and also required the utilization of medical personnel and hospital facilities, sometimes for long periods of time.

Before the management of any case of recurrent dislocation of the shoulder was decided upon, it had to be evaluated individually, in the light of the following considerations:

1. It had to be established that the lesion was a true dislocation. It was not uncommon to find that what a patient called a dislocation was simply a relaxation of the joint, associated with frequent subluxations and a general feeling of instability. An occasional soldier could produce, at will, luxation of sufficient extent to be demonstrated to the medical examiner. Some, who were malingerers at heart, could furnish a glib history of numerous previous recurrences. A careful series of questions and a careful physical examination usually settled the matter, but many a medical examiner, in these circumstances, was glad to be able to fall back on the instructions in North African Theater of Operations Circular Letter No. 48, that there must be a definite Medical Department record of a previous dislocation or a supporting roentgenogram before the diagnosis was made or concurred in.

2. The degree of disability caused by the lesion had to be determined. Intelligent management and disposition were impossible without such an evaluation. Dislocation of the shoulder was seldom completely disabling except for a brief period following the actual luxation. The type of dislocation followed by partial disability for a few days or even a few weeks was the variety most often seen in Army orthopedic clinics. It rendered the soldier unfit for combat infantry duty, as well as for certain other types of duty, but still permitted him to handle many useful assignments without danger of serious or permanent injury to himself.

In some cases, the dislocation recurred frequently, sometimes every few weeks. There was no pain between the episodes, and no disabling muscle atrophy occurred. Fear of recurrence, however, materially reduced the soldier's efficiency and in a sense made him chronically disabled; he tried not

to abduct his arm because he was afraid of producing a recurrence. This type of lesion was amenable to surgery; it was fear rather than the lesion per se which disabled the patient. On the other hand, surgery promised very little from the standpoint of returning him to useful duty if muscle atrophy or painful tendonitis was part of the clinical picture. In such cases, it was best to defer disposition as long as possible and permit the soldier to continue in his current assignment. A patient in this condition was practically never found in front-line service, and the outcome of operation sometimes resulted in his further downgrading.

3. When a case suitable for surgery was encountered, two points had to be settled before operation was recommended. The first was whether the prognosis with surgery was good for some form of duty in the theater. If it was not, operation was not justified overseas, and the correct policy was either to continue the soldier in his current assignment, if he were capable of performing his duties, or to return him to the Zone of Interior for surgery. The second point was related to the first. What was the man's mental attitude? This consideration always had at least as much to do with the decision to undertake surgery as did the physical lesion, and in some instances it had more to do with it.

4. The final consideration was the essentiality of the soldier. Key personnel were sometimes operated on overseas, in disregard of ordinarily accepted criteria, because they were regarded as useful or essential. Nonessential men were left in their current status or, if surgery was clearly indicated, were returned to the Zone of Interior for treatment.

FRACTURES OF THE CARPAL SCAPHOID BONE

The results of the methods used in fractures of the carpal scaphoid bone during the North African campaign were not conclusive, and considerable doubt was felt as to the soundness of the techniques employed and the criteria of disposition. Circular Letter No. 48, Office of the Surgeon, North African Theater of Operations, 1943, offered guidance in the management of this injury as follows:

Greater care must be exercised in making a precise and prompt diagnosis of carpal fractures and dislocations, since early reduction is essential for a satisfactory result. Surgical treatment of an old, unrecognized fracture of the scaphoid will not rehabilitate a soldier. If his disability is complete, he should be transferred to the Zone of Interior.

The exact method of treatment was left to the decision of the surgeon who encountered the case, and disposition was according to the judgment of the disposition board of each hospital.

Survey of cases.—In an effort to determine the effectiveness of the methods employed in the management of fractures of the carpal scaphoid bone, a survey of the cases observed in the theater in 1944 was carried out in 1945 along the general line of the plan described for derangements of the knee joint.

Because of the nature of this injury, the circumstances of this survey and of the surveys already described were not entirely similar. As in the other investigations, no account was taken of patients not hospitalized for their injuries, which means that the number of carpal scaphoid fractures analyzed does not nearly indicate the total number of cases observed. This injury was often treated in outpatient clinics, without hospitalization. At the 182d General Hospital, for instance, there were no admissions for this cause during 1944, but 50 carpal scaphoid fractures were treated in the outpatient clinic. Unfortunately, the records for outpatient clinics were generally so fragmentary as to make their use in this investigation worthless.

Patients with fractures of the carpal scaphoid bone, particularly in station hospitals, were often discharged to duty or to quarters status after the fracture had been reduced and they had adjusted themselves to their casts, the remainder of their treatment being conducted in outpatient orthopedic clinics. As a result, the figures collected for hospital-stay days do not nearly reflect the length of time required for return to duty or other disposition. They merely show the length of time hospital facilities were utilized in the care of carpal scaphoid fractures and do not indicate the length of time the men affected were unable to perform useful duties for their organizations.

The information analyzed includes data from the hospitals transferred to the European theater after the invasion of southern France. These hospitals, however, were not asked to supply the number of carpal scaphoid fractures in the hospital 1 March 1945, as, obviously, no such patients were from the Mediterranean theater. On this date, there were 58 patients with carpal scaphoid fractures in the general and station hospitals in the Mediterranean theater. Admissions for noncombat injuries during the week ending 1 March 1945 had numbered 3,335. This means that fractures of the carpal scaphoid bone accounted for 1.73 percent of all such admissions.

During 1944, 16 general and 23 station hospitals in the Mediterranean theater reported the admission of 291 soldiers with fractures of the carpal scaphoid bone. The number of cases available for analysis is reduced to 180 by the elimination of 92 duplicate admissions and of 19 other cases in which the records were too incomplete to be used. Disposition of these patients was as follows:

Returned to full duty, after average hospitalization periods of 44.89 days, 128 patients (71 percent).

Returned to limited duty, after average hospitalization periods of 79.21 days, 27 patients (15 percent).

Classified to category C, after average hospitalization periods of 49.28 days, 25 patients (14 percent).

Since the average time for the healing of carpal scaphoid fractures is 3 to 4 months, no clinical significance can be read into the figures for hospitalization. Most of the category A and B dispositions must have been made with the hand and forearm still in plaster, the patients being assigned to light duties with their outfits. Whether the dispositions made when they were

discharged from the hospital prevailed when the casts were removed it is not possible to say.

Methods of management.—Although no theaterwide policies of management were established, orthopedic surgeons all tended to use the same general principles in carpal scaphoid fractures. Both military and civilian experience indicated that one routine was required for recent or fresh fractures and another for old fractures. The prognosis of fresh fractures was good if early, efficient immobilization was instituted and was continued until union had occurred, assuming, of course, that the fragments were in good position. The prognosis was less good, and was often poor, if adequate treatment was not begun within the first few days after the injury or if immobilization was inadequate or was not continued until healing occurred. If the blood supply of the fragments, as demonstrated by roentgenograms, remained adequate, healing could be expected under proper management in 3 to 4 months. If one or more of the fragments was avascular, healing was likely to be delayed and was frequently unsatisfactory.

The following principals, based on these concepts, were followed by many surgeons in the theater. If they had been universally adopted, most of the poor results observed in these injuries would have been avoided.

All sprains of the wrist were examined roentgenologically, with the idea of demonstrating or eliminating possible fractures of the carpal scaphoid bone. This was an essential precaution. In the orthopedic clinic of the 182d General Hospital, all nine of the old carpal scaphoid fractures which had to be treated for nonunion had been regarded as sprains when they were sustained and had not been correctly immobilized. The situation was entirely different in 41 fresh injuries, which were recognized as soon as they occurred and were promptly and properly immobilized. Healing was complete in every instance within 12 weeks, and the fracture line had usually disappeared entirely by this time. A smaller series from the 46th General Hospital also pointed to the role of the missed fracture in poor results. In this hospital, disposition-board records showed that 6 or 7 nonunions of carpal scaphoid fractures occurred in cases in which early care had not been given, while the course of 12 promptly treated fractures was uncomplicated and satisfactory.

If a fracture was not demonstrable in the roentgenograms but it still seemed likely that the bone had been broken, the wrist and thumb were put up in a plaster cast. The cast was removed cautiously at the end of 2 weeks, and additional roentgenograms were made. A new cast was applied if a fracture was visualized on these films.

If a fracture was visible in the first roentgenograms, a plaster cast was at once applied. It included the forearm and hand, with the thumb encased to the distal joint. The wrist was in dorsiflexion and radial deviation, and the thumb was abducted and in the position of semiapposition. The cast extended only to the distal palmar crease and allowed free finger motion, which made it practical for the patient to use his hand for light, simple work. He was told

that correct immobilization would determine the end result and was instructed to report to the clinic as soon as the cast became loose or soft.

The cast was removed between 6 and 8 weeks after it was applied, and additional roentgenograms were made. At this time, it was possible to determine the vascularity or avascularity of the fragments and to arrive at some decision as to disposition. If calcification seemed to be proceeding and union to be occurring, the prognosis was considered good, and the patient was retained in the theater of operations for further treatment. If the relative density of one or more fragments indicated avascularity, the prognosis was not considered good. The healing process in such a case was likely to be prolonged, possibly requiring many months, and unless treatment could be continued in an outpatient dispensary disposition to the Zone of Interior was recommended. Continued use of overseas hospital facilities was not regarded as justified under these circumstances.

Complete, sound healing of a carpal scaphoid fracture could be assumed only when the fracture line had completely disappeared. Immobilization was necessary until there was roentgenologic proof that this had occurred.

Old carpal scaphoid fractures, which had been unrecognized or had been treated improperly, were likely to show nonunion; avascular necrosis; and traumatic arthritis, with instability of varying degrees. Some soldiers with lesions of this kind could perform combat duty. Others suffered from so much pain and weakness that they were more or less disabled and were often unfit even for limited duties.

The procedures employed to correct the consequences of neglected carpal scaphoid fractures included drilling, bone grafting, excision of the fragments, or prolonged immobilization. All gave uncertain results and treatment was likely to be time consuming. Such methods were therefore not indicated in a theater of operations unless the particular officer or enlisted man was performing essential duties and the prognosis in the case was particularly favorable.

Careful evaluation and correct disposition of patients provided the answer to the problem of old carpal scaphoid fractures. A period of observation, during which rest and physical therapy were employed, might promise enough improvement to justify assignment to limited service or even to full duty. If treatment was likely to be prolonged, however, it was not logical to institute it overseas. If the soldier's disability prevented his performing even limited service in the theater, the better plan was prompt evacuation to the Zone of Interior.

Ninety-five records of old carpal scaphoid fractures were available for analysis in the 1944 survey. Less than half of the soldiers (40) could be returned to full duty, after spending an average of 23.23 days in the hospital and unknown periods of time in further treatment in outpatient clinics. The remaining patients were almost equally distributed between categories B and C. The hospital-stay days in the category C group averaged 31.54 days and in the B group 19.41 days. There was no economy of military manpower and medical facilities in these results.

Principles of disposition.—In carpal scaphoid fractures, as in other non-combat injuries in which the symptoms were chiefly subjective, the mental attitude of the patient was of primary importance in determining his disposition. Exaggeration of minor difficulties was often suspected but was extremely difficult to prove. The soldier who persisted in his complaints was usually, therefore, successful, at least eventually, in his attempts to avoid duty. Frequently he had to be given the benefit of the doubt. The disposition board had the major responsibility of conserving manpower for combat, but it had an equally important responsibility in limiting the duties of soldiers to work which they could reasonably be expected to perform successfully and perform without injury to themselves.

CHAPTER XI

Disposition of Patients From Orthopedic Services of General Hospitals¹

GENERAL PRINCIPLES OF DISPOSITION

An important phase of the management of wounded in any overseas hospital was to determine, as promptly as possible, the expected duration of hospitalization required for each patient before return to duty or some other disposition. Ideally, this determination was made immediately after the patient's admission to the hospital, on two military principles, (1) that because manpower, resources, and other hospital facilities were limited, they must be conserved and utilized as efficiently as possible; and (2) that a soldier who could not be returned to duty with a reasonable degree of promptness should be evacuated farther to the rear or to the Zone of Interior, in order to leave empty beds and other hospital facilities for casualties arriving from areas farther forward.

In forward hospitals in the Mediterranean theater, holding policies varied with the rate of casualty flow. When casualties were heavy, only those patients expected to return to duty within 48 hours were held. In very quiet periods, on the other hand, the holding time might be extended from 10 to 21 days. The great majority of duty dispositions from forward hospitals, in addition to those for medical conditions, were for minor sprains, bruises, and superficial wounds. Patients with bone and joint injuries obviously had to be sent to the rear, for care in fixed hospitals.

The same plan of prompt estimation of hospitalization time was employed in fixed hospitals, so that soldiers whose military value to the theater was ended could be sent to the Zone of Interior as soon as was feasible. In the Mediterranean theater, soldiers whose return to duty could be expected within 90 days or, at other times, within 120 days, were held for treatment in the theater. All others were evacuated to the Zone of Interior as soon as was compatible with good surgical practice.

In practice, the determination of transportability was always on an individual basis. Not only the risk to life but the possible effect of evacuation on future function and anatomic restoration were considered in the timing. The general plan was to effect the transfer during some lag period of treatment, when no specific therapeutic procedure was required. It was also

¹ The extensive data on which the material in this chapter is based were collected and tabulated by Lt. Col. George A. Duncan, MC, 45th General Hospital.

necessary to correlate individual transportability with the availability of transportation facilities.

Civilian standards for discharge from the hospital or return to work were not applicable in military dispositions. A soldier returned to duty had to be ready to perform all his assigned tasks in his special branch of the service. For that reason, hospitalization was necessarily prolonged in comparison with the period which would be required for a comparable condition in civilian practice.

Dispositions in the Mediterranean theater were as follows:

Category A, to full duty.

Category A₂, to a replacement depot for 6 weeks. As a practical matter, most patients discharged from fixed hospitals were sent to these depots. Those who had been classified as category A were returned to duty at once. The others (category A₂) underwent reconditioning for 6 weeks. At the end of this time, each soldier appeared before a medical board consisting of a surgeon, an orthopedic surgeon, and an internist, for determination of his final disposition. As a general rule, some 80 percent or more of men classified as category A₂ had their classifications raised to A at the end of the reconditioning period. Replacement centers, like the convalescent centers organized in fixed hospitals, were operated in the Mediterranean theater by the Combat Conditioning Command.

Category B, to limited-duty assignment, usually noncombatant.

Category C, to the Zone of Interior.

In the early days of the Mediterranean theater, there was a decided tendency to hold some soldiers with bone and joint injuries in the theater, in the hope that they could be returned to duty. This tendency was strengthened by the pressure brought upon the Medical Corps by combat commanders to return as many men as possible to duty. Orthopedic surgeons fully appreciated the importance of the maintenance of manpower, but many of them felt—and events proved that they were correct—that the pressure exerted in favor of duty dispositions would result in the return to duty of many soldiers of questionable fitness, who would be unable to carry out the tasks expected of them and who would thus be a liability to their commands.

As experience increased, the fallacy of the original policy as it applied to bone and joint injuries became apparent. The very nature of the injuries which required the admission of the patients to the orthopedic sections of fixed hospitals automatically established many of them as immediate candidates for evacuation to the Zone of Interior as soon as their condition permitted. The best that could be expected for others was disposition to limited assignments, usually noncombatant, within the theater. Only a limited number of casualties with simple fractures and a very much smaller number with major compound fractures or with joint injuries of any severity could be returned to duty within a 120-day holding period, much less a 90-day period. Even wounds of the hands and feet with only moderate bone and joint damage resulted in long periods of disability, and the majority of dispositions in these

groups had to be to category B or C. The few patients with injuries of the long bones who could be returned to full or limited duty had usually sustained incomplete fractures.

For a large part of the war, it was the practice in many forward hospitals to evacuate to the rear soldiers with chronic, noncombat conditions related to the bones and joints. This was a regrettable expenditure of medical effort and hospital-bed space. Some of these men, it is true, obviously required category C disposition, and their evacuation to the rear was justified. Many of them, in fact, should never have been sent to serve in forward combat units. The others, however, required no additional treatment, and their cases could have been disposed of immediately in forward hospitals by their prompt return to duty. The practice, described elsewhere (p. 272), of screening these men directly behind the battlefield, which was instituted in the late months of the war, was the solution of this particular problem.

The return to duty of patients with injuries to bones and joints from general hospitals overseas was considerably less than might have been expected, even in the light of the nature of most injuries of the bones and joints. A large part of the explanation in such cases was the mental attitude of the soldiers. It was difficult to maintain a proper attitude toward return to duty after long periods of hospitalization, and the experience of the Mediterranean theater paralleled the experience in other theaters, that the farther from the firing line a soldier was removed, the more difficult it was to get him back to full duty, even when his condition was such that return to full duty was entirely justified.

A SAMPLE HOSPITAL EXPERIENCE

An analysis of the disposition of 4,287 patients with bone and joint injuries and diseases treated on the orthopedic section of the 45th General Hospital during 1944 bears out what has been said earlier in this chapter. This hospital had come into the North African theater early in 1943 and by the beginning of 1944 was thoroughly experienced in the problems of military orthopedic surgery, including the problem of disposition of patients. Its experience may be taken as typical of the experiences of many other general hospitals in the theater.

The 4,287 patients in this series represented approximately 20 percent of the total (medical and surgical) hospital admissions for 1944. More than 60 percent were battle casualties. The cases further represented 5,203 separate orthopedic diagnoses and 1,546 diagnoses of additional injuries not connected with the bones and joints.

Of these 4,287 patients, 24 percent were returned to full duty, either directly from the 45th General Hospital or after the 6-week period of reconditioning just described. Nineteen percent were returned to limited duty in the theater. The remaining 57 percent were evacuated to the Zone of Interior. The predominance of Zone of Interior (category C) dispositions is the more

impressive when it is recollected that the total figure of 4,287 includes innumerable sprains, many non-combat-connected simple fractures, and many chronic noncombat orthopedic conditions. The patients in these special groups accounted for a large number of the category A dispositions to full duty.

Very few patients with compound fractures of the long bones of the extremity were returned to duty within the theater holding period of 90 or 120 days. Of 374 patients with fractures of the femur of all types, for instance, only 19 were returned to full duty, and 334 were evacuated to the Zone of Interior. The same proportions held for most patients with fractures of the bones of the leg and of the arm and forearm. Even fractures of bones of the hand and foot disqualified a large number of patients for further overseas duty. In 179 compound fractures of the metacarpal bones, for instance, there were 91 dispositions to category C and only 49, well under a third of the total number, to full duty. In 224 compound fractures of the metatarsal bones, there were 150 dispositions to category C and only 43, less than 20 percent of the total number, to full duty.

APPENDIX

Pertinent Circular Letters

HEADQUARTERS
NORTH AFRICAN THEATER OF OPERATIONS

Office of the Surgeon

APO 512

15 MAY 1943

CIRCULAR LETTER NO. 13

MEMORANDA ON FORWARD SURGERY

1. *Surgical Echelons.*

a. The welfare of the patient and the tactical necessity for rapid evacuation demand a clear understanding of the function or mission of each unit of the Army Medical Corps. This is best arrived at by dividing the treatment of a casualty into two stages—primary and definitive. Separate groups of units provide each stage of treatment. In general, the equipment of each group is designed for that purpose only.

b. Stations of the first and second echelons—Aid Stations, Collecting Stations and Clearing Stations are equipped and staffed for the primary phase of treatment. Arrest of hemorrhage, splinting of the injury, resuscitation measures needed to make the patient transportable and administration of sulfonamides are the urgent functions of these stations. In addition, the treatment of minor injuries that allow immediate return to duty is carried out without evacuation. A Clearing Station is not designed to provide definitive treatment of battle casualties.

c. During combat, especially with long distances in evacuation to the rear, Surgical Teams are attached to certain Clearing Stations. It is their function to give emergency surgical treatment to selected cases requiring immediate operation. This treatment would not otherwise be available in this echelon. The lack of facilities for pre-operative X-ray examination and for post-operative care of adequate duration place a grave responsibility on the surgeon in the selection of cases for surgery. *These same limitations exist during quiet times.* The length of the evacuation line to the next echelon and changing tactical conditions require frequent redefinition of the surgery undertaken in the clearing station.

d. It must be remembered that the lightly wounded soldier, or a casualty due to accident may regain full combat status within the Theater if proper surgical treatment is carried out, but the Theater may be deprived of his service by faulty surgical judgement. Because a surgical procedure appears simple is not sufficient reason for performing it in a Clearing Station unless the man can be returned to immediate duty without evacuation to the rear.

e. Hospitals of the third echelon (Evacuation Hospitals) are designed to initiate definitive surgical treatment to battle casualties. The more delay there is before reaching this echelon and the more hands the patient passes through in reaching it, the poorer will be the final result. The evacuation line is *not an assembly line* in which each surgeon does his bit to the patient. It is a *conveyance line* along the course of which the progress of the patient may be halted to save life or limb or render him transportable.

f. While Evacuation Hospitals are adequately equipped and staffed to perform rehabilitation operations, it is not the function for which they were designed. Even in quiet times these patients are evacuated to the fourth echelon for operation unless the Commanding Officer assumes full responsibility based on a knowledge of the existing tactical situation as well as the surgical aspects of the individual case.

2. Surgical Procedures.

a. *Dressings*: Ideally, the primary phase of treatment is completed in the first unit reached that is equipped to provide it. The dressing is then left undisturbed until the patient reaches an Evacuation Hospital for operation. There are certain safeguards and adjustments that must take place enroute, but these *do not include inspection of the wound by removal of the dressing unless definite indications* are present. A compound fracture is halted at the Clearing Station for more adequate immobilization or resuscitation, but this need not involve redressing the wound unless there is reason to arrest continuing hemorrhage. A wound is not redressed solely for the purpose of reapplying local sulfonamide. Oral administration is sufficient safeguard.

b. The same principles apply after operation has been completed and the patient is being evacuated to the rear.

c. Uninformed hands do unnecessary dressings. The best safeguard for the patient is an adequate and legible record that accompanies him. A receiving officer is then in a position to refer to the record instead of looking at the wound. Many wounds after debridement and arrival at the base can be closed by secondary suture. Infection arising from contamination at the time dressings are changed makes this impossible.

d. *Wound Management*: Common mistakes in war surgery are: (1) *Suture of wounds*. (2) *Tight Plugging by Packs*. Hemorrhage is controlled by a stitch ligature if from a large vessel. Otherwise, by a temporary pack, elevation and firm pressure. If a pack is left in a wound make a note that it should be removed at the first opportunity. Vaseline gauze is laid loosely in a wound, not packed in. (3) *Failure to Immobilize Site of Injury*. Large wounds

are immobilized even though fracture has not occurred. (4) *Overexcision of skin*. Circular defects are slow to heal. Very little skin need be excised, and in some instances none at all. (5) *Failure to Open Deep Spaces* during definitive treatment by freely incising fascial planes.

* * * * *

p. Compound Fractures: It is essential to distinguish splinting applied for a limited time as a *transportation* splint from apparatus or splinting designed for reduction and prolonged or rigid immobilization. An adequate transportation splint prevents additional soft part injury and further deformity. It cannot in itself cause nerve injury, pressure sores, or jeopardize the circulation of the extremity. It provides adequate fixation for ambulance transport over rough roads, but may not secure the fragments in rigid fixation or exert the traction necessary for further reduction.

q. Plaster Casts: A more liberal use of plaster of paris casting is urged. Plaster casings or slabs applied as temporary transportation splints are padded and either bivalved or completely split. Encircling bandages and cotton rolling under the cast are also split as it soon becomes inflexible with dry blood or serum. Plaster casings applied directly to the skin are rarely found advisable in forward areas. If a skin plaster is applied for a definite indication, bony prominences are padded and the cast is immediately split in its full length. No encircling bandages or adhesive strips are placed under a plaster.

(1) *All plaster casts applied in forward areas should be split or bivalved as soon as sufficiently dry.*

r. Skeletal Traction: There is no indication for the use of skeletal traction or skeletal fixation in conjunction with transportation splinting in the forward area.

s. Internal Fixation: The use of bone plates or screws is not recommended in stations forward of an Evacuation Hospital.

t. Humerus: Skin traction, skeletal traction and high abduction spica plasters or splinting are not only uncomfortable but dangerous transportation methods. A hanging plaster is unsuitable for transportation purposes. A simple U plaster slab running from the affected shoulder over the anterior aspect of the forearm and upward to the axilla is usually sufficient. The wrist is supported by a bandage sling. Following definitive surgery, the same type of splinting may be used for further transport, or a carefully applied spica with limited abduction (30°-35°) may be used.

u. Femur: Traction applied by a clove hitch, ankle bracelet or through the boot is not advisable for longer than six hours. This type of traction should be changed to skin traction at the Clearing Station.

v. Attention is drawn to the Tobruk transportation splint highly recommended by the R. A. M. C. reports from the Middle East. Medical Officers should be familiar with the design and methods of application of this splint and a more frequent use is suggested.

w. If a plaster spica is used the extremity is fixed in slight abduction and care taken to see that the upper part of the cast does not impinge on the costal margin. If the other leg is not tied into the spica, and it rarely need be, the plaster casing is extended well above the costal margin with fenestration provided for the abdomen.

x. Spica casting for either the upper or lower extremity must be well applied with adequate padding to avoid discomfort and pressure sores during transportation. These complications as well as easier application have led to the development of the Tobruk splint.

y. *Amputation*: In military surgery an amputation is a two-stage operation—the first stage performed in the overseas theater, the final stage, if necessary, in the Zone of the Interior.

(1) The circular type Guillotine is the amputation of choice. The indications for primary amputation are control of hemorrhage, destruction of circulation, removal of irreparably destroyed extremity and as a step in the debridement of a traumatic amputation. The site of primary amputation is the lowest possible level of viable tissues regardless of the eventual utility of the stump so formed.

(2) Delayed amputation is performed for circulatory insufficiency, infection, gas gangrene in which more conservative measures have been inadequate or in the judgement of the surgeon will be inadequate, and uncontrollable secondary hemorrhage. The site of secondary amputation is determined by the judgement of the surgeon with respect to preservation of maximum bone length.

(3) Sulfanilamide is dusted on the end of the stump and vaseline gauze dressing applied. Skin traction is *applied on the operating table and continued until the stump is healed*. All lower leg amputations are splinted with a posterior slab to prevent flexion deformity of the knee. The splint extends below the level of the stump. Transport in $\frac{1}{2}$ ring Thomas splint with support of the stump and continued skin traction.

(4) Adhesive plaster traction is recommended in the forward areas where a bulky dressing may be desirable. Stockinette applied with skin glue may be substituted at the base. Adhesive plaster traction strips must extend *to the edge* of the incised skin and be anchored by two circular strips. They should not extend upward beyond the base of the limb.

(5) Secondary closure of amputation stumps is not recommended.

z. *Peripheral Vascular Insufficiency*: Following wounds that jeopardize the blood supply of an extremity *transport beyond an Evacuation Hospital is delayed* until the collateral circulation has been demonstrated adequate or until amputation has been performed. Immobilization for transport, or the additional trauma and shock incident to transport may be a determining factor in producing gangrene.

(1) Principles guiding treatment of a limb with defective circulation are as follows: (1) Immediate restoration of blood volume with plasma supplemented by whole blood transfusion to establish normal oxygen carrying capacity of the blood. (2) Prevention of loss of body heat by dry woolen coverings for body and limbs. (3) Do not ligate a major artery in continuity. Divide the vessel between ligatures. (4) Ligate and divide the companion vein. (5) The extremity supplied by the divided vessel should not be elevated but slightly depressed. Wrap in wool or cotton. Do not directly heat.

(2) To stimulate the development of collateral circulation the following measures are recommended: (1) Heat the body (not the limb) under a cradle. (2) Novocain block of sympathetic chain repeated daily if necessary. (3) Under special circumstances, sympathectomy. (4) Vasodilating drugs are of questionable efficacy. (5) Passive vascular exercises. (6) Incision of deep fascia planes if a tense hematoma is present.

(3) Arterial spasm may be encountered when a missile passes close to an artery or there is an adjacent fracture. There is no external bleeding or hematoma. The limb is cold, numb and muscle action lost. Peripheral pulses are absent. There is no pain in contrast to occlusion of the artery by an embolus.

(4) Peripheral pulses return in a few days as color and warmth reappear in the limb. Treatment is directed toward warming the body, and the use of sympathetic novocain block. If the vessel is exposed during debridement direct application of procaine may be tried.

(5) All casualties with defective circulation in an extremity, particularly of the leg should be under close observation for the development of gas gangrene.

* * * * *

(S) F. A. BLESSE
F. A. BLESSE,
Brig. General, AUS,
Surgeon.

DISTRIBUTION:

CG, Fifth Army	500
CG, II Corps	450
CG, NAAF	300
CG, ABS	500
CO, MBS	800
CO, EBS	
CO, Hq. Comd., AF	50
SURGEON, NATOUSA	100

HEADQUARTERS
NORTH AFRICAN THEATER OF OPERATIONS
Office of the Surgeon

APO 534

9 JUNE 1943

CIRCULAR LETTER NO. 16

SUBJECT: MEMORANDA ON FORWARD SURGERY ESPECIALLY
APPLICABLE TO AMPHIBIOUS OPERATIONS

1. General Principles of Wound Management:

a. Surgical operation performed under unfavorable conditions without facilities for proper after care is often *more hazardous* than prompt evacuation if the patient is transportable or can be made so.

b. Wounded evacuated by water should, particularly during early phases of combat, be so bandaged and splinted that they can swim or at least remain afloat should emergency require it.

c. Overdosage with morphia produces dangerous coma and respiratory depression that may delay the administration of an anaesthetic or render evacuation transport hazardous.

d. All wounds are left open after debridement, frosted with sulfonamide and loosely filled with vaseline gauze. *There are no exceptions.* (See below for specialized regional situations).

e. Only bruised and devitalized skin need be excised, and this with narrow margin. Avoid circumscision of wounds leaving circular defects by using linear extensions to gain exposure.

f. During debridement open all deep pockets and transversely divide fascial planes.

g. Do not *pack* wounds with gauze or sulfonamide.

h. Immobilize site of extensive injury even if fracture is not present.

i. Continue oral administration of sulfonamide.

j. Make notations on casts *and* on Field tags and records, (casts are frequently changed) particularly of what was done at operation. These notes are not merely for statistical purposes although essential as such. *They are required for the subsequent care of the patient.*

2. Plaster Casts.

a. *Split or bivalve all casts as soon as dry.* *There are no exceptions.*

b. Pad all casts and split padding as well as cast. Non-padded plaster is not suitable for transportation splinting.

c. Apply no circular adhesive or bandage under cast.

d. Maintain foot in neutral position with correction of tendency toward equinus, valgus or varus.

3. *Compound Fractures.*

a. Objects to be achieved in initial surgery are control of infection and safe, comfortable transportation. Reduction and rigid fixation of fracture can be accomplished at The Base.

b. Careful debridement as priority case. No internal fixation forward of Field or Evacuation Hospitals. Do not *pack* wound—loosely fill with vaseline gauze. Splint for transportation. Skeletal fixation or traction not recommended for transportation splinting.

c. *Femur*: Evacuate in Tobruk splint (See Appendix) as early as circumstances permit to reach Base for correction of deformity. A fractured femur should reach a General Hospital in the rear within 10 days. Do not evacuate with clove hitch or boot traction—use skin adhesive.

d. *Knee-joint*: In debridement minimize incisions that compound joint. Remove accessible foreign bodies. Irrigate joint with saline. Close synovial membrane. Loosely fill debrided wound with vaseline gauze. Evacuate early, immobilized in plaster or preferably Tobruk splint.

e. *Leg*: Careful debridement *all* wounds in multiple injuries, as circulation frequently impaired and gas gangrene likely. Penetrating wounds of calf may require incision for hemostasis as deep hematoma impedes circulation. Bivalve rather than split casts so inspection dressings may be possible without losing position in compounded fractures. Hold patient if circulation is questionable, otherwise evacuate as early priority.

f. *Humerus*: Use modified Velpeau plaster bandage to hold arm to trunk, or "U" plaster. Skin traction, skeletal fixation, high abduction spica and hanging cast unsuitable for transportation splinting.

* * * * *

10. *Amputations:*

a. Circular type guillotine is amputation of choice. In forward surgery performed for control of hemorrhage, destruction of circulation, removal of an irreparably destroyed extremity, and as a step in the debridement of a traumatic amputation. *The site is the lowest possible level of viable tissues* regardless of the eventual utility of the stump.

b. Gas gangrene infection occurs in certain cases with 24 hours delay in evacuation from the field. Amputate only if more conservative surgery and full dosage (80,000 to 100,000 units of polyvalent anti-toxin) are judged inadequate.

c. Apply skin traction on the operating table and maintain during evacuation.

d. No sutures. There are no exceptions.

(S) F. A. BLESSE
F. A. BLESSE,
Brig. General, AUS,
Surgeon.

Incl: Appendix

DISTRIBUTION:

To all Medical Officers	
CG—Fifth Army	900
CG—NAAF	450
CG—ABS	500
CG—MBS	800
CG—EBS	700
CO, Hq. Command AF	50
Surgeon, NATOUSA	250

APPENDIX

Tobruk Transportation Plaster.—Recommended for fractures of the femur, wounds involving the knee joint and fractures of the leg near the knee.

1. Dress wound and retain dressing with strips of adhesive plaster. No circular dressing or bandages should ever be put on under a plaster case.

2. Support patient with a pelvic rest, or bowl under sacrum. One assistant holds the foot by the heel and toes and exerts traction. The foot is kept at *right angles*. A second assistant supports the fracture and keeps the knee bent at 10 degrees flexion with the palms of the hands *not* the fingers.

3. Apply traction strapping as close up to the wound as possible. Fold distal ends of straps into cords.

4. Pad the heel and malleoli with wool. Turn back the traction straps from the region of the malleoli while winding the wool round. Pad the knee prominences similarly. There have been some cases of foot drop from pressure on the external popliteal nerve. Pad the upper part of the thigh close to the ring of the splint with a layer of wool. Pad the entire extremity with sheet wadding or stockinette.

5. Lay a strip of tin (obtainable from ration boxes etc.) wrapped in paper over the anterior surface of the length of the limb to beyond the toes.

6. Prepare a plaster slab (6 thicknesses)—apply posteriorly as high as possible and distally *over heel and sole of foot* to project 3–4" above the toes.

7. Complete plaster cast with circular bandages round the slab enclosing the whole of the leg and foot except the dorsum of the toes and mould. Do not cover over traction straps further than just above the malleoli.

8. The traction straps are now emerging from the plaster just above the malleoli. Turn them back and cut the plaster away from where they emerge,

sufficiently to free the straps from the plaster. This allows the traction to be on the leg and *not on the cast*. Trim the plaster over the dorsum of the toes. See that the little toe is free.

9. Apply Thomas Splint preferably half-ring and fit lower part of ring against Tuber Ischii and adductor muscles. Hold up ring so as to obtain correct position and insert pads of wool anteriorly and laterally between the ring and the thigh to maintain the position. Tie traction straps to notch in splint and insert spreader and Spanish Windlass.

10. Wind plaster bandages round the side bars of the splint, and round the limb to anchor the splint to the limb.

11. Support distal end of splint with splint bracket.

12. When plaster is moderately firm cut down on thin strip *over whole length plaster* and withdraw strip and *split the plaster*. Cut the underlying padding with scissors or knife. It is not necessary to cut stockinette.

13. With indelible pencil draw diagram of fracture and write simple details, date of wounding, treatment, date of application of plaster, unit, etc.

NOTE. This splint is only intended as a *transportation* splint for the journey to the base. There is no need to aim at accurate apposition in the Forward Area. On arrival at the Base Hospital X-ray examination should be made, position corrected if necessary and routine treatment employed.

This form of fixation will do quite well even for fractures of the upper third of the femur for transport.

HEADQUARTERS
NORTH AFRICAN THEATER OF OPERATIONS
Office of the Surgeon
APO 534

26 JUNE 1943

CIRCULAR LETTER NO. 19

* * * * *

Operations on the Knee Joints..... IV

* * * * *

IV—OPERATIONS ON THE KNEE JOINTS.

1. Careful surgical judgement is to be exercised in the selection of cases for excision of semilunar cartilages. A history of locking is essential. Instability of the knee joint is a contraindication. Post operative care in the form of early weight bearing without crutches and exercise of the quadriceps muscle groups instituted early under supervision is essential to recovery.

2. Operations for major knee disabilities such as repair of collateral or cruciate ligaments, or removal of both cartilages are to be undertaken only on recommendation of a Disposition Board of a General Hospital.

For the SURGEON:

(S) E. STANDLEE
E. STANDLEE,
Colonel, M. C.,
Deputy Surgeon.

DISTRIBUTION:

CG, Fifth Army	600
CO, ABS	500
CG, MBS	600
CO, MBS Center District	200
CG, EBS	600
CG, NAAF	450
CG, Force 141	300
CO, HQ Comds., AF	50
Surgeon, NATOUSA	150

HEADQUARTERS
NORTH AFRICAN THEATER OF OPERATIONS
Office of the Surgeon
APO 534

22 JUNE 1943

CIRCULAR LETTER NO. 20

SUBJECT: Tunisian Campaign--Comments by Hospitals of the Zone of Communications on the Treatment of Battle Casualties in Forward Areas.

NOTE: At the end of the final phase of the Battle of Tunisia, several hospitals of the Zone of Communications were asked to submit comments on the surgical treatment of battle casualties received during the campaign. Although quotation marks have been eliminated, the following paragraphs are direct transcriptions of these comments and suggestions. Specific case histories have been assembled in the Appendix with designations as footnotes. Many of the principles emphasized in these comments have been incorporated in Circular Letters, and they should be carefully observed by all Surgeons in the Theater.

Figures in parentheses refer to case histories in the Appendix. Comments in parentheses were not received from the hospitals.

1. *General Considerations.*

a. In general, the great majority (90%) of patients received from the combat zone have been well and adequately treated, and good judgement has been exercised in selection of cases suitable for evacuation to this general hospital.

b. In several instances the severity of the injury has not seemed to warrant evacuation to this point, where, with a large proportion of the cases prospectively to be evacuated to the Zone of the Interior, it is inevitable that the patients should acquire an exaggerated idea of the severity of their injury, and a reluctance toward return to duty. (1)

c. There are rare instances of patients who were so critically ill on admission that their evacuation has appeared unwise and unduly hazardous.

d. Many patients might have been returned to full or limited service if they had not been told that they were to be sent to the Zone of the Interior, or that they would not regain full function of an injured part.

e. Almost all of our patients have spoken with appreciation of the skilled and kindly treatment they have received in the most forward areas—litter bearers, battalion surgeons, and on back. Most of the patients have had excellent treatment and in particular the work of the Surgical Teams has been outstanding.

f. A number of our patients have received wounds due to shell fragments. The vast majority of these wounds have been satisfactorily treated by excision and left open. Most of them have healed kindly and have required only secondary closure or skin grafting for complete healing.

g. Judging from the comparatively small number of war casualties treated in this hospital it seems evident that delayed primary suture of wounds, particularly in patients who are to be evacuated is an ill-advised procedure. (This does not apply to secondary suture in a Base Hospital where the patient can be held until healing is complete.) The suture of wounds using a gauze pack as a drain should be avoided. The pack dries and acts as a plug rather than a drain.

2. *Initial Treatment of Wounds.*

a. Adequate debridement of wounds in combination with a filling of vaseline gauze and the use of sulfa drugs and plaster immobilization has produced clean wounds in most instances. The patients have arrived in good condition, relatively comfortable, and have only rarely shown even slight temperature elevation.

b. The extent of some wounds suggests that skin removal has been too extensive in many cases.

c. Large numbers of foreign bodies are still present in the wounds in many cases. The metallic foreign bodies only occasionally are responsible for persistent draining sinuses. In one case fragments of cloth were found just beneath the skin, where even casual debridement might have discovered them.

d. Conservation of digits. Numerous fingers with compound injuries and lacerated tendons have been treated conservatively, often with tendon

suture and splinting. An over heroic attempt has been made in the presence of sepsis to preserve digits devoid of function. The protracted splinting in these cases results in diffuse stiffness of the hand unrelieved by late amputation of the useless digits, and necessitating evacuation to the Zone of the Interior. From the standpoint of military usefulness the results of early amputation in badly damaged fingers have been more satisfactory.

e. There have been several instances of attempted primary tendon repair in severe crushing or gunshot wounds of the hand. None of these has been successful.

f. Packing. The commonest criticism of the packing of wounds is that excessive amounts of gauze have been used, frequently acting as a plug, and often introduced through a small wound of entrance. In several cases through and through gauze strips have been used to pack perforating wounds of the extremities. Coarse meshed dry gauze has been used for packing in many cases, the removal of which is difficult and unnecessarily traumatizing. When it is necessary to use dry gauze packs to control bleeding, early removal is urgent and a notation that such packing has been employed would ensure an early change of cast.

g. On many occasions when the casts were removed and the wounds dressed, tight vaseline packs were found in place and when these were removed there was a gush of dammed back discharge. It seems desirable that the vaseline gauze strips be laid from the bottom of the debrided wound out over the skin in an axis at right angles to the wound. Having lain such strips all about the circumference of the wound the remaining central cavity can be filled with vaseline gauze folded back and forth. It is worth repeating that the debridement should be complete, the sulfanilamide sprinkled into all crevices of the wound and the vaseline packing inserted loosely.

(It is recommended that the term "pack" be dropped from common usage and reserved specifically for a temporary procedure used to control hemorrhage.)

h. Immobilization. Many casts are excessively thick and heavy. Insufficient padding, or padding carelessly applied, has resulted in pressure sores in several cases. The use of circular bandages inside casts, or of slings, may result in constriction or pressure sores. Simple linear incision of a circular cast is not sufficient safeguard against swelling and circulatory embarrassment. In one instance of simple uncomplicated fracture of both bones of the leg, amputation was barely averted because of circulatory damage which could have been avoided by proper padding or bivalving of the cast.

i. We particularly condemn the use of the skin tight plaster on the acute injury, even those split up the front. We have had about 20 cases of fracture of the leg and a few of the arm come to us in plasters applied directly to the skin at the time of debridement in forward hospitals. With very few exceptions the skin has been blistered when these casts were removed. Sheet cotton, stockinette, cloth of any kind or even newspaper should be used to protect the skin.

j. Insufficient splinting and immobilization has been applied. (2) (3) Contractures have developed which have been very troublesome and in some

cases have necessitated evacuation to the Zone of the Interior for this reason alone. Cock-up splints for radial nerve injuries are generally too short. Patients with peroneal palsy are not protected against foot drop.

k. Hip spicas in the majority of cases are carried unduly high and cause a considerable amount of unnecessary discomfort. In shoulder spicas a common error is to place the arm in too great abduction, and in or behind the frontal plane of the body rather than forward of it. Patients transported in "hanging casts" for fracture of the humerus do not travel well. (4)

l. Of the 272 patients treated, 111 were compound fractures, all but four of whom entered this hospital by air ambulance in excellent condition. The great majority of these patients had been treated by early debridement, local application of a sulfonamide packing with vaseline gauze and application of a padded plaster cast.

m. Fractures have been well immobilized and the plaster work has been excellent. In only a few instances has it been necessary to remove plaster because of constriction.

n. In badly comminuted fractures where good position has been obtained at operation loss of position is to be feared with change of cast. These cases are problems. While we favor the 10th to 12th day change of plaster we have allowed them to go several weeks pending soft tissue fixation of the fragments. It would be helpful if plasters in such cases could be bivalved rather than split down the center, so the dressing might be done and a new cast applied over the remaining half.

(Bivalving plasters prior to transportation means strengthening the halves by slabs and secure approximation before evacuation.)

o. Penetrating or perforating injuries of the knee have frequently been opened surgically in forward hospitals, foreign bodies or bone and cartilage chips removed, the joint irrigated thoroughly, sulfanilamide inserted into the joint, the synovial membrane closed and the wound then packed open. All so treated have done well with a minimum of synovial reaction. After the operative procedure all cases should be immobilized in a long leg plaster to the groin and the use of a cross stick at the ankle to prevent rotation.

3. Amputations.

a. The small number of amputations seen would have benefited had they been transported in Thomas splints with skin traction applied to the skin flaps. The open wounds were clean but the skin had retracted to the point that reamputation will probably be necessary to accomplish a serviceable stump.

b. In two instances a final amputation was done at too high a level to permit use of an artificial limb. Several cases of amputation have arrived with severe flexion contracture of the knee for lack of a posterior splint. Several cases of severe hip flexion contracture have been received as a result of omitting posterior splints following thigh amputations.

c. Out of twelve cases of anaerobic gas bacillus infection in one hospital, 2 were in sutured amputation stumps.

d. In the following case, (5), a conservation type of amputation was performed through a level far below the site of vascular occlusion in an infected leg. I think the lesson here is that the line of demarcation in infected extremities with vascular occlusion does not mark the level at which an amputation stump will be sustained. Circulation just enough to maintain viability of tissues will not withstand an amputation or cope with an infection. Amputation in such cases must be high, if possible above the level of vascular occlusion.

* * * * *

(S) F. A. BLESSE
F. A. BLESSE,
Brig. General, AUS,
Surgeon.

Incl: Appendix

DISTRIBUTION:

CG, Fifth Army	600
CO, ABS	500
CG, MBS	600
CO, MBS Center District	200
CG, EBS	600
CG, NAAF	450
CG, Force 141	300
CO, HQ. Comd., AF	50
Surgeon, NATOUSA	150

HEADQUARTERS
NORTH AFRICAN THEATER OF OPERATIONS

Office of the Surgeon

APO 534

18 NOVEMBER 1943

CIRCULAR LETTER NO. 48

PARAGRAPH IV, CIRCULAR LETTER NO. 19 IS AMENDED---	I
PARAGRAPH III, CIRCULAR LETTER NO. 19 IS AMENDED---	II
USE OF EXTERNAL SKELETAL FIXATION APPARATUS (ROGER ANDERSON) IN TREATMENT OF FRACTURES OF THE EXTREMITIES-----	III
DELAYED OPEN REDUCTION AND INTERNAL FIXATION OF COMPOUND FRACTURES WITH OR WITHOUT SEC- ONDARY SUTURE OF WOUND-----	IV
FRACTURES OF CARPUS-----	V
HERNIATED NUCLEUS PULPOSUS-----	VI
"PARRY" OR MONTEGGIA FRACTURE-----	VII

THE TOBRUK SPLINT AND HIP SPICAS.....	VIII
TRANSPORTATION OF CASUALTIES WITH PARAPLEGIA.....	IX

I—PARAGRAPH IV, CIRCULAR LETTER NO. 19 IS AMENDED AS FOLLOWS:

Operations of the Knee Joint

Follow-up studies on over 200 operations performed in this theater for removal of dislocated or ruptured semilunar cartilages and other derangements of the knee joint have been compiled. Appraisal of these results lead to the following recommendations:

1. Operations for the repair or reconstruction of the collateral or cruciate ligaments of the knee, or for recurrent dislocation of the patella, are not to be performed in this theater.

2. Careful study and mature surgical judgement will be exercised in the selection of cases for excision of a semilunary cartilage or joint mouse.

a. Elective arthrotomy of the knee will be performed only on the Orthopedic Service of a General Hospital.

b. Initial injuries of the semilunar cartilage without locking and those that unlock by gentle manipulation, or after 5 to 6 days of skin traction, will not be subjected to operation. Pressure support, rest, graduated to protected, then full weight bearing and carefully supervised quadriceps exercise for 2 to 10 weeks, are suggested as a method of management. Following symptomatic relief these soldiers may be returned to duty.

c. Arthrotomy will be limited to:

(1) The persistent locked knee.

(2) The unlocked knee in a soldier who cannot perform non-combat duty because of his disability. This will be only the exceptional case.

d. Contraindications to be considered are age, arthritic changes, instability of the joint and, in particular, any but the most favorable mental attitude of the soldier.

e. Recurrent cases, not locked, and those recurrent cases that unlock with non-operative therapy, are to be returned to duty unless the total period of disability in any calendar year exceeds 90 days. Under such circumstances, they will be transferred to the Zone of the Interior.

f. Operation for the removal of both cartilages from one knee or for one cartilage from each knee is to be performed only on written recommendation of a Disposition Board of a General Hospital.

3. A General Hospital in which arthrotomy of the knee is performed will be expected to hold the patient for a minimal period of six weeks, so that the operating surgeon may supervise the regimen of post-operative exercises and motion essential to a good result. Proper post-operative supervision is as essential to recovery as the operation. If prevailing evacuation policies indicate that the patient cannot be held for at least 6 weeks post-operatively, he should be transferred farther to the rear for operation.

4. After 6 weeks in a General Hospital, the patient may be transferred to a Convalescent Hospital for further care with full instructions relative to continuation of corrective exercises.

II—PARAGRAPH III, CIRCULAR LETTER NO. 19 IS AMENDED AS FOLLOWS:

Operations for Recurrent Dislocation of the Shoulder Joint or Chronic Dislocation of the Acromio-clavicular Joint

1. The history of a patient relative to previous dislocation of the shoulder is notoriously unreliable. Before making a diagnosis of recurrent dislocation, one or more episodes should be confirmed on Army Medical Records, preferably with supporting X-Ray evidence.

2. Operations of this type will be performed only with written approval of the Disposition Board of a General Hospital following demonstration that the disability is of a nature that the soldier cannot perform non-combat duty and when his age and mental attitude give a reasonable prospect of military rehabilitation.

III—USE OF EXTERNAL SKELETAL FIXATION APPARATUS (ROGER ANDERSON) IN TREATMENT OF FRACTURES OF THE EXTREMITIES.

1. This is a highly specialized method for the treatment of carefully selected cases, chosen on the basis of special indications.

2. The use of external skeletal fixation is to be limited to surgeons with training and experience in the method. If a special indication for use of the method is found in a hospital without such a surgeon, the patient will be transferred to a hospital with this trained personnel.

3. A patient with the apparatus in place is not to be transferred from one hospital to another within the theater except under emergency conditions. When a transfer is essential, he is to be routed to a hospital where there is a surgeon experienced in the method. Patients are not to be evacuated to the Zone of the Interior with the apparatus in place, but will be held for a sufficient time to permit the removal of pins and the substitution, if indicated, of conventional means of splinting.

4. Clinical records of each patient, on whom the method is utilized, will be forwarded through channels to the Surgeon, NATOUSA, after the treatment is completed. This record will contain essential data for identification of the case, date of injury, fracture diagnosis, original treatment, character of the wound if compound, problem involved and indication for use of the method, length of time required to apply the apparatus and reduce the fracture, number of X-Ray films required, date and extent of any observed distraction, incidence of pin infection and other complications, date of removal of the apparatus and subsequent treatment, result and disposition.

IV—DELAYED OPEN REDUCTION AND INTERNAL FIXATION OF COMPOUND FRACTURES WITH OR WITHOUT SECONDARY SUTURE OF WOUND.

1. This procedure is still under trial with reference to indications, hazards, and incidence of serious complications. Its use is restricted to special groups authorized to assume the responsibility as a special study.

V—FRACTURES OF CARPUS.

1. Greater care is to be exerted in making a precise and early diagnosis of carpal fractures and dislocations. Early reduction is essential if a satisfactory result is to be obtained.

2. Operative treatment for old unrecognized fractures of the scaphoid will fail to rehabilitate a soldier in this theater. If complete disability is present, he should be transferred to the Zone of the Interior.

VI—HERNIATED NUCLEUS PULPOSUS.

1. Recommendation Par. II, Circular Letter No. 19, 26 June 1943, is interpreted to apply to all patients, Army, Navy or Allied Force under treatment for this condition in U. S. hospitals.

VII—"PARRY" OR MONTEGGIA FRACTURE.

1. Attention is directed to fracture of the shaft of the ulna with dislocation of the head of the radius. Uncommon in civilian practice, this fracture due to direct violence to the forearm (blow with rifle butt or other blunt weapon), is not infrequent in military experience. It is essential that the dislocation of the radius be recognized and proper treatment instituted at the time of initial treatment.

VIII—THE TOBRUK SPLINT AND HIP SPICAS.

1. Experience has shown that the use of Tobruk splint is best limited to fractures of the lower one-third of the femur, supra-condylar fractures, and wounds damaging the knee joint. Even in these injuries it has no advantages over a well applied hip spica.

2. The most comfortable and efficient hip spica for immobilization of a fracture of the femur for transportation, following initial surgical treatment, is a short waisted, double spica extending only to the knee on the well leg and maintaining 20 to 30 degrees of abduction with the knee slightly flexed. The plaster on the injured leg is carried beyond the toes by a plaster slab, leaving the toes fully exposed anteriorly. Care is taken to avoid equinus and to hold the foot in a neutral position between valgus and varus.

3. High waisted plasters that extend to or above the costal margin cause discomfort. It is better to tie in the well leg and stop the plaster just above the iliac crest.

4. The chief responsibility of the surgeons of the forward area in the management of all compound fractures is the prevention of infection, rather than the anatomic correction of deformity. Early evacuation to the Base (a fractured femur should reach a General Hospital within 10 days) will allow for definitive reduction of the deformity.

IX—TRANSPORTATION OF CASUALTIES WITH PARAPLEGIA.

1. Meticulous nursing care is essential for the prevention of bed sores. This care is interrupted by rapid evacuation through a chain of hospitals. While it is important to transfer these cases to the Base, when they are transportable, they should not be subjected to long ambulance lifts. On arrival at an intermediate station, careful nursing care should be provided immediately. If there are signs of pressure sores, the patient should be held for corrective measures before further transfer. These patients do not complain of pain and quite different criteria are required in an estimation of whether they are to be classified as "transportable" than are found applicable in the management of other casualties.

For the SURGEON:

(S) E. STANDLEE
E. STANDLEE,
Colonel, M. C.
Deputy Surgeon.

DISTRIBUTION:

Surgeon, NAAF	400
Surgeon, NAASC	300
Surgeon, EBS	400
Surgeon, MBS	300
Surgeon, ABS	150
Surgeon, IBS	100
Surgeon, PBS	500
Surgeon, AMGOT	25
Surgeon, CD MBS	50
Surgeon, Seventh Army	350
Surgeon, Fifth Army	600
Surgeon, Hq. Command, AF	50
Surgeon, NATOUSA	200

HEADQUARTERS
NORTH AFRICAN THEATER OF OPERATIONS

Office of the Surgeon

APO 534

19 APRIL 1944

CIRCULAR LETTER NO. 26

SUBJECT: Wound Management.

1. The keystone of successful wound management is the initial surgical operation. When this is performed correctly the complications of infection are absent or minimal and secondary suture may be carried out promptly and successfully. To coordinate the initial surgery in the forward area with the definitive surgery at the base observance of the following principles is essential.

2. *Initial Wound Surgery.*

a. Adequate assistance and instruments, a good light and access to the wound that is unhampered by faulty position of the patient are basic requirements. Ample preparation of a wide field by shaving the skin will allow for extension of the incision or counter incision.

b. Bold *incision* is the first essential step in an operation on a wound. Adequate exposure is necessary to carry out *excision* of devitalized tissues. On the extremity the line of the incision is placed parallel with the long axis of the limb; elsewhere it follows the natural lines of skin structure. Only the devitalized skin of the margins of the wound is excised in a strip rarely wider than 2 to 3 mm. Circular defects are to be avoided.

c. Incision and excision of the fascial layers is carried out in the same manner to give free access to devitalized muscle. Unrestricted exposure of successive anatomic layers permits the complete excision of devitalized muscle and the removal of foreign bodies. The operation on a wound is an anatomic dissection and should never be made to resemble a digital pelvic examination.

d. The surgeon must be familiar with the blood supply of muscles, particularly large groups like the gastrocnemius-soleus muscles of the calf and respect these vessels in his dissection. Deep recesses of the wound containing foreign bodies may be approached by counterincisions planned anatomically rather than by sacrificing normal muscle structures.

e. Use fine hemostats. Use the finest ligatures compatible with the procedure. Include the smallest possible amount of tissue in ligating a bleeding point. Do not repeatedly bite the wound with tissue forceps. Sponge gently with pressure instead of wiping. *Remaining devitalized tissue produced by the missile or by the surgeon must slough before the wound can be closed by secondary suture.*

f. Large wounds in regions of heavy muscles particularly when complicated by comminuted fracture require especial care. The depths of these

wounds must be opened by a long incision with counterincision if necessary to allow free drainage of blood and tissue that may not be identified as dead at the time of debridement.

g. Only enough vaseline gauze is used to separate the surfaces of the wound. It should be smoothly laid in the wound—not “packed”.

h. Local application of sulfanilamide is a minor adjunct to surgery and is used as a fine frosting of the surfaces. It is not to be “rubbed in”.

i. Ether, white soap, and benzene have slight but definite necrotizing effects on living muscles. Green soap, hydrogen peroxide and various other substances used as detergents have greater necrotizing effects. Physiological saline solution, petrolatum and boric acid ointment are innocuous. If a detergent is needed, white soap is the least objectionable.

j. Old wounds (48 hours or longer) are managed in accord with the same principles except that in selected cases of established pyogenic infection and anaerobic cellulitis with toxicity the general condition of the patient to withstand radical surgery may be improved by immobilization, penicillin and repeated blood transfusions until an optimum time is selected for intervention. In postponement of surgery the advantage that accrues from the immediate drainage of septic hematomas, large masses of dead muscle and fascial plane abscesses is not to be forgotten. Postponement of surgery is not justified if clostridial myositis (gas gangrene) may be present.

3. *Secondary Wound Surgery.*

a. On arrival at a hospital where bed care can be assured for a period of 15 days the first dressing is removed in the operating room under aseptic precautions. X-ray films should be at hand. If the primary wound operation has been a complete one, all superficial wounds and many deep wounds may be closed by secondary suture at this time (4 to 10 days). Foreign bodies in soft parts adjacent to the wound are removed. Following suture, the part is immobilized preferably by a light plaster, or if this is impractical, by bed rest.

b. The presence of residual dead tissue or established infection indicated by profuse discharge of pus, reddening and edema of the wound margins, persistent fever or toxicity are the common indications for delay in secondary suture. When these indications are present but minimal, the wound is allowed to “clean up”. Moist dressings, heat and azochloramine are generally considered to hasten this process. Additional surgical excision of devitalized fragments may speed the process. Secondary suture can then be performed in a few days. If established infection is severe, or if the patient is toxic and anemic from deep seated sepsis, a course of penicillin therapy and blood transfusions is instituted and followed by radical wound revision.

c. Closure of wounds that compound fractures or joints is only to be undertaken when the surgeon is completely familiar with the use of penicillin as an adjunct to surgical wound revision. Penicillin will not “sterilize” a wound that contains devitalized bone, fascia, tendons or foreign bodies. Immediate success may be obtained, but delayed abscess formation, joint infections

and osteoperiostitis are likely to appear as sequelae. The wound revision that is an essential part of "cleaning up" wounds that complicate fractures or joints for closure, either at the time or subsequently, is not to be taken lightly. Preparation of the patient by transfusions, diet and accessory surgical procedures is essential.

d. Wounds that have been properly laid open at the initial operation tend to gape widely and give the impression of extensive skin loss. This appearance is actually due to loss of support of the deep fascia. Skin defects are more apparent than real in the majority of cases and closure of a defect is made from local tissue with suture in a straight line when possible. Undermining with advancement or rotation of flaps provides sufficient skin in nearly all instances and is preferable to grafting.

e. Technical considerations that are important to the success of secondary wound closure are:

(1) Atraumatic handling of tissue (see par 2, e).

(2) Avoidance of tension sutures.

(3) Accurate approximation of skin margins. The epithelial bridge is the main support of the wound for a considerable period of time.

(4) Obliteration of dead spaces by pressure dressings and immobilization.

(5) Leaving sutures in place for 12 days if stitch infection does not develop.

(6) Suture in straight lines rather than creation of sharp angles.

(7) Closure by adhesive plaster strips is not as satisfactory as suture.

f. The conditions that most often jeopardize results are:

(1) Suture of wound that is discharging a large amount of pus. This usually means dead tissue in the depths.

(2) Hemolytic streptococcus infection.

(3) Diphtheria wound infection.

(4) Too early motion. (Wounds breaking down for this reason should be immediately resutured.)

(5) Unrecognized foreign bodies adjacent to the wound.

g. Preliminary bacteriologic analysis of the flora of a wound does not provide information pertinent to making the decision to perform secondary suture or allow the prediction of the result. If the suture is not successful because of infection, appropriate studies and corrective therapy is instituted before resuture is attempted. Infection may be considered indicative of the susceptibility of the individual to the predominate wound organisms.

4. *Specialized Problems.*

* * * * *

c. Amputations.

Secondary closure of a circular guillotine amputation stump is not commonly indicated, as it is impossible to suture the inelastic fascia without wasteful shortening of the bone. Bone length can be saved by continuing the skin

traction for an additional period of time—4 to 6 weeks. Closure of stumps by sliding flaps, plastic resection with sacrifice of bone length, or formal reamputation are procedures to be carried out in the Zone of the Interior rather than in an Overseas Theater. Skin grafting of defects may be performed for temporary resurfacing of stumps that will later require plastic procedures or reamputation. It should not be employed when further use of skin traction will promote healing or covering of the bone end with normal skin. Vertical incisions in the stump made for infection or as part of the initial debridement should be closed by secondary suture while skin traction is being maintained to cover the defect at the end.

* * * * * * *

e. Closed Plaster Treatment (Truetta).

The regimen of closed plaster management of war wounds has not been judged applicable to the field conditions of this theater. It is advisable to remove the initial dressing for inspection of the wound in all cases at least by the 15th day. Incorporation of pins or other fixation devices in the initial plaster to maintain the reduction of fractures obtained at the initial operation has been found impractical as a means of transportation splinting.

While the necessity for the rapid turnover of large numbers of casualties might justify an adoption of the closed plaster method of management of compound fractures, a high penalty in the form of skeletal deformity would be the inevitable result. Results obtained by secondary suture do not justify the use of closed plaster for soft part wounds.

Infrequent change of plaster as practiced in the theater has many advantages, particularly when it is desired to allow granulations to cover exposed bone in deep irregular wounds (Orr). It is also an accepted method of management for established infection of bone particularly when the wound has caused an extensive loss of overlying soft parts or there is a bone defect. Small surfaces of bare cortical bone may be removed surgically when this permits closure of the defect by suture. When resurfacing by skin graft is possible in a shallow wound the bare cortical bone may be left for spontaneous sequestration.

f. Military Aspects. Secondary wound surgery in an Overseas Theater must be measured against the objectives that are sought. In general, these are:

(1) To return a soldier to duty with a minimum number of days lost.
 (2) To return patients to the Zone of Interior at an earlier date and in better condition.

(3) To reduce ultimate disability and deformity by preventing or cutting short a phase of late wound infection with fibrosis and other harmful sequelae.

An aggressive attitude is desired in the case of any soldier who may be returned to duty in this theater. On the other hand, to suture a small clean wound that is compounding a fracture of the femur is merely a stunt, as the soft parts will be healed before the bone unites.

It is not desirable to embark on elaborate plastic procedures such as crossed extremity skin flap grafts or operations undertaken for cosmetic purposes.

For the SURGEON:

(S) E. STANDLEE
E. STANDLEE
Colonel, M. C.,
Executive Officer.

DISTRIBUTION:

All Medical Installations	
Surgeon, SOS NATOUSA	800
Surgeon, Fifth Army	500
Surgeon, Seventh Army	100
Surgeon, AAFSC/MTO	800
Surgeon, NATOUSA	200

HEADQUARTERS
NORTH AFRICAN THEATER OF OPERATIONS

Office of the Surgeon

APO 534

1 July 1944

CIRCULAR LETTER NO. 36

SUBJECT: Penicillin Therapy in Wound Management, Surgical Disease, Burns, and Anaerobic Infections

1. *General.*

a. In World War II, two quite different policies have governed the use of chemotherapeutic agents in the management of wounds. Chemotherapy has been recommended: (1) as a substitute for adequate wound surgery, seeking to delay and minimize operative procedures; (2) as an adjunct to established and progressive surgical measures designed to achieve better results with an increased margin of safety. The latter has been and will continue to be the policy governing the management of the wounded in this theater.

b. The use of penicillin as an adjunct to surgery outlined in this circular is defined as *therapy* rather than *prophylaxis*. Routine immunization of troops with tetanus toxoid is a *prophylactic* measure. Administration of penicillin for contaminated wounds and established infection is a *therapeutic* measure. As with all therapy, if the desired goal is to be achieved, intelligent and precise professional supervision of every detail is essential.

2. *Scope of Penicillin Therapy.*

a. Penicillin is accepted as the best available antibacterial agent for gram-positive bacteria and gram-negative diplococci. It is ineffective for gram-negative bacilli.

b. Penicillin does not sterilize dead, devitalized or avascular tissue, nor does it prevent the septic decomposition of contaminated blood clot. There is no evidence that it can neutralize preformed bacterial exotoxins or inhibit the locally necrotizing bacterial enzymes in undrained pus. These limitations demand that surgical wound management retain the principles of excision of devitalized tissue, dependent drainage of residual dead space, evacuation of pus and delayed or staged closure of contaminated wounds (see Circular Letter No. 26, Office of the Surgeon, Hq. NATOUSA).

c. The use of penicillin in an individual patient is based upon the decision that infection is probable or present.

d. It is recommended that parenteral administration be the basis of penicillin therapy. The local or topical use of penicillin is a supplement to systemic therapy only in lesions of the central nervous system, serous cavities and joints. The diffusion of the drug into these areas appears slow and limited.

3. *Penicillin Therapy in Relation to Sulfonamide Therapy.*

a. Topical and oral administration of sulfonamides as first aid measures will be continued.

b. Intravenous sulfonamide prior to initial surgery will be replaced by parenteral administration of penicillin (par. 6, a).

c. At the conclusion of the initial wound operation, the decision will be made either to institute a postoperative course of penicillin therapy or to maintain chemotherapy with sulfonamides. It is recommended that the agents be used individually and not concomitantly. If a course of penicillin is elected, topical frosting of the wound with sulfonamide is omitted. The following observations will serve as a guide in this decision:

(1) Clinical experience with penicillin has been greatest with wounds of the extremities and the thorax. The drug is recommended for these injuries.

(2) The value of penicillin in craniocerebral wounds is well established, but an extensive experience has not been accumulated.

(3) Cleanly debrided soft part wounds uncomplicated by fracture, extensive tissue destruction, or retained missiles are adequately handled by sulfonamide therapy.

(4) Preliminary evaluation of penicillin therapy for fecal contamination of the peritoneal cavity is encouraging but at the present time is inadequate for comparison with sulfonamide therapy. In view of the difficulties in maintaining a fluid intake adequate to safeguard sulfonamide therapy in this group of cases, substitution of penicillin may be made at the discretion of the surgeon. Forcing of fluids is not necessary solely because of penicillin therapy and in fact, reduces the effective concentration of the drug by rapid urinary excretion.

4. *Routes of Penicillin Administration.*

a. Intramuscular. This is the standard route for administration. The deltoid, gluteus and thigh muscles are recommended as the sites for injection. The same area may be used repeatedly. Subcutaneous administration is to be avoided.

b. Intravenous. The intravenous route is reserved for patients with shock or immediately life endangering infection. A single intravenous injection provides a therapeutic concentration of the drug that lasts for two hours. If intravenous therapy is indicated to span a longer period, the injection is repeated or constant drip administration instituted.

5. Dosage.

a. Systemic therapy. Current practice dictates a dosage of 200,000 units in 24 hours, given as 25,000 units every three hours by the intramuscular route. Larger initial dosage or greater 24 hourly dosage have no demonstrable merit. Maintenance of full dosage schedules throughout the course of therapy is better than a graded terminal decrease in dosage.

b. Local therapy. The powdered sodium salt of penicillin is slightly acid and provokes a burning pain and serous discharge if applied to an open wound. A solution containing 10,000 units per c. c. is well tolerated as an intramuscular injection but may produce headache, meningismus and pleocytosis of the spinal fluid after intrathecal injection. The maximal effective local concentration is 250 to 500 units per c. c. The usual concentration employed clinically varies between 500 and 5,000 units per c. c. with predominate usage of a solution containing 1,000 units per c. c. The following dosage schedules are recommended for local instillation:

(1) Intrathecal space	7,500 units
(2) Pleural cavity	25,000 units
(3) Peritoneal cavity	50,000 units
(4) Knee joint	10,000 units

Local instillation of penicillin may be repeated at intervals of 12 to 48 hours in accordance with clinical indications. Needle aspiration and injection is preferable to inlying tubes.

6. *Use of Penicillin in Mobile Hospitals.* The following recommendations are made on the basis of procedures that have been found practical in Evacuation Hospitals:

a. Upon arrival in the shock or preoperative ward, the wounded will receive 25,000 units of penicillin intramuscularly, unless the wound is certainly of a trivial nature. If shock is present, an additional 25,000 units will be given intravenously.

b. Preoperative dosage is continued at 3 hourly intervals. It is more practical to give penicillin to every patient in a preoperative ward at the same time, than to keep each patient on a dosage schedule based on the time of arrival. There is no objection to a time interval of less than 3 hours between the first two injections.

c. The decision to continue penicillin or to substitute sulfonamide in the postoperative period is made when the operation is concluded and the nature and extent of the injury evaluated (see par. 3 c).

d. No patient will be held in a mobile hospital solely for the purpose of continuing penicillin therapy. The usual criteria based on the condition of the patient will determine the suitability for evacuation. In general, the drug is continued for 2 to 3 days beyond the period of clinical recovery from the hazard or subsidence of infection. A course of therapy may be associated with slight fever which disappears after the drug is stopped. Suitable periods of therapy are:

(1) Soft part wounds	5 to 7 days
(2) Compound fractures	10 to 12 days
(3) Thoracic wounds	8 to 10 days
(4) Abdominal wounds	8 to 10 days
(5) Craniocerebral wounds	5 to 10 days
(6) Joint wounds	7 to 14 days

e. Patients evacuated prior to completion of a course of therapy will carry a notation "On Penicillin" in the space provided under the designation "Special attention needed in transit, or other remarks" on the jacket of the Field Medical Record (Form 52d). This will indicate the need for continuation of therapy in holding stations, hospital ships and fixed hospitals.

7. *Use of penicillin in Holding Stations or Hospital Ships.*

a. Form 52d will be examined in each case upon admission to identify those patients receiving penicillin therapy (par. 5 e).

b. 25,000 units of penicillin will be administered intramuscularly every 3 hours to all such designated patients.

8. *Use of Penicillin in Fixed Hospitals.*

a. Patients designated as "On Penicillin" (par. 5 e) will have the course continued on admission to the hospital. Discontinuance of therapy will be the responsibility of a medical officer after he has reviewed the status of the patient.

b. Secondary suture of cleanly debrided soft part wounds does not require penicillin therapy. Soft part wounds requiring delayed debridement or secondary debridement or with established infection may properly receive penicillin.

c. Reparative surgical procedures on wounds complicated by skeletal, joint, nerve, tendon or vascular injury require penicillin therapy.

d. Established wound infection is an indication for penicillin therapy.

e. Early secondary reparative operations through recently healed wounds require penicillin therapy.

9. *Surgical Disease.*

a. Acute or chronic infections such as furuncles, carbuncles, felons, desert sores, tenosynovitis, etc. should be treated with penicillin whenever it is judged that loss of time from duty can be shortened.

10. *Burns.*

a. The local application of sulfonamide crystals or ointments containing sulfonamides is not recommended. Fine mesh (bandage cloth) vaseline or boric acid gauze is preferable. Under no circumstances are tannic acid preparations or other escharotic agents to be used in this theater.

b. Extensive burns or burns that may include areas of full thickness skin loss will be treated systemically with penicillin or if preferred, sulfadiazine.

c. See Circular Letter No. 26 regarding policy of early skin replacement.

11. *Anaerobic Infections.*

a. Clostridial myositis (gas gangrene). Early and adequate wound surgery remains the most effective preventive measure. Early diagnosis of this complication when it occurs, is essential to adequate treatment. Treatment utilizes surgery, penicillin, antitoxin and whole blood transfusion. It is recommended that penicillin be given in the following manner: Initial dosage of 100,000 units intravenously, with 25,000 units intramuscularly at the same time. A course of 25,000 units intramuscularly every 3 hours day and night is instituted. Larger dosages and other regimens have not afforded any more satisfactory results. Sulfonamides are discontinued during penicillin administration.

b. Anaerobic cellulitis and other anaerobic infections. Penicillin therapy is used as with clostridial myositis (par. 10 a).

c. Amputation for anaerobic infection.

(1) It is of prime importance to differentiate between clostridial myositis and other anaerobic wound infections to prevent the needless sacrifice of limbs on the basis of clinical findings of gas and putrid wound exudate.

(2) In the management of clostridial myositis a limb need not be amputated *solely as a measure designed to arrest the infection*. If trauma, vascular occlusion and advancing infection, acting singly or together, have so damaged the extremity that functional restitution is unlikely, amputation is performed as a ready and effective adjunct to the arrest of infection.

(3) The early diagnosis of clostridial myositis and the employment of penicillin and other adjuncts to therapy, permit the management of the infection to be confined to the excision of involved muscles. If the excision of muscles judged necessary to eradicate the infection must be so extensive that functional restitution of the extremity is unlikely, amputation should be performed.

(4) When amputation is performed as a part of the surgical treatment of clostridial myositis, the use of penicillin and other adjuncts to therapy allow other considerations than the eradication of infection to play a part in selecting the level for amputation. Provided all muscles invaded by the infection and

remaining in the stump are carefully excised, a more distal level of amputation may be selected if the ultimate function of the extremity is thereby conserved.

For the SURGEON:

(S) E. STANDLEE
E. STANDLEE,
Colonel, M.C.,
Deputy Surgeon.

DISTRIBUTION:

Surgeon, Fifth Army	600
Surgeon, Seventh Army	300
Surgeon, SOS NATOUSA	800
Surgeon, AAFSC/MTO	600
Surgeon, NATOUSA	300

HEADQUARTERS
NORTH AFRICAN THEATER OF OPERATIONS

Office of the Surgeon

APO 534

29 AUGUST 1944

CIRCULAR LETTER NO. 46

* * * * *
SURGICAL MANAGEMENT OF THE WOUNDED----- III
* * * * *

III—SURGICAL MANAGEMENT OF THE WOUNDED.

Note: The contents of this circular letter as well as Circular Letter Nos. 26 and 36 are to be brought to the attention of every Medical Officer in the Theater who is assigned responsibility for the management of the wounded.

* * * * *

7. Reparative Surgery of the Lightly Wounded.

a. It is an eloquent tribute to the high standards that have been attained in forward surgery that the suture of wounds at the time of the first dressing at the base is established as a routine procedure. To maintain this standard requires constant vigilance in techniques as described in Circular Letter No. 26. The lightly wounded combat soldier is the most valued military asset entrusted to the care of the Medical Corps. His treatment must be carried out or closely supervised by surgeons with mature judgement and experience. There are no "minor" wounds.

b. Forward surgeons will indicate on the record or on the cast the extent of actual skin loss. At the time secondary suture is performed it is difficult

to distinguish between the gaping of a long incision that can be closed by approximation and the existence of a sizeable defect that will require skin graft.

c. An increased use of splinting of soft part wounds following debridement is advisable. Circular plaster encasement if placed proximally on an extremity must be immediately bivalved to avoid constriction.

d. In the closure of wounds, particularly those of the extremities, further refinements are desirable in techniques that have a direct effect on restoration of function and early return to duty.

(1) Transversely divided muscle bundles may be closed by suture, staging the closure of the skin to a later date.

(2) Very accurate approximation of the skin as in a plastic procedure is desirable. When drainage is required, this should be through a counter incision.

(3) More use should be made of the principles of plastic surgery, viz., the advancement and rotation of skin flaps, zig-zag plastics and other tricks of closure that minimize scar contracture and limitation of motion.

(4) Trauma to skin margins by rat tooth forceps and rough handling is productive of necrosis and imperfect healing.

(5) Prolonged hospital neglect of unhealed wounds and skin defects must be stopped. It is recommended that the chief of surgical service personally review cases of unhealed soft part wounds that remain in hospital longer than four weeks so that proper treatment can be expedited.

8. Amputations.

a. The most important phase in the management of amputations is the functional rehabilitation of the patient by the fitting of a prosthesis. Amputation centers have been established in the Zone of the Interior for this purpose. It is the expressed desire of The Surgeon General that the early management of amputations in overseas theaters conform with policies that have been set forth in numerous Bulletins and Circular Letters. There will be no deviation from these policies in this theater.

(1) Forward Area.

(a) Level. Amputations will be performed at the lowest possible level except that a proximal amputation will be done in preference to a disarticulation.

(b) Technique. The properly performed flapless guillotine stump exhibits slightly concave open cross section of the extremity. A circular incision is made through the skin at the lowest level compatible with viable tissue and the skin allowed to retract; the fascia is then incised at the level to which the skin has retracted. The superficial layer of muscle is then cut at the end of the fascia and permitted to retract. At its point of retraction, the deep layers of muscle are cut through to the bone. After the deep muscles have retracted the periosteum of the bone is cleanly incised and the bone sawed through flush with the muscles. No cuff of periosteum is removed as in a closed amputation. Bone denuded of periosteum will sequestrate if

infection is present and a ring sequestrum often results when the periosteum has been removed. It is important also that no periosteum be elevated or torn from the bone in the stump by rough handling.

(c) Dressing and skin traction. The end of the stump is dressed with fine mesh gauze in such a manner that it does not overlap the skin edges. Skin traction is applied immediately. This may either be by a stockinette cuff attached with ace adherent or by adhesive tape. Traction is obtained preferably by a light plaster cast with a wire ladder banjo. The cast always incorporates the joint above the amputation, e. g., a spica for an amputated thigh. A Thomas splint may be utilized as an alternative. When this is done in lower leg amputations, a posterior splint from midthigh to beyond the stump is provided to prevent flexion contracture of the knee. Medical Supply Item No. 36614—Cord, Elastic, for Traction—is available and is preferable to plasma tubing for the elastic traction. Before evacuation, the traction is examined and if doubt exists as to its effectiveness, it is reapplied.

(2) Base.

(a) All thigh amputations and those of the leg at or near the site of election will be treated by continuous skin traction. Secondary suture or skin grafting of the terminal defect with or without revision will not be done. Removal of the cast or splint and maintenance of 6 to 10 pounds of traction over a pulley at the foot of the bed is recommended. Traction is continued for several weeks (at least 6) until all layers of soft tissue have been firmly fixed by scar formation. Priority air evacuation to the Zone of Interior is available for amputation cases as soon as they are able to be transported. Traction during evacuation is provided for by stockinette and a banjo plaster.

(b) Amputations in the lower third of the leg and of the upper extremity may be closed by secondary suture provided the wound is clean and a course of penicillin is instituted. If closure is not feasible, skin traction is maintained.

(c) Amputations of the thigh or leg performed in fixed hospitals for trauma, vascular insufficiency or infection will be carried out in conformity with the above principles. In the upper extremity, modifications to secure primary or early secondary closure are permissible in individual cases.

(d) Patients received with injuries that require amputation will benefit by an explanation of why the amputation is necessary prior to the operative procedure. About one in five patients will exhibit psychic reactions, often depressive in type, a few days after the operation. As soon as the patient is surgically comfortable and mentally receptive, an interview with a psychiatrist may be extremely helpful. Particular attention should be paid to what the patient may reasonably expect in the way of aid. The establishment of amputation treatment centers in the ZI may be explained, and assurance given relative to prosthetic appliances, and his potential economic and social status. Fortification of this type, before a patient becomes the target of a sympathetic family and friends, may tip the scales in favor of rehabilitation in contrast to life long disability and resentment.

9. Fractures of the Femur.

The program of reparative surgery in fixed hospitals, improvements in skeletal traction techniques, and penicillin therapy are expected to result in improved apposition and alignment of the fractures and improved knee and muscle function, after the fracture has united. Therefore the following recommendations are made:

a. Fractures treated by skeletal traction.

(1) Knee flexion produces quadriceps stretch and predisposes to patellar fixation. As flexion increases quadriceps exercises become more difficult. While some knee flexion is necessary for comfort and to aid in reduction of the fracture it should be held to a minimum. For lower third fractures two-wire skeletal traction is recommended. By this method traction is made by a wire (or pin) in the tibial tubercle while a second wire through the lower femoral fragment permits vertical "lift". Extreme knee flexion is avoided.

(2) Quadriceps setting exercises and knee motion should be carried out several times daily as soon as wound management permits. Knee motion begun early produces less strain on the fracture site than that begun late after joint "stiffness" has set in.

(3) Duration of traction. Traction in the great majority of cases must be continued until there is *bony* fixation clinically and roentgenologically. This will average about 10 to 12 weeks. Prolonged traction permits an increasing range of knee motion and will prevent angulation in a cast during evacuation to the Z of I.

(4) A low spica extending to the knee on the well side is the recommended splinting for transportation to the Z of I. Uncertainty of evacuation and because a spica is preferably applied at least 48 hours prior to transporting, have resulted in many fractures of the femur remaining in plaster for several weeks or months awaiting and during evacuation, thereby predisposing to restricted knee motion. Collaboration between the surgeon and the disposition officer permits the application of the spica 48 hours prior to evacuation. Fractured femurs immobilized after traction are excellent priority 4 cases for air evacuation.

b. Fractures Treated by Internal Fixation.

(1) Wire loop fixation. Alinement should be protected by prolonged skeletal traction followed by a spica (see 9 a (3) (4)).

(2) Plating or Multiple Screw Fixation. Postoperative immobilization in a Thomas splint with Pierson attachment permits early knee motion. Following wound healing and a period of knee motion and quadriceps exercises, a spica (see 9 a (3) (4)) is used for evacuation to the ZI.

IV—DISASTER MANAGEMENT IN FIXED HOSPITALS.

Any hospital in the theater, no matter how far removed from the Combat Zone suddenly may be called upon at any hour of the day or night to receive and care for large numbers of wounded or injured. It is essential, therefore,

that plans for such an emergency be made in advance and be clearly understood by both administrative and professional staffs. The following principles are important:

1. Early recognition of what may be termed the "pattern of trauma" so that appropriate treatment may be instituted without delay. This is established by a careful examination of a representative sample of the injured and supplemented by inquiry regarding the source and nature of injury, the time elapsed since injury and the possible number of casualties to be admitted. Serious secondary effects may be masked by obvious primary manifestations: thus, the lethal effects of underwater blast may be masked by the effects of immersion; the inhalation of noxious fumes may pass unrecognized while superficial flash burns are treated. With explosions of ammunition ships or dumps in a theater of war, consideration must always be given to the possibility that agents of chemical warfare may have been released.

2. Establishment of wards adjacent to the admitting ward for reception of patients is essential rather than distribution of the new patients throughout the hospital.

3. Triage is established at the time of admission to sort three groups of patients:

a. Those in immediate need of resuscitation, close preoperative supervision and emergency operative procedures.

b. Those that require surgery but will be transportable if and when it is necessary to reduce the backlog of cases awaiting operation by transfer to other hospitals for treatment.

c. Lightly injured that will be discharged to duty after a short period.

Patients in group a. will be sent to a "shock" ward where treatment is carried out under close supervision. They receive first priority X-ray and laboratory service.

Group b. require ordinary ward supervision and second priority X-ray and laboratory service. Clinical records should be maintained and a tentative evacuation list prepared.

Group c. should be fed and made comfortable, but professional attention postponed during the emergency period unless special indications arise.

4. Surgical Management.

Patients in group a. are assigned to operative teams who direct the preoperative care, request necessary laboratory examinations and schedule the operation. One or more officers are assigned to the Shock Ward and remain on the ward. It is their duty to be familiar with the progress of each patient; what treatment has been ordered, and what examinations are in progress or have been completed. In addition they carry out resuscitation measures under surgical direction.

After operation, if the patient is in precarious condition he should be returned to the Shock Ward or to an adjacent Postoperative Ward—but under no circumstances sent to some remote ward of the hospital.

5. Whole Blood Transfusion.

Plans must include a well thought-out method of supplying whole blood in considerable quantity. Circular Letter No. 30 should be studied. Reliance cannot be based on securing blood from theater transfusion units, as the function of these installations is to supply blood to armies in combat. A supply of vacuum bottles, transfusion sets, refrigerator space and a donor list from the detachment will enable the laboratory to start a banked reserve. Immediate steps may be taken to supplement the donor list from organizations in the immediate vicinity. Type specific blood should be used as most economical of donors.

6. Reserve Surgical Supplies.

Sufficient supplies must be kept on hand at all times to meet the demands of an emergency. Vaseline gauze, fine mesh gauze and other sterile supplies may be stored in sealed containers and resterilized as often as necessary.

7. X-ray Service.

Request for X-ray examinations should be based on the priority of the case, and the X-ray Department must not be flooded with examinations that can be postponed. Patients that may be transferred to another hospital for surgical operation need not be X-rayed unless necessary to the determination of transportability or disposition.

A system for viewing wet films should be planned, and facilities made available for the films to accompany the patient to the operating theater.

8. If doubt exists regarding the nature, source of circumstances surrounding the incident, examination of casualties dead on arrival or dying in hospital may be of importance not only for official record but for treatment of the survivors.

For the SURGEON:

(S) E. STANDLEE
E. STANDLEE,
Colonel, M. C.,
Deputy Surgeon.

DISTRIBUTION:

Surgeon, Fifth Army	600
Surgeon, Seventh Army	300
Surgeon, SOS NATOUSA	800
Surgeon, AAFSC/MTO	750
Surgeon, Replacement Command	50
Surgeon, NATOUSA	300

HEADQUARTERS
MEDITERRANEAN THEATER OF OPERATIONS
UNITED STATES ARMY

Office of the Surgeon

APO 512

10 March 1945

CIRCULAR LETTER NO. 8

SUBJECT: Notes on Care of Battle Casualties.

The contents of several previous circular letters pertaining to the surgical management of the wounded are consolidated and in certain instances extended or modified in the following recommendations.

1. The care of the wounded must always be shaped by conditions and circumstances that govern the tactical situation at the moment. It has been shown by this Theater that the surgery of war need not be molded by concessions to the need for haste and the confusion of caring for overwhelming numbers of patients. Military surgery is not a crude departure from accepted surgical standards, but a development of the science of surgery to carry out a specialized and highly significant mission. Modern surgical treatment employs many adjuncts to operative techniques, such as chemotherapy, fluid replacement therapy, the transfusion of whole blood and fractions of blood employed as substitutes, potent anesthetic agents and narcotics. These tools are as important to the military surgeon as his scalpel, but are equally dangerous to the patient if used without expert precision. One of the major responsibilities of the military surgeon is to make full use of these and similar measures and at the same time to avoid the dangers that may attend their usage.

The ever-present necessity for evacuation of the wounded to the rear is in fundamental conflict with ideal surgical management of the individual patient. To minimize this conflict, close coordination between the functions of administration and professional services is required. It is the responsibility of the medical officer charged with the surgical management of the patient to place technical procedures properly, both in time and in space, with due regard to the tactical situation on the one hand and to the welfare of the patient on the other. Unless the surgeon visualizes his position and the function of his hospital in relation to other surgeons and other hospitals, he may become confused in the mission he is to perform. Although some needed operation may be performed correctly, the military effort may be impeded and unforeseen harm done to the patient if the operation is done at the wrong time or in the wrong place.

It is the responsibility of administrative officers charged with the establishment of evacuation and hospitalization policies to adapt the schedules of movement of patients to the maintenance of highest standards of surgical treatment. Priority of movement must be accorded to patients with certain types of injuries just as the duration of hospitalization in a given zone must be differentially adjusted to the urgent surgical needs of the patients. The term "nontrans-

portable" as relating to the unfitness of battle casualties for interhospital transfer must, when military necessity permits, be extended beyond actual danger to life by a consideration of the likelihood of deformity, ultimate disability, and delay of recovery when these hazards exist.

Just as the placement of various types of hospitals and consequently the provision of the facilities for surgery are determined by the geographic deployment of a military force, phases of surgical management exist that in general will conform with military echelons. These phases of surgical management are: first aid measures, initial wound surgery, reparative wound surgery, reconstructive surgery, and rehabilitation measures.

First Aid Measures. Within the divisional area surgical management is limited to first aid measures and emergency resuscitation. Hemorrhage is controlled, splints and dressings applied, morphine administered for pain, plasma infused for resuscitation, a booster dose of tetanus toxoid is given, and chemotherapy initiated.

Initial Surgery. Actual conditions of warfare will determine both the facilities provided for emergency wound surgery and their location with reference to the combat area. In general, initial surgery is concerned with complete resuscitation so that surgery may be performed, and with surgical procedures designed to prevent or eradicate wound infection. Many of the seriously wounded casualties can be resuscitated only by a surgical operation in conjunction with transfusion and plasma therapy. For this reason, it is important that delays for the purpose of resuscitation ahead of an installation equipped for major surgery be kept at a minimum. Placement of the advance surgical hospital in physical proximity to the divisional clearing station accomplishes this end.

Reparative Surgery. The general hospitals of the communications zone receive casualties from the hospitals of the forward area for further surgical management. As the initial wound operation is by definition a limited procedure, nearly every case requires further treatment. Soft part wounds, purposely left unsutured at the initial operation, are closed by suture, usually at the time of the first dressing on or after the fourth day. Fractures are accurately reduced and immobilized until bony union takes place.

Designed to prevent or cut short wound infection either before it is established or at the time of its inception, this phase in the surgical care of the wounded is concerned with shortening the period of wound healing and seeks as its objectives the early restoration of function and the return of a soldier to duty with a minimum number of days lost. In addition, it affords the return of patients to the United States at an earlier date and in better condition and minimizes the ultimate disability and deformity in the seriously wounded.

The success of this important phase of surgery depends on the provision of an adequate period of hospitalization in addition to competent surgical care, particularly in specialized fields. It is not to be confused with the reconstructive phase of surgery, which may be postponed until return to the Zone of the

Interior. The ideal time for the procedures of reparative surgery will be found between the fourth and tenth days after wounding. The patient then becomes "non-transportable" for a period of time which, in the case of fractures, may extend to eight or ten weeks. Transfer of patients between fixed hospitals within the zone of communications must be regulated with these considerations in mind, otherwise the objectives of this phase of surgical management may be sacrificed. The establishment of special centers within general hospitals for certain types of surgery during this phase is highly desirable, as the procedures are oftentimes of considerable magnitude and call for mature and experienced professional judgment. Advancement of general hospitals in close support of Army or utilization of air evacuation from Army to more remote fixed installations are two measures that further the establishment of a program of reparative surgery.

Reconstructive Surgery. Early evacuation to the United States is desirable for patients whose return to duty cannot be anticipated within the limits of the hospitalization policy of an overseas theater. The phases of reconstructive surgery and rehabilitation may then be integrated.

2. *Wound Management.*

a. *Initial Wound Surgery.*

(1) X-ray. In the preoperative examination of a battle casualty X-ray examination is essential.

(2) Adequate assistance and instruments, a good light, and access to the wound that is unhampered by faulty position of the patient are basic requirements. Ample preparation of a wide field by shaving the skin will allow for extension of the incision or counterincision.

(3) Bold *incision* is the first essential step in an operation on a wound. Adequate exposure is necessary to carry out *excision* of devitalized tissues. On the extremity the line of the incision is placed parallel with the long axis of the limb; elsewhere it follows the natural lines of skin structure. Only the devitalized skin of the margins of the wound is excised in a strip rarely wider than 2 to 3 mm. The creation of circular skin defects is avoided.

(4) Incision and excision of the fascial layers is performed in the same manner to give free access to devitalized muscle. Unrestricted exposure of successive anatomic layers permits the complete excision of devitalized muscle and the removal of foreign bodies.

(5) The surgeon must be familiar with the blood supply of muscles, particularly large groups like the gastrocnemius-soleus muscles of the calf and respect these vessels in his dissection. Deep recesses of the wound containing foreign bodies may be approached by counterincisions planned anatomically rather than by sacrificing normal muscle structures.

(6) Use fine hemostats. Use the finest ligature compatible with the procedure. Include the smallest possible amount of tissue in ligating a bleeding point. Do not repeatedly bite the wound with tissue forceps. Sponge gently with pressure instead of wiping. Remaining devitalized tissue produced by

the missile or by the surgeon must slough before the wound can be closed by secondary suture.

(7) Large wounds in regions of heavy muscles, particularly when complicated by comminuted fracture, require especial care. The depths of these wounds must be opened by a long incision with counterincision if necessary to allow free dependent drainage.

(8) Only enough dry, fine, mesh gauze is used to separate the surfaces of the wound. It should be smoothly laid in the wound—not “packed”.

(9) Ether, white soap, and benzene, have slight but definite necrotizing effects on living muscles. Green soap and various other substances used as detergents have greater necrotizing effects. Physiological saline solution is relatively innocuous. In general, progress in wound management points away from the introduction of any agent into a wound, either for its supposed mechanical or antiseptic effect.

(10) Old wounds (48 hours or longer) are managed in accord with the same principles, except that in selected cases of established pyogenic infection and anaerobic cellulitis with toxicity the general condition of the patient to withstand radical surgery may be improved by immobilization, penicillin and repeated blood transfusions until an optimum time is selected for intervention. In postponement of surgery the advantage that accrues from the immediate drainage of septic hematomas, large masses of dead muscle, and fascial plane abscesses, is not to be forgotten. Postponement of surgery is not justified if clostridial myositis (gas gangrene) may be present.

(11) Proper transportation splinting is provided for skeletal and joint injuries. Soft part wounds are supported by firm pressure dressings and may, if extensive, be advantageously enclosed in a light plaster. Care is taken to avoid any constricting action of a pressure dressing placed on an extremity. Plaster casts must always be padded and split or bivalved before the patient is returned to the ward.

b. *Reparative Wound Surgery.*

(1) On arrival at a hospital where bed care can be assured for a period of at least fifteen days (soft part wounds) the original dressing is removed in the operating room under aseptic precautions. X-ray films should be at hand. If the primary wound operation has been complete and has been properly done, all superficial wounds and many deep wounds may be closed by secondary suture at this time (4 to 10 days). Foreign bodies in soft parts adjacent to the wound are removed. Following suture, the part is immobilized, preferably by a light plaster, or if this is impractical, by bed rest.

(2) The presence of residual dead tissue or established infection manifested by profuse discharge of pus, reddening and edema of the wound margins, persistent fever or toxicity is an indication for delay in secondary suture. When these manifestations are present but minimal, the wound is allowed to “clean up”. This process can be hastened by moist dressings or by additional surgical excision of devitalized fragments. Secondary suture

can then be performed in a few days. If established infection is severe, or if the patient is toxic and anemic from deep seated sepsis, a course of penicillin therapy and blood transfusions is instituted and followed by radical wound revision, and staged closure.

(3) Wounds that have been laid open properly at the initial operation tend to gape widely and give the impression of extensive skin loss. This appearance is actually due to loss of support of the deep fascia. Skin defects are more apparent than real in the majority of cases and closure of a defect is made from local tissue with suture in a straight line when possible. Undermining with advancement or rotation of flaps provides sufficient skin in nearly all instances and is preferable to grafting.

(4) Technical considerations that are important to the success of secondary wound closures are:

(a) Atraumatic handling of tissue.
(b) Avoidance of tension sutures.
(c) Accurate approximation of skin margins. The epithelial bridge is the main support of the wound for a considerable period of time.

(d) Obliteration of dead spaces by pressure dressings and immobilization. Stab wound drainage may be instituted when desired and is preferable to drainage through the suture line.

(e) Leaving sutures in place for twelve days if stitch infection does not develop.

(f) Suture in straight lines rather than the creation of sharp angles.

(5) Preliminary bacteriologic analysis of the flora of a wound does not provide information pertinent to making the decision to perform secondary suture or allow the prediction of the result. If the suture is not successful because of infection, appropriate studies and corrective therapy is instituted before resuture is attempted.

(6) The conditions that most often jeopardize results are:

(a) Suture of a wound that is discharging pus. This usually means dead tissue in the depths.

(b) Too early motion. (Wounds breaking down for this reason should be immediately resutured.)

(c) Unrecognized foreign bodies adjacent to the wound.

c. Closed Plaster Treatment.

(1) The regimen of closed plaster management of war wounds is not considered as satisfactory as the method described above when field conditions permit the use of the latter.

(2) While the necessity for the rapid turnover of large numbers of casualties might justify an adoption of the closed plaster method of management of compound fractures, a high penalty in the form of skeletal deformity would be the inevitable result. Results obtained by secondary suture do not justify the use of closed plaster for soft part wounds.

(3) When it is desired to allow granulations to cover exposed bone in deep irregular wounds, the wound may be encased in plaster subject to in-

frequent changes. This is also an accepted method of management for established infection of bone, particularly when the wound has caused an extensive loss of overlying soft parts or there is a large bone defect. Before application of the plaster, all devitalized tissue and loose bone fragments are excised. There should be no pocketing or pooling of pus in the fracture site or adjacent fascial compartments. Small surfaces of bare cortical bone may be removed surgically when this permits closure of the defect by suture or skin graft.

* * * * *

h. Amputations.

(1) The most important phase in the management of amputations is the functional rehabilitation of the patient by the fitting of a prosthesis. Amputation centers have been established in the Zone of the Interior for this purpose. It is the expressed desire of The Surgeon General that the early management of amputations in overseas theaters conform with policies that have been set forth in numerous Bulletins and Circular Letters and which are summarized below.

(2) In the forward area, amputations will be performed at the lowest possible level except that a proximal amputation will be done in preference to a disarticulation. The technique for the performance of amputations is as follows: A circular incision is made through the skin at the lowest level compatible with viable tissue and the skin allowed to retract; the fascia is then incised at the level to which the skin has retracted. The superficial layer of muscle is then cut at the end of the fascia and permitted to retract. At its point of retraction, the deep layers of muscle are cut through to the bone. After the deep muscles have retracted, the periosteum of the bone is cleanly incised and the bone sawed through flush with the muscles. No cuff of periosteum is removed as in a closed amputation. Bone denuded of periosteum will sequestrate if infection is present and a ring sequestrum often results when the periosteum has been removed. It is important also that no periosteum be elevated or torn from the bone in the stump by rough handling. The properly performed flapless guillotine stump exhibits a slightly concave open cross section of the extremity.

(3) The proper dressing of the stump is important. The end of the stump is dressed with fine mesh gauze in such a manner that it does not overlap the skin edges. Skin traction is applied immediately. This may either be by a stockinette cuff attached with ace adherent or by adhesive tape. Traction is obtained preferably by a light plaster cast with a wire ladder banjo. The cast always incorporates the joint above the amputation, e. g., a spica for an amputated thigh. The Army Hinged Half-Ring splint may be utilized as an alternative. Medical Supply Item No. 36614, Cord, Elastic, for Traction, is available and is preferable to plasma tubing for the elastic traction. Before evacuation, the traction is examined and if doubt exists as to its effectiveness, it is reapplied.

(4) At the base areas, secondary closure of a circular guillotine amputation stump is not indicated, as it is impossible to suture the inelastic fascia

without wasteful shortening of the bone. Bone length can be saved by continuing the skin traction for an additional period of time—4 to 6 weeks. Closure of stumps by sliding flaps, plastic resection with sacrifice of bone length, or formal reamputation are procedures to be carried out in the Zone of the Interior rather than in an overseas theater. Skin grafting is not indicated. Vertical incisions in the stump made for control of infection or as part of the initial debridement should be closed by secondary suture while skin traction is being maintained to cover the defect at the end.

(5) In the Communications Zone continuous skin traction is maintained in all cases. After removal of the cast or splint, maintenance of 4 to 6 pounds in below-knee and 6 to 8 pounds in thigh stumps of traction over a pulley at the foot of the bed is indicated. Traction is continued until the wound is healed. Priority air evacuation to the Zone of Interior should be available for amputation cases as soon as they are able to be transported. Traction during evacuation is provided for by stockinette and a banjo plaster.

i. *Fractures.*

(1) The management of a compound fracture is divided into the following phases: first aid splinting in the field; debridement and the application of transportation splinting in a mobile hospital; final correction of the deformity and attainment of wound healing and bony union at a fixed hospital (reparative phase); reconstructive or corrective surgery (bone grafting, osteotomy, sequestrectomy, etc.) in the Zone of the Interior. In every phase attention is directed to the *ultimate function of the extremity* which is dependent on muscles, nerves, blood vessels and joints as well as on skeletal integrity.

(2) *Transportation Splinting* applied subsequent to initial wound surgery for evacuation from mobile to fixed hospitals is not designed to provide anatomic reduction or prolonged fixation in suitable reduction. Except in rare instances it is by plaster of Paris. Plaster bandages are adequately padded and bivalved or split through all layers to the skin. Skeletal fixation by the incorporation of pins or wires into the plaster is not recommended. The only indication for the use of internal fixation in the forward area is to preserve the vascular integrity of the extremity.

Methods of transportation splinting that have proved safe and comfortable are:

Femur: A low waisted "one and one half" plaster spica with the knee slightly flexed and minimal abduction.

The Tobruk plaster and the Army leg splint with skin traction do not provide as adequate immobilization and should only be used as emergency measures when large numbers of casualties or multiple wounds in a single casualty demand concessions to operating time or for special indications such as the presence of a colostomy or suprapubic cystostomy. When restricted to lower third femoral fractures and knee joint injuries the Tobruk splint provides adequate immobilization.

Humerus: A thoracobrachial plaster with the arm forward in internal rotation.

A plaster Velpeau bandage binding the arm to the trunk with the forearm flexed at a right angle and placed across the chest.

The Army humerus splint designed for field (first aid) use is not suitable for postoperative transportation splinting.

A hanging cast is both uncomfortable and ineffective as a method of transportation splinting.

Forearm:

A circular plaster bandage that extends to the midbrachial region with flexion of the elbow and extending only to the proximal palmar crease.

Plaster slabs in the form of "sugar-tongs."

Tibia and Fibula:

A circular plaster bandage from toes to groin. The knee is slightly (15 degrees) flexed and the foot held in neutral position at 90 degrees to the axis of the limb. A plantar slab may extend beyond the toes to afford protection, but hyperextension is to be avoided.

(3) *Reparative Surgery of Compound Fractures.* (See Wound Management, par. 2 c on Closed Plaster Treatment.)

Reparative surgery in compound fractures is made necessary by leaving unsutured the large incisions made for debridement and the recognized fact that splinting suitable for transportation is inadequate for complete reduction and fixation of the fracture. The goal is functional restoration of the extremity and demands treatment of muscle and nerve injury as well as skeletal damage. Observance of certain basic principles are important to the success of this phase of management.

Preoperative correction of anemia by whole blood transfusion. Despite whole blood transfusion for resuscitation in the forward area, a high percentage of compound fracture cases will arrive at a fixed hospital in the Communications Zone with low red cell volume (hematocrit) and hemoglobin. An approximate estimate of the quantity of whole blood needed to restore red cell volume may be deduced from the rough rule of 500 cc blood for each 3 points of the hematocrit or 0.9 grams of hemoglobin. In the use of whole blood transfusion for correction of secondary anemia or hypoproteinemia the total volume administered in a 24 hour period should not exceed 1000 cc except to replace blood lost at operative procedures. This is in contrast with the larger volumes that are administered for resuscitation when the total circulating blood volume may be greatly reduced. No correlation exists between the hematocrit or hemoglobin levels and circulating blood volume and care must be taken not to precipitate pulmonary edema by overtransfusion of a patient in whom the blood volume has been restored by dilution but who still shows a greatly reduced cell volume (hematocrit) and hemoglobin.

The surgical elimination of residual necrotic tissue. No available chemotherapeutic agent can "sterilize" an open wound containing devitalized tissue or blood clot. A properly managed clean wound requires no local antiseptic.

The control of invasive infection by systemic chemotherapy. Systemic penicillin therapy in a dosage of 25,000 units every three hours is recommended

as a routine adjuvant for secondary operations on compound fractures. Treatment is continued postoperatively until the likelihood of invasive infection is passed.

Reduction or closure of soft tissue defects. Exposed cortex of bone, nerves and tendons are vulnerable to the necrotizing effect of wound suppuration and are protected by the apposition of adjacent soft parts. Transversely divided important muscle groups are united by suture. Fascial compartments are restored to minimize scarring and improve muscle function. Certain of these procedures may be staged operations. Emphasis should not be placed on early or complete skin closure, as in most cases any remaining cutaneous defect will heal before bony union occurs.

Provision of drainage for residual exudate. Severely comminuted fractures may require dependent drainage in association with the apposition of soft parts over exposed bone. Exteriorizing fascial plane incisions have proven superior to stab wounds or rubber drains. Upper extremity fractures rarely present a drainage problem. The thigh may be drained by a posterolateral incision between the vastus lateralis and the biceps. An adequate posterior drainage route for the shaft of the tibia does not exist and such an injury may necessitate a period of "on the face" nursing.

Internal fixation of battle fractures is not feasible commonly because of extensive comminution. Further, the method demands further periosteal stripping and surgical trauma to the wound. Limitation of the use of this method to cases carefully selected by specialists fully experienced in the techniques and hazards of its usage is strongly advised. An example of sound usage is the employment of screws for restoration of the articular surface of a major joint. Reduction of the fracture is the goal of reparative surgery—not the use of internal fixation.

Use of suspension traction. The application of suspension traction in the treatment of fractures, particularly those of the femur, is the safest and most satisfactory method of management. In fixed hospitals fractures of the femur should be treated by skeletal traction for ten to twelve weeks until enough union has been obtained to permit safe transportation to the Zone of the Interior in a plaster spica. The use of suspension traction promotes the maintenance of joint and muscle function and prevents angulation or over-riding deformity.

Overpull and resulting distraction must be avoided at all times, particularly in cases associated with injury or division of the thigh muscles. Certain cases of this type require very expert attention and delay in the application of traction until firm fibrous union of muscles has been attained by suture.

j. *Joints.*

Early complete debridement is the keystone of success in the management of wounds that compound a joint. The wound of the soft part is excised and the bone and cartilage damage assessed through incisions that provide complete exposure. Comminuted fragments of bone and cartilage are removed from the joint and a careful search made for foreign material. Badly comminuted frac-

tures of the patella are excised completely as a step in the debridement of a knee joint wound.

Every effort is made, after cleansing the joint cavity, to close the capsule. The skin is left unsutured. Closure of the joint is especially difficult in the face of extensive loss of soft parts. When it is impossible to close a joint by suture of synovia or capsule, an occlusive dressing is applied. On arrival at a fixed hospital, effort is directed toward closing the defect by advancement of a skin flap or other plastic procedure.

Adequate exposure of the hip joint is a specialized procedure that requires precise anatomical orientation. The same principle of management must be applied to improve the results of this particular lesion.

Penicillin is inserted into a joint at the end of the operation. In joints that are accessible to needle aspiration, accumulating exudate may be withdrawn and penicillin injected during the postoperative period.

Wounds of the ankle joint with comminution of the os calcis or astragalus are peculiarly liable to sepsis. Initial debridement of comminuted bone fragments must be minimal if function is to be preserved and early efforts are made in the reparative surgical phase to reduce or close the skin defect with split thickness graft when necessary. When sepsis is established, subperiosteal excision of necrotic bone fragments followed by wound closure by graft or suture should not be delayed.

For the SURGEON:

(S) E. STANDLEE
E. STANDLEE,
Colonel, M. C.,
Deputy Surgeon.

DISTRIBUTION:

Surgeon, PENBASE	300
Surgeon, NORBS	20
Hq. A/G of S	10
Surgeon, Adriatic Base Command	100
Surgeon, Fifth Army	600
Surgeon, AAFSC/MTO	700
Surgeon, Replacement Command	50
Surgeon, Rome Area Command	25
Surgeon, Hq. Command, AF	30
Surgeon, MTOUSA	300

INDEX

MEDICAL DEPARTMENT, UNITED STATES ARMY

The volumes comprising the history of the Medical Department of the United States Army in World War II are divided into two series: (1) The administrative and operational series, which constitutes a part of the general series of the history of the United States Army in World War II, prepared by The Surgeon General and published under the direction of the Chief of Military History; and (2) the professional, or clinical and technical, series, prepared by and published under the direction of The Surgeon General. This is one of the volumes published in the latter series.

INDEX¹

- Abduction of thumb—
in splinting for carpal scaphoid fractures, 292
in splinting for radial-nerve paralysis, 47
in testing for radial-nerve injury, 72
- Abscess formation in fractures of bones of leg, 163
- Abscesses:
about fracture site, 93
about lower femoral pin in external skeletal fixation, 205
drainage of, 63, 72
of fascial plane, 72, 139
- Accidents. *See* Noncombat orthopedic lesions.
- Acetabulum, damage to articulating surfaces of, 237
- Adjutant General's Office, MTOUSA, 280 283
- Agents of wounding. *See* Wounding agents.
- Aidmen, medical, 32-33
- Air evacuation of amputees, 253, 257
- Alinement of fractures by—
external skeletal fixation, 208
internal fixation, 134, 198, 199-200, 202
plaster immobilization, 40-41, 125, 165, 182
skeletal traction, 139, 149, 182
- Ambulation, after meniscectomy, 286
- American Red Cross, 31
- Amputation, 245-270
avoidance of, 130
directives on, 7, 245, 247-249, 251-254, 257, 259
in fractures of—
bones of foot, 183
bones of leg, 166, 175-176
femur, 139, 158
in reparative-surgery program, 107, 197
in wounds of knee joint, 216, 231, 235
indication(s) for, 245, 246-247, 266-269
disease as 247, 262-264
infection as, 247, 249
trauma as, 246, 264-265
trenchfoot as, 262
vascular insufficiency as, 246, 249
- Amputation—Continued
level of, 247-249
multiple, 262, 270
of arm, 261
of leg, 253, 254
of lower extremity, 261, 262, 269
of thigh, 253, 254
of upper extremity, 247-249, 254
psychological considerations in, 245
recommendations on, by consultant in orthopedic surgery, 7-8
reparative surgery after, 253-257
site of, 262
statistics on, 260-270
technique of, 251-253
through long bones, 249
timing of, 269
traction after, 253, 256, 257
traumatic, 246, 249, 262, 264, 265
- Amputation centers, in Zone of Interior, 245, 253
- Amputation stump, 251-260
closure of, 253-257
healing of, 256-257
revision of, 259-260
- Amputees:
air evacuation of, 253, 257
deaths of, 260
- Anatomic restoration, as factor in disposition of patients, 295
- Anemia, secondary, before reparative surgery, 82-83
- Anesthesia for reparative surgery, 83
- Angulation of fractures of—
bones of foot, 182
bones of leg, 167
femur, 154-155
humerus, 34, 125
- Ankle:
disarticulations at, 261
emergency splinting of, 35-39
transportation splinting of, 51
- Ankle joint:
arthrotomy of, 286-287
involvement of, in fractures of bones of leg, 175

¹ Unless it is otherwise specified, all references in this index are to (1) orthopedic surgery, (2) battle-incurred compound fractures, and (3) the Mediterranean (formerly North African) Theater of Operations. "Disposition of patients" refers to disposition from general hospitals of base sections.

- Ankle joint—Continued
 loose bodies in, 286-287
 position of, in immobilization of fractures of bones of leg, 164
 resection of, 243-244
 use of external skeletal fixation after, 210
 wounds of:
 management of, 243-244
 suppurative arthritis in, 244
- Ankylosis, in wounds of hip joint, 214, 237, 242
- Anomalies, congenital, disposition of patients with, 274
- Antibiotic therapy, 64, 72, 83. *See also* Penicillin.
- Anzio, 43, 63, 81, 138, 139, 186, 217
- Appliances, manuals on, 31-32
- Arch supports, use of, in management of painful feet, 275
- Arm. *See* Humerus.
- Army Air Forces:
 disposition of patients in, 276-277
 elective surgery policy in, 277
 hospitals supporting, 276, 280, 282
- Army half-ring leg splint. *See* Hinged half-ring leg splint.
- Arthritis:
 as factor in management of noncombat lesions, 274, 279
 suppurative:
 of hip joint, 237, 242, 243
 of knee joint, 214, 215, 217-219, 227, 236
 of smaller joints, 244
 traumatic, 293
- Arthrotomy of—
 ankle joint, 286-287
 elbow joint, 286-287
 knee joint, 231, 235-236
 contraindication for, 283-284
 disposition of patients after, 277-278, 281, 282-283, 284, 286-287
 incision for, 223
 prognosis after, 284-285
 statistics on, 277, 280, 282, 286
 theater policy on, 279
- Articular cartilage:
 damage to—
 in fractures of humerus, 123
 in wounds of hip joint, 241
 in wounds of knee joint, 219
 necrosis of, in wounds of knee joint, 221
 removal of, 223, 243, 279, 286
See also Semilunar cartilage.
- Articular surfaces:
 anatomic replacement of, 187
 damage to, in wounds of hip joint, 237
 damage to, in wounds of knee joint, 217
 defect in, as factor in diagnosis of joint mice, 286
- Aspiration-instillation regimen, in wounds of knee joint, 219-221, 231
 at initial surgery, 227
 at reparative surgery, 227, 235
- Astragalus, fractures of, 183
- Atrophy of muscles, as factor in diagnosis, 283, 289
- AUTOFRANCE, Maj. OTTO E., 160n
- Axillary contents, risk of injury to, in use of hinged full-ring arm splint, 34
- Axillary nerve, damage to, in fractures of humerus, 122
- Backs, painful, 271-275
 diagnosis of, 272-274
 disposition of patients with, 274-275
 management of, 274-275
- Bacterial count in wound closure, in World War I, 58-60
- Bacterial flora in war wounds, 59
- Bagnoli, 20
- Balanced-suspension skeletal traction—
 in fractures of femur, 139, 142-143, 149-155, 156, 159
 in wounds of knee joint, 227
- Bandages:
 Carlisle, 32, 34
 figure-of-eight plaster, 51
 manuals on, 31-32
 muslin, 40
 roller, 32, 34-35, 41
 triangular, 32, 34-35
- Banjo traction:
 after amputation, 251, 253, 257
 in fractures of bones of foot, 182
- Basswood splints, use of, in emergency splinting, 32, 34
- Battalion aid stations, 33, 34
 first aid in, 66-67
- Battlefield, first aid on, 66-67
- Bed rest—
 after fractures of bones of foot, 183
 as treatment for noncombat orthopedic lesions, 274, 275, 279, 288, 293
- Bed space, 271-272
 as consideration in elective surgery, 7
 waste of, caring for patients with chronic orthopedic, noncombat lesions, 297
- Belgium, 212

- Belts, for painful backs, 275
- Biceps femoris muscle, 148
- BIP (bismuth subnitrate, iodoform, and paraffin), use of, in World War I, 53
- Bizerte, 4, 20
- Bladder, urinary, 237
- Blister formation in closed plaster method of fracture management, 55
- Blood, availability of, 63, 67
- Blood pressure in shock, 68, 70
- Blood replacement—
in management of fractures—
after initial surgery, 80
after reparative surgery, 82–83
before initial surgery, 68–70
before reparative surgery, 82–83
of bones of leg, 162–163
of femur, 80, 138
of upper extremity, 116–117
in management of wounds of knee joint, 219
in reparative-surgery program, 63, 64
- Blood supply of bone fragments, 292, 293
- Blood transfusions. *See* Blood replacement.
- Blood vessels, 246
injuries to, associated with wounds of hip joint, 237
ligation of, at initial surgery, 74
protection of, in fractures of upper extremity, 117
- Body warmth, conservation of, before initial surgery, 67
- Bone and nerve surgery in fractures of—
bones of leg, 161
humerus, 128–129, 132
upper extremity, 116
- Bone cortex:
coverage of, at reparative surgery, 93–103
excision of fragments of, at initial surgery, 79
exposure of, in fractures of bones of leg, 160, 161
fragmentation of, in fractures of tibia, 79
- Bone coverage, in fractures, 186
after internal fixation, 87
of bones of foot, 181
of bones of leg, 163
of humerus, 129
of upper extremity, 116, 117
- Bone fragments:
blood supply of, 292, 293
displaced, 182
distraction of, 201
- Bone fragments—Continued
excision of, in carpal scaphoid fractures, 293
management of, in fractures, 198, 207
at initial surgery, 78–79
at reparative surgery, 84, 86, 87
by delayed internal fixation, 134, 146, 187, 199, 201, 207
of bones of foot, 182
of bones of forearm, 41, 134
of bones of leg, 163, 165, 170
of femur, 142, 149, 154
of humerus, 128
of upper extremity, 117
policy on, 78–79
role of, as bone grafts, 79
- Bone grafting—
after fractures, 196, 199, 200, 201
as factor in reparative surgery, 134, 165, 166, 173, 207
after wounds of knee joint, 237
- Bone injuries:
data on, methods of accumulation of, 28
disposition of patients with, 295–298
initial surgery for, 64–81
management of:
administrative considerations, 3–28
objectives of, 7
personnel required for, in general hospitals, 26–27
responsibility for, 25
reparative surgery for, 81–114, 139–186
See also specific bones, techniques, injuries.
- Bone loss, 87, 107, 185, 187, 199, 201
after massive sequestration, 196, 199
as indication for application of hip spica, 156
as indication for external skeletal fixation, 207
avoidance of, 79
- In fractures of—
bones of forearm, 134–135, 202
bones of leg, 160, 161, 165, 170, 173, 201
femur, 144
humerus, 116, 126–127, 201
lower extremity, 245
upper extremity, 116
- Bone-nerve injuries, in fractures of bones of forearm, 134–135
- Bone shortening, 187
in fractures of—
bones of forearm, 135
bones of leg, 165, 201
humerus, 126–127, 128

- Bone shortening—Continued
 in wounds of knee joint, 231, 236
 indications for, 87
- Bone tumors, disposition of patients with, 274
- Boot plaster cast, 182, 183, 275
- Bou Hanifia, 19
- Boxing-glove type of plaster cast, 8
- Bracemakers, assignment and utilization of, 15-20, 27
- Braces, for painful backs, 275
- Braceshops, 275
 equipment for, 15, 20
- Brachial artery, risk of damage to, in splinting, 34
- BROTT, Capt. C. R., 245n
- Bruises, disposition of patients with, 295
- Burns associated with fractures, 209
- BUTTERWORTH, Maj. R. D., 168n
- BUXTON, St. J. D., 250
- CAHEN, Maj. IRVIN, 137, 146, 149, 152
- Calcification, in carpal scaphoid fractures, 293
- Calf, wounds of, 73
- Callus formation, after fractures, 81
 of metatarsal bones, 182
- Capillary attraction, drainage of wound exudate by, 78
- Capsule of hip joint, closure of, 241
- Capsule of knee joint. *See* Synovial membrane.
- Carlisle bandages, 32, 34
- Carpal scaphoid fractures, 271
 diagnosis of, 292
 disposition of patients after, 291, 293-294
 surveys on management of, 276, 290-294
 theater policy on management of, 290, 292
 union of, 293
- Carrel-Dakin method, 53, 211
- Cartilages, articular:
 damage to—
 in fractures of humerus, 123
 in wounds of hip joint, 241
 in wounds of knee joint, 219
 necrosis of, in wounds of knee joint, 221
 removal of, 223, 243, 279, 286
See also Semilunar cartilages.
- Casablanca, 3
- Caserta, 63
- Cassino, 4, 43, 62, 139, 186
- Casts, plaster:
 banjo, 182, 251, 253, 257
 boot, 182, 183, 275
 boxing-glove type, 8, 9
- Casts, plaster—Continued
 hanging, 41, 27-31, 33, 117, 123-126, 127
 hip spica, 8, 48-49, 139, 154
 long arm, 41
 long leg, 49, 51, 170, 173, 216
 shoulder spica, 41, 43, 123, 125, 127
 U type, 43
 Velpeau, 41, 43
See also Plaster immobilization, Plaster casts.
- Casualties. *See* Patients.
- Cellulitis, 72
- Certificate of Disability discharge, 237
- Chain of evacuation, 14
 role of, in reparative-surgery program, 62
- Chemotherapy, 57
 institution of, as first-aid measure, 67
See also Sulfonamide therapy.
- Chiefs of orthopedic sections:
 classifications of, 26
 duties of, 26, 27
 role of, in accumulation of data, 28
- Chiefs of surgical services, responsibility of, 6
- Chip fractures of knee, 283
- CHURCHILL, Col. EDWARD D. *See* Consultant in surgery.
- Circular amputations. *See* Open circular amputations.
- Circular letters:
 No. 13, Office of the Surgeon, NATOUSA, 15 May 43-47n
 No. 16, Office of the Surgeon, NATOUSA, 9 June 43-47n
 No. 36, Office of the Surgeon, NATOUSA, 1 July 44-10
 No. 46, Office of the Surgeon, NATOUSA, 29 Aug 44-7, 8, 9, 245, 247-249, 251-254
 No. 48, Office of the Surgeon, NATOUSA, 18 Nov 43-185, 203-204, 278-279, 287, 289, 290
 No. 91, Office of the Surgeon General, 26 Apr 43-247n
- Circular wounds, 74
- Circulatory status of extremities, determination of, after initial surgery, 80
- Civilian orthopedic practice, 273
 knee disabilities in, 284-285
 wounds of joints in, 212-213
- CLARY, Capt. BEVERLY B., 160n
- Clearing stations:
 first aid in, 66-67
 responsibility of, 14
- CLEVELAND, Col. MATHER, 1

- Closed plaster method of fracture management, 53-58
 clinical observations on, 57
 discontinuance of use of, 58
 in fractures of bones of leg, 63, 178
 modification of, 56
 objectives of, 53
 results of, 53, 55-56
- Clostridial myositis—
 after amputation, 249, 256
 as indication for amputation, 247, 249, 267, 269, 270
 in fractures of bones of leg, 178
 in fractures of femur, 139, 140
- Closure of amputation stump, 253, 254-257
- Closure of capsule of hip joint, 241
- Closure of knee joint, 216, 219
- Closure of synovial membrane in wounds of—
 knee joint, 216, 217, 219, 221, 223
 smaller joints, 243
- Closure of wounds. *See* Wound closure.
- Collecting stations, first aid in, 66-67
- COLLOM, Maj. SPENCER A., Jr., 211n, 137n
- Colostomy, 47
- Comminuted fractures, 87, 129, 134, 146, 159, 165-170, 173, 175, 178-179, 186, 201, 207, 208-209, 219, 223
- Comminution—
 as contraindication to internal fixation, 86, 87, 122-123, 128, 186
 as indication for external skeletal fixation, 207, 208-209
- Committee on Surgery, Division of Medical Sciences, National Research Council, 31
 Subcommittee on Orthopedic Surgery, 213
- Como, 3
- Condylar fractures, 198
 of femur, 87, 146
 of humerus, 87, 129
- Conference, Interallied Surgical, 1917, 211
- Congenital anomalies, disposition of patients with, 274
- Consultant(s):
 in neuropsychiatry, Fifth U. S. Army, 272-273
 in orthopedic surgery, 1, 4, 5, 63, 188, 189, 238, 242, 277
 activities of, 7, 12, 238, 277
 mission of, 4, 6-7
 to field armies, advantages of appointment of, 5, 13, 237
 to Fifth U. S. Army, 5
 399661°—57—24
- Consultant(s)—Continued
 in surgery, 1, 4, 58, 65
 function of, 6, 7
 to Fifth U. S. Army, 5, 7, 8, 10
 to Seventh U. S. Army, 4, 5, 12, 51
 role of, in training of medical officers, 65
- Consultant system, evolution of, 3-5
- Continental Advance Base Section, 10-12
- Contraindications to—
 delayed primary wound closure, 59, 91, 103, 163
 external skeletal fixation, 207
 internal fixation, 86, 186
 periosteal stripping, 86
 surgery for knee disabilities, 279, 283-284
 Trendelenburg position, in shock, 68
- Convalescent hospitals, 66, 279
- Copper sulfate hematocrit and serum protein determination, 82
- Counterincisions, utilization of, for—
 elimination of dead space, 77
 removal of foreign bodies, 73
 wound drainage, 74, 93, 103
- COX, Col. FRANCIS J., 137n, 148
- CRIDER, Capt. RUSSELL J., 137n, 152, 155
- CROUCH, Capt. FRANCIS R., 115n, 160n
- Dead space, 57, 59, 93, 163-164, 166
 as surgical limitation to wound closure, 59, 103
 drainage of, 186
 obliteration of, 77, 117, 142
- Deaths—
 after delayed internal fixation, 197
 in fractures of femur, 137, 139, 140, 158
 in reparative-surgery program, 107
 of amputees, in fixed hospitals, 260
- Debridement:
 at reparative surgery, 59
 in closed plaster method of fracture management, 54, 55
 in wounds of—
 hip joint, 242
 knee joint, 216, 217, 219, 223-227, 235
 smaller joints, 243-244
 objectives of, 71
See also Initial surgery
- Delayed internal fixation of fractures, 91, 146, 155, 185-202
 about joints, 185, 187
 advantages of, 197
 comminution, as contraindication to, 186
 disadvantages of, 187
 hazards of, 195-196, 198-199
 indications for, 190-191, 197

- Delayed internal fixation of fractures—Con.
- of bones of forearm, 185
 - of bones of leg, 185, 199
 - of femur, 197, 199
 - of long bones, 187
 - of upper extremity, 199
 - results of, 186, 188-202
 - techniques of, 187
 - theater policy on, 185
 - with segmental bone defects, 185, 187
 - with soft-tissue loss, 185
 - with unhealed wounds, 185, 186
 - See also* Screw fixation, Plating, and other specific techniques.
- Delayed primary suture of amputation stump, 256
- Delayed primary wound closure. *See* Wound closure, delayed primary.
- Delayed union in fractures, prevention of, 198
- Delta Base Section, 11, 12
- Deltoid muscle, 122
- Dependent drainage, 77, 142, 143, 148, 161, 163
- Devitalized tissue, 57
- drainage of products of, 91, 143, 148, 186
 - excision of, 188
 - as criterion for wound closure, 59
 - at initial surgery, 73
 - at reparative surgery, 84
 - in closed plaster method of fracture management, 57
 - in fractures, 63, 117, 142, 179-180, 181
 - in wounds of joints, 219, 241
 - effect of, on wound closure, 60, 149
 - effect of, on wound healing, 112
 - in fractures of femur, 142, 149
 - inadequate excision of, 56
 - sequestration of, 81, 107
- Diagnosis of noncombat orthopedic lesions, 272-274
- in civilian orthopedic practice, 272
 - of back, 274
 - of carpal scaphoid fractures, 290, 292
 - of knee, 283
 - of shoulder, 287
- Dirty wounds:
- after incomplete initial surgery, 117
 - extensive wound revision for, 103
 - necessity of drainage in, 149
 - reparative surgery in management of, 107
 - restriction or avoidance of periosteal stripping in, 87
- Disarticulation, 261
- theater policy on, 247-249
- Disease, as indication for amputations, 247, 262-264
- Dislocation(s) of—
- hip, in management of wounds of hip joint, 243
 - humerus, 122
 - patella, 278
 - shoulder, 271-274, 276, 287-290
- Disposition boards in hospitals, 276, 279, 287, 290, 294
- Disposition of patients. *See* Patients, disposition of.
- Drainage—
- in fractures, 83
 - after reparative surgery, 63, 91-103, 107, 186, 188
 - at initial surgery, 72, 74, 78
 - in closed plaster method of fracture management, 53-58
 - in external skeletal fixation, 204
 - of bones of foot, 182
 - of bones of leg, 161, 163-164, 175-178
 - of femur, 142, 148-149, 201
 - of upper extremity, 117
 - in wounds of—
 - hip joint, 237, 242
 - knee joint, 216, 217, 219, 231, 235
 - smaller joints, 244
- Drains:
- gauze used as, 103, 163
 - rubber tissue, 77, 103, 163
- DRAYER, Lt. Col. CALVIN S., 272-273
- Dressing of stump, after amputation, 251
- Dressing of wounds:
- after initial surgery, 74, 77-78
 - after reparative surgery, 103, 182
- Drilling, in carpal scaphoid fractures, 293
- DUNCAN, Lt. Col. GEORGE A., 115n, 137n, 160n, 211n, 295n
- Edema:
- in closed plaster method of fracture management, 55
 - control of, 103, 183
- Elastic cord, use of, after amputations, 8, 11, 253
- Elbow:
- arthrotomy of, 286-287
 - disarticulations at, 261
 - extension of, in hinged full-ring arm splint, 34

- Elbow—Continued
 fractures about, 122, 129-130
 delayed internal fixation of, 198
 emergency splinting for, 34
 transportation splinting for, 41, 43-44
 loose bodies in, 286-287
 protection of function of, in fractures of radius, 134
 resection of, 54
 wounds of, management of, 243-244
- Elective surgery:
 general discouragement of, 7
 in Army Air Forces, 277
 policy on, 278-279
- Elephant-tusk splint, 43
- Emergency splinting. *See* Splinting, emergency.
- England, 1
- Equipment:
 for braceshops, 15, 19-20
 for emergency splinting, 32, 34, 35, 37, 39
 for transportation splinting, 39, 41
 in communication zone, 14, 15
 in forward area, 14
- Evacuation:
 after amputation, traction during, 257
 after initial surgery of fractures, 80
 air, of amputees, 253, 257
 chain of, 14
 role of, in reparative-surgery program, 62
 effect of, on patient, as consideration in disposition, 295
- Evacuation hospitals. *See* Hospitals, evacuation.
- Evacuation policies:
 as factor in management of noncombat orthopedic lesions, 279
 general principles of disposition and, 295-298
 military considerations in, 64
- EWING, Maj. WILLIAM M., 137n
- Exercises, quadriceps, 150, 154, 279, 284, 286
- External skeletal fixation, 80, 156, 165, 170, 203-210
 in closed plaster method of fracture management, 53-58
- Extremities:
 circulatory status of, determination of, after initial surgery, 80
 nerve function in, determination of, at initial surgery, 72
See also Lower extremity, Upper extremity.
- Facilities in hospitals, 7, 271, 272, 295, 297
 in communications zone, 14-15, 19-20
 in forward areas, 14
See also Equipment, Personnel.
- Falling-drop technique. *See* Copper sulfate hematocrit and serum protein determination
- Fascia:
 coverage of, at reparative surgery, 93
 excision of, at initial surgery, 76
 incision of, at initial surgery, 73
 sloughing of, in fractures, 91
- Fascia flaps, use of in wounds of knee joint, 223
- Fascia lata, 76, 141-142
- Fascial plane:
 abscesses of, 72, 139
 drainage through, in fractures of femur, 143, 148
- Fat pad, excision of, in menisectomy, 285
- Feet:
 amputation of, 183, 262
 fractures of bones of, 180-183
 banjo traction in, 182
 disposition of patients with, 181, 296, 298
 emergency splinting for, 35
 initial surgery of, 181
 manipulation in, 182
 plaster immobilization of, 182
 reparative surgery of, 181-183
 transportation splinting for, 40-41, 51
 painful, 271-272, 274
 diagnosis of, 272-274
 disposition of patients with, 275
 management of, 275
See also Lower extremity.
- Femur:
 articulating surfaces of, damage to, 237
 fractures of, 137-159
 about joints, 221
 amputations in, 139, 158
 associated with wounds of thigh, 84
 balanced-suspension skeletal traction
 after, 139, 142-143, 149-155, 156, 159
 blood replacement in management of, 68, 70, 80, 82, 138
 complications in, 140
 deaths in, 137, 139, 158
 disposition of patients with, 298
 drainage in, 148-149, 159
 duration of traction after, policy on, 9
 emergency splinting for, 39

Femur—Continued

fractures of—Continued

- external skeletal fixation of, 156, 207, 209
- hip spica in, 139, 156
- infection in, 139, 140, 156, 159
- internal fixation of, 87, 143-148, 155-156, 199, 201
- Kirschner wire in, 142
- knee motion after, 140, 153, 154, 197
- management of, 138-140
- nerve injuries associated with, 141
- operating time for initial surgery of, 138
- periosteal stripping in, 146
- quadriceps muscle tone after, 140
- reduction of, 139-140, 143-148, 150-157, 159
- reparative surgery of, 141-159
 - operative position for, 142
 - results of, 157-159
- scar formation in, 139, 140
- sequestration in, 159
- shock associated with, 138
- sinus formation in, 140, 158-159
- statistics on, 137-141, 158
- transportation splinting for, 47-48
- two-wire skeletal traction after, 149
- union of, 154-155
- wound healing in, 139, 140, 155, 159
- wound management in, 148-149

FERGUSON, Maj. WILLIAM R., 115n, 137n, 155, 160n

Fibula, fractures of, 160-180

- blood replacement in management of, 68, 162-163
- bone loss in, 160, 165-170
- closed plaster technique in management of, 163
- disposition of patients with, 164-165, 173
- drainage in, 161, 163-164
- external skeletal fixation of, 208, 209
- infection in, 160
- internal fixation of, 170-173, 199, 201
- manipulation in, 160
- nerve and bone surgery in, 161
- nerve injuries in, 162
- nonunion of, 161
- plaster immobilization of, 164, 165, 166-170, 173
- reduction of, 57, 160, 161
- reparative surgery of, 162-180
- scar formation in, 160
- sequestration of, 160
- skeletal traction in, 160, 166-170

Fibula, fractures of—Continued

- statistics on, 162, 175-178
 - tissue loss in, 161
 - transportation splinting for, 40-41, 51
 - union of, 160-161
 - wound closure in, 161, 163-164
 - wound healing in, 160, 163
 - wound management in, 162-164, 175-179
- Field hospitals. *See* Hospitals, field.
- Field manuals. *See* Manuals.
- Fifth U. S. Army, 4, 49, 51, 138, 261
- consultants to, 4, 7, 272-273
- Figure-of-eight plaster bandage, 51
- Fingers:
 - determination of circulatory status of, 80
 - motion of, in fractures of upper extremity, 117
 - motion of, in splinting for carpal scaphoid fractures, 292
 - transportation splinting of, for radial-nerve paralysis, 43, 47
- First aid for fractures, 65-67
- First-aid splinting. *See* Splinting, emergency.
- Fixed Hospitals. *See* Hospitals, fixed.
- Flat feet, disposition of patients with, 275
- Flexion contracture of knee after amputation, prevention of, 253
- Flexion of—
 - elbow, in emergency splinting, 34
 - hip joint—
 - in hinged half-ring leg splint, 39
 - in hip spica, 49
 - knee—
 - in balanced-suspension skeletal traction, 150, 152
 - in emergency splinting, 39
 - in transportation splinting, 40, 41, 49, 52
 - in immobilization after wounds of knee joint, 227
 - thumb, in testing for ulnar-nerve injury, 72
 - toes, in fractures of bones of leg, 164
- FLYNN, Capt. JAMES H., 115n
- Forearm. *See* Radius, Ulna.
- Foreign bodies:
 - removal of, 63, 73, 84, 181, 223, 241
 - retained, 68
- Forward hospitals. *See* Hospitals, forward.
- Fracture frames, 14, 15
- Fracture table, portable, 14, 39
- Fractures:
 - about joints, 87, 185, 187, 221
 - amputation after, 139, 158, 249

Fractures—Continued

- avoidance of amputation in, 130
- blood replacement in management of, 68, 70, 82–83, 116–117, 162–163
- bone fragments in, 78–79, 128, 134, 163
- bone loss in, 87, 126–127, 160, 165, 185, 187
- characteristics of, 65–66, 138
- closed plaster technique in management of, 53–58, 163
- complications in, 140
- deaths in, 137, 139, 158
- delayed internal fixation of, 91, 146, 155, 185–202
- displacement of, in plaster casts, 56
- disposition of patients with, 164–165, 173, 181, 296, 298
- drainage in, 54, 91–103, 148–149, 161, 163–164
- emergency splinting for, 31–39
- external skeletal fixation of, 128–129, 156, 165, 203–210
- first aid for, 66–67
- functional restoration of extremity after, 87, 129
- granulation in, 130, 132
- infection in, 57, 63, 123, 132, 134, 139–140, 156, 158, 159, 160, 199, 236
- initial surgery of, 64–81
- internal fixation of, 86–91, 126–127, 129, 130, 134, 143–148, 165, 170–173
- malposition of, prevention of, 159
- management of. *See* Management of fractures.
- manipulation in, 160, 182
- motion after, 153, 154
- nerve injuries in, 50, 116, 127–129, 130, 132, 134–135, 141, 161, 162
- nonclosure of wounds in management of, 74, 77
- nonhealing of wounds in, 192–202
- nonunion of, 192–202
- of ankle, 35, 51
- of astragalus, 183
- of bones of—
 - forearm, 34, 41, 43, 47, 57, 68, 87, 115–117, 133–137, 185, 202, 207, 208, 209, 298
 - foot, 35, 51, 180–183, 298
 - leg, 35, 37–39, 40–41, 51, 57, 68, 79, 160–180, 199, 200, 201, 207, 209, 298
- of condyles of—
 - femur, 87, 146
 - humerus, 87, 129, 298

Fractures—Continued

- of femur, 9, 39, 47–49, 68, 80, 82, 84, 137–159, 197, 199, 201, 207, 209, 221, 298
- of humerus, 34, 41, 43, 68, 87, 115–133, 201
- of long bones, 187
- of lower extremity, 245
- of olecranon process, 87, 134
- of patella, 219, 221, 223
- of upper extremity, 115–117, 199
- operating time for initial surgery of, 138
- operative position for reparative surgery of, 142
- osteomyelitis in, 132
- plaster immobilization of, 103, 122–127, 133, 139, 156, 164, 165, 166–170, 173, 182
- protection of function in, 134
- range of motion following internal fixation of, 197
- reduction of, 55, 56, 57, 63, 80, 86–91, 107, 122, 123, 126, 129, 130, 133–134, 135, 139–140, 142–148, 149–157, 159, 160
- reparative surgery of, 81–114, 122–133, 162–173
 - golden period for, 81, 141
 - objectives of, 8, 137
 - results of, 130–133, 135–137, 141–159, 173–180
- scar formation in, 139, 140, 160
- sequestration in, 132, 159, 166
- shock in, 138
- sinus formation in, 132, 140, 158, 159
- skeletal traction in, 134, 139, 142–143, 149–155, 156, 160, 166–170, 182
- soft-tissue loss in, 87, 130, 161, 197, 199
- splinting after reparative surgery for, 4, 117, 150
- stabilization of, 64
- statistics on, 115, 137–138, 139–141, 161, 162, 175–180
- tendon injuries in, 116
- transportation splinting for, 39–52
- union of, 79, 83, 126, 130, 132, 154–155
 - after delayed internal fixation, 186, 192–202
- unreduced, internal fixation of, 186
- vascular damage in, 80
- without bone loss, 123–126
- wound closure in, 74, 91–103, 123, 129, 133, 161, 163–164
- wound healing in, 55, 57, 79, 116, 130, 132–133, 134, 135, 139, 155–166, 163
 - after delayed internal fixation, 92–202, 186

Fractures—Continued

- wound management in. *See* Management of wounds.
- Fractures, comminuted, 87, 129, 134, 146, 159, 165-170, 173, 175, 178-179, 186, 201, 207, 208-209, 219, 223
- Fractures, simple, 207, 271, 276, 290-294, 296, 298
- France, 4, 9, 31, 51, 161, 204, 280, 291
- FRANKAU, C. F. S., 215
- Full-ring hinged splint. *See* Hinged full-ring arm splint.
- Fusion of joints, 215, 237, 244
- Gangrene, as indication for amputation, 246, 268, 269
- Gas-bacillus infection, identification of, after initial surgery, 80
- Gastric lavage, before initial surgery, 68
- Gastrocnemius muscle, 52, 73
- General hospitals. *See* Hospitals, general.
- German prisoners of war, analysis of amputations on, 261-270
- Glenoid process, 122
- Gluteus maximus muscle, 148
- GODFREY, Maj. JOSEPH D., 137n, 142, 152
- Golden period for reparative surgery, 81, 141. *See also* Reparative surgery, timing of.
- GOTTSCHALK, Capt. ROBERT B., 115n, 160n
- Grafting. *See* Bone grafting.
- Grafts. *See* Skin grafts.
- Granulation, wound healing by, in fractures, 58, 59, 64, 91-103
 - in closed plaster method of management, 55, 57
 - of bones of foot, 181
 - of bones of leg, 160, 163, 175
 - of femur, 139, 159
 - of humerus, 130, 132
- Gross normal alinement of injured extremity, maintenance of, by splinting, 40
- Guillotine amputations. *See* Open circular amputations.
- Half-ring leg splint. *See* Hinged half-ring leg splint.
- Hallux valgus, disposition of patients with, 275
- Hammertoes, disposition of patients with, 275
- HAMPTON, Col. OSCAR P., JR. *See* Consultant in orthopedic surgery.
- Hamstring muscle, 148
- Hand:
 - emergency splinting of, 34
 - importance of function of, in management of fractures of upper extremity, 115
- Hand injuries:
 - disposition of patients with, 296, 298
 - management of, 8, 9, 74
- Hanging plaster cast, use of, in fractures of humerus, 117, 127
 - advantages of, after reparative surgery, 123-126
 - inadequacy of, for transportation splinting, 41
- HARRIS, Maj. HERBERT W., 148, 203n, 211n
- Heel bone, fractures of, 181, 183, 245
- Hematocrit, copper sulfate determination of, 82
- Hematocrit level, before reparative surgery—
 - in fractures, 82
 - of bones of leg, 162-163
 - of femur, 138
 - of upper extremity, 116-117
 - in wounds of knee joint, 219
 - See also* blood replacement.
- Hematomas, in fractures, 93
 - elimination of, as criterion for wound closure, 59
 - purulent decomposition of, 57
 - septic, drainage of, 72
- Hemoglobin level, 82
- Hemorrhage, 82
 - control of, at first aid, 66
 - control of, before initial surgery, 67
 - detection of, after initial surgery, 80
- Hemostats, use of—
 - in first aid, 66
 - in initial surgery, 73
- Hinged full-ring arm splint, use of—
 - in amputation, 257
 - in emergency splinting, 32, 34
 - in transportation splinting, 41
- Hinged half-ring leg splint, use of—
 - in amputation, 253, 257
 - in balanced-suspension skeletal traction, 150, 151, 152, 227
 - in emergency splinting, 32, 35-39, 67
 - in transportation splinting, 47, 51
- Hip joint:
 - capsule of, closure of, 241
 - emergency splinting of, 35, 37, 39
 - flexion of, 49
 - transportation splinting of, 47-49
 - wounds of, 237-243
 - ankylosis in, 237

- Hip joint—Continued
wounds of—Continued
infection in, 237, 238-241, 242
management of, 237, 242-243
suppurative arthritis in, 237, 242
wound healing in, 241
- Hip spica, use of—
after thigh amputation, 253
in fractures of femur, 139, 154, 156
in transportation splinting, 48-49
in wounds of hip joint, 242
in wounds of knee joint, 8, 227
- Holding periods in hospitals:
after elective arthrotomy, 279
for accomplishment of reparative surgery,
63, 65, 83
for fractures of femur, 9
for wounds of hip joint, 242
in forward areas, 295
theater policy on, as factor in disposition
of patients with noncombat orthopedic
lesions, 276
- HOPKINS, Maj. GEORGE S., 245n
- Hospital(s):
captured German military, 261
convalescent, 279
mission of, 66
evacuation:
8th—7
9th—236
16th—68, 138
38th—7
94th—7
See also Hospitals, forward.
- field:
33d—7
See also Hospitals, forward.
- fixed:
amputation at, 246, 260-261
disposition of patients, 295-298
management of—
amputation stump at, 246, 253-256
fractures at, 55-57, 138, 139-140, 187-
188, 203-210
noncombat lesions at, 272-294
wounds of joints, 216-221, 227, 231,
235-236, 242, 243, 244
mission of, 63
reparative surgery at, 81-114
segregation of bone and joint injuries
at, 25
See also Hospitals, general; Hospitals,
station.
- Hospital(s)—Continued
forward:
amputations at, 246
assignment of general surgeons to, 12, 13
assignment of orthopedic surgeons to,
5, 12-13
disposition of patients from, 295, 297
facilities at, 14
holding period at, 242, 295
initial surgery at, 14, 67-81
management of—
fractures at, 55, 138, 163
wounds of joints at, 231, 242-243
mission of, 63
screening of patients at, 272-273
transportation splinting at, 39-52
See also Hospitals, evacuation; Hos-
pitals, field.
- general:
disposition boards at, 276, 279, 287
disposition of patients from, 295-298
facilities at, 14-15, 19-20
numbered:
3d—11
6th—9, 101-108
12th—9, 148, 286-287
17th—148, 219, 235
21st—10, 19, 82, 115, 121-138, 141-
183, 186, 197, 219, 244
23d—81, 82, 138, 142, 152, 186, 219
24th—20, 140-183
26th—280, 282-283
33d—8, 9, 121-133, 140-183, 286-287
36th—10, 11, 12
43d—11
45th—115, 133-137, 161-181, 215,
219, 286-287, 297-298
46th—10, 12, 19, 292
64th—8, 140-183
70th—236
182d—291, 292
300th—121-138, 141-183, 186
outpatient dispensaries in, 27
personnel required in, 26-27
See also Hospitals, fixed.
- station:
disposition boards at, 276
numbered:
35th—11
70th—11
73d—9
78th—11
80th—11
180th—10

- Hospital(s)—Continued
 station—Continued
 outpatients clinics in, 27
 See also Hospitals, fixed.
 supporting the Army Air Forces, 276, 280, 282
 Zone of Interior, mission of, 64, 116
 Hospital administration, 25-27
 Hospital center for prisoners of war, 261
 Hospital disposition boards, 276, 279, 287, 290, 294
 Hospital facilities, 7, 271, 272, 295, 297
 Hospitalization period:
 after arthroto-my of knee joint, 277-278, 279, 281, 282
 after carpal scaphoid fractures, 291-292, 293
 after disabilities of knee, 280-281, 282
 after reparative surgery of fractures, 65
 of bones of foot, 183
 of femur, 157
 after shoulder dislocations, recurrent, 288
 Hospitalization policies, military considerations in, 64, 65
 Humerus:
 amputations of, 261
 dislocations of, 122
 fractures of, 115-133
 about elbow joint, 129-130
 about shoulder joint, 122, 126
 blood replacement in management of, 68
 disposition of patients with, 298
 emergency splinting for, 34
 granulation in, 130, 132
 infection in, 123, 129-130, 132
 internal fixation of, 87, 126-129, 201
 management of, 115
 nerve and bone surgery in, 128-129
 nerve injuries associated with, 116, 122, 127-129, 130, 132, 134
 osteomyelitis in, 132
 plaster immobilization of, 123-127
 reduction of, 122-130
 reparative surgery of, 122-133
 sequestration in, 132
 sinus formation in, 132
 soft-tissue damage in, 130
 tendon injuries associated with, 116
 transportation splinting for, 41-46
 union of, 132
 with bone loss, 116, 126-127, 201
 without bone loss, 123-126
 wound closure in, 123, 129
 wound healing in, 130, 132-133
 wound management in, 122-124
 Improvised sacral rests, 39
 Improvised splinting. *See* Splinting, emergency, improvised.
 Incidence. *See* Statistics.
 Incisions:
 enlargement of, at reparative surgery, 84
 for amputations, 251
 for initial surgery—
 of fractures, 72, 73, 74-76, 163
 of wounds of knee joint, 223
 for meniscectomy, 285
 relaxing, for wound closure, 163
 Indications for—
 amputation, 245, 246-247, 266-269, 270
 arthrotomy, 277
 changes of cast in closed plaster method of fracture management, 54
 external skeletal fixation, 207-210
 hip spica, in fractures of femur, 156
 internal fixation of fractures, 87, 128, 134, 173, 197
 elective, 191, 200, 201, 202
 obligate, 190-191, 200, 201, 202
 resection of knee joint, 231, 236
 Infection:
 after amputation, 256
 as indication for—
 amputation, 247, 266, 269, 270
 re-amputation, 270
 in fractures, 66, 80, 81, 84, 103, 107
 after external skeletal fixation, 204
 after internal fixation, 186, 188
 control of, 72, 199
 in closed plaster method of fracture management, 55-57
 in World War I, 53
 of bones of foot, 183
 of bones of leg, 160, 175, 178
 of femur, 87, 139, 140, 142, 146, 148, 149, 154, 156, 158, 159, 201
 of humerus, 123, 129, 132
 of radius, prevention of, 134
 of upper extremity, 116
 in wounds of—
 hip joint, 237, 238-241, 242-243
 knee joint, 49, 216, 217-221, 227, 231, 235-237
 smaller joints, 244
 prevention of, 57, 103, 183, 186
 by initial surgery, 71, 73
 by utilization of reparative-surgery program, 64
 See also Sepsis.

- Initial surgery, 14
 amputations at, 246
 in wounds of—
 hip joint, 237, 241, 242
 knee joint, 223-227, 235-236
 smaller joints, 243-244
 of fractures, 64-81
 appraisal of wound at, 71-72
 blood replacement in, 138
 evacuation following, 80
 first aid preceding, 66-67
 fracture management at, 80
 general principles and practices of, 72-74
 management of bone fragments at 78-79
 objectives of, 71
 of bones of foot, 181
 of femur, 138
 postoperative regimen after, 80
 preoperative preparation for, 67-71
 technical considerations in, 74-78
 timing of, 64-66, 72
 role of, in prevention of amputation, 268
See also Debridement, Staged management.
- Injuries. *See* Fractures, Wounds, and special wounds.
- Interallied Surgical Conference, 1917-211
- Internal fixation of fractures, 86-91, 107, 187, 188
 advantages of, 86, 87
 contraindications to, 86, 128
 disadvantages of, 87
 indications for, 87, 126
 of bones of forearm, 134
 of bones of leg, 165, 170-173, 178
 of femur, 142-148, 153, 155-156
 of humerus, 126-129
See also Delayed internal fixation, Plating, Screw fixation, and other specific techniques.
- Intestines, involvement of, in wounds of hip joint, 241
- Intra-abdominal wounds, associated with wounds of hip joint, 237
- Inverted-cone stumps in amputation, 251
- Irrigation in wounds of joints, 216, 223, 227, 243
- Italy, 3, 4, 8, 13, 19, 20, 26, 121, 133, 139, 140, 236, 243, 261
- JERGESEN, Maj. FLOYD H., 5
- Joint(s):
 fractures about, 57, 87, 185, 187
 loose bodies in. *See* Joint mice.
 wounds of, 211-244
 data on, methods of accumulation on, 28
 disposition of patients with, 295-298
 in civilian orthopedic practice, 212-213
 in Spanish Civil War, 213
 in World War I, 211-212
 initial surgery for, 64-81
 management of:
 administrative considerations in, 3-28
 evolution of, 3, 63, 214-231, 242-243
 objectives of, 7
 personnel required for, in general hospitals, 26-27
 resection in, 213
 responsibility for, 25
See also specific joints.
- Joint mice:
 disposition of patients with, 286
 survey on management of, 276, 286-287
 theater policy on management of, 278
- Joldersma technique of balanced-suspension skeletal traction, 151-152
- JOLLY, D. W., 213
- Kirschner wire, 142, 149, 182
- Knee:
 arthrotomy of, 277-278, 281, 286-287
 disabilities of, 271-272
 diagnosis of, 272-274, 283, 284
 disposition of patients with, 277-278, 279, 280-281, 282-284, 286-287
 management of, 276-286
 disarticulations at, 261
 flexion contracture of, after amputation of lower leg, 253
 position of, in—
 emergency splinting, 35, 37, 39
 skeletal traction, 150, 152
 splinting after reparative surgery, 164
 transportation splinting, 40, 41, 49-52, 227
 resection of, 210, 216, 221, 231, 235-237
 suppurative arthritis of, 215, 217-219, 227, 236
 wounds of, management of, 8, 214-237
- Knee motion after—
 fractures of femur, 140, 142, 150, 151, 154, 159, 197
 wounds of knee joint, 216, 221, 227
- LaPanne, 212

- Leg:**
 amputation of, 253, 254, 262
 wound closure after, 253
 emergency splinting of, 35, 37-39
 fractures of bones of, 160-180
 associated with bone loss, 245
 blood replacement in management of, 68
 disposition of patients with, 298
 external skeletal fixation of, 207
 inadequate reduction of, 185
 transportation splinting of, 51-52
See also Tibia, Fibula.
- Leghorn, 8**
- Ligaments of knee, injuries to, policy on management of, 278, 281**
- Ligation of blood vessels, at initial surgery, 74**
- LINCH, Maj. ALBERT O., 151**
- Litter, use of, as operating table, 71**
- Long arm plaster cast, 41**
- Long bones:**
 amputations through, 249
 fractures of, 87, 187
 disposition of patients with, 297, 298
 external skeletal fixation of, 207
 hematocrit values in, 82
 internal fixation of, survey on, 188-202
- Long leg plaster cast, 49, 51, 170, 173**
 in wounds of knee joint, 216
- Loose bodies in joints:**
 disposition of patients with, 286
 survey on management of, 276, 286-287
 theater policy on management of, 278
- Lower extremity:**
 amputations of, 261, 262, 269, 270
 emergency splinting of, 35, 37-39
 transportation splinting of, 47-52
See also Femur, Tibia, Fibula.
- Lymphangitis, 72**
- LYONS, Maj. CHAMP, 63, 83**
- Malalignment in fractures, persistent, 207**
- Malingers, 283, 289**
- Malposition in fractures, 80, 159**
- Malunion of fractures, 57, 198**
- Management of fractures, 53-114**
 at initial surgery, 80
 at reparative surgery, 86-103
 by delayed internal fixation, 185-202
 by external skeletal fixation, 203-210
 by internal fixation, 86-90
 closed plaster method in, 53-58
 concept of, 58, 114
 functions of fixed hospitals in, 63
 functions of forward hospitals in, 63
 in World War I, 53
- Management of fractures—Continued**
 of bones of foot, 182-183
 of femur, 141-159
 favorable factors in, 141-142
 results of, 139-140
 unfavorable factors in, 142
 of fibula, 160-180
 results of, 173-180
 unfavorable factors in, 160-161
 of humerus, 122-130
 results of, 130-133
 of radius, 133-134
 results of, 135-137
 of tibia, 160-180, 188-189
 results of, 173-180
 unfavorable factors in, 160-161
 of ulna, 133-134
 results of, 135-137
 of upper extremity:
 favorable factors in, 116
 objective of, 115
 principles of, 116-117
 problems of, 115-116
- Management of noncombat orthopedic lesions, 271-294**
 diagnosis in, 272-274, 283
 surveys on, 272-294
- Management of wounds:**
 associated with fractures—
 at initial surgery, 71-78
 at reparative surgery, 84
 of bones of foot, 181-182
 of bones of forearm, 133
 of bones of leg, 162-164, 175-179
 of femur, 148-149
 of humerus, 122-123
 of upper extremity, 117
 closed plaster method in, 53-58
 concepts of, 58, 113-114
 of joints, 211-244
 evolution of, 3, 63, 214-231, 242-243
 in civilian orthopedic practice, 212-213
 in Spanish Civil War, 213
 in World War I, 211-212
 of ankle, 243-244
 of elbow, 243-244
 of hip, 242-243
 results of, 237-241
 of knee, 215-231
 in fixed hospitals, 216-221, 227
 in World War I, 223
 results of, 231-236
 of shoulder, 243-244
 of wrist, 243-244

- Manipulation, in management of—
fractures, 81, 91, 185, 199, 271
in closed plaster method, 56, 57
of bones of foot, 182
of bones of leg, 160, 165
knee with injuries of semilunar cartilage,
279, 283-284
- Manpower:
as factor in disposition of patients, 295, 296
loss of, from noncombat orthopedic lesions,
271, 274
- Manual(s):
Bandaging and Splinting, FM 8-50,
1944-32
First Aid for Soldiers, FM 21-11, 1943-32
Guides to Therapy for Medical Officers,
TM-8-210, 1942-213
Military Medical Manual, 31
Orthopedic Subjects (Military Surgical
Manual), 1942-31, 213
Soldiers Handbook, FM 21-100, 1941-32
Splints and Appliances, 1917-31, 39
Splints, Appliances and Bandages, FM
8-50, 1940-31, 32
- March fractures, management of, 275
- MEAD, Maj. NEWTON C., 148, 151, 271n, 280
- Mechanic's waste, use of in hand injury, 8, 9
- Median nerve, 117, 127-128, 134
- Medical aidmen, 32, 33
- Mediterranean Base Section, 19, 277
- Medullary canal, cortical fragments in, 79
- Menisci, injuries of, 280, 281, 283
disposition of patients with, 280-282
management of, 221, 223, 276, 279
- Meniscectomy, 284-285
postoperative management after, 285-286
- Merano, 261
- Metacarpals:
fractures of, disposition of patients with,
298
position of, in transportation splinting, 47
- Metatarsals, fractures of, 181-182
disposition of patients with, 298
- Meyerding sacral rests, 39
- MODLIN, Capt. JOHN., 137, 146, 149, 151,
152, 153, 155
- MOLLIN, Capt. EDWIN L., 203, 211
- Morphine, administration of, as first-aid
measure, 66-67
- Muscle tension in fracture of femur, 207
- Muscles:
atrophy of, 283, 289
damage to, as consideration in amputa-
tion, 249
- Muscles—Continued
deficits of, 87, 187
excision of, 73, 76-77
methods for determining viability of, 77
See also specific muscles.
- Naples, 4, 20, 63, 132, 139, 153, 158, 217,
219, 238
- National Research Council, Division of
Medical Sciences, Committee on Surgery,
31
Subcommittee on Orthopedic Surgery, 213
- Navy technique of balanced-suspension
skeletal traction, 151-152
- Necrosis, 57
as factor in determining level of amputa-
tion, 249
avascular, 293
in fractures of bones of forearm, 133
in fractures of humerus, 123
of articular cartilage, in wounds of knee
joint, 221
of tissue, in fractures, 91, 93, 107
pressure, protection from, in emergency
splinting, 39
- Nerve and bone surgery in fractures of—
bones of leg, 161
humerus, 128-129, 132
upper extremity, 116
- Nerves:
injuries of, 72, 87, 116, 127-129, 130, 132,
134-135, 141, 187, 196
protection of, in splinting, 34, 117
See also specific nerves.
- Neuropsychiatric-orthopedic consultation, in
management of noncombat orthopedic
lesions, 272-273
- 90-90-90 technique of balanced-suspension
skeletal traction, 142, 152
- Nodules, avascular, 286
- Nonclosure of wounds—
after initial surgery, 74, 77
after reparative surgery, 91-103, 122, 123,
148, 163-164, 175, 231
- Noncombat orthopedic lesions, 162, 181, 215,
271-294
diagnosis of, 272-274, 283
disposition of patients with, 274-275, 277-
284, 286-290, 297, 298
hospitalization period after, 277-278, 280-
282
surveys on management of, 276-294
theater policy on management of, 278-279

- Nonhealing of wounds, in fractures—
 after internal fixation, 192-202
 of bones of leg, 79, 178
- Nonunion of fractures, 57, 107, 292, 293
 after internal fixation, 192-202
 of bones of leg, 161
 prevention of, 87, 198
- OBLETZ, Maj. BENJAMIN E., 137n, 142, 152
- Olecranon process, fractures of, 87, 134
- Open circular amputation, 247-270
 directives on, 245, 247-249, 251-254, 257
 level of, 227-250
 reparative surgery after, 253-257
 technique of, 251
 traction after, 253, 256, 257
 statistics on, 260-270
- Open reduction of fractures, 86, 91, 122, 155,
 185. *See also* Internal fixation.
- Operating room, in general hospitals, 14
- Operating table, litter used as, 71
- Oran, 4, 19
- ORR, H. WINNETT, 53
- Orthopedic sections, chief of:
 Classification of, 26
 duties of, 26, 27
 role of, in accumulation of data, 28
- Os calcis, 181, 183, 245.
- Osteoarthritis, as contraindication to arthro-
 tomy, 284
- Osteochondritis dissecans, 276, 277-278, 283,
 286-287
- Osteomyelitis, 185
 following external skeletal fixation, 204
 in fractures of humerus, 132
- Oxygen, administration of, before initial
 surgery, 68
- Pain:
 after fractures of bones of foot, 182
 in backs, 271-275
 in feet, 271-274, 275
 in old carpal scaphoid fractures, 293
 in wounds of knee joint, 231
 relief of, 32, 34, 66
- PARKER, Maj. JOSEPH M., 115n, 137n, 160
- Patella:
 fractures of, 219, 221, 223
 defects of, disposition of patients with, 286
 dislocations of, policy on management of,
 278
- Patients:
 chain of evacuation for, 14
 disposition of, 272-273, 295-298
 after arthrotomy of joints, 278, 281,
 282-284
- Patients—Continued
 disposition of—Continued
 as consideration in elective surgery, 7
 as factor in assignment of orthopedic
 personnel, 12
 categories of, 276, 296
 Army Air Forces, 276-277
 considerations in, 66, 272-274
 with carpal scaphoid fractures, 290,
 293-291
 with fractures, 296, 298
 of bones of foot, 181, 183
 of bones of forearm, 137, 298
 of bones of leg, 164-165, 173, 298
 with joint mice, 286-287
 with knee disabilities, 278-279, 280-283,
 284
 with painful backs, 274-275
 with painful feet, 275
 with shoulder dislocations, recurrent,
 288-290
- Penicillin, use of—
 in amputation, 253, 268
 in wounds of hip joint, 243
 in wounds of knee joint, 8, 217-221, 223,
 227, 231, 235
 role of, in reparative-surgery program, 63
 theater policy on, 10
See also Antibiotic therapy.
- Periosteal stripping, in internal fixation of
 fractures, 86, 87, 91, 187, 195, 198
 of bones of leg, 170, 188, 199
 of femur, 146, 199
 of humerus, 126, 127, 129
- Peroneal nerve, damage to, 141, 162
- Personnel:
 assignment and utilization of, 5, 12-13, 15
 problems of, in management of bone and
 joint injuries, 4, 5, 6, 65
 use of—
 for initial surgery, 73
 for transportation splinting, 39, 40, 41
 in general hospitals, 26-27
See also Surgeons, orthopedic.
- Petrolatum-impregnated gauze, 9, 55, 56, 78,
 182
- Physical therapy, as treatment for noncom-
 bat orthopedic lesions, 273, 274, 275, 288,
 293
- Physiologic salt solution, in testing for nerve
 damage in fractures, 128
- Pierson attachment to hinged half-ring leg
 splint, 150-152, 227

- Plasma transfusion:
 as first-aid measure, 67
 before initial surgery, 68, 70
- Plaster casts, 253, 293
 bivalving of, 49
 policy on, 40
 changing of, 55
 indications for, 54-55
 timing of, 54-56
 molding of, around arch of foot, 51, 164
 records of wound data on, 40
 splitting of, 49
 policy on, 40
 windows in, 43, 103, 227
- Plaster immobilization:
 after open circular amputation, 253
 after reparative surgery, 117
 in carpal scaphoid fractures, 292-293
 in closed plaster method of fracture management, 53-58
 in fractures, 185, 271, 275
 of bones of foot, 182-183
 of bones of forearm, 133
 of bones of leg, 164-170, 173, 178
 of femur, 139, 156
 of humerus, 123, 126
 use of, with external skeletal fixation, 207-208, 210
 in transportation splinting, 39-52, 242
 in wounds of hip joint, 242
 in wounds of knee joint, 216-217, 221, 227
 in wounds of smaller joints, 244
- Plaster room, equipment for, in general hospital, 15
- Plaster spica, 210. *See also* Hip spica, Shoulder spica.
- Plaster Velpeau, use of, in transportation splinting, 41, 43
- Plating of fractures, 87, 187, 198, 199
 advantages of, 86
 of bones of forearm, 134, 135, 202
 of bones of leg, 170-173, 188, 197, 199, 202
 of femur, 146, 199, 201
 of humerus, 126-128, 201
 results of, 192-196
- POOL, EUGENE H., 211-212, 223
- Popliteal artery, protection of, in fractures of femur, 39
- Popliteal space, protection of, in splinting, 49
- Position, Trendelenburg, in shock, 68
- Postoperative management—
 after initial surgery of fractures, 80
 after meniscectomy, 285-286
- Postoperative management—Continued
 after reparative surgery of fractures, 103
 of bones of foot, 183
 of femur, 129-157
 of upper extremity, 117
 for wounds of knee joints, 231
- Preoperative preparation—
 for initial wound surgery, 67-71
 for reparative surgery, 82-83, 116-117, 187
- Pressure dressings, 9, 66, 285
- Pressure sores, in closed plaster method of fracture management, 55
- Primary suture, delayed. *See* Wound closure, delayed primary.
- Prisoners of war, analysis of amputations on, 261-270
- Psychological considerations in—
 amputation, 245
 disposition of patients, 297
 management of noncombat orthopedic lesions, 272-273, 279, 285, 287, 290, 294
- Quadriceps exercises:
 after fractures of femur, 150, 153, 154
 after knee disabilities, 279, 284, 286
- Radial deviation of wrist, in splinting for carpal scaphoid fractures, 292
- Radial-nerve injuries, associated with fractures:
 of bones of forearm, 134
 of humerus, 130
 splinting for, 117
 statistics on, 127-128
 testing for, at initial surgery, 72
- Radial-nerve paralysis, transportation splinting for, 43, 47
- Radius:
 fractures of, 87, 115-117, 133-137
 blood replacement in management of, 68
 disposition of patients with, 137, 298
 emergency splinting for, 34
 external skeletal fixation of, 207-209
 infection in, 134
 internal fixation of, 134, 202
 management of bone fragments in, 134
 nerve injuries in, 116, 134-137
 plaster immobilization of, 133
 protection of function in, 134
 reconstructive surgery of, 134, 135
 reduction of, 57, 133-135
 reparative surgery of, 133-137
 skeletal traction in, 134
 tendon injuries in, 116
 transportation splinting for, 41, 43, 47

Radius—Continued

- fractures of—Continued
 - wound healing in, 134, 135
 - wound management in, 117, 133
- involvement of, in fractures of humerus, 129
- RAWLES, Maj. BENJAMIN W., 160n, 211n, 245n
- Reconstructive surgery of fractures, 64, 134, 137, 175
 - considerations of, at reparative surgery, 165, 166
- Rectum, wounds of, associated with wounds of hip joint, 237
- Rectus femoris muscle, 73
- Red Cross, 31
- Redebridement, in wounds of hip joint, 243
- Reduction of fractures, 57, 63, 64, 80, 107, 271
 - by delayed fixation, 185-202
 - by external skeletal fixation, 203-210
 - by internal fixation, 86-90
 - by manipulation, 81, 91, 199
 - by skeletal traction, 91, 139, 142-143, 149-156, 159
- in closed plaster method of fracture management, 55-56
- of bones of foot, 182-183
- of bones of forearm, 133-134, 135
- of bones of leg, 160, 161, 165-173, 175, 179
- of femur, 139-140, 142-148, 149-157
 - of humerus, 122, 123, 126, 129, 130
- Rehabilitation of patients with noncombat orthopedic lesions, 273, 277, 284, 287, 290
- Reparative surgery:
 - after open circular amputation, 253-257
 - appraisal of wound at, 84
 - concept of, 81
 - delayed internal fixation at, 185-202
 - drainage at, 91-103
 - golden period for, 81, 141
 - holding period after 9, 63, 65, 83
 - internal fixation at, 86-91, 107, 187, 188
 - nerve and bone surgery as part of, 128-129
 - nerve repair in, 116
 - objectives of, 137, 186
 - of fractures, 59, 81-114
 - of bones of foot, 182, 183
 - of bones of forearm, 133-135
 - of bones of leg, 162-173
 - of femur, 141-159
 - of humerus, 122-130
 - of soft-tissue wounds, 58-60, 61
 - of wounds of knee joint, 227, 231-237

Reparative surgery—Continued

- postoperative management after, 103, 117
- preoperative preparation for, 82-83, 116-117, 187
- revision of wound at, 84
- splinting after, 117
- technical considerations in, 83-103
- timing of, 65, 81, 116-117, 141, 162, 163, 227, 236, 241
- wound closure in, 91-103
- See also* Staged management.
- Reparative-surgery program:
 - application of, to fractures, 61-64
 - application of, to soft-tissue wounds, 58
 - application of, to wounds of joints, 63, 223
 - development of, 58-60
 - holding period required for, 9, 63, 65, 83
 - objectives of, 64
 - survey of, by consultant in orthopedic surgery 7-12
- Resection of joints, 213, 243, 244
 - of ankle, external skeletal fixation after, 210
 - of hip, 243
 - of knee, 216, 221, 231, 235-237
 - external skeletal fixation after, 210
 - indications for, 231, 237
- Resuscitation:
 - in preparation for initial surgery, 68-71
 - emergency splitting as part of, 32
 - in fractures of femur, 138
- Roentgenologic examination, 68, 72, 73, 82, 86, 122, 153, 274, 279, 283-284, 287, 289, 291-292, 293
- Roller bandage, 32, 34, 35, 41
- Rome, 8, 158
- ROVANE, Capt. JOHN W., 115n
- Rubber-tissue drains, 77, 103
- Russell traction, 152-153
- Sacral rests, 39
- Salerno, 4
- Scar formation—
 - after amputation, 253
 - in closed plaster method of fracture management, 57
 - in fractures, 64, 188
 - of bones of leg, 160
 - of femur, 139, 140, 159
- Sciatic-nerve injuries, statistics on, 141
- Screw fixation of fractures, 87, 187, 198
 - advantages of, 86
 - of bones of forearm, 134
 - of bones of leg, 170-173, 178, 199
 - of femur, 146, 197, 199

- Screw fixation of fractures—Continued
of humerus, 122, 127, 129
results of, 192-196
- 2d Auxiliary Surgical Group, 249
- II Corps, 4
- Secondary surgery, in closed plaster method
of fracture management, 56
- Secondary suture of amputation stump, 253
- Sedatives, use of, as first-aid measure, 67
- Semilunar cartilage, injuries of:
disposition of patients with, 277-278, 282-283
management of, 276, 278-279, 282
See also Articular cartilage.
- Sepsis:
after inadequate debridement, 73
consideration of, in delayed primary wound closure, 59
in fractures of femur, 153, 159
in wounds of knee joint, 216, 221
See also Infection.
- Sequestration in fractures, 91, 93, 107
after delayed internal fixation, 195-196, 198-201
after periosteal stripping, 86
of femur, 159
of fibula, 160
of humerus, 132
of tibia, 160, 175, 188
- Serum protein, copper sulfate determination of, 82
- Seventh U. S. Army, 4-5, 12, 51
- Shock:
in fractures of femur, 138
prevention of, by emergency splinting, 32
recurrence of, 71
resuscitation in, 68-71
- SHORBE, Maj. HOWARD B., 211n
- Shortening of bone—
in fractures, 187
indications for, 87
of bones of forearm, 135
of bones of leg, 165
of femur, 135
of humerus, 126-127, 128-129
in wounds of knee joint, 231, 236
- Shoulder:
disarticulations at, 261
dislocations of, 271-272
diagnosis of, 272-274, 287, 289-290
disposition of patients with, 288-290
management of, 287-290
immobilization of, in fractures of humerus, 122-123
- Shoulder joint:
emergency splinting of, 34
involvement of, with fractures of humerus, 122-126
transportation splinting of, 41-46
wounds of, management of, 243-244
- Shoulder spica, use of—
in fractures of humerus, 123-127
in transportation splinting, 41-46
- Sicily, 4, 13, 26, 47
- Simple fractures, 207, 271, 276, 290-294, 296, 298
- Sinus formation in fractures, 93, 107
of bones of leg, 175, 179
of femur, 140, 158, 159
of humerus, 132
- Sixth Army Group, 12
- Skeletal traction, use of:
in closed plaster method of fracture management, 56, 57
in fractures, 9, 91, 185, 199
of bones of forearm, 134
of bones of leg, 166-170, 178
of humerus, 123
in wounds of hip joint, 242
See also specific types.
- Skin:
devitalized, excision of, at initial surgery, 73, 76
excoriations of, in closed plaster method of fracture management, 55
preparation of, at initial surgery, 73
- Skin defects:
avoidance of, 73
in fractures of bones of leg, 164
management of, at reparative surgery, 107
- Skin deficits, management of, at reparative surgery, 59
- Skin flaps, use of, 59, 93
in fractures of—
bones of forearm, 133
bones of leg, 163, 164
humerus, 129
in wounds of hand, 74
in wounds of knee joint, 223
- Skin grafts, 84
after amputation, 253, 255
split-thickness, 59, 133, 164
- Skin traction—
after amputation, 251-253, 255, 256, 257
by use of elastic cord, recommendation on, 8, 11
in management of knee disabilities, 279
in wounds of hip joint, 242

- Skintight plaster casts, 40
- Sling(s), 32, 33, 34, 35, 47
- SNYDER, Col. HOWARD E. *See* Consultant in surgery, Fifth U. S. Army.
- Soft tissue:
- damage to, in fractures of—
 - bones of foot, 181
 - bones of leg, 165
 - humerus, 123, 130
 - loss of, in fractures, 87, 103, 185, 197, 199
 - loss of, in wounds of knee joint, 223
 - role of, in determination of level of amputation, 247-249
 - wounds of, management of, 103
 - closure in, 58-60
 - recommendations on, by consultant in orthopedic surgery, 8
- Soleus muscle, 73
- Spanish Civil War, 39, 53, 125, 164, 213
- Spica, plaster, 210. *See also* Hip spica, Shoulder spica.
- Splint(s):
- basswood, 32, 34
 - elephant tusk, 43
 - hinged full-ring arm, 32, 34, 41, 257
 - hinged half-ring leg, 15, 32, 35, 37, 39, 47, 51, 67, 253, 257
 - with Pierson attachment, 150, 151, 152, 227
 - improvised, 32, 33
 - plaster of paris, 253
 - removal of, after amputation, 253
 - requirement for, in forward areas, 14
 - Tobruk, 8, 47, 49-51, 221, 227
 - wire ladder, 32, 34, 251
- Splinting:
- after reparative surgery of fractures:
 - of bones of foot, 183
 - of bones of leg, 164
 - of femur, 154
 - of upper extremity, 114
 - classification of, 29
 - in World War I, 31
 - manuals on, 31-32
 - objectives of, 29
- Splinting, emergency, 31-39
- equipment for, 32, 33
 - inspection of, before initial surgery, 67
 - objectives of, 32
 - regional, 34-39
 - timing of, 33
 - training in, 31-32
- Splinting, transportation, 39-52
- equipment for, 39, 41
 - objectives of, 40
 - personnel required for, 40, 41
 - regional, 41-52
 - use of plaster in, 39-52
- Split-thickness skin grafts, 59, 133, 164
- Spondylolisthesis, disposition of patients with, 274
- Sprains:
- disposition of patients with, 295, 298
 - in diagnosis of carpal scaphoid fractures, 292
- Staged management, 63
- concept of, 84
 - evolution of program of, 3, 53-64
 - See also* Initial surgery, Reparative surgery.
- Statistics:
- amputations, 254-257, 259, 260-270
 - balanced-suspension skeletal traction, 152-153, 155
 - blood replacement at initial surgery, 68
 - carpal scaphoid fractures, 291-294
 - delayed primary wound closure, 60
 - fractures of—
 - bones of foot, 180-181
 - bones of leg, 162, 173, 175-178
 - femur, 139-141, 158, 159
 - humerus, 122, 130
 - upper extremity, 115
 - external skeletal fixation, 204-206
 - hematocrit levels before reparative surgery, 82
 - internal fixation, 146, 165, 192
 - joint mice, 286-287
 - knee disabilities, 276-284
 - nerve injuries, 127-128, 134, 141, 162, 196
 - nonbattle injuries, 162
 - refractures, 197
 - shoulder dislocations, 287-290
 - wounding agents, 141, 162
 - wounds of hip joint, 241
 - wounds of knee joint, 215, 231-236
- Steinmann pin, 202
- Stockinet, use of, after amputation, 251, 253, 257
- Strains of back, disposition of patients with, 275
- Streptococcus infection, 57
- Stump, amputation, 253-260
- Subcommittee on Orthopedic Surgery, Committee on Surgery, Division of Medical Sciences, National Research Council, 213

- Sulfonamide therapy:
in closed plaster method of fracture management, 57
in wounds of knee joint, 216, 285
See also Chemotherapy.
- Suppurative arthritis—
of hip joint, 237, 242, 243
of knee joint, 214, 215, 217-219, 227-231, 236
of smaller joints, 244
- Surgeon(s):
general, 12, 13, 25, 26
of Delta Base Section, 11
of Fifth U. S. Army, 261
of NATOUSA (MTOUSA), 189, 204, 238, 280
orthopedic, 4, 5, 6-7, 12-13, 25, 26, 28, 40, 79, 173, 204, 245, 253-254, 257, 268, 286, 296
See also Personnel.
- Surgeon General, The, 253-254
- Surgical Consultants Division, Office of the Surgeon General, 189
- Sutures:
for initial surgery, 74
for reparative surgery, 9, 93, 117
- Synovial membrane, closure of—
in wounds of knee joint, 216, 217, 219, 221, 223
in wounds of smaller joints, 243.
- Synovitis, as factor in disposition of patients with knee disabilities, 282
- T-fractions of humerus, 129
- Tarsus, fractures of, 181-183
- Technicians, orthopedic, 20, 27
- Tendon(s):
coverage of, at reparative surgery, 93
coverage of, in fractures of bones of foot, 281
injuries of, in fractures of upper extremity, 116
sloughing of, in fractures, 91
- Tendonitis, in shoulder dislocations, 290
- Tetanus toxoid, 67
- Thigh:
amputation in, 245, 253, 254
emergency splinting of, 35, 37, 39
transportation splinting of, 47-49
wounds of, 73, 84
- Thomas splint, 51. *See also* Hinged half-ring leg splint.
- Thoracentesis, 43
- Thrombophlebitis in fractures of femur, 140
396961°—57—25
- Thrombosis, as indication for amputation, 247
- Through-and-through wounds, 77
- Thumb, position of:
in splinting, 43, 47, 292
in testing for nerve injuries, 72
- Tibia, fractures of, 160-180
blood replacement in management of, 68, 162-163
bone fragments in, 163
bone loss in, 160, 165-170
bone shortening in, 165
closed plaster technique in management of, 163
disposition of patients with, 173
drainage in, 161, 163-164
external skeletal fixation of, 165, 208, 209
exposure of bone cortex in, 160, 161
infection in, 160
internal fixation of, 91, 165, 170-173, 188-189, 199, 201
loss of tissue in, 161
manipulation in, 160
nerve and bone surgery in, 161
nerve injuries in, 162
nonunion of, 161
plaster immobilization of, 164-170, 173
reduction of, 57, 160, 161
reparative surgery of, 162-180
scar formation in, 160
sequestration of, 160
skeletal traction in, 160, 166-170
statistics on, 161-162, 175-178
transportation splinting for, 40, 41, 51
union of, 160-161
wound closure in, 161, 163-164
wound healing in, 79, 160, 163
wound management in, 162-164, 175-179
- Tibial nerve, 141, 162
- Timelag, from—
initial surgery to reparative surgery, 65, 81, 116
institution of first-aid measures to initial surgery, 65
wounding to—
initial surgery, 72, 217, 241
institution of first-aid measures, 65
reparative surgery, 81, 117, 141, 162, 163, 227, 236, 241
- Tobruk splint:
precaution in use of, 51
use of, in transportation splinting, 47, 49, 51
use of, in wounds of knee joint, 8, 221, 227

Toes:

- avoidance of hyperextension of, 51
- circulatory status of, determination of, at initial surgery, 80
- flexion of, in fractures of bones of leg, 164
- fractures of bones of, 181-182

Tourniquet, use of—

- after meniscectomy, 285
- at initial surgery, 67, 223
- during first aid, 66

Toxemia, associated with wounds of—

- hip joint, 237
- knee joint, 216

Traction:

- in transportation splinting, 39
- with Tobruk splint, 51
- See also* specific types.

Traction hitch, 34, 67

Traction ward, in general hospital, 14

Training—

- in emergency splinting, 31, 32
- in military management of bone and joint injuries, 5, 6, 7

Transfixion pins, use of, in closed plaster method of fracture management, 55

Transfusion. *See* Blood replacement.

Transportability of patients:

- after initial surgery, 81
- as factor in disposition, 295
- as factor in early reparative surgery, 65
- military considerations in, 64

Transportation splinting. *See* Splinting, transportation.

Trauma:

- as indication for amputation, 246, 249, 264-266, 269-270
- operative:
 - at initial surgery, 74
 - at wound closure, 163
 - from internal fixation, 86, 87, 143-146, 187
 - in meniscectomy, 285

Traumatic arthritis, in carpal scaphoid fractures, 293

Trenchfoot, as indication for amputation, 247, 262, 269

Trendelenburg position, in shock, 68

Triangular bandages, 32, 34

TRUETA, J., 53, 54, 213

Tuberculosis, as indication for amputation, 247

Tumors:

- bone, disposition of patients with, 274
- malignant, as indication for amputation, 247

Two-pin plaster technique, in management of fractures, 165, 170

Two-wire method of balanced-suspension skeletal traction, 149-151

U-type plaster cast, 43

Ulna:

- fractures of, 115-117, 133-137
 - blood replacement in management of, 68
 - bone fragments in, 134
 - disposition of patients with, 137, 298
 - emergency splinting for, 34
 - external skeletal fixation of, 207, 208
 - internal fixation in, 133-135, 202
 - management of, 15, 17, 133-134
 - nerve injuries in, 116, 134-137
 - plaster immobilization in, 133
 - reconstructive surgery of, 135, 137
 - reduction of, 57, 133-137, 185
 - reparative surgery of, 133-137
 - skeletal traction in, 134
 - statistics on, 115
 - tendon injuries in, 116
 - transportation splinting for, 41, 43, 47
 - wound management in, 117, 133
 - wound healing in, 133, 185
 - involvement of, in fractures of humerus, 129

Ulnar-nerve injuries

- in fractures of bones of forearm, 134
- statistics on, 127-128
- testing for, 72

Ulnar-nerve palsy, 117

- in fractures of humerus, 130

Union of fractures, 87, 292-293

- after internal fixation, 186, 192-202
- concept of, 79
- in closed plaster method of management, 55
- of bones of leg, 160-161
- of femur, 154-155
- of humerus, 132

Upper extremity:

- amputation of, wound closure after, 253, 254
- emergency splinting of, 34
- fractures of bones of, 115-137
 - blood replacement in management of, 116-117
 - external skeletal fixation of, 207

- Upper extremity—Continued
 fractures of bones of—Continued
 internal fixation of, 199
 management of, 115-117
 nerve injuries in, 116
 splinting after reparative surgery of, 117
 tendon injuries in, 116
 wound healing in, 116
 wound management in, 117
 See also Humerus, Radius, Ulna.
 transportation splinting of, 41, 43, 47
- Urinary bladder, wounds of, associated with
 wounds of hip joint, 237
- Vascular impairment, determination of, after
 initial surgery, 80
- Vascular insufficiency, as indication for am-
 putation, 246, 249, 266-269, 270
- Vascular status, appraisal of, at initial
 surgery, 72
- Vaseline gauze. *See* Petrolatum-impreg-
 nated gauze.
- Vastus lateralis muscle, 148
- Velpeau plaster cast, use of, in transporta-
 tion splinting, 41, 43
- War of the Rebellion, 212
- Ward officers, 26-27
- Wards, orthopedic:
 management of, in general hospital, 14
 traction, desirability of, in general hospital,
 14
- Webbing strap, 37
- Weight bearing—
 after disabilities of knee, 279
 after march fractures, 275
 after meniscectomy, 286
- Willems method, 212, 216, 244
- Window edema, prevention of, 103
- Wire ladder splints, use of—
 after amputation, 251
 in emergency splinting, 32, 34, 35
- Wire-suture fixation of fractures, 87, 187,
 198, 199
 of bones of forearm, 134, 202
 of bones of leg, 170-173, 178, 199
 of femur, 146, 156, 199, 201
 of humerus, 122, 126, 127, 129, 201
 results of, 192-196
- World War I:
 management of bone and joint injuries in,
 53, 211-212, 223
 delayed primary wound closure in, 58
 responsibility for, 25
 splinting in, 31, 39
 statistics on fractures of femur in, 137-138
- Wound(s):
 access to, 182, 209, 210
 appraisal of:
 at initial surgery, 71-72
 at reparative surgery, 59, 84
 before initial surgery, 67-68
 circular, 74
 closure of. *See* Wound closure.
 dressing of, after initial surgery, 77-78
 nonclosure of. *See* Nonclosure of wounds.
 of calf, 73
 of hands, 8, 9, 74, 296, 298
 of joints, 211-244
 of rectum, 237
 of thigh, 73, 84, 151, 152
 of urinary bladder, 237
 revision of, at reparative surgery, 84, 103,
 107
 saucerization of, at initial surgery, 77
 through-and-through, 77
 unhealed, delayed internal fixation of frac-
 tures with, 185, 186
 See also specific regions and wounds.
- Wound closure:
 delayed primary, 9, 58-60, 63, 91-103
 by approximation of soft parts, 117
 by skin flaps, 59, 74, 129, 133
 by skin graft, 175
 by split-thickness skin grafts, 59, 133
 concept of, 58-59
 criteria for, 59
 effect of excisional surgery on, 84
 effect of holding period on, 83
 in fractures, 117, 123, 133, 149, 161,
 163-164, 175, 181, 186, 188
 in World War I, 58
 in wounds of hip joint, 242
 in wounds of knee joint, 221, 227, 231,
 235
 in wounds of smaller joints, 244
 objectives of, 93, 148
 partial, 163, 175
 results of, 103-114
 statistics on, 60
 primary, 58
 timing of, 65, 81
- Wound healing:
 after delayed primary wound closure, 59,
 60
 after external skeletal fixation, 205-210
 after internal fixation, 91, 186, 192-202
 by granulation, 55, 57, 59, 64, 91, 103, 139,
 159, 163, 175, 181
 concept of, 79

- Wound healing—Continued
effect of excisional surgery on, 84
effect of holding period on, 83
in carpal scaphoid fractures, 293
in closed plaster method of fracture management, 57
in fractures, 79, 91, 116, 126, 130, 132-133, 134, 140, 142, 155-156, 159, 160, 166, 171, 173, 175, 178, 179-180, 186
promotion of, 83, 183
in reparative-surgery program, 64, 103-114
in wounds of hip joint, 241
in wounds of knee joint, 216, 221, 231
in wounds of soft tissues, 58, 59-60
of amputation stump, 255-257
- Wounding agents:
determination of sites of entry and exit of, 71-72
in amputations, 261-266, 270
in fractures, 65-66, 73, 141, 162, 181
in wounds of knee joint, 215
- Wrist:
disarticulations at, 261
position of:
in splinting for carpal scaphoid fractures, 292
in transportation splinting, 41, 47
sprains of, as factor in diagnosis of carpal scaphoid fractures, 292
wounds of, management of, 243-244
X-ray. *See* Roentgenologic examination.
Z-shaped incision, use of, at initial surgery, 76, 163
Zone of Interior, 4, 9, 20, 29, 63, 126, 127, 129, 130, 132, 156, 158, 159, 165, 166, 170, 173, 181, 183, 221, 236, 242, 254, 257, 259, 271, 272, 274, 275, 276, 278, 279, 280, 281, 282, 283, 286, 290, 293, 295, 296, 297, 298
amputation centers in, 245, 253
followup study on delayed internal fixation in, 185-202
hospitals in, function of, 64, 115, 175

NATIONAL LIBRARY OF MEDICINE



NLM 00059936 5