

# DOWNWARD DISPLACEMENT OF THE TRANSVERSE COLON.

## THREE CASES, WITH AUTOPSIES.

CHARLES HERMON THOMAS, M.D.,

*Surgeon to Philadelphia Hospital.*



A deformity of the transverse colon, consisting in the elongation of that portion of the large intestine and its displacement downward in the form of a loop or festoon, has been observed by me in three instances in private practice. Autopsies were had in them all. In the first the most dependent portion of the gut was found midway between the umbilicus and the pubic symphysis; in the second it was deeply impacted in the cavity of the pelvis; and in the third it reached the level of the umbilicus.

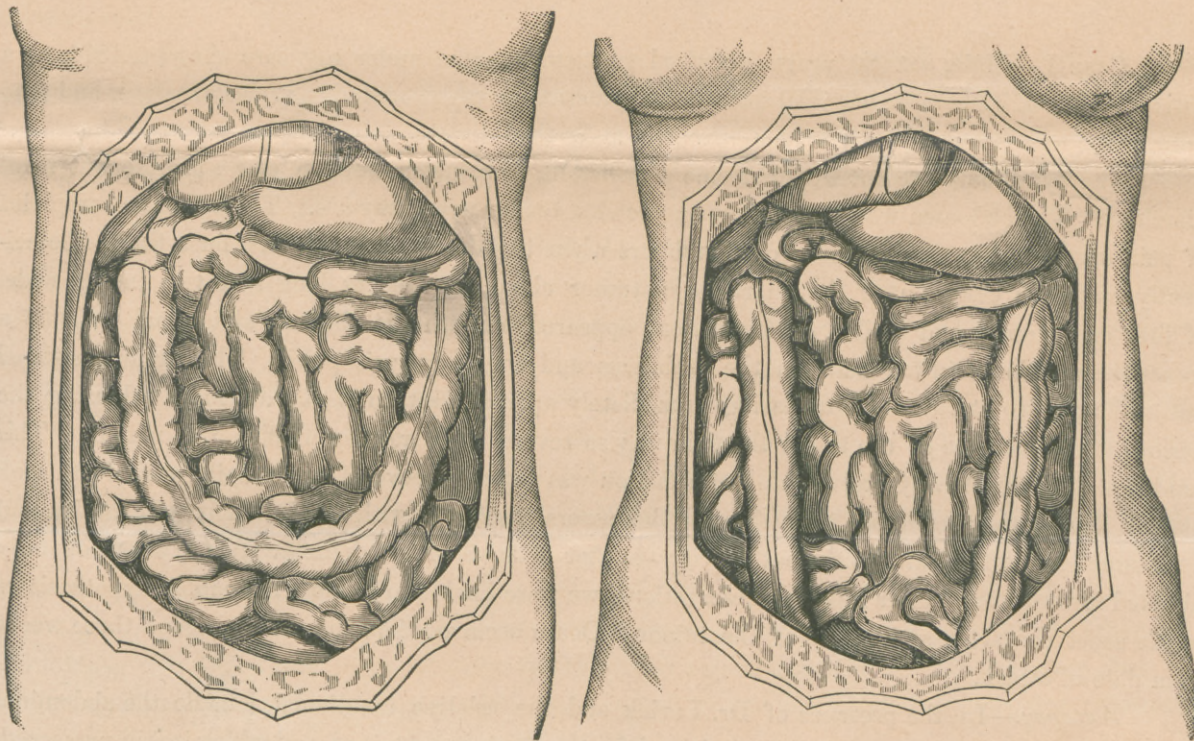


FIG. 192

FIG. 193.

A positive diagnosis was not made in any of the cases, although in two of them the striking clinical conditions present were studied with special care in association with experienced and highly



Thomas (C.H.)

898  
298  
196

## DOWNWARD DISPLACEMENT OF THE TRANSVERSE COLON.

skilled observers. In the second in order of occurrence, the relationship between it and the preceding one suddenly occurred to my mind, and was communicated to the operator while on our way to make the *post-mortem* examination. In the third case the actual condition present was strongly suspected before death. So that in both of these latter, special precaution was used at the autopsies to avoid disturbing the relative position of the abdominal viscera until their location had been accurately determined.

The lesion here described seems to be of rare occurrence. Thus far I have failed to discover a single recorded case; and not until this paper was nearly completed was I able to find any published reference to the condition, however vague. Several months ago I asked the assistance of Dr. Formad, who informed me that in a series of autopsies, numbering over 2,000, which he had made, he had not observed an instance of like character. He has also kindly sent me the following note:

“UNIVERSITY OF PENNSYLVANIA, Dec. 15, 1882.

“*Dear Dr. Thomas:*

“\* \* \* I looked very thoroughly through the literature of intestinal lesions, but did not meet any record of misplacement of the transverse colon.

“Very truly yours,

“H. F. FORMAD.”

CASE I.—Male, *act.* 80 years, a retired gentleman, came under my care August, 1874, as a patient of Dr. J. J. Levick, who had placed his practice in my charge during his vacation, and who informs me that there was no previous history of abdominal disease.

The symptoms present were extreme emaciation, feebleness, anorexia, and a profuse but fitful diarrhœa. The abdomen was retracted and somewhat tender upon pressure. There was no complaint of pain except at intervals of three or four hours when the diarrhœa had ceased for a time. Coincidentally with the cessation of the diarrhœa a tumor about five inches long and two inches wide, of firm consistency, and visible on inspection, appeared beneath the thinned abdominal walls in a transverse position midway between the umbilicus and the symphysis pubis. The tumor persisted but an hour or so at a time, disappearing immediately upon the return of the diarrhœa. During the periods of continuance of the tumor the pain was so severe as to rapidly weaken the patient. This condition of alternate flux and painful tumefaction was repeated several times daily until death took place. During the attendance upon the case there were associated with me Dr. Albert H. Smith and a distinguished physician from another city—a near relative of the patient. With attention fully directed toward it, and after repeated observations, we were unable to frame a reasonable hypothesis as to the exact character and origin of the tumor. Death occurred September 12th, about three weeks from date of attack.

*Autopsy.*—In the presence of Dr. Levick and the relative mentioned, I made the abdominal section. To the former I am especially indebted for the specimen obtained, and which is still preserved.

Upon laying open the abdominal cavity the transverse colon was found to be greatly elongated and proportionately narrowed, the loculi being nearly obliterated, forming a loop open at the top similar to the letter U (Fig. 192), the most dependent portion occupying the position of and constituting

## DOWNWARD DISPLACEMENT OF THE TRANSVERSE COLON.

the tumor as above described, i. e. the horizontal portion of the loop rested upon the small intestines, midway between the umbilicus and the pubic symphysis.

II.—Female, *act.* 54 years, a lady of delicate frame and refined habits of life, was under my charge for about ten months prior to her decease. During the greater portion of this period Dr. Jas. H. Hutchinson was associated with me in the attendance. Dr. Chas. K. Mills also saw her for me during my vacation. The patient had previously been attended by a homeopathic practitioner who had diagnosticated her condition as enlargement of the liver and stricture of the rectum. The latter supposed condition he had treated by the introduction of rectal bougies; this practice being afterward abandoned on account of the pain produced, and the lack of beneficial results.

Profound cerebraesthesia from other causes, with several months of delirium, and which finally led to a fatal result, served greatly to complicate the issues involved. The abdominal conditions which had been recognized from the beginning were thus either masked or placed entirely in abeyance during much of the time.

The more prominent symptoms recognized were (1) pain, referred chiefly to the region of the liver and extending both upward and downward, which pain was aggravated by walking, and was described as of a dragging, tearing character, and which had existed for four years or more. It was very much relieved by the recumbent posture, and after some months spent mostly in bed almost entirely vanished.

(2) Obstinate constipation with indications of obstruction, even a liquid passage being voided with difficulty. The capacity of the rectum to retain enemata also was diminished to two ounces.

(3) Two solid tumors elongated in form and of the consistency of solid fœces were discovered, located one on each side of the abdomen, and evidently just beneath the parietal structures. They were vertical in position, and about eight inches distant from and so parallel to each other, and were traced from the border of the ribs to within about two inches of the pelvic brim. This condition was observed but a few times, and at considerable intervals; at other times it was absent. The hypothesis was adopted that these masses were the ascending and descending colon, respectively, in a state of fœcal impaction.

Death occurred March 30, 1883, supervening upon a severe mental shock. An autopsy was made by Dr. Wm. M. Gray two days later, Dr. Hutchinson and myself being present. To quote from Dr. Gray's notes: "Upon opening the abdomen found complete prolapse of the transverse colon (Fig. 193). It was carried beneath the pubis and rested on the bladder. The large intestine was much narrowed, and was filled throughout with hard nodulated fœces; the meso-colon was absent and the omentum, which was free from fat, was extremely atrophied; the rectum was normal, showing no evidence of stricture; the liver was of normal size, but upon microscopic examination showed marked cirrhosis."

Thus, that which had appeared to be the ascending colon proved to be the descending limb of the displaced transverse colon; and that which had seemed to be the descending colon was shown to be the ascending limb of the same malformation.

The pain which had previously been felt in the region of the liver and which had been relieved by recumbency had manifestly been caused by the sharp flexure of the colon contiguous to it; and the rectal obstruction by the crowded condition of the pelvis produced by the invading loop of large intestine.

DOWNWARD DISPLACEMENT OF THE TRANSVERSE COLON.

CASE III.—Male, *æt.* 30 years, a tailor's cutter, under attendance nine days prior to decease. He was the subject of advanced Bright's disease, with "hyaline, epithelial and granular tube casts, mucous cells, compound granule cells, and free oil globules." He also complained of severe pain in the abdomen to the right of and slightly above the level of the umbilicus. Upon inspection and palpation of the part no enlargement or induration was discovered; but light percussion developed an intensely tympanitic sound confined to the region described. Misplacement of the transverse colon was suspected, and the region kept under observation for any evidences of fœcal impaction which might, but which did not, present. Death occurred suddenly March 19, 1883. *Autopsy* two days later, Dr. Wm. M. Gray operator, Dr. Wm. H. Burke and myself being present.

The following notes were made by Dr. Burke. \* \* \* "Body rather emaciated, and showing signs of commencing decomposition. On opening abdomen absence of fat noted, omentum normal. Peritoneum showing traces of lymph and pus, in the pelvic region especially, but no general inflammation. "Transverse colon empty, distended with gas, and has a sharp flexure at its center, bending obliquely downward and toward the right, to the level of the umbilicus, thence sharply upward to its normal position at the hepatic flexure. Meso-colon intact and apparently normal except in length. No sign of fœcal obstruction at the point of flexure. Both kidneys scirrhotic; capsule adherent, and secreting structure destroyed."

Evidently the heightened tympany localized near the umbilicus, which had been previously recognized and ascribed to the presence there of a portion of the transverse colon misplaced, had in reality been so caused.

No adhesions of the displaced parts were found in any of the cases cited. The intestinal fault was probably not the cause of death in any of them. Taking them together it will be seen that clinical conditions and *post-mortem* appearances agree in at least one important particular, viz., the location of the displaced intestine in contact with the anterior abdominal wall and below its normal site.

The anatomical relations of the ascending and descending colon respectively, it should be borne in mind, are in contact with the *posterior* abdominal walls, behind the small intestines, being bound down by reflections of the peritoneum. It therefore seems a practical impossibility for these portions of the colon to become spontaneously misplaced anteriorly. But of the transverse colon which is normally in contact with the *anterior* wall, in front of the small intestines, where it is suspended by the longer transverse meso-colon, these cases show that its displacement downward is of repeated occurrence.

*Conclusions.*—(1) Displacement of the transverse colon downward within the abdomen may be to any degree, partial or complete.

(2) Such displacement will present as solid tumor if the bowel be in a state of fœcal impaction, or as a limited area of heightened resonance if the bowel be distended with gas; but in either case the displaced part is to be found *in contact with the anterior abdominal wall.*

(3) The occurrence of intra-abdominal tumor situated below the normal site of the transverse colon, and having the same general configuration as the colon, such tumor being of a certain consistency, and presenting evidences of being in contact with the anterior abdominal wall; or, the occurrence of areas of special tympany with like outlines and similarly located, constitute diagnostic signs strongly indicative of downward displacement of the transverse colon.



Monroe (6-X-1)