

Taylor. (Thos)

INTERNAL PARASITES IN THE
COMMON FOWL.

By THOMAS TAYLOR, M. D., Washington, D. C.

Reprinted from the Proceedings of the American Society of Microscopists.

[Buffalo, 1883, VI 7

CHICAGO MEETING, 1883.



Internal Parasites in the Common Fowl.

BY THOMAS TAYLOR, M. D., Washington, D. C.

Mr. D. Turner, of Washington, D. C., observing that one of his domestic fowls had been ailing for some weeks, requested me to make a post-mortem examination of it to ascertain, if possible, the cause of its sickness. The fowl was brought to me in a moribund condition, and died within an hour after its reception. Its comb presented a deep red color, changing to black. I removed the viscera, and found them, with the exception of the lungs, in an apparently healthy condition. I observed, however, on the intercostal muscles, bordering on the ribs, what resembled a reddish-

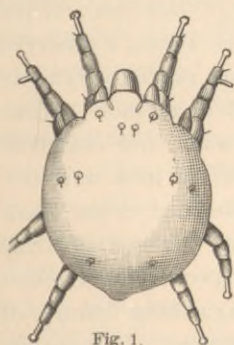


Fig. 1.

yellow pigment spreading over the surface in streaks, while small specks of various forms covered the lining of the abdominal cavity. These specks varied in size from the point of a pin to that of a small pin head. On removing a small portion of the colored matter and viewing it under the microscope, I found it to consist of mites, *Cytoleichus surcoptoides*, Megnin (Fig. 1,) in various stages of growth. I next removed a small portion of the lung tissue, and found in it several living mites of the same character. I subjected other portions of the lungs to the same examination, and found in them large numbers of these living mites, some of them so lively that it was difficult to keep them long in view under a $1\frac{1}{2}$ inch objective. Although there is no record of this species being hitherto discovered in this country, it is known in Europe and is described by Megnin, who states that it causes there the death of



wild and domestic fowls. He says it is found in the air passages of the lungs, in the bronchial tubes and their diversions, in the bones with which the air sacks communicate, and in other cavities. It is also found in the bronchi of birds, and when present in large numbers causes titillations of the bronchial mucous membrane, indicated by a slight cough, in some cases giving rise to symptoms of asphyxia and congestion, to which the bird may succumb. He instances the case of a pheasant which died of an unknown disease, and in which, when dissected, this obstruction of the bronchi was plainly seen. I think it probable that these mites, after they have effected a lodgment in the lungs, bore through the pleura and invade the thoracic and abdominal cavities, where they breed in large numbers, producing great irritation and ultimately the death of the fowl.

About two months after the dissection of the fowl above mentioned, a second one was brought to me for examination by the same gentleman who brought the first. The comb of this, like that of the other, was highly engorged with blood and black at the tips. Its crop was greatly distended. It was unable to stand up, had a slight cough, and breathed with difficulty, yet exhibited considerable strength when about to be killed. It had been ailing during the previous four weeks. On removing the skin of this fowl, for the purpose of examining the condition of its cellular tissue, I observed great numbers of small white specks of calcareous matter, varying in size from the one-hundredth to the one-twelfth of an inch. When these opaque bodies were gently crushed in water and examined under the microscope, the remains of a species of mite were discerned. On further investigation I found imbedded in the whole region of the cellular tissue quantities of living mites wholly free from the calcareous matter and of a different species from the first described. One of the most prominent distinguishing features of this mite was the presence of two caudal appendages. This species proved on further examination to be *Laminosioptes gallinorum*, Megnin, (Fig. 2), or a species closely related to it. The habitat of these mites seemed to be confined to the cellular tissue. I examined the flesh and viscera of this fowl for these mites, but found neither living mites, their remains, nor yet calcareous specks. Megnin states that in Europe this acarus has been found in all turkey hens, and

especially in foreign turkeys of the family Phasania. He says that these acari gather in millions in the cellular tissue and destroy the fibers, but without causing any other change than the production of the calcareous concretions spoken of. He further says that they have been noticed in such numbers in old birds as to leave no doubt as to their being the cause of their death. On examining the crop of this second fowl, which, as I have already said, was greatly distended, I observed without the aid of the microscope numerous specks, of a

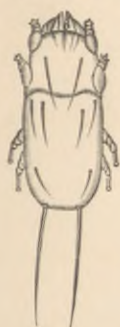

Fig. 2.

more uniform character than those found on the cellular tissue, distributed over the whole surface. I examined a small portion of the crop, not exceeding a quarter of an inch square, under a low power of the microscope, and found these specks to consist of what appeared to be a profusion or encysted *Trichina spiralis*, but on removing one of these nematoid worms from its watery cyst, and viewing it under a power of five hundred diameters, I found it to be an undescribed species; the male differing from any other nematoid, with which I am acquainted, in having on the terminal point of its caudal appendage a bulbous body covered with short spines. These encysted worms swarmed over the entire walls of the stomach and intestines and were apparently incased within the muscular coating.

On examining the tissue of a third fowl, which died from an unknown cause, I found numerous mites in its cellular tissue of the species *gallinorum* above described, while no other parasites were to be seen within its tissue or viscera. From the results of these examinations it seems probable that a considerable amount of disease prevailing among American domestic fowls, and not referable to any known type, may be due to the presence of such parasites as are described in the cases mentioned above. Investigations, therefore, in this direction may have an important bearing on the healthful raising of domestic fowl. I would suggest as a remedy for diseases so caused the sprinkling of the nests with a few grains of naphthaline, and the ground floor of the hen-houses might be sprinkled occasionally with a mixture of coal-oil and water in the proportion of one tablespoonful of oil to a gallon of water.

