



MONTGOMERY (D.W.)

A Case of Extirpation of the Uterus
per Vaginum for Epithelioma of the
Cervix, Complicated by Sarcoma
of the Body. _____





Montgomery (D.W.)

To Library

D. L. Lewis

Reprinted from the OCCIDENTAL MEDICAL TIMES, June, 1893.

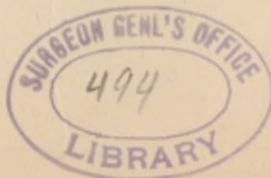A Case of Extirpation of the Uterus per Vaginam for Epithelioma of the Cervix, Complicated by Sarcoma of the Body.

By D. W. MONTGOMERY, M. D., Prof. Pathology and Histology, University of California, San Francisco, Cal.

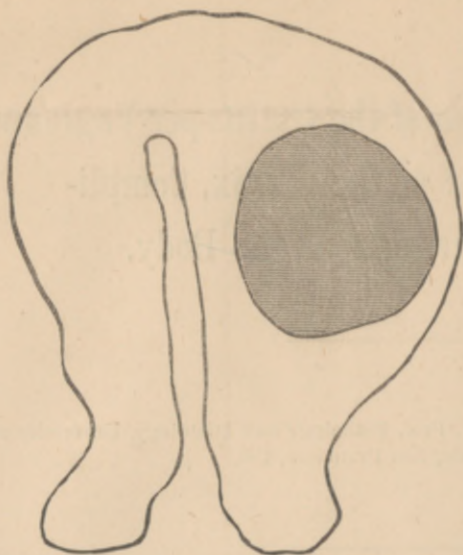
On August 30th, 1889, Dr. H. Kreutzmann brought me two small pieces of tissue, curettings from the uterus of a woman who had applied to him for an opinion, and in whom he suspected cancer. One of these pieces was from the uterine cavity, and with the exception of a large number of blood vessels, appeared to be normal. The other piece was from the cervix at the place where the flat epithelium of the cervical portion changes into the glandular structure of the mucous membrane lining the internal surface of the neck. A large, thick mass of flat epithelial cells could be seen driven down into the subjacent tissue, and in one specimen there were branches given off from this mass running down still deeper; and far down in the tissue of the cervix there were alveoli filled with irregularly arranged, flat epithelial cells. Both Dr. Kreutzmann and myself looked carefully over the specimens, and came to the conclusion that we had to do with a very early, but, microscopically, clearly recognizable case of epithelioma.

A few days later, Dr. C. Cushing sent me a wedge-shaped piece of cervical tissue, which he had cut out for microscopical examination. I sent back a report that there was some epithelial infiltration extending into the submucous tissue; that it was slight but unequivocal, and that it therefore must be regarded as epithelioma at an early stage of its development.

It transpired in a conversation with Dr. Cushing relative to this case, that both examinations had been made for the same patient. Dr. Cush-



ing removed the uterus and its appendages (both tubes and ovaries) some time in the beginning of September, within a week of the last examination.



Shaded portion shows telangiectatic round-celled sarcoma in anterior wall. This tracing was taken by placing a ground-glass plate over the cut surface of uterus. The tracing was made after the organ had been in alcohol for some time, so that all its dimensions are somewhat smaller than life size.

be a round-celled sarcoma, positively riddled with blood vessels.

As for the diagnosis, it was easy to see it was not an epithelioma derived from the neoplasm in the cervix for it was not alveolar in structure, and was composed of young, round, connective tissue cells, which were not at all epithelioid in character. It was not a lymphoma, for there are no lymphatic glands in this situation, and none of the other superficial lymphatic glands of the body were affected. Tuberculosis and syphiloma (gumma) were excluded, because of the peculiar telangiectatic blood vessels, and the absence of either the giant cells or the cheesy degeneration of tubercle, or the coagulation necrosis and low connective tissue of syphilis.

Forty-two months have now gone by without a relapse, a sufficient argument for early operation in such cases, and, furthermore, it illustrates the beneficial results of removing the whole diseased organ when attacked by malignant growths.

1124 Sutter Street.



