

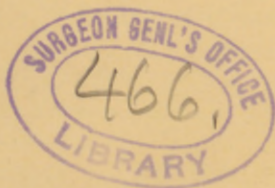ROBB (H)

RUPTURE OF THE SAC OF AN
EXTRA-UTERINE PREGNANCY
THROUGH THE FIMBRIATED
EXTREMITY WITHOUT TEAR-
ING THE FALLOPIAN TUBE.
OPERATION, RECOVERY.

BY HUNTER ROBB, M.D.,
RESIDENT GYNÆCOLOGIST TO THE JOHNS
HOPKINS HOSPITAL, BALTIMORE, MD.

Reprinted from
THE NEW YORK JOURNAL
OF GYNÆCOLOGY AND OBSTETRICS,
February, 1892.

NEW YORK:
M. J. ROONEY, PRINTER AND STATIONER,
1329 Broadway.



RUPTURE OF THE SAC OF AN EXTRA-UTERINE PREGNANCY THROUGH THE FIMBRIATED EXTREMITY
WITHOUT TEARING THE FALLOPIAN TUBE.
OPERATION, RECOVERY.

By HUNTER ROBB, M.D.

Resident Gynecologist to the Johns-Hopkins Hospital, Baltimore, Md.

Mrs. E. E. was admitted August 16, 1891, to Ward H of the Johns Hopkins Hospital, and came under my charge in the absence of Prof. Kelly. She was thirty years of age, had been married six months and had had no previous pregnancy. Her menses appeared first at the age of thirteen, were monthly and without pain until last March. The flow was always moderate lasting three or four days. Bowels constipated. Frequent micturition.

March 11th she complained of an unusual amount of aching pain in the left ovarian region during the time of her menstrual period; this recurred at each succeeding period. She returned home July 10th after an absence of one month.

August 11, 1891, no period appeared. The last menstruation July 11th had lasted three days, in no respect differing from the preceding ones.

August 1st she suddenly complained of sharp shooting cramp-like pains, in the left lower zone of the abdomen, accompanied by nausea and severe vomiting, which had not been present previous to the attack of pain. The pain was severe enough to cause fainting and "spasms" lasting four hours. The next day she was able to rise from bed and attend to her household duties for two hours, when she was again seized with pain and vomiting as before. The pain was now constant in the left lower abdominal region, while the "spasms" recurred morning and night lasting three hours each time. She also continued to suffer from nausea and vomiting and was unable to take any nourishment. In this condition she was admitted to the hospital August 16th.

A vaginal examination made on the day after admission revealed nothing definite. At the examination (without anæsthesia) the following notes were made: Outlet relaxed, cervix near the outlet, patulous and soft. Uterus enlarged, anteflexed and sensitive; sensitiveness most acute along its left side. To the left of the uterus an



enlarged and soft "tubo-ovarian mass" can be felt. This mass is of a doughy, semi-fluctuant consistence. Nothing can be felt on the right side. There was a peculiar stringy, slightly bloody secretion in the vagina. The breasts were not painful; and did not contain milk.

A diagnosis was at once made of a tubo-ovarian mass of doubtful nature.

Absolute rest was enjoined, and the patient prepared for more thorough examination upon the following day under chloroform narcosis; when the following additional notes were recorded: the outlet relaxed, cervix in the axis of the vagina, soft and somewhat bluish in appearance, most marked upon the posterior lip. The external os patulous, discharging a long, tenacious, muco-sanguineous plug. I also removed a dead house-fly from the upper part of the vagina. The uterus was anteflexed, movable, and enlarged about the size of a two-months' pregnancy. On the right side slight resistance in the broad ligament. The tube and ovary on this side could not be distinguished. On the left side the adherent tubo-ovarian mass, somewhat larger than a hen's egg is easily palpable. This is closely adherent to the uterus without a pedicle, and runs up the pelvis on this side, and with its axis obliquely upwards from the left cornu uteri towards the sacro-iliac symphysis.

Urine: Analysis of voided urine on the 17th of August. Reaction acid, color opaque, slightly reddish. Specific gravity 10.34. Abundant pinkish sediment. Amorphous urates, bladder cells and a few pus corpuscles. No albumen.

Examination August 21st, catheterized urine; cloudy amber color. Sp. gr. 10.23. No albumen, mucous sediment. Microscopic examination negative.

Operation: Incision through fat abdominal walls (6 cm. thick). On opening the peritoneal cavity a stream of black blood spouted out. The incision was enlarged to 8 cm. enabling me to rapidly remove many large clots (about 500 cc.) of blood, associated with about 500 cc. of fluid blood. After removing the blood from the pelvis, handful by handful, the mass was grasped, elevated and removed by transfixion ligature and cautery. The mass comprised the tube and ovary, densely adherent to each other and to the broad ligament. The extra-uterine sac lay in the tube near its fimbriated extremity and just within the ostium abdominale. Rupture had taken place through the fimbriated extremity which was patulous, and 2 cm. in diameter and choked with clotted blood.

The right tube and ovary were normal, perfectly free from adhesions, and were therefore not removed. The pelvis was washed out with six litres of a sterilized salt solution and then sponged as dry as possible. On account of the liability to subsequent hæmorrhage from the adhesions I used a drainage tube. The abdomen was then closed as usual. The drainage tube was removed six hours after the operation, only a few pledgets of cotton being moistened with blood. The patient reacted well; pulse and temperature remaining below 100° F. for the first twelve hours. They then began to increase; the tongue became dry and brown and considerable nausea with some abdominal distention existed. These symptoms continued for three days and then subsided. Through this time she was receiving stimulating treatment and after a thorough fæcal evacuation on the fourth day she improved. Again the temperature arose and the pulse became rapid; the outlook was not at all promising; but the vomiting diminished and she began to look better. After the seventh day she was out of danger. On removal of the sutures on the seventh day a small amount of purulent fluid exuded from the track of the drainage tube. The sutures at the upper and lower angles of the wound were not infected at this time, but the track of the drainage tube was thoroughly infected and within twelve hours time the whole line of the incision was also infected. The pus discharged freely for three or four days. Inoculations made from the pus in the track of the drainage tube at the time of the removal of the sutures, were pure cultures of the *Staphylococcus Pyogenes Aureus*. Cover slip examinations were also made showing numerous bacteria within and without the pus corpuscles.

I do not believe the infection originally existed in the abdominal cavity, but came entirely from the skin; entering by the track of the drainage tube, and to it were due in all likelihood the temperature and pulse disturbances as well as her general systemic disturbance.

Analysis of temperature chart following operation:

The temperature was registered for fourteen days by the mouth, rectum and vagina, and shows in some instances a difference of two degrees. The highest point registered was 105° F. by the rectum on the third day. It then fluctuated between 99.4° F. by the mouth and 101° F. by the rectum to 104.2° F. by the rectum and 102.4° F. by the mouth. The temperature then progressively decreased from the eighth day until the fourteenth, when it registered 100° F. by the rectum and 99.4° F. by the mouth, and 98.8° F. by the va-

gina. From the fifteenth day until the twenty-ninth the rectal temperature fluctuated from 100° F. to 103.2° F. This point it reached only once. The patient is now perfectly well.

Macroscopic description of specimen:

The specimen consists of the right fallopian tube containing the foetal sac, and the right ovary. The tube is 9 cm. long ($3\frac{1}{2}$ in.). Beginning at the cornual end of the uterus it is 1.2 cm. in diameter ($\frac{1}{2}$ in.) for 4 cm. ($1\frac{1}{2}$ in.) of its length; the remaining 5 cm. (2 in.) is 4 cm. ($1\frac{1}{2}$ in.) in diameter. The posterior surface of the tube is covered with well formed connective tissue adhesions, which had bound the tube to the posterior surface of the uterus in the *cul-de-sac*.

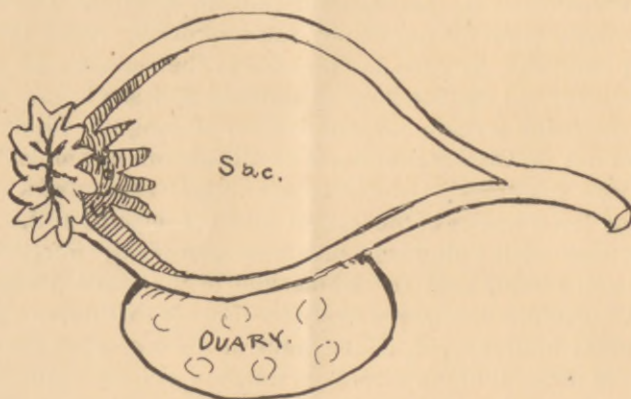


Figure is diagrammatic, showing the relation of the sac to the tube wall, its ruptured outer extremity pouring blood out of the intact tube through its fimbriated end. The shading represents the blood clot plugging the tube.

The walls of the tube are thickened and injected. At no point can a rupture be discovered in the tube. The fimbriated extremity however, is patulous, 1.3 cm. ($\frac{1}{2}$ in.) in diameter; the fimbriæ are enlarged, congested, thickened and spreading; the ostium abdominale is plugged with a firm clot of blood. On displacing this and opening the tube a stellate rupture is seen in the sac communicating with the ostium abdominale by a short canal, 6 mm. ($\frac{1}{4}$ in.) in diameter. Here the rupture occurred, and from this, part of the hæmorrhage followed, thus entering the abdominal cavity without rupture of the tube. In an area adjacent to this point of rupture there is also a complete separation of the sac; from the wall of the tube, this space was filled with a yellowish, firm, decolorized clot.

Microscopic examination showed the chorionic villi. A thorough examination of the two litres of blood-clots removed failed to discover the embryo, which could not therefore be found.

Summary :

We had therefore the following elements in forming a diagnosis :

1. *A woman always regular in her menstrual habit and free from disease.*

2. *Marriage, menstrual period continued regular and natural.*

3. *Sudden cessation of menses without any apparent morbid cause.*

4. *Seventeen days after cessation of last menstrual period (which occurred on July 11th) she was suddenly seized with paroxysms of severe cramping pains in the left lower abdomen accompanied by nausea and severe vomiting. Another attack the day following. The pain and nausea were persistent.*

5. *The next menstrual period due August 11th failed to appear.*

6. *Examination. Bloody discharge in the vagina, soft cervix, blue color, enlarged anteflexed uterus. Ovoid mass to the left of the uterus, very tender to touch.*

Diagnosis: ruptured early extra-uterine pregnancy, verified by operation.

