

Ross (Gas. F. W.)

Abdominal Section for Purulent Peritonitis Re-
sulting from Ectopic Gestation.

BY

JAMES F. W. ROSS, M. D.,

TORONTO, CANADA.

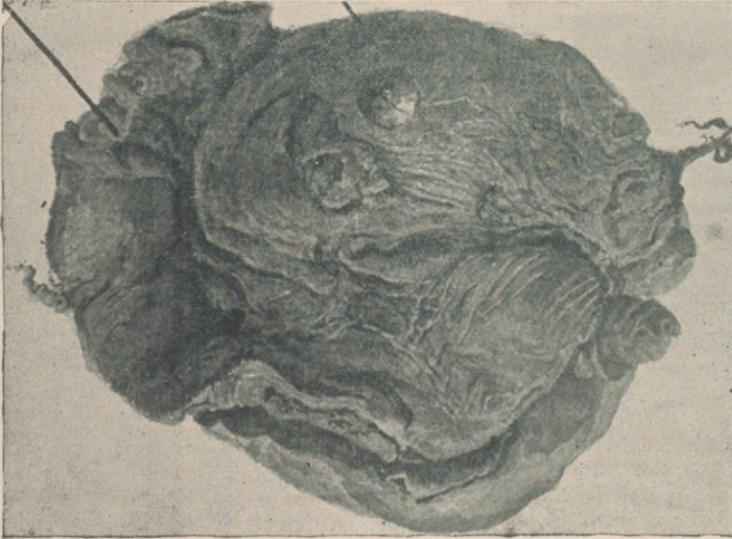

REPRINTED FROM

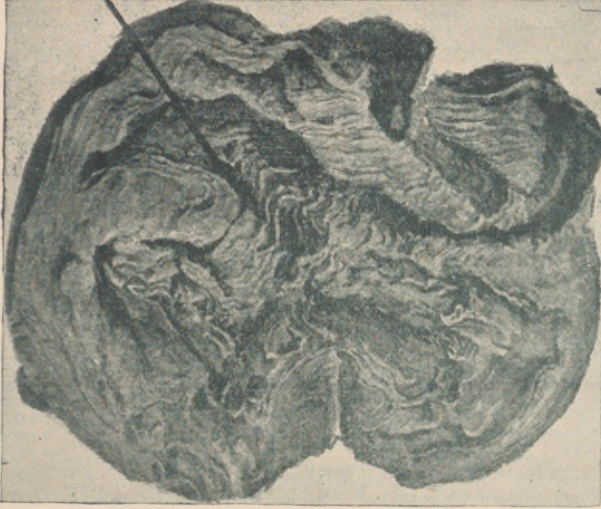The American Gynecological Journal, Toledo, O.,

JUNE, 1892

Tube with
placenta
inside of it.





Organized
blood clot.



Suppurating
interior
of organized
blood clot.



CLOT IN WHICH SUPPURATION TOOK PLACE, AND FROM WHICH PUS RUPTURED INTO ABDOMINAL CAVITY,
CLOT DUE TO OLD RUPTURE OF ECTOPIC GESTATION.



ABDOMINAL SECTION FOR PURULENT PERITONITIS RESULTING FROM ECTOPIC GESTATION.¹

BY JAMES F. W. ROSS, M. D., TORONTO, CANADA.

The study of ectopic gestation has brought to light many conditions that before were scarcely dreamed of, and the list of these has perhaps not yet been exhausted. The case presented to you to-day is one that in my experience is unique. I have now operated on the following cases of ectopic gestation:

No. 1.—Extra-uterine foetation in a woman with a bicornuate uterus. Operation done two weeks after term. Recovery.

No. 2.—Tubal gestation; rupture into the abdomen during a vaginal examination. Immediate summons to the house to find the woman collapsed. Operation three days later. Abdomen filled with blood. Recovery.

No. 3.—Tubal rupture, evidently into the broad ligament. Operation done owing to excessive uterine hemorrhage and for purposes of exploration. The sac washed out and drained and not removed owing to the difficulties encountered. Subsequent hemorrhage through the drainage tube for nearly two months, at times so free as to cause alarm. Recovery after six months. I examined the pelvis of this woman a few weeks ago, two years after operation, and found no trace of any abnormality. Uterus freely movable. Complete absorption must have taken place. She is now about two months pregnant.

No. 4.—A case of tubal pregnancy. Rupture of tube, and abdomen full of blood, with no resulting shock. Woman walking around until the morning of the operation. Recovery.

No. 5.—A case of what appeared to be an abdominal pregnancy. The sac with the foetus was high up on the left side and imbedded among the intestines. Rupture had taken place into the abdominal cavity, and the foetus (that of about three months' gestation) died and was found at the operation in a partially decomposed condition. The intra-peritoneal hemorrhage had produced inflammatory action, and the blood had become shut off from the general peritoneal cavity, but communicated with the foetal sac. This collection of blood began to suppurate and I saw the woman only in the last stage of septicæmia, after five weeks of intra-peritoneal suppuration. Operation was performed with but slight hope of benefit, and the patient sank and died in about thirty hours. The uterus and broad ligaments were examined after death, and I could not make out any connection between the foetal sac or suppurating cavity and the broad ligaments.

No. 6.—This is the case I desire specially to bring before you to-day, and you will therefore be inflicted with the tedium of a detailed history.

1. Read by invitation before the Section of Obstetrics and Gynecology of the Michigan State Medical Society, May 5th, 1892.

Mrs. M., aged 24 years. She menstruated first at the age of 13 years, and up to the time of marriage was in good health. On June 24th, 1891, she married. On July the 3d or 4th she became unwell. She was regular until October when she went one week over her usual time. Menstruation then came on as usual, and four weeks after, in November, the menstrual flow again appeared. She does not know the exact date of the first onset of pain. When it did appear it was of a darting character, passing from the right groin across the lower abdomen. She was doubled up with it and supposed that she was suffering from ordinary colic. As she put it, she "held herself together with her hands" to obtain relief. The pain then left her, but soon came on again. On Thanksgiving day, in November, she was out driving, when there was a sudden invasion of pain accompanied by nausea, but with no vomiting. She hurried home, took a hot drink and went to bed. Next morning she rose and went around as usual, but felt very sore across the lower abdomen. She could not straighten herself up. She felt weak, but did not faint, nor was there any cold perspiration. The next attack affected her right leg; the pain shot down the inner side of the right thigh. Menstruation appeared as usual; there was nothing abnormal to be noticed about her menstruation. The pains were similar to, though much more severe than those of a monthly period. Frequent desire to urinate now came on and the urine was of a brownish color. Defecation was perfectly normal. The suffering was so great that she frequently cried with it. Her husband became very uneasy, and said that something must be done to relieve her, and her physician, Dr. Cuthbertson, called me in to see her in consultation. She was so nervous that no satisfactory examination could be made without using an anæsthetic, and chloroform was administered. A distinct mass was to be felt in a very unusual position right behind the pubic bone on the right side, and between the bladder and the uterus. It seemed to be fixed to the bladder. The posterior cul-de-sac was empty and the left parametrium clear. The case was a very puzzling one. There were no symptoms of pregnancy present. The uterus was not enlarged, but was, in fact, smaller than the virgin uterus in most females. Menstruation had been perfectly regular with the exception of the few days of delay of the period in October. I was first called to see her about the 7th of December, and advised tentative measures. She appeared to suffer so much, from her own story and that of her husband, and to have so little systemic disturbance, according to the account of her physician, that I felt unable to venture any opinion. Ectopic gestation was talked of, but not positively asserted to be present.

Pus tube was also taken into consideration, but was not thought to be indicated by the symptoms. Her physician leaned toward a diagnosis of parametritis, but I pronounced such a disbelief in this disease, except in very rare cases following some definite cause, that he

became doubtful of the correctness of his diagnosis. It is true that the text-books tell us that a mass found between the uterus and bladder is usually a deposit due to cellulitis. But my cases of cellulitis have not borne out the opinions of the books, but have proved to be cases of actual intra-peritoneal disease. I did think, however, that at last I had a case of true cellulitis and therefore hesitated before advising a laparotomy. She refused to come into the hospital under my care until she had enjoyed the usual Christmas festivities. She was admitted on the 7th of January, 1892. Temperature and pulse normal. She seemed to be very nervous, but otherwise appeared in perfect health. The hardness in the right inguinal region could be distinctly felt by firm pressure with the finger tips, pressing from above toward the pelvic cavity. Three days after her admission I found her suffering from slight pain in the "old spot," as she called it, and with a slight elevation of temperature. This was on a Saturday. On Monday she was in about the same condition, but not requiring any opiate. I was unable to see her again until Wednesday evening, when, while passing hurriedly through my wards, I was struck with her appearance. On looking at the temperature chart I found that her temperature had gone up suddenly the evening before to 103° and pulse to 115. She had been suddenly attacked with vomiting and this had continued all night. She lay with her knees drawn up, face pinched, and two hot water tins had been placed in bed beside her. The evening before she had had a rigor. The abdomen, though excessively tender all over, was perfectly flat. No distention was as yet to be noticed. On passing my finger tips down to feel the hardness I found that it had to a great extent disappeared, and at once diagnosed the rupture, of what I now supposed to be a pus tube, into the abdomen. After reprimanding those in charge for not having apprised me of her condition the day before, I ordered her immediate preparation for operation early next morning. Fearing the difficulty to be encountered in the vomiting following the anaesthesia, I ordered a large dose of calomel, to be followed by two or three Seidlitz powders and enemata until thoroughly effective, so that the full benefit of purgatives would be obtained while the stomach was retentive. This large dose did not have any more effect than the ordinary dose given before laparotomy as a matter of routine, and next morning the abdomen was markedly distended. I felt sure of my diagnosis of ruptured tube and general peritonitis the night before, though I now know that others thought that I was too hasty in coming to a conclusion. But when morning came and the distention was so visible, I felt reassured. I felt some anxiety when making the incision, before a critical audience of doctors and students, until the peritoneal cavity was opened and the pus gushed out. I had operated on several cases of purulent general peritonitis before, but not until the diagnosis was made easy by the distention and rapid pulse and the patient was past

hope (as I now know) of recovery. The mass felt before operation was now found surrounded by chocolate-colored decomposed blood and pus, and to my astonishment it shelled out with the greatest of ease. I found curled behind it a dilated tube and, after ligating, removed it. The sac first shelled out lay in the lateral pouch, with the uterus behind and on its inner side, and the bladder on its anterior and inner side. The tube lay fixed along the peritoneal fold that constitutes the utero-sacral ligament. The cul-de-sac of Douglas was empty and the uterus and bladder were free from adhesions except where coming into immediate contact with the mass. After shelling out the first sac I was agreeably surprised to find that there was no hemorrhage. Usually the hemorrhage is alarming until the uterine end of the tube is ligated. I now washed the pus from behind the liver and spleen, from in front of the kidneys, from among the non-adherent intestines, with gallons of hot water passed through the largest sized Tait's trocar from a large douche pail. I have irrigated many an abdomen, but never scoured one out so thoroughly before. A drainage tube was placed to the bottom of the cavity from which the sac was shelled and not to the bottom of Douglas' pouch. The patient was put to bed in a weak condition. Within twenty-four hours the fluid coming from the abdomen became clearly serous and of a straw color. It was not purulent after the washing out, until about the third day after the operation, when it became very evident that the newly formed tissue lining the cavity from which the sac was shelled out was breaking down. Intra-abdominal washing was now carried out every two hours through the drainage tube. The serum must have been excessively poisonous. It irritated the fingers just like a very sour solution of nitric acid and water. For one and a half inches around the wound, in spite of antiseptic powders and dressings, the skin took on a reddish, glazed, almost erysipelatous appearance and numerous red lines, looking like the branches of a tree, could be traced for another inch away from its margin, running into the healthy skin. These were septically infected capillaries.

The bowels were extremely obstinate. After the operation the distention increased and was almost too much for us. Hourly enemata of castor oil, soapsuds and turpentine were given, and calomel, compound cathartic pills, Seidlitz powders by the mouth, and these were later on fortified by parvules of aloin, belladonna and strychnia (Aloin, gr. $\frac{3}{8}$; belladonna, gr. $\frac{1}{4}$; strychnia, gr. $\frac{1}{30}$) every four hours.

I never saw the effects of increase or diminution of distention to such advantage. If the purgatives were omitted for a time, the distention would increase and the patient would complain of pain, and the pain was entirely absent as long as the bowels were only moderately inflated. Convalescence was slow and anxious, and it is partly to bring this fact before you that I am presenting this case to-day. If cases of peritonitis are to be saved by operation, no half-way measures will

suffice, and even after the offending nidus of infection is removed the patient will have a hard struggle for life. But, without operation, such cases must surely die; and if only five per cent. are saved, we are assuredly snatching five people from the very edge of the grave. Only a few days ago I had an interesting chat with the lady, and she told me that she had never felt better in her life.

On examining the specimens, I found that the dilated tube was the seat of an ectopic gestation and that the placenta was still in situ; that the foetation had only advanced (as far as one could judge by comparison with other cases) to about the sixth or seventh week; that no foetus could be found; that the sac, shelled out so readily, was an organized blood clot, with firm walls, in an advanced state of change to fibrous tissue; that the centre of the clot had broken down and become purulent; that a rupture of this pus had occurred into the abdominal cavity and had set up the intra-peritoneal inflammation.

Many lessons may be learned from such a case as this and cases such as those mentioned previously.

First.—An ectopic gestation may rupture either into the abdominal cavity or into the broad ligament, and become so completely absorbed as to leave no trace of its previous existence and this absorption will be carried out without the use of electricity.

Second.—Such rupture may be immediately dangerous from excessive hemorrhage, or remotely dangerous from subsequent suppuration.

Third.—That such suppuration may be due to a decomposition of the foetal structures or may occur in the centre of an organized clot, independent of any such decomposition.

Fourth.—That a sudden attack of peritonitis may be due to the rupture of such a suppurating clot into the peritoneal cavity, and that this may be a much more frequent cause of peritonitis than we have ever believed it to be.

Fifth.—That the usually accepted symptoms of ectopic gestation may be almost entirely absent when ectopic gestation is present.

Sixth.—That operation for the cure of purulent peritonitis must be done early, before extreme distention is present.

Seventh.—That in obscure cases of acute general peritonitis laparotomy is a correct and justifiable procedure, if carried out by some one accustomed to abdominal surgery, with a sufficiency of trained help to carry on the vigorous measures that constitute the after treatment.

In preparing a paper to present to your flourishing society, I consulted the Secretary of this section and offered him several subjects on which I was ready to write and he chose this one. My intention was to present something short and practical and I have endeavored to keep within reasonable bounds. If you have been disappointed, your Secretary must shoulder the responsibility. And now, before closing, I would like to reiterate opinions I have expressed elsewhere. The surgical

treatment of obscure intra-peritoneal disease is as yet in its infancy. We are prepared to make a few mistakes for the sake of the benefit that must accrue to mankind from the vast amount of actual accurate information that we will obtain. To operate on a patient with an enormously distended abdomen, cold hands, rapid, thready pulse, and in a profoundly septic condition is unwise. If the patient dies—as they always do—people at once ask themselves the very reasonable question: “Why did the doctor operate?” Well, why did he operate? Because everything else had been tried and failed; he operated as a last resource. This should not be. Operation should be instituted in all cases of peritonitis that do not show signs of improvement, and in which the origin of the disease is veiled in obscurity, for purposes of diagnosis, before all chance of relief from the operation is removed. Opening into a peritoneum, already the seat of a violent inflammation, cannot add to the inflammation already present. For every attack of peritonitis I believe there is a cause, and we will find the cause if we look for it in the proper way. Guessing at the cause from without the abdominal walls will not help us. If any of you have carried out experimental work on the abdomen of the dog, you must frequently have been amazed at the intra-peritoneal condition found after pistol shot wounds of this cavity. The abdomen is full of feces, blood, and even worms, after a very few minutes. Intestines are smashed to pieces in many places. We are convinced that such an abdomen, in a dog, after such an injury, should be opened at once. If this is true of the abdomen of a dog, it is equally true of the abdomen of a man. Our methods of dealing with such injuries after the abdomen is opened are not yet as perfect as they will be ten years hence, but they are better than the “no method” treatment of calling to see the patient three or four times a day, with or without consultants, of giving him opiates to relieve his pain, and buoying ourselves up with the hope that the bullet, or the knife, or the kick, or other violent injury did no serious damage. And then when the patient is handed over to the undertaker we console ourselves, and endeavor to console the friends of the deceased, by saying that all was done that could be done. I can point out to you three surgeons who have lost three sons from appendicitis. Surgeon No. 1 lost his eldest son before the operation was instituted for the relief of this condition. Surgeon No. 2 lost his only son—himself a physician—after the operation had been performed. Surgeon No. 3 lost a lad, scarcely four years of age, after operation for perforation of the appendix and purulent peritonitis had been performed—but too late. Each surgeon learned a life-long lesson that has been of practical value to him since, and has enabled each of them to save lives that would otherwise have been sacrificed.

Many a young practitioner, when brought face to face with a case of acute peritonitis or a case of abdominal injury, strong with the faith that is within him, is forced by the overpowering weight of circum-

stances to stay his hand and to let the golden opportunity slip by. If these feeble utterances are of value in reassuring any such, I shall feel more than amply repaid for coming so far to express them.

