

100
246

Henrotin & Herzog.

Myoma Ovarii; Endothelioma
Ovarii; Calcified Corpus
Luteum

BY

FERNAND HENROTIN, M.D.
Professor of Gynecology,
Chicago Polyclinic

AND

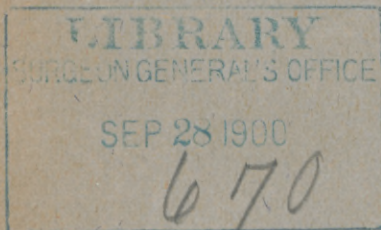
MAXIMILIAN HERZOG, M.D.
Professor of Pathology,
Chicago Polyclinic

REPRINTED FROM

THE AMERICAN JOURNAL OF OBSTETRICS
Vol. XI. No. 6, 1899

NEW YORK

WILLIAM WOOD & COMPANY, PUBLISHERS
1899



MYOMA OVARII;
ENDOTHELIOMA OVARII;
CALCIFIED CORPUS LUTEUM.¹

The three cases to be reported in this paper represent pathologic findings only rarely met with in the ovary, and they therefore deserve to be placed on record.

I. LARGE MYOMA OF THE OVARY.

Myomata must be enumerated among the rarest connective-tissue tumors of the ovary. Some writers have formerly claimed that these neoplasms are never found in the ovary. There are, however, now on record a few well-authenticated cases of this kind, to which we can add another. Our case is that of a pure myoma like the one recently described by Martin and Orthmann,² who also quote the reports of similar tumors observed by Sangalli, Jacoby, Doran, and a few others. While pure myomata of the ovary are evidently very rare, fibromata are much more frequently found, though they are by no means very common. From a study of the literature of the subject, it appears that the pure myoma of the ovary to be here described is larger than any other one heretofore observed. There have been described, however, larger ovarian fibromata.

The history of the case is as follows: April 16, 1898, Mrs. O. J., Canton, Ill., 22 years old; married; a rather small though plump woman; has never had any children or miscarriages. The family history does not present anything particular; it is negative with reference to tumors. Mrs. J. began to menstruate at the age of 13 years; menses normal till 16 years. At this time patient had a fall from a bicycle and the handle bar struck her in the left inguinal region. She complained of

¹ Read before the American Association of Obstetricians and Gynecologists, at Indianapolis, September 19-21, 1899.

² Martin: *Die Krankheiten d. Eierst, Leipzig, 1899, vol. ii., p. 642.*

severe pain in the abdomen immediately after this accident, and was laid up in bed for some time. Her menses ceased for three months, then reappeared and were regular for three months. Again they ceased, this time for four years. From 1897 to the present time she has flowed only occasionally.

Soon after the fall Mrs. J. noticed in her abdomen a lump the size of a hen's egg. This swelling gradually but slowly grew larger until about two or three months ago, when its size increased very rapidly to enormous dimensions, filling the whole lower portion of the abdomen. Mrs. J. complained of being nauseated at times, and being inconvenienced by frequent desire to micturate, also by being constipated, nervous, weak, and of suffering frequently from headaches and bearing-down pelvic pains.

A bimanual examination revealed the presence of a large, hard, roundish, smooth, non-fluctuating tumor situated entirely in the abdominal cavity. It was movable and distinct from the uterus, which, however, in consequence of traction, appeared to move with the tumor. In view of the fact that the tumor appeared perfectly distinct from the uterus, a probable diagnosis of large solid tumor of the ovary was made and an operation advised.

Operation April 16, 1898, at the Policlinic Hospital. The abdomen was opened by a median incision extending from half an inch above the symphysis pubis to very near the umbilicus. A large, oval, perfectly solid tumor of the right ovary presented. The new growth was smooth all over its surface and had not formed adhesions with any of the neighboring parts or organs. The uterus, the ovary and tube of the left side were normal. The abdominal cavity contained a moderate amount of clear, serous fluid. The large tumor of the right ovary and the tube of the same side, as well as the free fluid, were removed from the abdominal cavity.

Peritoneal Toilet.—Abdominal wound closed by stages of interrupted sutures of catgut for the peritoneum and the muscle sheath and by silkworm gut for the superficial layers. The patient made an uneventful recovery. She was last heard from in April, 1899, when she stated in a letter that she was feeling very well and strong.

The tumor after removal weighed $9\frac{3}{4}$ pounds. It is egg-shaped in outline, its base *in situ* having been directed toward the right side. The diameters of the new growth are: 24 centimetres from side to side; 20 centimetres from above down-

ward; $14\frac{1}{2}$ centimetres from before backward. The anterior and posterior surfaces of the tumor are somewhat flattened;



FIG. 1.—Myoma of the ovary, $9\frac{3}{4}$ pounds in weight, 24 centimetres in its longest diameter.

the other surfaces are bulging and round. The entire growth is surrounded by a firm, smooth capsule, which is shining and highly translucent. It cannot be peeled off from the tumor




FIG. 2.—The myoma on the cut surface.

tissue proper, but is firmly adherent. On section the cut surface of the very firm growth looks like a typical myoma of the

uterus. The tumor is solid throughout; cysts of any kind are not seen. No trace of normal ovarian tissue is left. At the place where the pedicle was severed close to the tumor, the lat-

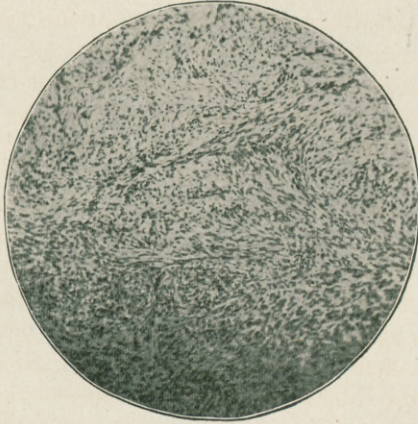


FIG. 3.—Section from myoma of the ovary, showing involuntary muscle cells. $\times 80$.

ter is denuded of its capsule, and the triangular surface shows numerous tolerably large, gaping, fairly thick-walled blood

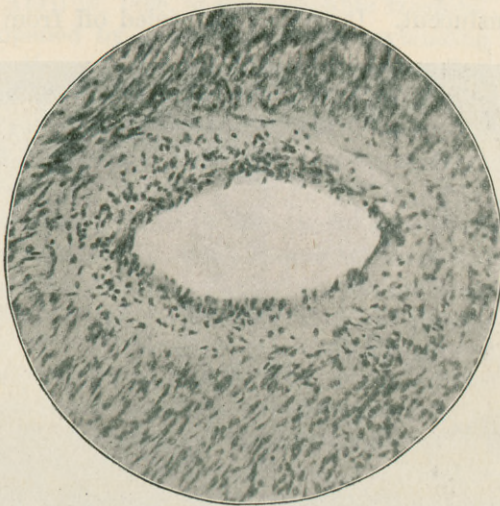


FIG. 4.—Section more highly magnified ($\times 200$), showing origin of tumor cells from the muscularis of a vessel.

vessels. There was removed with the tumor part of the tube of the right side to the extent of $4\frac{1}{2}$ centimetres. The inter-

stitial part of the tube as far as removed is enlarged to a diameter of over 2 centimetres. The fimbriated extremity is quite large; spread out it has a diameter of 4 centimetres. The fimbria ovarica is particularly large, being $2\frac{1}{2}$ to 3 centimetres in length (Figs. 1 and 2).

Microscopic examination shows that the tumor tissue consists of involuntary, non-striped muscle cells. These are arranged in bundles which interlace each other freely. A study of the section shows that the neoplasm took its origin from the muscular coat of the vessels (Figs. 3 and 4).

The tumor above described is interesting from more than one point of view. Its large size is, of course, an unusual feature. It appears that the origin of this benign neoplasm is directly traceable to a trauma. It is, of course, somewhat dangerous to draw such a conclusion concerning a true tumor, but it appears clearly from the history that, after the accident described, menstrual disturbances set in and a progressive swelling of the abdomen was simultaneously noticed. The tumor first grew quite slowly; later on it suddenly increased its rate of growth enormously. Such behavior has been previously noticed in connection with solid benign connective-tissue tumors of the ovary. The presence of ascites is likewise a not uncommon feature in large fibromata or myomata of the ovary. The microscopic examination failed to demonstrate the presence of any normal ovarian tissue. The latter had evidently been entirely replaced by tumor tissue. The neoplasm very probably from its start developed diffusely in the ovary, as these tumors commonly do.

II. ENDOTHELIOOMA OVARIUM.

A certain class of malignant tumors described formerly as alveolar sarcoma, carcinoma, or sarcoma carcinomatosum, is now more correctly classified as endotheliomata, since we know that they arise from endothelial cells. These neoplasms may be divided into vascular and lymphatic endotheliomata. The necessity for a proposed third group, called perithelioma (those endothelial tumors taking their origin from perivascular lymph spaces), does not appear to exist.

Endotheliomata have also been observed occasionally, but not frequently, in the ovary. Here they are sometimes of hard, sometimes of soft, consistence. They are generally unilateral, occasionally bilateral. Histologically the endotheliomata show an alveolar, a tubular, or a diffuse arrangement of

the proliferated endothelial cells. Any one of these types may be almost exclusively present, or they may all be found in one and the same tumor.

The case of endothelioma of the ovary to be reported occurred in a married woman about 30 years old. The patient, herself a practitioner of medicine, furnished the following history: "My trouble first began in the winter of 1891, previous to which time I had always had perfect health. First symptoms were irregular menstruation, severe nervous headache, and insomnia. In July, 1892, I had an attack of severe pain in the right ovarian region, attended with fever and complete prostration. Cause unknown. I gave it no attention, but attended to my business. Menstruation became less and less, till it stopped altogether for two years, during which time I felt perfectly well. I had a peculiar sensation on right side of abdomen just below waist line. I can scarcely describe it, but it reminded one somewhat of the first sensations of 'quickening.' This lasted several months while the tumor must have been forming. I had several of these attacks of pain of the character indicated. They were liable to come on any time without apparent cause. They were followed by intense soreness, a feeling like an attack of peritonitis. In the winter of 1896-97, after a long fifteen-mile drive to see a patient, I found I was flowing for the first time in over two years. I menstruated again after three months, and the flow now never stopped longer than for intervals of perhaps two or three days till my operation in September, 1897.

"Before the above-described trouble began I had always been well, never had hemorrhage, leucorrhœa, or any form of uterine trouble. I was examined in the spring of 1896, when a growth the size of a hen's egg was found, supposed then to involve the broad ligament. The growth did not appear to grow much till the following winter. Was examined by Dr. Henrotin in April, 1897, while attending a course at the Polyclinic. The doctor at this time told me the tumor was the size of his fist. He advised immediate operation. My husband would not consent.

"The tumor, having a pedicle, would swing down and across the rectum, causing me no little trouble all the summer. Bearing-down pains were followed by extreme tenderness. The enlargement of the right side appeared to increase. I became melancholy and unconcerned. No one, however, except my

husband, was aware that I had any trouble, and I attended to my practice up to the day I left for the operation."

Operation September 7, 1897, at the Policlinic Hospital. A median abdominal incision being made, there presented a tolerably soft, pediculated tumor of the right ovary. The new growth had not formed any adhesions to the surrounding parts. The pedicle was ligated without any difficulty and the growth removed.

The tumor as removed is of a grayish-white, somewhat pinkish color and fairly soft in consistence. It is almost spherical in shape and has a greatest periphery of 35 centimetres. It is surrounded by a perfectly smooth, shining, whitish, translucent capsule, through which are seen enlarged blood vessels. The new growth has entirely replaced the ovary, and no trace of normal ovarian tissue is visible. The place of attachment is marked by a triangular space over which the capsule is missing, so that the tumor tissue proper presents to view. Extending over the outer half of the upper margin is a part of the Fallopian tube. The part removed is 6 centimetres long, slightly tortuous in its course; the isthmus has a diameter varying from 0.7 to 1.4 centimetres. The fimbriated extremity is well developed and the ostium abdominale is open. Springing from the mesosalpinx about 2 centimetres to the inside of the outer margin of the ampulla, there is a stalked hydatid of Morgagni, about 1 centimetre in diameter, suspended from a short, constricted pedicle. The capsule of the tumor is intimately adherent.

Microscopic Examination.—The capsule investing the tumor consists of very densely packed, small, slender connective-tissue fibres. Epithelial cells as an external lining are not found. The tumor tissue proper consists of a stroma of spindle cells very similar in character to the normal ovarian stroma cells. Between these cells are found cells of medium size, round or cuboidal, with comparatively large nuclei rich in a finely granular chromatin. These tumor cells proper show a tendency to arrange themselves in alveolar masses or in tubular cords. In other places they are found infiltrating the stroma diffusely and irregularly. It is noticeable that the alveolar or tubular arrangement is never as sharply defined as in a carcinoma, but that the tumor cells, on the contrary, change their shape, approach the spindle type, and shade off gradually into the surrounding stroma. Favorable places

show that the tumor cells arise from proliferating lymphatic endothelia. The tumor is therefore to be classified as a lymphatic endothelioma. Follicles were not found in the tumor tissue; they appear to have completely perished in the new growth (Fig. 5).

In a letter dated September 19, 1899, the patient makes the following statement as to how she got along after the operation. She says: "I was a complete wreck for eighteen months after the operation and despaired of ever being myself again, but now am much better; have menstruated every three weeks since date of operation till this summer, now menstrual flow comes every twenty-eight days, very painful, pass shreds.

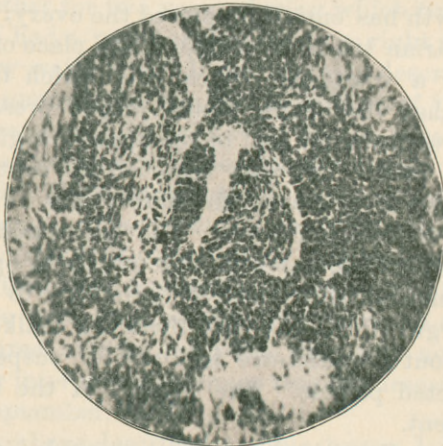

FIG. 5.—Endothelioma of the ovary. Section showing origin of tumor cells from lymphatic endothelium.

Of what? I cannot tell. I think I have several times felt that 'peculiar sensation' in my side; have had several attacks of bearing-down pain, followed by such tenderness that the least jar was painful." The patient's letter closes with a request to give a prognosis as to whether she has to expect any further trouble.

In answering this question it must be first stated that endotheliomata vary a good deal as to clinical type. And while they must in general be classified as malignant connective-tissue neoplasms, there are a good many cases on record of permanent cure after removal of these tumors. Besides, the sarcomatous neoplasms of the ovary—and to these the endotheliomata belong—are usually not as malignant as sarcomata in

most other parts of the body. Some statistics of permanent cure after removal of sarcoma of the ovary are quite favorable; for instance, those published a few years ago from the clinic of Czerny, who had over one-third permanent cures. In the case detailed above the chances of a permanent cure appear very good. There had not formed at the time of the operation any adhesions; the tumor was completely encapsulated, it had nowhere broken through. Tumors of the ovary of this type do not form early metastasis. At the time of the operation the chances for a permanent result appeared quite favorable. Since then over two years have elapsed. Mrs. X., while yet complaining about some menstrual disturbances, has for the last six or seven months been feeling fairly well. Signs of recurrence are not present. So the patient may be conscientiously assured that her chances for a permanent cure and non-recurrence of the growth are excellent.

III. CALCIFIED CORPUS LUTEUM.

Calcified corpora lutea of the ovary have but seldom been described. Such pathologic formations were either seen in the specimens obtained by an operation for other conditions, or in material collected from the postmortem table. These peculiar calcareous masses of the ovary were first mentioned by Morgagni, and other cases have been described by Rokitansky, Slavjanski, Sutton, Williams, Ries, Peterson, and Martin. The latter's "Diseases of the Ovaries and Tubes" is the only text book published which discusses the subject and gives a short review of the very scanty literature, which shows that the condition is very rare. It should be borne in mind, however, that diffuse calcareous deposits in the ovary in general are not so very rare, since we find them not infrequently as the consequence of inflammatory processes or of degenerative changes of tumors.

The case which we want to add to the very small list of reports of calcified corpora lutea presents the following features.¹

Mrs. W. R. was operated August 11, 1898, at the St. Joseph Hospital. On opening the abdomen by a median incision it was found that the uterus contained four tolerably large intramural fibroids. The left ovary formed a flat mass of fibrous, tough tissue, from the outer lower corner of which there

¹ Unfortunately the report of this interesting case is in some respects incomplete, since the history has been lost and could not be replaced.

sprang a calcareous tumor to which a loop of intestines was adherent by means of fibrous bands. The latter were carefully ligated off and then the uterus, fibroids, and appendages of both sides were removed, the peritoneum sutured over the stump of the uterus, and the operation finished. She recovered promptly.

The calcareous mass removed (Fig. 6) is as big as a good-sized walnut. It is almost spherical, and the surface presents elevations and depressions which look very much like coiled loops of small intestines or like the convolutions of a brain. The elevations are, however, much more prominent than the convolutions of a brain, and the depressions are proportionately deeper. The hard mass can be split by the aid of a strong car-

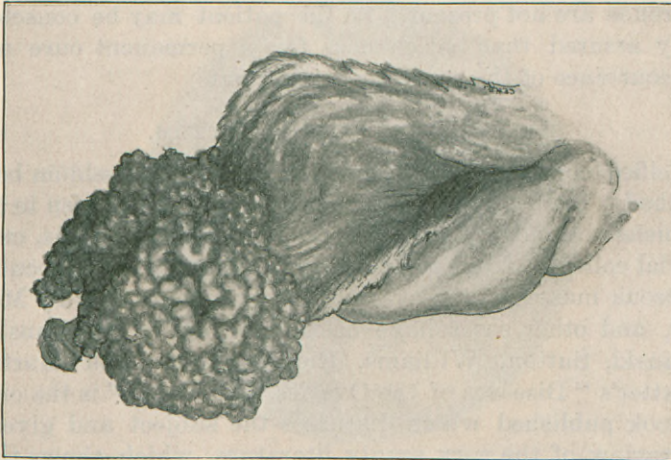


FIG. 6.—Calcified corpus luteum (natural size).

tilage knife and a hammer, and is found to be hollow. The cavity has a diameter of $1\frac{1}{2}$ centimetres, and the surrounding calcareous wall is over 5 millimetres thick. The inside of the cavity is lined by a thin, tough, and leathery membrane which is intimately adherent to the shell. The calcareous convolutions on the outside are likewise covered by a firmly adherent fibrous tissue. The soft tissue removed with the calcified mass is fibrous, tough, and completely flattened from before backward.

Microscopic Examination.—Pieces of the calcareous mass were decalcified, embedded, and then sectioned. It was found that the decalcification had not been complete, but some of the mineral matter had been left in the tissue. This occurrence,

while very hurtful to the cutting microtome knife, proved quite favorable in regard to orientation as to the zone of calcification (Fig. 7).

Microscopic examination shows that the peripheral parts of the sections (the zone representing the fibrous tissue covering the lime shell) consist of coarse hyaline fibres without nuclei. The inner zone (representing the inner membrane) is composed of the same elements. The middle zone, that appearing in black on the photomicrograph (black on account of the infiltrating, non-diaphanous lime salts), consists of finer fibres. They are not, like the outer and inner fibres, arranged in a con-

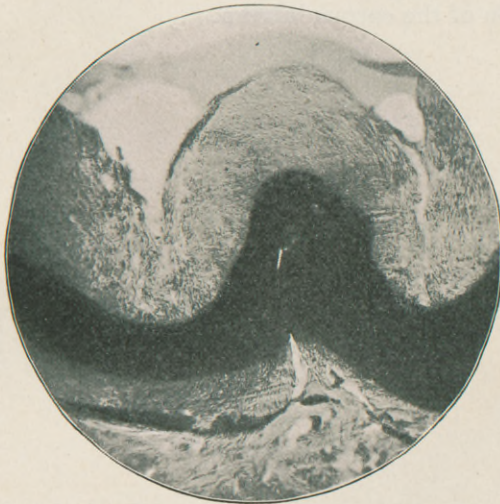


FIG. 7.—Section of calcified corpus luteum of the ovary. (Low magnification.) The zone of calcification is indicated by the deep shadow in the photomicrograph.

centric, but in a radial manner. These fibres form the stroma for roundish or square spaces densely infiltrated with lime salts. The square or roundish spaces so outlined are identical in size, and more or less in outlines, with the lutein cells. It appears, therefore, that the process of calcification is most marked or exclusively confined to the lutein cells of the yellow body.

The soft, non-calcified ovarian tissue consists of old hyaline connective tissue, containing vessels with thickened walls, some in a state of hyaline degeneration. There are also found a number of corpora albicantia and patches of areolar tissue (remnants of fatty degeneration?).

The whole picture clearly shows that we are dealing with the remnants of profound chronic inflammatory processes. That the latter, in our case, are most likely responsible for the calcification of either a corpus luteum or possibly a corpus luteum abscess, appears clear from the histologic findings as well as from the other known features of the case (adhesion of intestine to calcareous mass). Most of the few cases of corpus luteum calcareous masses which have been reported point to an inflammatory origin. The case of Martin and Orthmann, referred to above, that of a woman suffering from a bilateral sactosalpinx purulenta and a unilateral corpus luteum abscess, also unmistakably points to inflammation as the cause of the calcification of the corpus luteum.

