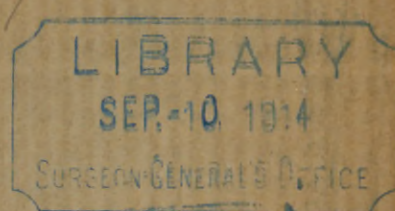


894

17



NOTES OF CASES

ILLUSTRATING SURGICAL LESIONS

OF THE

VASCULAR SYSTEM.

By RUDOLPH MATAS, M. D., NEW ORLEANS, LA.*

Reprint from the October, 1894, number of the New Orleans Medical and Surgical Journal.

NOTES OF CASES ILLUSTRATING SURGICAL LESIONS OF THE VASCULAR SYSTEM.

By RUDOLPH MATAS, M. D., NEW ORLEANS, LA.*

Reprint from the October, 1894, number of the New Orleans Medical and Surgical Journal.

OBSERVATION I.—A large spontaneous (atheromatous) aneurism of the right common carotid involving the bifurcation and trunk, to a point two inches above the origin of the artery, in an old alcoholic subject. Ligation of artery low in the neck between sternal and clavicular attachments of the sterno-mastoid, under cocain anesthesia. Recovery.

The patient was admitted in Ward 2, Charity Hospital, in April, 1888. He is a tall, thin, but muscular, negro. Blacksmith by occupation; age nearly eighty years. Peripheral arteries all markedly atheromatous; "pipe-stem" radials; arcus senilis. Addicted all his life to alcoholic indulgence. The general bad condition of the arterial system, together with the age and the habits of the patient, decided that I should operate under cocaine anæsthesia.

As the neck was long and thin and the interspace between the sternal and clavicular heads of the sterno-mastoid quite large and favorable, this space was selected for the application of the ligature (Sedillot's method). No difficulty was experienced in creating a cocain atmosphere over the line of

*Proceedings Louisiana State Medical Society, May, 1894.

the artery with a 3 per cent. aq. sol. of cocaine hydrochlorate. The artery was exposed and ligated without difficulty as low in the neck as possible to avoid the neighborhood of the aneurismal region. The innominate bifurcated high in the neck and the bifurcation was recognized. An aseptic silk ligature was used and the wound closed without drainage. The wound healed without complications, *per primam*. Patient never complained of pain either during or after the operation. When the patient left the ward, twenty days after the operation, the aneurism had become quite hard and was much smaller.

OBSERVATION 2.—*Arterial varix* (cirroid aneurism) of the right common carotid extending from origin to a point one inch from bifurcation. Double ligature of the common carotid; one below bifurcation of the carotid and one over the dilated trunk itself. Recovery with aseptic healing of wound and apparent improvement in aneurismal condition.

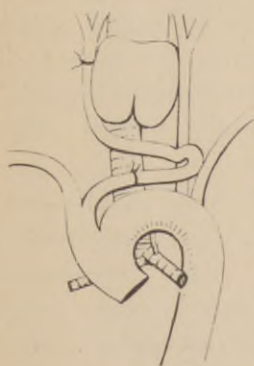

Diagram illustrating a cirroid aneurism of right common carotid, and points of ligation. (Dr. Matas' collection.)

The patient, James C., of Baton Rouge, La., negro laborer, aged sixty years. Was admitted to Ward 2, 1890. No hereditary history; no distinct history of syphilis. Some alcoholism. On January 1, 1890, noticed a small tumor pulsating near root of neck immediately above sternal notch. It gradually increased in size, and last June cough, dysphagia and dysphonia annoyed him to an extent that decided him to go to the hospital for assistance. He was treated in one of the medical wards one month for thoracic aneurism before he was transferred to the surgical service.

On examination patient appeared to enjoy a good general health. He is moderately stout, muscular, with a short, broad neck, covered with thin skin and little fat. Examination readily reveals a distinct tubular swelling starting under right sterno-clavicular articulation and sternal origin of right sterno-

mastoid muscles; the swelling fills up the supra-sternal fossa and extends over trachea to anterior border of left sterno-mastoid muscle in an obliquely upward direction, from right to left, reaching apparently the lower level of the left lobe of thyroid. A characteristic, expansile pulsation, thrill, and loud, systolic *bruit* confirm the aneurismal nature of the tumor. The abnormal vessel lies under the sterno-hyoid and sterno-thyroid muscles and it is difficult to determine its precise outline, but the direction would suggest that the tumor originates in the anterior mediastium and escapes upward into the neck as high as the lower thyroid level until it reaches the anterior border of sterno-mastoid overlapping the *left* carotid sheath. The left carotid is felt pulsating on a level with the upper border of thyroid, apparently perfectly normal at bifurcation. The right carotid pulsates more vigorously and is clearly recognized at level of normal bifurcation, though apparently closer to the median line and hugging the thyroid.

The exact condition is difficult to determine. At first examination concluded that it affected the arch of the aorta, which was congenitally displaced upward, but further examination discouraged this idea because the contour of the tumor could be made out, above the sternum, on the left side. I decided finally that it would be better to perform an exploratory operation, and to expose the aneurismal vessel if possible, believing that owing to the absence of inflammatory adhesion, in the peri-vascular territory and the laxity and apparent soundness of the overlying tissues it would be possible, by careful manipulation, to determine the true condition and relations of the involved parts.

Accordingly, on August 6, after very careful antiseptic preparation and with the valuable assistance of Dr. Michinard and other members of the staff, a free incision was made from the cricoid to the anterior sternal region. After dividing the fascia and carefully separating the muscles in the median line, I exposed a large tortuous trunk which evidently originated deeply in the chest, apparently at the point of bifurcation of the innominate under the right sterno-clavicular articulation and ascended obliquely upward until it touched the left carotid sheath under the edge of the left sterno-mastoid muscle.

There the large dilated vessel became suddenly contracted, and forming a curve folded on itself and returned over the trachea, following the contour of the thyroid and returned to the right carotid region, where it terminated in an apparently normal common carotid that bifurcated at the usual level. The vessel in its first portion had the caliber of a large innominate trunk; its coats were very thick, and the impression conveyed was that it was a large artery that had undergone a uniform dilation with some thickening of its coats, but without any saciform or fusiform dilation. The diagnosis was, therefore, *arterial varix* or *cirsoid aneurism* of the common carotid.

This condition was so peculiar and novel to us that we hesitated for a moment, but concluded that it would be safe to apply a distal ligature to the common carotid on the Brasdor principle, just below the bifurcation. This was done without difficulty and a sterilized silk ligature was used. As the coats of the dilated artery over the trachea were thick but soft and apparently free from calcareous deposit, we decided to risk the application of another ligature over the middle of the varix itself. This was not done until an attempt had been made to trace the varix to its origin at the root of the neck. The fear of injuring the left innominate vein, which was separated with difficulty from the arterial trunk, compelled me to desist from satisfying myself as to the exact origin of the dilated trunk, but it appeared to me from its length and depth that it must have arisen from the arch of the aorta itself or from a very short innominate trunk.

As stated previously, the condition of the abnormal artery was such that I felt justified in applying a ligature over the middle of the dilated portion, using a double heavy aseptic catgut ligature and employing just sufficient force to merely approximate and keep in contact the arterial coats. No attempt was made to lacerate the intima, only simple approximation of the arterial surfaces was aimed at. The object of this second ligature was to produce sufficient irritation at the point of ligature to excite adhesive inflammation, and in conjunction with the distal ligature, below the bifurcation of the carotid, to obliterate the vessel. A marked diminution in the size of the ves-

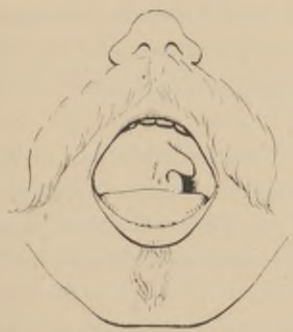sel and the *almost* complete cessation of pulsation beyond it, attested its obstructive action.

Dr. S. M. Fortier (one of the present Assistant House Surgeons, Charity Hospital), then interne of the service, writes in his notes: "Dressing, August 8 and 10; sutures removed, union having taken place by first intention. A pulsation still exists (over supra-sternal fossa), but not as vigorously as before. As the patient imagined himself cured he persisted in leaving, feeling very much improved."

I received a letter from him one month after, stating that he was doing well and felt himself cured, as all his previous symptoms had been relieved. I have not heard from him since, and it has been impossible for me to ascertain his whereabouts.

There may have been some temporary arrest in the progress of the disease, but it is not at all probable that a permanent cure has been effected, as the first or proximal portion of the artery was too long and pulsating too actively to warrant the belief that it would undergo any retrogressive change.

OBSERVATION 3.—Suspected aneurism of the right internal carotid, possibly of traumatic origin, projecting into the fauces and threatening life by suffocation, etc. Ligature of common carotid at point of election. Recovery.



Supposed Aneurism of the internal carotid bulging into fauces. Showing displacement of palate and encroachment of tumor into pharyngeal isthmus. (Dr. Matas' Collection.)

H. B., Englishman, hostler, aged 35 years. Came to Eye, Ear, Nose and Throat Hospital of this city, complaining of a difficulty in swallowing and inability to speak and even breathe properly on account of a large tumor which nearly filled his throat.

He stated that about six years ago, while working in Ontario, Canada, he was taken ill with an acute inflammation of the throat, accompanied with swelling and huskiness of voice, which his medical attendant thought necessary to "lance," but without apparent result. From that time he no-

ticed that the swelling in his throat had continued and gradually increased to present size.

On examination, externally, it is noticed that an irregular ovoidal tumor fills the submaxillary and parotid regions. The tumor appears, on careful palpation, to be indented by the digastric muscle, which gives it a bi-lobar contour. The submaxillary portion of the tumor projects about $1\frac{1}{2}$ inches from the angle of the jaw. It extends from the tragus to the hyoid bone; from the angle of the jaw to the mastoid. The tumor feels very hard, but pulsates vigorously; and, if it is aneurismal, must contain a great deal of hard, active clot in its outer walls.

Intra-buccal examination.—A large bulging mass projects into the fauces almost filling the whole isthmus. It springs from a broad base of attachment in the right tonsillar region. Intra-buccal palpation confirms the marked pulsation of the whole mass; but the peculiar, tense, expansile feel of a typical aneurism is wanting. The mass feels unusually hard for an aneurism. There is only a very narrow passage left for food and drink and the patient is compelled to subsist on semi-solid or liquid food. Uvula and palate displaced, to left; below, the mass extends to the epiglottis and hyoid. Compression of the common carotid at point of election causes complete arrest of all pulsation and *some* diminution in size of tumor.

The patient is seen by Drs. Logan and Souchon, consulting surgeons of the hospital, who pronounce the case one of aneurism of the internal carotid of traumatic origin and advise the ligature of the common carotid.

I must confess to having entertained some doubts as to the aneurismal character of the swelling in spite of the history, and especially after one year's observation of the case subsequent to the ligature of the artery; but the ligation was clearly indicated, if only as a denutrient factor.

With the valuable assistance of Dr. de Roaldes and staff of the Eye, Ear, Nose and Throat Hospital, the common carotid was exposed and ligated at the point of election. The tumor was immediately reduced in size, but not as much as was anticipated. The wound healed aseptically, and the patient left the hospital apparently much improved,

as the reduction of the intra-pharyngeal portion had facilitated speech and deglutition. The effect on the size of the tumor was disappointing, however, as, even now, after two two years' observation, I find that the tumor remains, only smaller in size, though it does not pulsate nor appear to grow. I am therefore inclined to believe that this is really a case of tonsillar fibro-adenoma, which has been reduced and kept dwarfed through arterial fasting.

OBSERVATION 4.—Enormous traumatic aneurism of the common femoral, simulating an aneurism of the external iliac. Sac filled the thigh and the whole iliac fossa, pushing up the external iliac and femoral, almost causing spontaneous cure through upward pressure of the overlying iliac artery. Laparotomy; ligation of the external iliac midway between Poupart's ligament and origin; aseptic healing. Death from anemia and exhaustion one week after operation. Autopsy reveals a cavity containing fully one gallon of clot.

This patient, a young mulatto, aged 23, was admitted in Ward 2, June, 1892, presenting an exceedingly wasted and anemic appearance. He had a tumor which filled the right iliac fossa, the inguinal and upper femoral and obturator regions. The swelling was semi-elastic, tense, full, covered by a glazed skin; there was no sense of fluctuation except at inner half of base of Scarpa's triangle, where a soft spot existed, in which a slight thrill and murmur could be perceived. The first impression caused by the appearance of this tumor was that of a tubercular abscess. But the history of traumatism (a gunshot injury sustained several months before), carefully elicited by Mr. Brady (Dr. C. Milo Brady, of Gretna), interne of the service, convinced us that we were dealing with a large traumatic aneurism. The solid, elastic feel indicated that the sac had filled with a large mass of clot and that the circulation within it was quite sluggish.

The exact point of communication of the sac with the artery of supply could not be ascertained, but owing to the extension of the tumor above Poupart's ligament we concluded that the common femoral was injured on a level with the ligament

and that a higher exposure of the iliac artery or even of the common iliac would be required to apply a safe ligature. Accordingly, after careful preparation of the patient, median laparotomy was performed and the artery was exposed. It was noticed then that the tumor which filled the entire iliac fossa extended deeply down into the pelvis in the direction of the obturator foramen. An aseptic silk ligature was applied without difficulty at the point of election midway between Poupart's ligament and the bifurcation of the common iliac. The artery was flattened against the tumor, but pulsated vigorously down to Poupart's ligament, where it was lost in the tumor. The Tredelenburg posture permitted of a ready exposure of the affected area and exhibited the pelvic relations of the aneurism.

The patient rallied slowly from the anesthetic, ether. No marked difference in the size of the tumor was observed, but the purring thrill and murmur over Scarpa's triangle disappeared. The patient was not seriously affected by the operation. There never was a sign of peritonitis, but hiccough set in; the abdomen retracted more and more every day, the pulse gradually grew weaker and finally the patient succumbed on the seventh day, apparently from exhaustion.

REPORT OF AUTOPSY.

Subject injected about twelve hours after death with chloride of zinc and glycerine, followed by plaster of Paris. The injection was made through the abdominal and thoracic aorta (this was on Thursday, 14th).

Autopsy on Sunday, 17th. The subject remarkably emaciated. Abdominal wall retracted, presenting a wound in the linea alba about $4\frac{1}{2}$ inches in length, extending from a point about $1\frac{1}{2}$ inches above the pubes to a point just a little above the umbilicus. This incision had to be torn apart, and its edges throughout the entire thickness, including the peritoneum, show evidences of recent plastic exudation as if primary union had taken place along the whole extent of the wound. Inspection of the peritoneal cavity revealed a total absence of adhesion or exudation in the peritoneal cavity.

There were no evidences of vascular injection anywhere. The intestines were collapsed and empty, and everything pointed to a perfectly normal condition of its cavity and total absence of peritonitis. After enlarging the wound and cutting down to Poupart's ligament a perfect view was obtained of the whole extent of the common iliac and external iliac arteries from the bifurcation of the abdominal aorta to Poupart's ligament. It was then seen that about $2\frac{1}{2}$ inches above Poupart's ligament the external iliac artery had been ligated and that the ligature (silk) was imbedded in a mass of exudation, which covered also a slight perforation in the peritoneum through which the ligature had been applied. The artery above the ligature was distended with plaster, while below it, all the way down to the sac, the vessel was empty and collapsed.

By continuing the abdominal incision into the thigh down to a point about eight inches below Poupart's ligament, a complete view of a large semi-fluctuating tumor was obtained. This tumor filled up the whole of the right iliac fossa up to the iliac crest posteriorly and bulged into the pelvis below the iliac vessels. It was apparently constricted at Poupart's ligament and then appeared to fill up the whole of the thigh down to about the level of Hunter's canal. At a point midway between the anterior superior spine of the ilium and the spine of the pubes the fascia lata which covered the tumor appeared to be very thin and threatened to burst. By carefully exposing the artery from the point of ligation down to Poupart's ligament, it was easily seen that it had not been injured in any way until Poupart's ligament was reached, when it was found to have become very adherent to the surrounding fascia and that it communicated with the tumor directly by an opening which nearly measured one inch in its longest diameter. Below this point the artery was easily separated from the surrounding parts and was traced down about four inches below Poupart's ligament where the profunda was given off. Upon laying open the artery it was found filled with a thin thrombus from the point of ligation to the opening which led to the aneurismal pouch.

The sac was now laid open by a free incision and enormous quantities of clot were removed, which measured at least a gallon. The clots were of the passive, grumous variety, indicat-

ing recent coagulation, while masses of adherent active clot were found attached to the distal walls of the sac and especially to the parts neighboring the foramen, which communicated with the artery. After washing out the aneurismal cavity it was found that the anterior walls were formed entirely of very thin atrophied cutaneo-musculo-peritoneal layers, and the posterior walls were formed mainly by the denuded skeleton of the iliac fossa and thigh. The ilio-psoas muscle had been entirely disintegrated and absorbed, leaving the venter ilii entirely exposed. A rudimentary tendon attached to the lesser trochanter of the femur, which was exposed in the cavity, was the only vestige of the psoas-iliacus. The femur down to about three inches below its surgical neck was entirely exposed and only covered by periosteum. All the anterior femoral and the adductor group of muscles had been amalgamated with the fascia lata and were reduced to an exceedingly thin musculo-membranous sheet, which included the femoral sheath, the vein, artery and nerve. It was found that the capsule of the hip joint had been entirely eroded in its anterior portion, exposing the head of the femur in the acetabulum. The femoral vein was found uninjured.

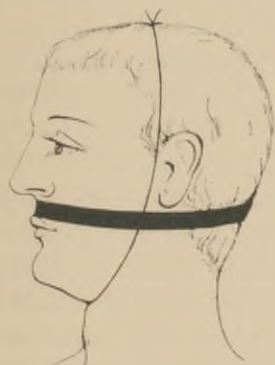Further examination of the lower extremity shows that the injection did not reach these parts, while on the opposite side the soft parts were saturated with the preservative fluid.

The position of the limb was that of complete abduction and outward rotation.

CONCLUSIONS.—1st. There was no peritonitis. 2d. The abdominal wound was healing by primary union. The ligature which was placed on the external iliac between Poupart's ligament and the bifurcation of the common iliac was being rapidly encysted. 3d. The cause of death appears to have been exhaustion and anemia, due to the enormous internal drain upon the vascular system by this vast aneurismal cavity, which contained fully a gallon of coagulated blood. 4th. Coagulation of the contents appeared to have been almost completed before death. 5th. The aneurism was evidently caused by a gunshot injury involving the artery about the level of Poupart's ligament.

OBSERVATION 5.—Contusion of the upper lip in an infant 9 months old. Laceration of the *frænulum labii*; hemophilia, bleeding. Failure of hemostatics and suture. Arrest of hemorrhage by direct elastic compression.

In August, 1894, I was called to attend a little Italian baby, aged 9 months, nursing at the breast. It accidentally fell on its face and contused the upper lip and lacerated the mucous membrane at the gingivo-labial commissure, corresponding to the bridle of the upper lip. Little importance had been attached to the accident at the time, but the continuous bleeding which took place from the laceration in the lip decided the parents to call the family physician, who upon examination regarded the injury as trivial in view of the small extent of the laceration, which did not exceed one-quarter of an inch and was very superficial. Washes with



Obs. 5.—Diagram illustrating application of elastic compression of upper lip for arrest of hæmorrhage in hæmophilic subject. (Dr. Matas' Collection.)

arnica tincture were ordered, but as these failed the tincture of chloride of iron was applied. This only served to blacken the mouth, but had no effect in arresting the steady, continuous oozing that constantly filled the mouth with blood, especially when the baby took the breast. The child had bled in this manner about four days, and was exceedingly weak and pale. At this stage I was called, and recognized that the condition was of the utmost gravity in view of the feebleness of the little patient and the extreme anemia, which caused almost cadaveric pallor. It was evident that so trifling an injury could not have caused this rebellious bleeding without the aid of some constitutional condition which interfered with coagulation and physiological hemostasis. It was also plain that the suction movement of the lip, while nursing, greatly favored the tendency to bleed. The first indication was to stop nursing and to substitute the spoon for the breast or the bottle; then the wound itself was closed by a single suture with a small round milliner's needle and fine

thread; the tissues were grasped deeply and for the moment the hemostasis was complete. The next morning I was again notified that bleeding had returned and that the child was growing weaker. I called, and noticed that some slight but continuous oozing still came from the wound, so that I again applied two more deep sutures with a view of compressing all the tissues at a distance from the trauma. The sutures now completely concealed the little laceration. This for the moment seemed to accomplish the desired result until the next day, when I was again summoned, with the explanation that there was *still* some oozing from the wound. I could scarcely believe this statement, as the wound had been practically buried by the sutures, but upon careful examination I discovered that the oozing came *from the points of suture*. This discovery was certainly discouraging, but after thinking of the situation for some time it occurred to me that simple elastic compression applied externally to the lip would be effectual in arresting the flow. I therefore applied an elastic band, such as is sold by all stationers for holding papers together, and which I happened to have at the moment around my pocketbook, and secured this snugly over the lip and occiput, after protecting these parts with pads of gauze. The elastic was prevented from slipping upward or downward by the attachments shown in the accompanying figure. The band exercised just the pressure that was required and effectually stopped the bleeding. It was worn continuously during three days after confirming the permanent arrest of all bleeding. Feeding was not interfered with by this simple hemostatic contrivance, and the child soon recovered from the extreme weakness and anemia that threatened its life.

There were several petechial and ecchymotic spots over the chest and limbs which indicated a purpuric condition, but these have since disappeared and the child is now apparently in the best of health.

This is instructive, in so much that it illustrates the great danger attending even the most trivial injuries in hemophilic subjects and suggests a method of relief which may be of service to those who may be confronted by a similar perplexing and troublesome experience.

OBSERVATION 6.—Prophylactic ligation of the external carotid artery as a preliminary to the resection of the second and third divisions of the trigeminus for tic douloureux on a level with the basal foramina, viz.: f. rotundum and ovale, by Mixer's modification of Salzer's operation. Unexpected death forty hours after, notwithstanding apparent complete recovery from operation, with symptoms of sudden respiratory and cardiac failure, due possibly to the formation of cardiac or medullary thrombus.

The patient, a white male, type-setter, æt. 36, had suffered for eight years prior to operation with a progressively aggravated neuralgia of the trigeminus, for which all classical remedies, including galvanism and large doses of morphia hypodermically administered, had absolutely no effect. The superficial as well as deep branches of the superior and inferior maxillary divisions were involved, the gustatory branch being the seat of the most intolerable pain. As the patient's general condition was otherwise excellent, I decided to resort to the modification of Salzer's operation described and successfully practised by Mixer, of Boston (*vide* Boston Medical and Surgical Journal for August 13, 1894).

The operation was performed January, 1893, with the valuable assistance of my friends Drs. F. W. Parham, L. F. Reynaud, and other gentlemen of the Charity Hospital staff.

To protect the patient against the dangers of excessive bleeding from the temporal, meningeal and terminal branches in the speno-palatine fossa of the maxillary artery, I began by a preliminary ligation of the external carotid at the point of election. The ligature was applied without notable difficulty.

A temporal flap consisting of all the soft parts down to the bone was raised from the skull; the zygomatic arch divided with a saw and the pterygoids lifted with a periostotome from the zygomatic and speno-palatine fossæ. The superior maxillary trunk was divided in the speno-palatine fossa on a level with the foramen rotundum, and after clearing the fossa with a blunt curette and insuring the destruction of Meckel's ganglion, the terminal portion of the nerve was exposed in the infra-orbital foramen and the whole nerve extracted entire from

the infra-orbital canal. The terminal, nasal, labial and palpebral filaments were also dissected and removed.

After exposing the external pterygoid plate the inferior maxillary trunk was recognized in the space between the spinous process and posterior border of the pterygoid; fully one inch of the inferior maxillary was resected from the level of the foramen downward. There was no arterial bleeding, the venous flow from the pterygoid plexus was considerable, but was finally completely controlled by an iodoform gauze pack, which was left in the pterygoid fossa. The zygomatic arch was restored by drilling through the malar bone and zygoma and wiring with silver. The control of the venous hemorrhage consumed considerable time and the patient was kept under chloroform for fully two hours. Nevertheless, the general condition was excellent and never gave a moment's concern. The patient recovered perfectly from the anesthetic and examination of the tongue and face corresponding to the affected regions demonstrated an absolute anesthesia, showing that the section of the superior and inferior maxillary nerves had been complete.

The patient's mind was perfectly lucid after the operation; nothing peculiar was observed in the pulse, which fell to 110 after the patient was removed to his bed and the respirations were normal.

All went along smoothly until the second night after the operation, when the patient complained of weakness and pain deep in the neck on a level with the carotid ligature. The pulse at the same time rose rapidly in frequency, running up to 140, 150, and soon became so rapid and compressible that it could not be counted. The respirations, on the other hand, progressively diminished in frequency and finally were so retarded that no voluntary breathing could be observed except when artificial stimulation and respiration were resorted to.

The pupils were contracted. The mental state simulated somnolence and stupor, but the patient could be roused and gave intelligent but monosyllabic answers when repeatedly and loudly questioned.

A quarter of a grain of morphia had been given hypoder-

matically early in the evening when the patient had first complained of pain in the neck, and as the condition imitated opium narcosis completely he was treated on an antidotal basis, with repeated injections of atropia, caffeine, strychnia, ammonia and digitalis, which were administered with a liberal hand by Dr. Parham and myself. But all this seemed to be of no avail and the patient gradually sank into total unconsciousness, coma, and death about eight hours after the initial disturbance began. The temperature, which had been 99° in the evening, gradually became sub-normal. The wound looked healthy; slight oozing had occurred through the drainage tube; there was no hæmorrhage, but the iodoform pack which had been left in the pterygoid fossa was removed shortly after the pain and cardio-respiratory disturbance began, for fear that the bad symptoms were due to excessive pressure upon the pneumogastric.

There was no paralytic symptoms. The urine, which had been carefully examined before and after the operation, showed no trace of sugar or albumen.

What was the cause of death in this case? It was surely not opium narcosis, because the patient had taken large doses of morphia prior to the operation, one and two grains hypodermically, without any untoward effect. Yet the symptoms were nearer those of opium poisoning than those of any other condition. An injury to the pneumogastric during the operation would have caused a disturbance in the respiration and circulation at the time of the injury and would not have waited nearly a day to manifest itself. I can not account for this unfortunate complication and termination in a manner satisfactory to myself. It has occurred to me that a small embolus which would have lodged in a branch of the vertebral controlling the circulation of the fourth ventricle and the pneumogastric nuclei would have accounted for this condition; but this is not at all probable, as there were no paralytic or other nervous manifestations than those mentioned.

The cause of death in this case will ever remain a mystery, as no autopsy was held.

OBSERVATION 7.—Secondary diffuse lympho-sarcoma of the axilla involving the axillary vein in the middle and lower thirds recurring nearly one year after amputation of the breast for primary growth. Resection of the diseased axillary vein and prophylactic ligature of the axillary artery below the subscapular to prevent venous choking of the limb. Uneventful recovery from operation, but recurrence of disease almost immediately after cicatrization. Enormous lymphatic edema and neuralgia from pressure, four months after last operation. Death.

Mrs. H. A., æt. 38, white, apparently in perfect health apart from the existence of a painless tumor which involves the right mamma and is slightly adherent to its upper and outer quadrant. No glands in axilla can be felt. Tumor discovered three months previously, when it was detected as a small nodule in the breast. Growth has been rapid during the last month. In November, 1891, the breast and axillary contents were removed by Gross' method. No diseased gland could be detected in the axillary fat. Microscopical examination revealed the tumor to be round-celled sarcoma. The wound healed *per primam*, and outside of a slight impediment in raising the arm the recovery of the patient was complete. Nearly twelve months after, a slight edema of the hand made its appearance. Neuralgic pain in the arm became annoying. A characteristic infiltration in the axilla, along the outer boundary and over the vascular sheath, easily accounted for the symptoms and announced the recurrence of the growth.

A secondary operation was decided upon and the axilla was freely exposed. A large nodular, diffusely infiltrated mass was discovered surrounding the axillary sheath. Much difficulty was experienced in making the dissection, as the vein—a short large trunk—had been partially incorporated in the growth. In order to gain free access to the diseased mass the pectoralis major was divided, and, finally, after much patient work the artery and nerves were isolated. The vein was ligated above and below the diseased portions and resected with part of the adherent mass attached. Adopting a precaution (Braun, Pilcher, Souchon) which I now believe to be unnecessary in dealing with wounds of the large venous trunks

of the neck and upper extremity, I ligated the axillary artery below the sub-scapular to prevent venous choking of the limb. The hand and arm were cold for a few days, but no notable circulatory phenomena followed this operation. The axillary wound healed partially by first intention and by granulation. The rapidity with which the axillary gap was closed was extraordinary and was only accounted for by the unusually vigorous physique of the patient. Cicatrization had barely taken place, however, when the scar became hard, brawny and manifestly diseased. The movements of the arm were seriously crippled, and in two weeks after convalescence lymphatic edema of the arm and of the whole extremity soon gave it an elephantine appearance. Neuralgic pains, which followed the course of the median and musculo-spiral branches, added greatly to the distress of the patient. The scar assumed a fungous appearance; emaciation and cachexia supervened and multiple nodules of malignant infiltration appeared on the chest and neck.

Morphia in enormous doses was the only agent that momentarily relieved the patient, who continued to live through this constantly increasing torture until nearly four months after the second operation, when death closed a scene that I have never seen paralleled by its horrors as well as by the heroic fortitude of the patient in all my surgical experience.

I have selected this unfortunate case from a list of thirteen cases of malignant diseases of the breast which have been treated by modern operative methods simply to call the attention of the members of this society to the propriety of advising disarticulation at the shoulder in this especially unfortunate class of patients who, being still young, vigorous and robust, are prepared to offer a long resistance when attacked by axillary growths which involve the vascular sheath and nerve plexus and in whom lymphatic edema and neuralgia are sure to follow attempts at radical extirpation.

These cases are practically incurable, but they are often operable, and there is no doubt in my mind that a more satisfactory effort at radical extirpation can be attempted if the useless preservation of a worthless limb is left out of consideration. If disarticulation is performed, as advocated by Watson

Cheyne, not only will the operation be more thorough and the chances of recurrence diminished, but the patient will be relieved of an enormous burden. The lymphatic edema in these cases is progressive. The arm assumes gigantic proportions; it is rigid and absolutely immovable; even the fingers become so swollen that they are inflexible. As the arm swells it becomes flexed and its weight upon the abdomen or chest interferes with rest in any position. The sitting or recumbent postures are nevertheless the only positions that the poor sufferer can tolerate, because the weight of the huge swollen limb drags and chains the patient down, like an anchor, to his bed. The neuralgia of the arm is also a terrible cause of suffering and compels the use of morphia in excessive doses. By resorting to disarticulation at the shoulder early, recurrence will not necessarily be prevented, but life will be prolonged without the martyrdom that otherwise characterizes these terrible cases.

OBSERVATION 8.—Large cavernous angioma of nevoid origin, involving palm of hand; the whole thenar region, entire thumb, index and part of medius, involved in the tumor. Attempt at conservatism by resection of diseased soft parts, leaving a purely tegumentary flap. Ligation of radial artery in first inter-space with other digital branches. Sloughing of all diseased area, with great and nearly fatal shock; secondary amputation of all but the fourth and fifth fingers and metacarpals. The remnants of the medius utilized to fill the gap caused by the loss of the index and its metacarpal.

In July, 1892, a little mulatto boy, F. V., æt. 6 years, was brought to me for the relief of a swelling which had developed shortly after birth in his right hand. The child was born with a spot in the hand like a "mother's mark," which at first attracted little attention, as it was insignificant in size and appearance. Gradually as the baby developed, the spot enlarged and became thicker. As the functions of the hands were brought into greater play by the increasing activity of the child, the palmar spot began to swell, and finally a distinct, prominent deformity of the hand aroused the anxiety of

the parents, who sought the advice of a physician. The doctor recognized the nevoid character of the growth and advised that the child be at once subjected to surgical treatment. Nothing was done, however, until several months after, when the boy was brought to me for treatment. When first seen by me the little patient appeared to be a healthy, vigorous child, possibly a little pale and underweight for his size, but yet showing no abnormality outside of the deformity of the hand, which at once commanded attention. As shown by the accompanying illustration, the whole thenar eminence, including the thumb and part of the proximal portion of the index, was abnormally blue in color, and swollen. The swelling was equally visible on the dorsal surface over the metacarpal bone of the thumb to the styloid process of the radius, and as far as the middle metacarpal. If the hand was allowed to hang down the swelling markedly increased; if elevated above the head the tumor diminished, so that the hand had an almost normal appearance. If an elastic string was applied above the wrist, as is shown in Fig. 2, the swelling remained and appeared to be more turgid than ever.

Upon careful palpation the vascular and erectile nature of the tumor was easily determined. By systematic pressure, the tumor could be easily emptied of its fluid contents. The metacarpal bone of the thumb could be easily outlined in the centre of the swelling and appeared to be entirely denuded of all the soft parts, as if the palmar muscles had been entirely atrophied by the growth. It felt like a skeleton finger in a rubber bag. The second metacarpal gave much the same sensation to palpation. There was no distinct pulsation, but the affected area felt unusually warm. The skin covering the parts was very thin, and when the elastic band was applied so as to interfere with the venous circulation the tension was so great over the thenar eminence that it appeared as if the skin would burst. It was plainly a case of *angioma cavernosum* with a preponderance of venous ectasis. What to do in the way of treatment was a question which could not be answered easily. Amputation of the hand or a part of it appeared to be the easiest and safest way out of the difficulty. Injections of carbolic acid or other irritating coagulants appeared dangerous from both the

standpoints of embolism and sloughing. Electrolysis has been exceedingly unsatisfactory in my experience and was especially difficult of application, because of the long duration of the treatment and the restlessness of an active child under restraint.

I concluded that I would carefully lay open the diseased area and dissect away as much of the erectile tissue as possible after ligating all visible vessels of supply. Chloroform was administered and the Esmarch bandage was applied. An immediate collapse of the erectile tissues followed, and the hand assumed a perfectly natural appearance. An incision was now made from the base of the first phalanx of the thumb to the middle of the palm, which completely bisected the thenar eminence and exposed the interior of the most prominent part of the tumor. It was now easily ascertained that the flexor muscles of the thenar eminence had entirely disappeared and that a loose cribriform connective tissue—evidently erectile—had taken their place. The bone was only covered by this tissue and periosteum. Another incision was now made on the dorsal surface of the hand which extended from the second phalanx of the index, along the line of the second metacarpal up to the styloid process of the radius. This was connected with the thenar incision by another incision over the edge of the first interdigital web, thus leaving a flap attached to the extensor surface of the thumb. The first interosseous muscle was brought to view, but it had evidently participated in the abnormal process, as it was riddled with vascular cavities through its whole extent. The second interosseous was likewise affected. The skin itself appeared to be essentially diseased. This was very discouraging but had been expected, and an attempt was now made to excise as much of the diseased muscle and erectile tissue as possible. The whole area of the skin was trimmed, and made so thin by constant shaving on its under surface that it resembled a large Thiersch graft consisting only of epidermis; the first interosseous muscle was excised *in toto*, and the vascular mass which represented the thenar group of muscles was likewise excised with scissors and knife.

While clearing the field in this way the radial artery was purposely exposed as it enters the palm in the first interosseous space. After securing this vessel we decided to relax the con-

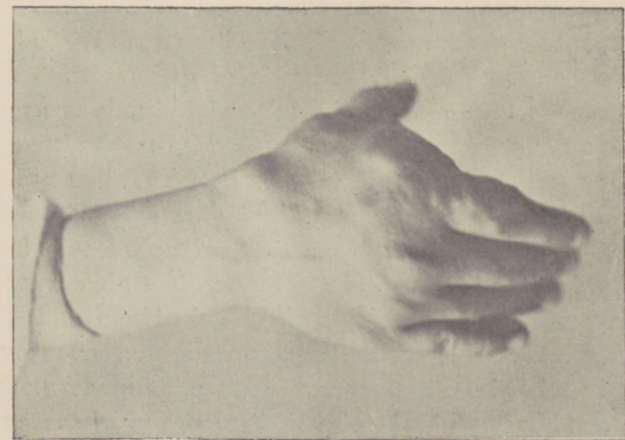

FIG 1. Dorsal Aspect.

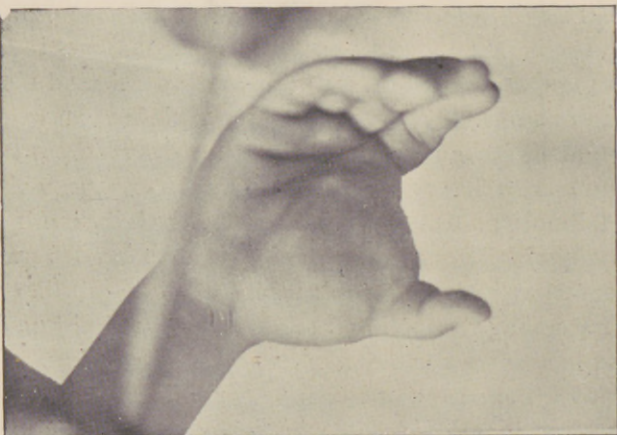

FIG. 2. Palmar Aspect

OBSERVATION 8.—Cavernous Angioma of the Hand. (Dr. Matas' collection.)

strictor and observe the restoration of the circulation in the parts. We were prepared for a change, but the spectacle offered by the sudden exhibition of the extraordinary vascularity of the tissues was astonishing. The skin, which appeared to be thinned to a mere epidermal parchment, was now swollen, angry, turgid, and blue as if nothing had been done to it. The whole wound swelled up and it was almost impossible to understand the enormous capacity for distention that was exhibited by the merest shred of connective tissue. With all this, however, there was no spurting of arterial blood; there was simply a general and copious oozing, which came from every quarter and flooded the whole field of the operation. All attempt at further extirpation was given up and our efforts were simply directed to hemostasis, which fortunately was readily secured by returning the dissected flaps to their places and compressing the whole thenar region with packs of iodoform gauze, cotton, and firm bandaging over a splint that extended to the elbow. The child recovered perfectly from the anesthetic (chloroform) and was removed to his home from the hospital that evening.

Early the next morning, I was summoned by the parents to see the boy. There had been no hemorrhage, but I was told that a severe and long chill had come on during the night, and that very high fever accompanied by intense pain in the hand had followed. When I saw the child it was unconscious and in convulsions. The temperature had risen to $105\frac{1}{2}^{\circ}$ F., and the pulse was so rapid that it could not be counted. It was evident that serious mischief had been caused, but I could not believe that it was due to septic infection. The hand was hurriedly unbandaged and I discovered that the whole diseased area was cold, dark and completely anesthetic. This meant sloughing. The hand was bathed in very hot water and a loose dressing, consisting of lintine saturated in a weak carbolized solution, and loosely bandaged, was kept constantly applied. An ice bag to the head, general sponging of the body with cold water and the internal administration of digitalis, potassium bromide, and minute doses of phenacetin in whiskey toddy constituted the basis of the treatment for that day. The unconscious state continued with elevated temperature all that day and following night—but finally the temperature slowly fell

to 103° and continued at this height with slight remissions forty-eight hours longer. The hand in the meantime did not improve. The vitality of the affected area had been permanently destroyed and a line of demarcation began to show itself before the third day. This line mapped out with absolute precision the whole erectile area on both the palmar and dorsal surfaces. The sloughing process did not extend one line's breadth beyond the diseased area, but when the sloughs were removed, it was found that only half of the palm had been left, together with the third, fourth and fifth metacarpals and their corresponding fingers. The medius was so much denuded on the radial side that I decided, some time later, to turn it down after the extirpation of the unguis phalanx, and utilize it to fill the gap caused by the removal of the second metacarpal and index finger. The hand is now reduced to part of the palm and two last fingers, which are very useful to the patient.

The remarkable feature of this case is the limitation of the slough to the diseased tissues, which were differentiated from the normal elements with extraordinary accuracy and in a manner that could not have been approached by the surgeon with the help of the naked eye. At the same time it teaches the lesson that conservatism in these cases is dangerous and that radical measures should be preferred from the start. The sloughing was evidently due to three unavoidable causes, viz.: (1) impaired vitality from arrested arterial supply; (2) prolonged ischemia caused by Esmarch bandage; (3) interference with a weakened circulation by firm and prolonged compression, with a view of maintaining hemostasis after the operation.

The conclusion is finally forced upon us that in advanced cavernous angioma of the hand which involves the deeper structures and the true derm as well, it is best to amputate, as conservatively as possible, as an initial procedure.

OBSERVATION 9.—Gunshot injury causing a large traumatic aneurism in the lower and inner femoral region. Incision of the whole sac along the line of the femoral vessels ten days after injury. Exposure of the femoral artery and vein completely divided at the bottom of the sac in Hunter's canal. Ligation of both trunks. Packing and iodoform gauze. Recovery without notable complications.

This case is selected out of a group of four traumatismis involving the ligation of the femoral because of the special severity of the injury, which included both the artery and vein in their passage through Hunter's canal. The patient, N. D., a white laborer, æt. 21, was admitted to Ward 8, Charity Hospital, in the summer of 1892. He stated that he had been shot accidentally by a friend. The revolver carried a 38-caliber bullet, which appeared to enter the middle of the thigh, near the apex of Scarpa's triangle, and then took a downward and inward course, to escape finally in the popliteal space, near the inner border of the inner hamstring tendons. The injury had been received the day before, and the patient had been admitted shortly after and put to bed, as it was evident that one of the femoral vessels had been injured. Much blood flowed through the anterior opening; a firm compress over this controlled the external bleeding, but the rapid swelling of the thigh indicated that a large hematoma was forming.

A firm bandage was applied and ice bags were kept over the wounded area, but the tumor continued to increase in size and soon developed a characteristic heaving pulsation, purring thrill and murmur which indicated the advent of the aneurismal state. On the 10th day after the injury, the patient was placed under the influence of chloroform, and after the application of the Esmarch, the sac was opened freely throughout its whole length.

The aponeurotic covering of Hunter's canal was divided, and a complete transverse section of the artery and vein was discovered. The artery had retracted, the divided ends being only held together by a portion of the sheath. The ends of the injured vessels were secured with sterilized silk ligatures, and the whole cavity packed with iodoform gauze after thorough preliminary irrigation with hot sterilized water.

The recovery of the patient was uneventful. A slight flexor contraction of the leg upon the thigh remained for several months, but I have recently examined the patient and he has now no trace of the injury in his walk. The scars alone indicate the site of the injury.

OBSERVATION 10.—Punctured and incised wound of the superficial and deep palmar arches. Wound soiled by cobwebs and perchloride of iron. Great prostration and acute anemia from excessive bleeding. Anesthesia, careful washing of the wound; bleeding points secured with hemostatic clamps; iodoform tampon in wound. The limb immobilized by long extensor and flexor splints and aseptic dressing. Removal of the hemostats in three days followed by complete healing by granulation.

In November, 1892, the patient, a robust male, *æt.* 36, while clumsily opening an oyster with an unusually sharp knife transfixes the left palm through and through, so that the rounded end of the knife appeared on the dorsum between the third and fourth metacarpals. Profuse bleeding followed, which indicated that an important vessel had been injured. He was brought to a neighboring drug store for assistance, but a handful of cobwebs had been applied in the meantime over both bleeding orifices. The druggist applied a compress of lint soaked in perchloride of iron and then bandaged the hand. This temporarily checked the bleeding, but in a few hours the hemorrhage recurred, soaking through the bandage, the blood soon dripping to the floor. When I saw the patient late at night, I found him exceedingly weak, with a small, rapid pulse. There was great pallor, nausea and inability to sit up. After the administration of aromatic spirits of ammonia, digitalis and brandy, I unbandaged the hand and applied an Esmarch bandage. A mixture of equal parts of chloroform and ether was administered and well taken by the patient. The whole hand was dipped into a bowl of hot carbolized water and scrubbed until the hard perchloride clots and cobwebs had been washed away.

The palmar wound was then freely enlarged on a line corresponding to the long axis of the medius and its metacarpal until the deep tendons were exposed. It was evident that both the superficial and deep arches had been injured, and that it would not be an easy matter to discover the bleeding points in the midst of the stained tissues. Nevertheless, after freely exposing the whole depth of the wound, the constrictor was relaxed and the point from which the blood spurted at the bottom

of the wound was promptly secured with a Tait's clamp, which was left *in situ*. The wound in the superficial arch gave no trouble and all further oozing was readily controlled by a firm iodoform gauze pack. A long extensor splint reaching to the elbow was then applied and the arm was thus immobilized. Three days after, the splint was removed and the hemostat unclamped. The wound had a healthy appearance and finally healed without accidental complications.

This case is presented to illustrate a simple method of treatment for an injury which is not rare and which is likely to cause no small amount of worry to the inexperienced practitioner.

It is well known and admitted that the ligature of the arteries in the forearm for a bleeding palmar arch is untrustworthy, and that nothing short of the ligation of the brachial at the bend of the elbow above the bifurcation, as recommended by Thiriar, of Brussels, can give security against secondary hemorrhage. But the ligation of the brachial at the bend of the elbow, simple as it may appear to the surgeon of experience, is nevertheless an *anatomical* operation which many practitioners will hesitate to attempt. Furthermore, it is always unsurgical to ligate a parent trunk when it is possible to control the bleeding vessel at the bleeding point. The danger of septic teno-synovitis has been the chief drawback in the past against the ligation of the deep palmar vessels. The difficulty of securing a bleeding vessel in the depths of the palm has also discouraged the application of the ligature in the wound, and favored ligation at a distance, but the modern methods of antiseptics and hemostasis have greatly cleared the field of these objections.

The practitioner of the present day should find no more difficulty in controlling a palmar hæmorrhage *in loco* than he would in dealing with bleeding in wounds of other localities.

