

MAYO (W. J.)

LOCALIZED TUBERCULOSIS
OF THE INTESTINE,
*WITH A REPORT OF
SEVEN OPERATED CASES.*

BY
W. J. MAYO, M. D.,
Surgeon to St. Mary's Hospital, Rochester, Minn.

REPRINTED FROM THE
New York Medical Journal
for August 19, 1899.

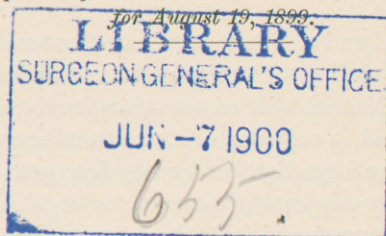
LIBRARY
SURGEON GENERAL'S OFFICE

JUN - 7 1900

655

Reprinted from the New York Medical Journal

for August 19, 1899.



LOCALIZED TUBERCULOSIS OF THE INTESTINE,

*WITH A REPORT OF SEVEN OPERATED CASES.**

BY W. J. MAYO, M. D.,

SURGEON TO ST. MARY'S HOSPITAL, ROCHESTER, MINN.

TUBERCULOSIS within the abdomen is of frequent occurrence, and clinical experience in abdominal surgery demonstrates that the disease as a primary infection is not uncommon, or, if not primary in all cases, the abdomen is, at least, the only locality involved in which it can be recognized.

The prevalence of tuberculosis of the bowel in children is shown by the statistics of Simms Woodhead. In a hundred and twenty-seven autopsies on children dying of tuberculosis the mesenteric glands were found to be involved in one hundred, and it is to be presumed that the intestinal was the primary lesion.

In the New York Pathological Society for November, 1898, Dr. R. G. Freeman reported a case of primary tuberculosis of the colon in a child and discussed the mooted point as to its frequency.

In adults the bowel infection is usually secondary.

* Read before the Minnesota Academy of Medicine, February 1, 1899.

Five hundred and sixty-six out of one thousand autopsies held on the victims of tuberculosis in the Pathological Institute of Munich showed secondary involvement of the intestines, and in only one case was the disease primary. Hilton Fagge says that in twenty-five years at Guy's Hospital only one case of primary tuberculous ulcer of the intestine was found. He, however, notes some intestinal strictures which may have had such origin.

The frequency of primary tuberculosis of the intestine in children is believed by Osler to be due to milk infection; it has been shown by Ernst that the milk may be actively infected without disease of the udder. Adult foods, such as cooked meats, etc., are less dangerous as a primary source of disease.

The prevalence of pulmonary tuberculosis in the adult and the frequency with which sputum is swallowed accounts for the secondary nature of the intestinal deposits.

H. A. Tomlinson, superintendent of the St. Peter, Minnesota, State Hospital for the Insane, has had an exceptionally large experience in the pathological study of tuberculosis among the inmates, and, as the mentally deficient usually swallow the sputum, he has found secondary intestinal infection to be the rule.

Osler mentions the possibility of secondary bowel infection through extension from the peritonæum.

Dr. N. Senn, in a most exhaustive paper on Intestinal Tuberculosis published in the *Journal of the American Medical Association* in May and June, 1898, says: "That the disease may occur as a primary infection can no longer be doubted. The results of an enormous clinical experience and thousands of necropsies furnish a substantial verification of this fact."

It is hard to reconcile the divergent opinions of men of large experience as to the relative frequency of primary intestinal tuberculosis. With a view of ascertaining the relative proportion from the standpoint of the operating room, rather than the deadhouse, I have examined the records and printed reports of St. Mary's Hospital of our city for the past six years. I find the total number of operations classed as abdominal within this period to be one thousand and three, and of this number sixty-four have been for tuberculosis, divided as follows: Tuberculous peritonitis, thirty; encapsulated tuberculous collections of fluid forming an abdominal tumor, three; ovaries and tubes, eleven; appendix, seven; kidneys, seven; intestinal wall, six. The patients treated in this hospital are drawn almost entirely from an agricultural community.

The reports previous to 1893 contain but few cases in which the diagnosis was made, although I have reason to believe it was often met with but went unrecognized. This would give tuberculosis a place in abdominal surgery of about six and a half per cent. The six cases in which the intestinal wall was involved and in which the infection appeared to be primary would amount to six tenths of one per cent. of the total number. These few cases, with the addition of one case operated in at St. Mary's Hospital in 1891, form the basis of this paper.

Experiments have shown that the tubercle bacillus is not killed in the gastro-intestinal juices, and that it is able to penetrate the intact mucous membrane. Peyer's glands and the lymph follicles are the common seat of infection, but the process soon involves the submucous tissue and then ulcerates through the agency of a

mixed infection. In primary tuberculosis the greater part of the involved tissue may slough, and by cicatrization a corresponding narrowing of the intestinal lumen take place.

The consequent interference with the progress of the intestinal contents may be the first symptoms of the disease. This form of obstruction in an acute stage led to operation in three of the reported cases.

In the causation of the symptoms the effects of secondary pyogenic infection is of the utmost importance. The peritonæum becomes thickened and boardlike over the ulcerated area, and to this point the neighboring coils of bowels may become attached, leading to kinking and partial obstruction, or form multiple intestinal fistulæ.

A complete ulceration through all the coats of the intestinal wall protected by adhesions may allow of a localized tuberculous pocket, giving the appearance of an abscess, as in Case V.

Rokitansky long ago pointed out the tendency of intestinal tuberculosis to follow along the blood-vessels and produce a circular deposit, as carcinoma is wont to do.

The healing process when established in such ulcers leaves a circular stricture. In secondary tuberculosis there is but little tendency to cicatrization, and the extent of disease is usually larger.

Primary tuberculosis in children is less apt to ulcerate deeply, the rule being early involvement of the mesenteric glands, which in turn act as a distributing depot to the general system, either through the lymphatic channels or blood-vessels.

The experience of nearly all observers has been that in adults there is a distinct tendency for the primary

disease to remain local, the prognosis, therefore, being far more favorable than in children. Senn points out the fact that in very many cases supposed to be primary there are other infected localities which may not be recognized.

The most common seat of primary tuberculous disease is in the ileo-cæcal coil. The sigmoid and the lower ileum are also often affected, although any part of the intestinal tract may be involved.

Senn describes two forms of disease: one fibrous, with markedly great hypertrophy, resembling carcinoma, and an ulcerative variety, more apt to cause stricture. The two phases of disease are often present in the same case.

According to Hofmeister, multiple strictures are found only in the ileum. The appendix is often the starting point of the infection in the cæcum.

The diagnosis of secondary tuberculous infection of the intestines is usually easy, but this can not be said of the primary variety. In only two out of the seven cases herein reported was the diagnosis made. In Case IV the appearance was that of cancer, although tuberculosis was thought of.

In a general way it may be said that the ages of the patients range between fifteen and forty. In my own cases the youngest was eighteen and the oldest thirty-seven.

A tuberculous family history was present in only two, and was not marked in either case. The general appearance in the cases with obstruction was good up to the time of the sudden bowel stoppage, and in none of the cases reported has there been the cachexia of a cancerous affection of the same duration.

In the three cases having the largest extent of ulceration there has been some evening rise in temperature.

In the majority of cases alternating constipation and diarrhœa have been observed, and in the strictured individuals serious symptoms of obstipation have appeared several times before the attack of obstruction rendered relief imperative. In only one case was diarrhœa marked, and in this patient the cæcum and ascending colon were extensively involved. Diarrhœa would argue in favor of larger extent of ulcerated surface, and is common in the secondary forms of the disease.

The constant symptoms in all cases have been colic and colicky pains, and in five out of the seven cases urinary irritation was an annoying feature.

Fixation of the uterus with seeming enlargement of the ovaries and tubes led to operation in two cases. In each instance a peculiar change in the apparent size and consistence of the lateral masses was manifest on different days, probably due to the amount of retention of bowel contents above the stricture, and perhaps, also, as Dr. H. A. Kelly has pointed out, to the changing amount of fluids in the coincident pelvic disease.

Rigidity of the abdominal muscles, preventing accurate palpation, was also present in these two cases, and in the experience of the writer this peculiarity with an undue sensitiveness has been common in tuberculosis of the ovaries and tubes.

A well-marked tumor in the cæcal region was present in three cases, and this enlargement was nodular and apparently contained gas.

Examination of the stools for tubercle bacilli should be practised, although the limited extent of dis-

ease does not lead to frequent success. Sawyer says that the mucous membrane just inside the sphincters is most likely to contain the germs.

Rectal discharges of pus and blood should lead to a careful examination of the rectum and sigmoid by Kelly's method. I have under observation at this time a patient with marked tuberculous ulceration of the sigmoid detected in this manner.

Strictures resulting from the healing of tuberculous ulcers must be distinguished from the congenital and traumatic varieties and from those following the reduction of inflamed hernias.

Only one case in which a stricture followed typhoid ulceration could be found by Treves. Syphilitic stricture, according to Senn, is always fibrous and never ulcerative. Of the various forms, the carcinomatous stricture will give the greatest difficulty in diagnosis, even when the parts are exposed. In both, enlarged glands are found. The tuberculous glands are hard and cheesy. The carcinomatous area will have dilated and tortuous blood-vessels underneath the peritonæum; it also shows no scars of cicatrization and is not so densely adherent in the early stages as the tuberculous variety. Maylard speaks of œdema and inflammation in the vicinity of the umbilicus as an indication of ulcerative tuberculosis, and Tillmanns remarks on the frequency with which chronic indurations of the abdominal wall, with slow formation of abscess, are followed by fistulas communicating with the bowel.

In Senn's monograph, previously referred to, will be found a differential diagnosis worthy of the most careful study.

The indications for treatment may be divided into

two classes: First, for the tuberculous process itself, and, second, for the relief of mechanical interference with intestinal action, the result of cicatrization. The management of localized intestinal tuberculosis without obstruction is certainly surgical; but to what extent should the operation be carried?

Clinical experience has demonstrated that nearly all forms of primary tuberculosis in the abdomen may be cured by simple incision of the peritonæum, and many cases of tuberculous intestinal disease relieved in this way have been placed on record.

It is possible that the "malignant tumors" in the abdomen cured by laparotomy, recorded by Tait and others, may have been tuberculous.

Removal of the cæcum and ileo-cæcal coil or ascending colon has been practised with good results, and many cases are now recorded by Senn, Pilcher, Ochsner, Koerte, Sachs, and others. In most cases extensive regional glandular infection will be found. The appendix is frequently the starting point of disease, and has often been removed, leaving the tuberculous cæcum and caseating glands untouched, and yet apparent cure has resulted. Each case must be judged on its own merits.

Strictures following upon the healing process and causing mechanical obstruction of the bowels belong to the radical operations of necessity.

Intestinal resection or extirpation of the ileo-cæcal coil is most frequently demanded. Occasionally the extent of the involved area or the debilitated condition of the patient may render intestinal anastomosis above and below the obstruction the safer procedure. This is particularly the case in extensive disease of the ileo-

cæcal coil, rendering ileo-colostomy the operation of choice. Senn notes in this connection that even a short length of remaining large bowel is sufficient to dry the stool, and this was our experience in Case IV, in which the patient was operated upon by Dr. C. H. Mayo; also in a second case of ileo-colostomy for the relief of ileo-vaginal anus, reported in the *Annals of Surgery* for November, 1897.

In other cases the adhesions of coils of bowel to the peritoneal plaque covering an intestinal ulcer may lead to angulation. In two of our cases this condition alone seemed to account for the obstruction. On separating these points of union we have noticed that the adhesions were thick and more vascular than in the ordinary inflammatory disease as encountered in the pelvis, and there were no planes of cleavage discoverable. There was also a structural change involving all the coats of the bowel at one limited point of contact. On separation, the affected parts had an eroded granular appearance, looking like a lupus of the skin after removing an adherent scab.

All these places should be either cleanly excised or turned into the bowel and carefully sutured in this position, as a point in the centre usually communicates with the intestinal lumen.

If the suture is secure and there is no need of gauze protection against possible leakage, silk should be used for that purpose, but if it seems desirable to quarantine the suspicious area, catgut should be employed as a suture material. In our experience the tract established by the gauze is almost certain to become infected with pyogenic organisms, and silk at the bottom of a tuberculous sinus means chronic suppuration, and a fistula

having a communication with the bowel will ultimately form.

Drainage of primary wound secretion in the abdomen is seldom necessary in chronic disease, and usually does not take place even if desired, but occasionally a suspicious point should be isolated and connected with the surface by the formation of adhesions around a piece of gauze, to protect against infection or leakage.

Such treatment leaves much to be desired. The post-operative suppuration in Cases IV and V was of a peculiar oily character, very foetid, with, eventually, a minute fæcal fistula; both of these patients had a considerable elevation of temperature while the discharge lasted.

If catgut has been used, the fistula will heal spontaneously in from three to twelve weeks, according to its extent; at least, this has been our experience.

In Case III there was no protection. While no post-mortem was secured, I believe there was a leakage at the suture line.

Intractable tuberculous ulceration of the sigmoid, either with or without stricture, has been successfully treated by a temporary or permanent inguinal colostomy.

In looking back over our experience in this class of cases we note their wonderful ability to withstand operative interference. The chronic nature of the disease seems to furnish a partial immunity to injury and operations can be fearlessly undertaken which would be unjustifiable in acute infections or cancer. The operations performed in several of these cases were very incomplete and unsatisfactory, yet apparent cure resulted.

CASE I. *Localized Tuberculosis of Ileum; Separation of Adherent Intestinal Coils; Secondary Operation for Fæcal Fistula; Recovery.*—Miss M. K., single, aged twenty-three years; American; Westfield, Minnesota. Admitted to St. Mary's Hospital, July 8, 1891, with a history of abdominal swelling and pain of a colicky character, which had begun rather suddenly a year previous. Constipation alternating with diarrhœa and occasional attacks of vomiting were prominent symptoms. Menstruation prolonged and excessive, bladder irritable. There had been a progressive loss of weight and strength. Family history negative. Examination of heart, lungs, and urine negative; temperature, 100° F.; pulse, 100; abdomen tympanitic; muscles rigid and in places board-like; uterus fixed by masses of a rather peculiar character in the small pelvis. This local condition on several examinations on different days never appeared twice just alike.

A diagnosis of pelvic peritonitis, probably of tubal origin, was made, and on July 12th the abdomen was opened in the middle line; the peritonæum was very thick and the omentum generally adherent; there was no fluid, and the intestines in the small pelvis were more or less covered with adhesions, and had formed the mass felt on vaginal examination.

In the vicinity of the umbilicus the small bowels were matted together, forming a partial obstruction. On separating these adhesions a coil of ileum was found to have a large, thick cicatrix on its free surface, not of itself obstructive, but to which the neighboring intestinal coils had become adherent. The adjacent peritonæum was studded with tubercles. A small drain was inserted and the abdomen closed.

On the sixth day the abdominal wound opened and began discharging the contents of the upper small bowel, the escape of food taking place within a few minutes of its ingestion. The prostration became extreme. Three weeks after the first operation a finger introduced into the fistula showed a sharp spur in the bowel at the angle of adhesion; this spur was caught with a pair of forceps,

one jaw in the afferent and one in the efferent portion of the bowel, and clamped (method of Dupuytren). Five days later the forceps cut its way through, and after a trying time during the next three months the wound healed. The patient completely recovered, and now, seven years and a half later, is in excellent health.

CASE II. *Tuberculous Ulceration of Ileum causing Obstruction; Intestinal Resection; Recovery.*—C. K., a man, aged eighteen years; German; Janesville, Minnesota. Admitted to St. Mary's Hospital October 8, 1896. Five months previously he had been suddenly seized with vomiting and pain in the hypogastrium. The abdomen became bloated and bowel movements could not be secured for a number of days. There had been some urinary distress. After three weeks he improved and was able to be about, but the colic and distress were almost constant; movements from the bowels were exceedingly hard to obtain, and gave only temporary relief. There was a gradual loss of seventy pounds in weight; nausea was constant, and vomiting of daily occurrence. Family history good.

Examination.—Emaciation extreme; pulse, 130; temperature slightly subnormal. Urine contained a tenth of one per cent. of albumin, and indican in abundance. Heart and lungs normal. Abdomen greatly distended, and the dilated coils of intestines could be plainly seen during peristalsis. No tumor could be discovered.

Diagnosis, chronic obstruction of the small bowel. Operation, October 9th. On opening the abdomen, coils of the greatly distended small bowel protruded and were allowed to remain outside under hot towels in sufficient quantity to expose the seat of trouble, which consisted of an adherent mass of ileum near the ileo-cæcal junction. In attempting to separate the adhesion and relieve the obstruction the distended bowel was opened and at once emptied and sutured. A large ulcerated and partially cicatrized surface was finally disclosed in the ileum, and this communicated with two coils of bowel by fistulous openings. In attempting to liberate this portion of bowel it was torn completely through.

Four inches of the ileum, including the diseased area, were excised and an end-to-end suture anastomosis effected. This was rendered very laborious on account of the inability to bring the parts to the surface, and the great disparity in size and thickness of the muscular coats of the two parts of the bowel united, the proximal portion being greatly dilated and much thickened.

The fistulous openings in the adherent coils were excised and the defects closed by purse-string sutures. A gauze drain was inserted. On removing the drain on the fifth day a small faecal fistula developed, which spontaneously closed in fourteen days.

Discharged November 14th in good condition. Now, two years and a half after the operation, he is in perfect health, and has gained a hundred pounds in weight. The pathological specimen showed the characteristics of tuberculous ulceration.

CASE III. Localized Tuberculosis of Sigmoid and Tubo-ovarian Disease; Secondary Involvement of Ileum and Bladder; Operation; Death.—Mrs. F. H., aged thirty-six years; American; married; no children; Kasota, Minnesota. Admitted to St. Mary's Hospital April 29, 1897, with a history of pelvic pain extending over a period of six years. Bowels obstinately constipated. Bladder irritable. Menstruation excessive and lasting from ten to fourteen days. Digestion poor, colics frequent. Family history of tuberculosis and cancer.

Physical Examination.—Patient fairly well nourished. Heart and lungs normal. Urine contains a few pus corpuscles. Pulse, 96; temperature, 98.4° F. Abdominal muscles rigid. Uterus retroverted and adherent. An indefinite painful swelling can be plainly felt on each side of the uterus.

Diagnosis, inflammatory disease of tubes and ovaries.

Operation on May 1, 1897. A coil of lower ileum and the bladder adherent to the sigmoid. There were no planes of cleavage, such as are usually found in inflammatory disease. The tissues were friable and looked granular when separated. Both the bladder and ileum were opened during separation and the injuries at once

were carefully sutured. An irregular ulceration of sigmoid, partially cicatrized, was drawn to the surface, turned in, and the peritonæum sutured over. The ovaries and tubes were bound down by dense adhesions, and both tubes contained straw-colored fluid. The appendages were removed and the uterus suspended anteriorly. The abdomen was closed without drainage. Death occurred on the fifth day from septic peritonitis. There was no post-mortem.

CASE IV. *Tuberculosis of Cæcum and Appendix; Operation; Improvement; Readmitted Seven Months Later with Obstruction of the Bowels; Ileo-colostomy; Recovery.*—Mrs. H. O., aged thirty-seven years; American; New Richland, Minnesota. Married and the mother of nine children, the youngest of whom is three years old. She has not been well since the birth of the last child, has been weak and tired, and hardly able to do her work.

For the past six months has had a constant pain in the right side and has suffered from cramps in the bowels; constipation alternating with diarrhœa and occasional discharge of a slimy character has been observed. There has been some irritation of the bladder, quite annoying at times. Menstruation normal. Patient also states that there is an enlargement in the right side which, she thinks, has been present for three years, and is increasing in size. Family history good.

Physical Examination.—The patient is of an anæmic appearance. Temperature, 99.5° F.; pulse, 100. No evidence of disease in the lungs. Heart normal. Urine contains pus corpuscles. An indefinite thickening in the region of the right broad ligament can be felt through the vagina and rectum. In the right side of the abdomen is a well-marked enlargement occupying the position of the cæcum and extending upward to the lower free ribs. It is irregular in outline and appears to contain gas. Diagnosis, probable carcinoma of the cæcum.

Operation on April 28th. A free incision was made directly over the enlargement, which was found to be

the cæcum. It was adherent and the surface was marked with boardlike scars. The appendix was thoroughly involved and lay in the pocket under the ileo-cæcal junction. The right ovary and tube were also involved in the caseating mass. Lymphatic glands in the neighborhood were enlarged and cheesy. A portion of the cæcum was excised with the appendix and right ovary and tube. A retrocæcal tuberculous pocket was curetted and iodoformized, and an iodoform gauze drain was inserted. On its removal a small fæcal fistula appeared. For six weeks an oily offensive discharge continued, and a continuous temperature elevation was noted. Patient was discharged with a cicatrized wound June 8th.

In September the patient was reexamined and appeared to be in excellent health, having gained thirty-three pounds in weight, but she complained of some stomach disturbance, with attacks of vomiting and obstinate constipation, which have appeared within two weeks.

November 7th.—The patient was readmitted to the hospital suffering from obstruction of the bowels, which had lasted nearly a week; vomiting was frequent and the abdomen was markedly tympanitic. It appeared that the symptoms of obstruction had been steadily increasing since the examination in September, and were relieved with more and more difficulty until the trouble had culminated in the present attack. It was also noted that the bladder had become involved, and shortly before an abscess had opened into this viscus and still discharged by this route, to her great distress.

Operation by Dr. C. H. Mayo. The ileo-cæcal coil was involved in a tuberculous process producing the obstruction. An indurated area connected this with the bladder and this extensive disease was not disturbed. The ileum was divided eight inches above the ileo-cæcal valve at a point well above the disease, and the distal portion was emptied and the cut end turned in and sutured. The proximal end of the ileum was anastomosed with the transverse colon by a Murphy button.

The contents of the enormously distended small bowel

were milked through the button into the colon. The abdomen was closed without drainage. The bowels acted freely within a few hours and the patient rapidly convalesced. The discharge of pus and tuberculous débris through the bladder immediately lessened, and in four weeks entirely disappeared. The button came away in twelve days. Patient was discharged December 15th in good condition. The ultimate result would seem to be uncertain.

CASE V. Tuberculosis of Cæcum and Ascending Colon; Formation of Tuberculous Abscess; Operation; Improvement.—Mrs. F. A. G., aged thirty-seven years; American; Le Roy, Minnesota. Admitted to St. Mary's Hospital September 27, 1898. Has been married two years, and is the mother of one child, two months old. She has been unable to nurse her child. Menses have not reappeared as yet. She states that for two or three years she has been annoyed by a pain in her right side, which was aggravated by the pregnancy.

After confinement, her physician, Dr. McMillet, of Le Roy, discovered a tumor in the right side of the abdomen, which has been exceedingly tender. Bowels irregular, of late a tendency to diarrhœa. Family history of tuberculosis.

Physical Examination.—A spare woman of anæmic appearance. Heart and lungs normal. Urine negative. Temperature, 101° F.; pulse, 110; generative organs normal. There is an oblong mass in the right side occupying the usual situation of the cæcum and ascending colon, which feels hard and nodular; it evidently contains gas. In the loin there is a tendency to induration which may be due to a deep-seated abscess. Leucocytosis not present. Diagnosis, tuberculosis of cæcum with secondary abscess.

Operation on October 1, 1898. A lateral incision was made with its centre over the inflamed area. On opening the abdomen, the walls of the cæcum and ascending colon were found to be enormously thickened, and in places, ulcerated patches, well roofed in by thick plastic deposit, could be made out.

The deep glands behind were caseated. The inflammatory deposit was a typical tuberculous abscess, adherent to the abdominal wall and communicating with the colon, into which it evidently discharged. The colon was opened and extensive tuberculous ulceration could be seen. So far as could be demonstrated, the disease was confined to this region. The abscess cavity was iodiformized and packed with gauze, and the opening in the bowel repaired and covered with an omental graft. A slight faecal fistula followed the removal of the gauze drain on the fourth day, and for six weeks a foetid oily discharge continued.

During this time the patient constantly had high temperature. Discharged from the hospital November 8th, greatly improved in health. Now, four months after the operation, the mass is very much less prominent, and there is a gain of thirty pounds in weight, and a corresponding improvement in general health can be noted.

CASE VI. *Tuberculosis of Sigmoid, causing Stricture; Operation for Obstruction of the Bowels; Recovery.*—Mrs. J. A. W., aged thirty-four years; Lime Springs, Iowa. Admitted to St. Mary's Hospital June 27, 1898. Patient has been married two years; no children. She has had three well-marked attacks of appendicitis, and at this time is just recovering from the fourth attack. Her physician, Dr. J. W. Reed, of Lime Springs, states that the character of the trouble appears to have changed, the earlier attacks being typical, while the illness from which she is now convalescing has been in the nature of an obstruction of the bowels. Menses regular, bowels generally constipated. Family history good.

Physical Examination.—Patient of delicate physique. Temperature and pulse normal. No evidences of disease of lungs, heart, kidney, or generative organs. Palpation of the appendix elicited some complaints of pain.

A diagnosis of relapsing appendicitis was made on the history. On June 26th the diseased organ was re-

moved through a short lateral incision. The appendix was adherent and contained several strictures. There were no signs of recent inflammation. Discharged July 15th.

Within one week of her arrival home she experienced another attack precisely like the last one. The obstruction was never fully relieved from that time. The vomiting, intense pain, and abdominal distention yielded only after great effort to act upon the bowels, and the relief afforded was very temporary. It was noted in this later history that only small enemata could be retained, although nothing could be felt by digital examination through the rectum.

Patient readmitted October 15th in bad condition. Pulse rapid and feeble. Abdomen greatly distended with gas, peristalsis being markedly visible. This was especially noticeable in the left iliac region. Emaciation extreme. No action of the bowels had taken place for two weeks; once flatus had escaped. The vomiting was almost constant, and the pain could be checked only by the subcutaneous exhibition of morphine.

Operation was performed as soon as the patient could be prepared. A median incision revealed a tangled mass of bowel in the pelvis. This proved to be two coils of ileum adherent to a point on the sigmoid within two inches of the beginning of the rectum. The separation was difficult and resulted in opening each loop of the small bowel. The adhesions were not general, but rather a dense union over a small area, being friable and granular. The surfaces containing the defects in the intestinal wall were turned into the lumen of the bowel by sutures. The disease in the sigmoid seemed to completely surround the gut, and it could not be brought to the surface. An assistant placed two fingers in the rectum and I was able to depress the stricture sufficiently to invaginate it into the rectum, while my assistant forced his fingers through and dilated it thoroughly. In doing this, the friable tissues ruptured. This was repaired as well as time would allow by transverse suturing, which enlarged the opening, and the result was far from being

satisfactory. The pelvic peritonæum was studded with tubercles.

A large iodoform-gauze tampon was placed to protect against the expected leakage. The sigmoid was brought to the surface and fastened to the upper end of the wound above the drainage, and marked with black silk guides, and finally the ileum proximal to the sutured parts was fastened along the side of the sigmoid to the peritoneal edge of the wound, and also marked with silk guides, to be used should it be necessary later to open the bowel to relieve the obstruction.

Patient in collapse, from which she but slowly recovered. The obstruction was not relieved, and the condition appeared to be hopeless. In forty-eight hours the sigmoid was opened, but without relief; twelve hours later, although the patient was barely alive, the small bowel was opened and some gas and liquid contents began to escape.

From this time on the discharge of small-bowel contents became profuse, and after a prolonged struggle the patient rallied. The fistulous openings healed spontaneously. The stricture below can now be reached by the fingers in the rectum and is stretched digitally twice a week. The patient is gaining rapidly in weight and strength. Discharged January 8, 1899.

CASE VII. *Tuberculosis of the Cæcum and Appendix; Appendectomy; Improvement.*—Miss A. E. B., German, aged eighteen years; Elma, Iowa. Admitted to St. Mary's Hospital November 28, 1898. The following history was obtained: Attacks of abdominal pain began about eight months ago. These spells have grown more severe and are accompanied by diarrhœa. From the first the looseness of the bowels has been marked, and the discharges are slimy and offensive in character. There has been some urinary irritation at times. Menses stopped five months ago. The weakness has been progressive and she has lost thirty-five pounds in weight. There has been a more or less constant soreness in the right side. Family history good.

Examination.—A slender, anæmic girl, with a pulse

of 116 and temperature 101° F. Lungs, heart, kidneys, and generative organs show no evidences of disease. Abdomen tympanitic, and considerable gurgling can be developed in the colon. The region of the cæcum is board-like and the lower right rectus muscle is fixed.

An indefinite enlargement at this point can be mapped out, which contains air and fluid. Examination of stools for bacilli of tuberculosis negative. Diagnosis, tuberculosis of cæcum and ascending colon.

Operation on November 30th. Cæcum adherent and greatly thickened; on releasing the adhesions, white, boardlike scars can be seen.

The appendix was of large size and cheesy, breaking off close to the cæcum while enucleating it. The deep glands were of considerable size and extended in a chain upward as far as could be reached. A gland was removed and found caseating. The omentum was converted into a ropelike mass and was adherent to the diseased area. The stump of the appendix was cut out of the cæcum, and the defect closed by suture.

The parts were iodoformized and the incision was closed without drainage. The diarrhœa was checked, and has not yet returned. The patient has gained in weight and strength, but the ultimate result is in doubt. Discharged December 29, 1898.

Physicians —

who desire to keep *au courant* with the advances
of medicine and surgery should read

**The New York
Medical Journal**

Subscription price, *per annum*, \$5.00

Volumes begin in JANUARY and JULY

D. APPLETON AND COMPANY, Publishers
72 Fifth Avenue, New York

